

Accepted Manuscript

Manual therapy and cervical artery dysfunction: identification of potential risk factors in clinical encounters

Brett Vaughan, Lecturer, Robert Moran, Philip Tehan, Gary Fryer, Mat Holmes, Steve Vogel, Alan Taylor



PII: S1746-0689(16)00025-0

DOI: [10.1016/j.ijosm.2016.01.007](https://doi.org/10.1016/j.ijosm.2016.01.007)

Reference: IJOSM 399

To appear in: *International Journal of Osteopathic Medicine*

Received Date: 25 May 2015

Revised Date: 17 December 2015

Accepted Date: 12 January 2016

Please cite this article as: Vaughan B, Moran R, Tehan P, Fryer G, Holmes M, Vogel S, Taylor A, Manual therapy and cervical artery dysfunction: identification of potential risk factors in clinical encounters, *International Journal of Osteopathic Medicine* (2016), doi: 10.1016/j.ijosm.2016.01.007.

This is a PDF file of an unedited manuscript that has been accepted for publication. As a service to our customers we are providing this early version of the manuscript. The manuscript will undergo copyediting, typesetting, and review of the resulting proof before it is published in its final form. Please note that during the production process errors may be discovered which could affect the content, and all legal disclaimers that apply to the journal pertain.

Manual therapy and cervical artery dysfunction: identification of potential risk factors in clinical encounters

Brett Vaughan^{1,2,3}

Robert Moran⁴

Philip Tehan¹

Gary Fryer^{1,2}

Mat Holmes¹

Steve Vogel⁵

Alan Taylor⁶

¹ Centre for Chronic Disease Prevention & Management, College of Health & Biomedicine, Victoria University, Melbourne, Australia

² Institute of Sport, Exercise & Active Living, Victoria University, Melbourne, Australia

³ School of Health & Human Sciences, Southern Cross University, Lismore, Australia

⁴ Department of Community & Health Services, Unitec Institute of Technology, Auckland, New Zealand

⁵ British School of Osteopathy, London, United Kingdom

⁶ Faculty of Medicine & Health Sciences, University of Nottingham, Nottingham, United Kingdom

Corresponding Author

Brett Vaughan

Lecturer, Osteopathy

Discipline of Osteopathic Medicine

College of Health and Biomedicine

Victoria University

PO Box 14428

Melbourne VIC 8001

Australia

P. 61 3 9919 1210

F. 61 3 9919 1030

E. brett.vaughan@vu.edu.au

Manual therapy and cervical artery dysfunction: identification of potential risk factors in clinical encounters

ACCEPTED MANUSCRIPT

ABSTRACT

Cervical artery dysfunction is a reported potential risk associated with manual therapy applied to the cervical and cervicothoracic spine. While a variety of physical examination tests have been advocated to screen patients who may be at risk of adverse events during or after manipulation, their clinical utility is limited. This paper provides an overview of the literature and current thinking with regard to risk assessment and clinical action related to the application of manual and exercise therapy for the cervical and upper thoracic spine.

ACCEPTED MANUSCRIPT

INTRODUCTION

For many years it has been proposed that a causal link exists between cervical spine manual therapy, particularly high-velocity 'thrust' manipulation, damage to the cervical arteries, and adverse neurovascular events. However, the literature investigating this link, although extensive, is inconclusive as it establishes an association rather than a clear undisputed causal relationship.¹⁻⁴ Nevertheless, it is important for practitioners to be aware of the potential risks associated with presentations of neck and head pain and manual therapy for the cervical and cervicothoracic area in order to inform patients and assist with clinical decision making. The inconclusive nature of the literature regarding the relationship between cervical spine manipulation and adverse neurovascular events is constrained by lower quality designs including case studies and retrospective audits of purported adverse events.

Whilst cervical artery dissections are the most clearly described and reported adverse event in the literature with respect to adverse events and pathology of the cervical arterial system, this review uses the term cervical artery dysfunction. This term better describes the range of disorders affecting the cervical arterial system, and includes pathology affecting the cranio-cervical structures, and local conditions such as dissection and insufficiency.⁵ The purpose of this commentary is to highlight the contemporary literature in this area and discuss the risk factors that may assist practitioners in identifying patients at risk of an adverse event or, more importantly, those currently experiencing a cervical artery dissection (CeAD) at the time of presentation.

EPIDEMIOLOGY

Cervical arterial dysfunction can involve the internal carotid and/or vertebral arteries. Although there has been an emphasis on the vertebrobasilar system in the manipulative therapy literature, it is important to consider not just the vertebrobasilar system, but the whole cervical arterial system. Consideration should also be given to

the pathologies and factors that affect the system, forming part of the clinical and diagnostic reasoning process.¹ The exact pathogenesis of non-traumatic CeAD remains unclear⁶ - it is possible that stroke or death following cervical spine manual therapy may be associated with pre-existing vascular pathologies.^{1,7} Kerry and Taylor⁸ have advanced an argument that our collective focus on this issue should not be limited to high-velocity low amplitude (HVLA) thrust manipulation applied to the neck, as "*The common denominator in the activities [non high-velocity thrust movements] indicated is cervical movement, thus the phenomenon might not be one of HVT [high velocity thrust], but of movement more generally*" (p. 11). This is a position also supported by other authors.^{9,10} In recent years, the role played by the styloid process as one mechanism to explain the relationship between carotid artery dysfunctions and cervical spine movement has emerged. Both increased styloid process length,¹¹⁻¹³ and proximity to the internal carotid artery,^{10,13} may be risk factors for CeAD when combined with cervical movements or trauma. Further, the hyoid bone has also been described as a potential mechanical compressor of the internal carotid artery.¹⁴

Data from the United States suggests the average annual incidence for CeAD is 2.6 persons per 100 000 population (95% CI 0.9 to 4.2),^{15,16} and it is noteworthy that dissections have been reported to occur in all age groups. Recent work by Metso et al.,¹⁷ distinguishes between internal carotid artery dissection (ICAD) and vertebral artery dissection (VAD). These authors report that ICAD is more likely to occur in younger age-groups (34-54 years) and VAD in older age groups (≥ 55 years), but regardless of the artery involved, the peak incidence occurs between 34 and 54 years of age.¹⁷ In a review of case series published between 1994 and 2003, Haneline and Lewokvich¹⁸ report the majority of CeAD are spontaneous (61%), 30% associated with trivial trauma, and approximately 9% associated with cervical spine manipulation. Based on a review of hospital medical records in the Canadian provinces of Ontario and Saskatchewan, Boyle et al.¹⁹ estimated that the incidence of stroke (or like event) was 0.855 and 0.750 per 100,000 person-years, however, there was no increase in the incidence associated with the number of manipulations performed. Manipulation applied to the cervical spine has been suggested as a risk factor, although as Kerry and Taylor⁸ suggest, the risk may be related to cervical spine movement rather than the manipulation *per se*. Further, there is limited agreement in

the literature regarding the strength of the association between cervical spine manipulation and VAD (Table 1), with point estimates ranging from *small* (OR = 2.41 95%CI 0.98 to 5.95) to *large* (OR = 11.9; 95%CI 4.28 to 33.2). The wide 95%CI for these point estimates suggests a degree of imprecision in the calculations, and the *true* point estimate could reasonably be anywhere between the CI values. Interestingly, Cassidy et al.²⁰ also reported *small* estimate (OR = 2.90; 95%CI 1.64-5.13) for patients having attended a primary care physician in the week preceding a stroke, similar to that reported for attendance at a chiropractor suggesting there may not be an “...excess risk of VA stroke...”⁹ (p. 4) when seeking chiropractic care.

Table 1. Association between cervical spine manipulation and vertebral artery dissection.

| Author | Point Estimate (OR) | 95% Confidence Interval | Interpretation of point estimate ¹ |
|-------------------------------|---------------------|-------------------------|---|
| Cassidy et al. ²⁰ | 2.41 | 0.98-5.95 | ‘Small’ |
| Rothwell et al. ²¹ | 5.03 | 1.32-43.87 | ‘Moderate’ |
| Smith et al. ²² | 6.6 | 1.4-3.0 | ‘Moderate’ |
| Engelter et al. ²³ | 11.9 | 4.28-33.2 | ‘Large’ |

Note: 1. Descriptors for the scale of magnitude for odds ratio based on Hopkins <http://sportsci.org/resource/stats/effectmag.html>

IMPORTANCE OF CLINICAL REASONING FOR IDENTIFICATION OF CERVICAL ARTERIAL DYSFUNCTION

Misdiagnosis as a consequence of deficient clinical reasoning is reported as one of the main factors associated with adverse events associated with manual therapy applied to the cervical spine.^{3,4} In a review of 134 cases of post-manipulative adverse events, Puentedura et al.²⁴ reason that 45% of cases were likely to be preventable if contraindications to manipulation (e.g., osteoporosis, rheumatoid arthritis, and cervical stenosis)

were identified and correctly interpreted. Several authors have also suggested that manipulation had been performed on patients who were already experiencing vascular dissection in progress at the time of manipulation.^{4,25,26} Grond-Ginsbach et al.²⁷ argue that asymptomatic CeAD may be “frequently undiagnosed” (p. 789), therefore highlighting the importance of identifying patients with a dissection in progress at the time of presentation. This suggests there could be considerable benefit in raising clinical awareness that vascular dysfunction may mimic cervical spine musculoskeletal complaints.^{28,29}

ROLE OF THE CLINICAL HISTORY

The clinical history is a fundamental part of the diagnostic process and can assist the practitioner in deciding on the appropriate examination(s) to be performed. It informs the development and implementation of an appropriate management plan for the patient.

Overview

It is essential that practitioners are mindful of the possibility that a patient with acute onset cervical spine pain may be presenting with a CeAD,^{17,20} because the initial symptoms of a dissection can mimic a musculoskeletal complaint.^{2,30,31} Symptoms of neck pain or headache associated with a dissecting cervical artery are thought to be due to the tunica adventitia of vessels being innervated with nociceptors.³² Schelfaut et al.³³ Schievink,³⁰ and Biller et al.⁹ suggest that these patients often present with at least two symptoms: typically unilateral head, neck or facial pain, and less frequently Horner’s syndrome* (accounting for approximately 50% of patients with ICADs). Headaches experienced by the patient are typically unilateral and in the fronto-temporal region, although they can present in the occipital region.^{30,34} Patients may characterise these headaches as a constant steady ache, throbbing or sharp, and importantly, their pain is commonly described as *unlike anything they have experienced previously*. Symptoms suggesting cranial nerve involvement have

* A collection of signs and symptoms including partial ptosis, miosis, anhydrosis as the result of interruption of the sympathetic nerve supply to the eye. Also referred to as Bernard-Horner syndrome.

also been reported,³⁵⁻³⁸ for example affecting the hypoglossal nerve.^{36,39,40} Horner's syndrome has been reported in approximately 33% of ICADs^{37,41} and 14.3% of VADs.⁴¹

Risk factors for CAD that may be identified in the history

From the research related to CAD, a number of factors in the clinical history have been identified that could assist the practitioner in identifying those patients who may have a dissecting cervical artery in progress or who are at risk of a CeAD.⁴² Table 2 lists factors that may contribute to the development of, or be potentially linked to CeAD. Questions should be targeted towards those that may help elicit information related to the historical factors that would indicate further examination or referral, prior to the application of manual interventions. In addition, consideration should be given to the genetic and congenital issues such as connective tissue disease, hyperhomocysteinemia, alpha-1 antitrypsin deficiency, fibromuscular dysplasia and Ehlers-Danlos syndrome as all have been associated with arterial dissection events.^{30,35,37,43} Several authors^{8,44} have also highlighted the potential for CeAD in post-partum women. Whilst dissections in this population are rare,^{44,45} it may be a clinically relevant differential diagnosis where other risk factors are present.

Table 2. Historical factors that could be linked to cervical artery dysfunction

-
- Acute onset unilateral cervical spine pain
 - Acute onset occipital, frontal, supraorbital or temporal headache
 - Current history of migraine (particularly without an aura)
 - Past history of migraine (particularly without an aura)
 - Family history of migraine
 - History of cervical spine trauma (including minor or 'trivial' trauma)
 - Onset of pain related to sudden cervical spine movement
 - Tinnitus (particularly 'pulsating tinnitus')
 - History of hypertension and risk factors for cardiovascular disease
 - Recent upper and/or lower respiratory infection (within the previous week)
 - Upper and/or lower extremity neurological symptoms and ataxia
-

Acute onset unilateral cervical spine pain

In terms of duration of complaint, cervical spine pain of less than one week duration is perhaps the most common presentation of a dissecting cervical artery, presenting in between 49% and 88%^{37,46,47} of CeADs. Given that pain of one week's duration is routine in manual therapy practice, a CeAD should be at least considered as part of the differential diagnosis for every patient presenting with recent onset cervical spine pain. Although Arnold et al.⁴⁸ suggest that pain associated with dissection may be of moderate intensity and described as 'constrictive', this offers little utility in differentiating between vascular and musculoskeletal causes. It is important to recognise that CeAD may present with a headache in the absence of cervical spine pain.³² Lee et al.¹⁶ report that 80% of CeAD present with pain in the head or neck, with up to 92% of VAD presenting with head and neck pain.⁴²

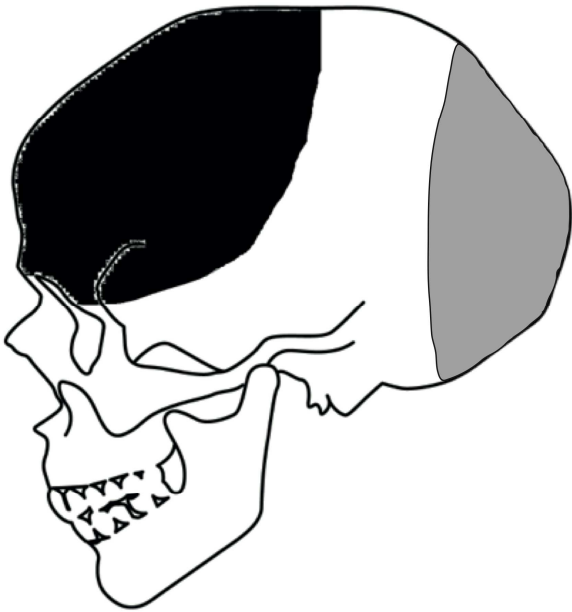
Acute onset headache: occipital, frontal, supraorbital or temporal

Headaches are a common presentation to osteopaths,^{49,50} and other manual therapy practitioners, and although the majority of presentations are benign, it should be recognised that a headache may also be the only symptom that a patient reports in some cases of a CeAD in progress. Over half of the patients with CeADs reported by Metso et al.,¹⁷ experienced headache as part of their presentation, and similar findings are also presented by Patel et al.,³⁵ and Bejot et al.³⁷ It is essential to recognise that headaches associated with CeAD are often accompanied by other signs and symptoms that can be revealed with careful questioning and examination.⁵¹ No distinct pattern to the headache has been identified in the literature however, the frontal, frontotemporal and frontoparietal regions have been suggested as being characteristic (see Figure 1).³⁵ All seven patients in a report of cases by Maruyama et al.⁵² described the intensity of the presenting headache as severe, typically with a throbbing nature. This is consistent with that reported by Arnold et al.,⁴⁸ however, this

picture is not a common one reported in the literature. Practitioners should consider CeAD as part of their differential diagnoses for every patient with an acute onset headache with or without trauma.

ACCEPTED MANUSCRIPT

Figure 1. Characteristic location of headaches related to a ICAD (black),³⁵ and VAD (grey).⁵³



In order to assist the differential diagnosis process, patients should be asked about their headache history. In particular, a current headache presentation which is new or different (e.g., increased intensity or different quality) to headaches previously experienced by the patient, should raise or increase the index of suspicion of a CeAD as the cause of the patient's presenting complaint. Signs or symptoms associated with the headache, including ptosis, facial numbness, ataxia/unsteadiness,^{43,54} should also raise the practitioner's index of suspicion.

Current or past history of migraine

A current or past history of migraine is associated with an increased risk of a CeAD,⁵⁵⁻⁶⁰ particularly in those under 33 years of age,¹⁷ and in females (these are independent risk factors).⁶¹ Pezzini et al.,⁵⁸ reported a moderate association between CeAD and a history of migraine without aura (OR = 3.91, *moderate*, 95%CI 1.71 to 8.90) and it is also possible that a patient presenting with an atypical migraine may be presenting with a CeAD.

Family history of migraine

Family history should be reviewed when taking the clinical history as the genetic basis of migraine may lead to a predisposition to develop or experience migraines,⁶² even if they do not currently experience them. There is some evidence in the literature that patients with a family history of migraine are at greater risk of developing a CeAD than those without a family history (OR = 3.23, *moderate*, 95%CI 1.36 to 7.64).⁵⁸

History of cervical spine trauma

Cervical spine trauma has been associated with dissecting cervical arteries, particularly the vertebral artery.^{25,46,63} Notably, trivial trauma^{1,6,23,43,57,63,64} (such as sneezing, sporting activities) accounts for between 12-34% of CeAD cases,^{65,66} while more substantial trauma, such as a motor vehicle accident, or very heavy exercise/physical activity to which the patient is unaccustomed is also reported.^{6,63} The symptoms may include unilateral cervical spine pain without any of the 'classic' signs or symptoms of vertebrobasilar insufficiency.^{1,67} Timing of the onset of symptoms can range anywhere from immediately post-trauma upwards of 5 days post-trauma.⁶⁸ Thomas et al.⁵² and Thomas et al.^{43,69} reported a strong association for patients presenting with dissection and trauma in the 3 weeks preceding the dissection (OR = 23.53, *very strong*, 95%CI 6.31 to 87.70; and OR = 25.29, *very strong*, 95%CI 6.04 to 105.82) respectively, whilst Metso et al.¹⁷ and Bejot et al.³⁷ reported just under half of patients with a CeAD had some sort of trauma within the preceding month, with a male predominance.⁶¹ The association between even minor trauma and arterial dissection, should prompt the practitioner to consider the possibility of arterial dissection regardless of the magnitude of the traumatic event. In addition, the potential for onset of CeAD symptoms in the month following trauma should be considered.

Thomas et al.⁴³ demonstrated that 7 of the 36 CeAD events reported in their study had recently received manual therapy (OR = 12.67, *large*, 95%CI 1.43-112.0), however this could be either a temporal or causal

relationship. HVLA manipulation applied to the cervical spine has been proposed as a potential 'traumatic' event precipitating the onset of a CeAD either through arterial occlusion or damage to the artery.⁹ Work by numerous authors suggests that the forces applied to cervical vasculature, in particular the vertebral artery, during an HVLA technique are unlikely to be sufficient to damage it.⁷⁰⁻⁷² Symons and Herzog⁷ report vertebral artery strain during HVLA is less than that found in range of motion testing, and substantially less than the point of mechanical failure of the artery. Similarly, studies investigating occlusion have suggested the head position for a HVLA thrust has little impact on vertebral artery or internal carotid artery flow,⁷³⁻⁷⁶ and that the duration of arterial occlusion during the application of an HVLA technique (100-150 milliseconds) is insufficient to effect blood flow to the brain.^{77,78}

A history of cervical spine trauma should also raise the suspicion of potential cervical spine instability and it has been suggested that there may be an association between this and internal carotid artery insufficiency.¹ With this in mind, consideration of the potential for upper cervical spine instability is also indicated in cases of cervical spine trauma.

Onset of pain related to sudden cervical spine movement

Sudden cervical spine movements have been reported as a potential historical factor indicating a CeAD.⁷⁹ A case study by Gilberti et al.⁶⁴ reported the onset of an ICAD following "head-banging" at a rock concert, reinforcing the need to establish the mode of onset of the patient's current complaint as part of the clinical history. However, these authors did not provide any information as to whether there was a pre-existing vascular pathology or risk factors that may have contributed to the development of the ICAD.

Tinnitus – particularly 'pulsating tinnitus'

Tinnitus has been reported by patients experiencing cervical arterial dissection.^{17,37} It is reported in the literature that the patients describe 'pulsating' tinnitus sensation.^{30,35,80} Therefore, enquiry as to whether the patient is experiencing tinnitus and their description of the sensation associated with the tinnitus is pertinent.

History of hypertension and risk factors for cardiovascular disease

The presence of cardiovascular risk factors in the history should increase the practitioner's awareness of the increased risk of developing a CAD. These risk factors include, but are not limited to:

- Hypertension^{1,28,29,37,58,81,82}
- Hypercholesterolaemia⁸²
- Type 2 diabetes mellitus^{37,82}
- Smoking^{58,81}
- Body Mass Index >25 kg/m²³⁷

The widely cited 1999 review by Haldeman et al.²⁵ found there was no consistent pattern in relation to dissections and the presence of cardiovascular risk factors. This finding has also been supported in more recent reviews by Dittrich et al.⁷⁹ and Thomas et al.⁴³ In contrast, Metso et al.¹⁷ have highlighted age-related differences between some of these factors where hypertension (OR = 5.52, *moderate*, 95%CI 2.65 to 11.51), hypercholesterolaemia (OR = 6.63, *moderate*, 95%CI 2.93-13.24) and a BMI between 25-30 kg/m² (OR = 3.13, *moderate*, 95%CI 1.61-6.10) are more likely in those patients who have experienced a dissection over age 55 compared to those under 33 years. The contrasting results of these studies requires further investigation to establish whether the cardiovascular risk factors are consistently associated with CeADs, however, a precautionary approach would suggest that practitioners actively consider the presence of cardiovascular risk factors in risk assessment.

Recent upper and/or lower respiratory infection (within the previous week)

Infection of the upper and lower respiratory tract has been associated with CeAD,¹⁷ particularly infection within one week of the onset of a CeAD.^{6,37,79,80} Guillon et al.,⁵⁶ report a moderate association (OR = 3.1, 95%CI 1.1 to 9.2) for recent infection in those patients with dissection CeAD. Similar findings have been reported by Dittrich et al.⁷⁹ (OR = 3.5, *moderate*, 95%CI 1.2 to 16.7). and Thomas et al.,⁶⁹ (OR = 1.90, *trivial*, 95%CI 0.58 to 6.22). A number of authors have also suggested a possible seasonal effect, with higher incidence of cervical artery dissection in the autumn and winter months,^{30,83} Regardless of the strength of the association, or season, the patient should be asked about any recent upper or lower respiratory tract infection. Where the patient reports a recent respiratory tract infection, this information should be considered with the presence/absence of other CeAD history risk factors as part of the clinicians' clinical reasoning, as patients typically demonstrate 2 or more of the historical risk factors.⁹

Whilst a correlation between recent infection and CeAD has been demonstrated, the mechanism by which the infection contributes to the dissection is less clear.⁵⁶ Investigations have looked at factors such as coughing, sneezing or vomiting, as well as direct vessel wall inflammation or infiltration by a microbial agent. However, these have been discounted by some as being causative.^{6,56}

Upper and/or lower extremity neurological symptoms and ataxia

Thomas et al.⁴³ reported that 65% of people with ICAD presented with upper extremity weakness and 50% of dissection cases with lower extremity weakness. Ataxia is reported to be common in VAD,⁴³ and there is evidence from a case report⁸⁴ that a cervical radiculopathy may be present if the VAD is compressing a nerve root.

Consideration of 'red flags'

In addition to consideration of potential risk factors, it is critical that practitioners are able to actively recognise the potential signs and symptoms of VAD (Table 3). Of note however, is that these signs or symptoms may not be present in cases of ICAD.¹

ACCEPTED MANUSCRIPT

Table 3. Potential signs and symptoms of vertebral artery dysfunction (Adapted from Hutting et al.⁶⁷ and Thomas et al.⁴³)

Minor mechanical trauma to the neck
 Occipital headaches
 Cervical spine pain
 Dizziness
 Dysarthria
 Dysphasia
 Diplopia
 Nystagmus
 Drop attacks
 Numbness (facial, upper extremity, lower extremity)
 Unsteadiness or ataxia of gait

The factors in Tables 1 and 2 should be considered in addition to the identification of other 'red flags' for serious conditions could be identified in the clinical history (Table 4).

Table 4. Red flags in the clinical history

Onset of new complaint under age 20 years or over 50 years
 Persistent night pain
 Constant unremitting pain
 Pain that does not change with position/movement
 Loss of appetite
 Unexplained weight loss
 Past history of malignancy
 Shortness of breath
 Constant unexplained fatigue
 Chest pain
 Constant and severe extremity pain
 Swelling in the extremities and abdomen with history of injury
 Changes in colour of the hands/feet
 Frequent or severe abdominal pain
 Changes in bladder function
 Frequent nausea and/or vomiting
 Fever and/or night sweats
 Recent onset headache (with no previous history)
 Sudden onset severe neck pain (with no history of injury or trauma)
 Changes in vision, speech and/or hearing
 Changes in balance and coordination
 Sudden weakness
 Progressive neurological symptoms
 Neurological symptoms over more than one dermatome
 Bilateral neurological symptoms

ROLE OF THE CLINICAL EXAMINATION

Identification of any of the factors in Table 1 should be followed by the appropriate systems examination, in addition to the musculoskeletal examination. The presence of a single factor in the clinical history should raise the index of suspicion about increased risk or presence of a CeAD, however, the precise threshold for undertaking clinical examination or referral should be guided by the practitioner's own clinical reasoning in the context of each presentation. The recently published 'International Framework for Examination of the Cervical Region for Potential Cervical Arterial Dysfunction' provides some guidance in this regard.⁸⁵ A high number of risk factors, or risk factors severe in nature, warrant referral for further investigation and management. A moderate number, or moderate severity, requires monitoring and possible avoidance of treatment. A low number of risk factors or low severity requires caution with the selection of manual therapy techniques and constant monitoring for new or changing symptoms.

Taylor and Kerry⁸⁶ and the International Federation of Orthopaedic Manipulative Physical Therapists framework for cervical spine risk assessment⁸⁵ suggest that the standard examination for a patient with cervical spine pain regardless of origin includes assessment of blood pressure, cranial nerve assessment, and assessment of proprioception and coordination, particularly where the clinical history is suggestive of arterial dysfunction. Table 5 expands on this standard examination and highlights the examinations that should be performed with each of the factors that might be linked to a CeAD.

Table 5. Historical risk factors and their required examinations.

| | Cranial Nerve | Coordination | Upper cervical stability tests | Extremity neurological | Cardiovascular | Respiratory |
|---|---------------|--------------|--------------------------------|------------------------|----------------|-------------|
| Acute onset unilateral cervical spine pain | ✓ | ✓ | | | | |
| Acute onset occipital, frontal, supraorbital or temporal headache | ✓ | ✓ | | | | |
| Current history of migraine (particularly without an aura) | ✓ | ✓ | | | | |
| Past history of migraine (particularly without an aura) | ✓ | ✓ | | | | |
| Family history of migraine | ✓ | ✓ | | | | |
| History of cervical spine trauma | ✓ | ✓ | ✓ | ✓ | | |
| Onset of pain related to sudden cervical spine movement | ✓ | ✓ | | | | |
| Tinnitus (particularly 'pulsating tinnitus') | ✓ | ✓ | | | | |
| History of hypertension and risk factors for cardiovascular disease | ✓ | ✓ | | | ✓ | |
| Recent upper respiratory infection | ✓ | ✓ | | | | ✓ |
| Upper and/or lower neurological symptoms & ataxia | ✓ | ✓ | ✓ | ✓ | | |

Patients with positive findings on any of the clinical examinations should be referred for further investigation and management²⁸ and not receive manual therapy or exercise prescription until clinical status is established.

Patients who report risk factors in the clinical history but with negative findings from the clinical examinations may still be eligible to receive manual therapy interventions and exercise prescription applied to the cervical spine. , In this situation, the practitioner should maintain awareness of the presence of these risk factors and remain observant for changes in the clinical picture that indicate a need for further investigation.

Pre-manipulative screening tests (e.g., combinations of provocative rotation and extension/rotation of the neck, and more recently Doppler sonography of vascular patency during neck movement) have been advocated in an attempt to identify those patients at risk of complications related to manual therapy.⁸⁷ These pre-manipulative test procedures were developed in response to reports in the literature suggesting an association between cervical spine manipulation and adverse events such as stroke. Whilst pre-manipulative tests have ostensibly been used to 'screen' for the presence of vertebral artery dysfunction, there is a sound rationale to extend reasoning to consideration of the whole cervical arterial system, particularly as ICADs occur at a ratio of approximately 2:1 compared to VADs.¹⁶ There is an emerging consensus that cervical spine pre-treatment screening for arterial dysfunction is not valid and therefore lacks clinical utility. A summary of the statistics for pre-manipulative screening procedures was presented by Kerry and Taylor.⁸ These authors reported a positive likelihood ratio of between 0.22% and 83.25%, with the screening procedure having limited sensitivity (S_n range varies from 0 to 57%) due to a large number of false-negatives. The specificity is relatively high (S_p range varies from 67 to 100%).⁶⁷ Hutting et al.⁶⁷ succinctly summarise the literature as "...the usefulness of the test is almost zero". Evidence for the utility of Doppler ultrasound as a possible substitute for pre-manipulative screening is lacking. A recent systematic review highlights the limited utility of Doppler ultrasound as a screening procedure pointing out that many investigations into this procedure have utilised participants who are otherwise healthy or not suitable for cervical spine manipulation,⁸⁸ thereby limiting the generalisability of these studies.

In recent years, and in light of the literature highlighting the poor clinical utility of this approach, there continues to be a growing emphasis on identification of risk factors in the clinical history combined with an understanding of the cervical arterial system and its potential involvement in adverse events potentially related to cervical spine manipulation.

In summary, the preceding section is intended to provide practitioners with information that may assist clinical reasoning, highlight alternatives to pre-manipulative screening tests, and provide up-to-date data on risk factors for CeAD. Further, this section presents the potential historical risk factors and suggests examinations that should be undertaken if any of these factors are identified in the clinical history, and an approach to clinical reasoning.⁶⁷ It is anticipated that this information may assist practitioners to identify those patients who are presenting with a CeAD in progress, and potentially assist in the identification of patients at risk of complications following cervical and upper thoracic spine manual therapy.²⁸ It is important for practitioners to be aware that although much of the discussion around CAD associated with manual therapy centres around cervical spine manipulation, consideration should also be given to cervicothoracic spine manipulation due to the cervical spine positions that some of the manipulations can involve. Further, in the context of emphasising the role of movement rather than manipulation, this information should aid clinical reasoning when applying all manual techniques and exercise rehabilitation.²⁸

CONCLUSION

It is now widely recognised that a dissecting cervical artery (internal carotid and/or vertebral artery) can present as acute onset cervical spine pain and/or headache. In a review of 64 cases of complications following cervical spine manipulation, Haldeman et al.⁸⁹ reported being unable to identify specific factors or characteristics from the history or examination that would indicate a greater risk of an adverse event following cervical spine manipulation.

It is well understood that serious adverse events from manipulation may not be predictable⁸⁹ and, in a small number of cases, may be unpreventable.²⁴ However, practitioners should employ clinical reasoning with a focus on identifying patients who might be at increased risk of an adverse event following manual or exercise therapy applied to the cervical and cervicothoracic spine, or who might be presenting to a clinician with symptoms of a CeAD in progress. There is a need to identify these patient groups before applying any manual therapy interventions or prescription exercise. It is incumbent on the practitioner to be aware of factors that may, as part of a systematic differential diagnosis process, indicate a need for further assessment or referral due to the potential of CeAD. Appropriate clinical examinations should be performed to clarify the clinical picture, and if indicated, organise referral for further examination and appropriate management. The current paper is intended to assist practitioners in identifying patients who may present with a myriad of symptoms associated with potential cervical artery dysfunction. Increased clinician awareness and prudent examination may help to reduce the risk of vascular and neurological complications associated with manual therapy applied to the cervical and cervicothoracic spine.

1. Kerry R, Taylor AJ, Mitchell J, McCarthy C. Cervical arterial dysfunction and manual therapy: a critical literature review to inform professional practice. *Manual Therapy* 2008;13:278-88.
2. Carpieaux M, Michotte A, Van Varenbergh D, Marichal MP. Spontaneous bilateral carotid artery dissection following cervical manipulation. *Legal Medicine* 2012;14:249-51.
3. Haynes M, Vincent K, Fischhoff C, Bremner A, Lanlo O, Hankey G. Assessing the risk of stroke from neck manipulation: a systematic review. *International Journal of Clinical Practice* 2012;66:940-7.
4. Tuchin P. Chiropractic and stroke: association or causation? *International Journal of Clinical Practice* 2013;67:825-33.
5. Kerry R, Rushton A, Flynn T, Hing W, Carlesso L, Rivett D. Response to – Risk reduction of serious complications from manual therapy: Are we reducing the risk? *Manual Therapy*;19:e3-e4.
6. Grau AJ, Brandt T, Buggle F, et al. Association of cervical artery dissection with recent infection. *Archives of Neurology* 1999;56:851-6.
7. Symons B, Herzog W. Cervical artery dissection: a biomechanical perspective. *The Journal of the Canadian Chiropractic Association* 2013;57:276.
8. Kerry R, Taylor A. Cervical spine pre-treatment screening for arterial dysfunction: out with the old, in with the new. *In Touch* 2014;147:10-4.
9. Biller J, Sacco RL, Albuquerque FC, et al. Cervical Arterial Dissections and Association With Cervical Manipulative Therapy A Statement for Healthcare Professionals From the American Heart Association/American Stroke Association. *Stroke* 2014;45:3155-74.
10. Renard D, Azakri S, Arquizan C, Swinnen B, Labauge P, Thijs V. Styloid and Hyoid Bone Proximity Is a Risk Factor for Cervical Carotid Artery Dissection. *Stroke* 2013;44:2475-9.

11. Raser JM, Mullen MT, Kasner S, Cucchiara B, Messe SR. Cervical carotid artery dissection is associated with styloid process length. *Neurology* 2011;77:2061-6.
12. Muthusami P, Kesavadas C, Sylaja P, Thomas B, Harsha K, Kapilamoorthy T. Implicating the long styloid process in cervical carotid artery dissection. *Neuroradiology* 2013;55:861-7.
13. Razak A, Short JL, Hussain SI. Carotid Artery Dissection due to Elongated Styloid Process: A Self - Stabbing Phenomenon. *Journal of Neuroimaging* 2014;24:298-301.
14. Yukawa S, Yamamoto S, Hara H. Carotid Artery Dissection Associated with an Elongated Hyoid Bone. *Journal of Stroke and Cerebrovascular Diseases* 2014;23:e411-e2.
15. Schievink W, Mokri B, Whisnant J. Internal carotid artery dissection in a community. Rochester, Minnesota, 1987-1992. *Stroke* 1993;24:1678-80.
16. Lee VH, Brown Jr. RD, Mandrekar JN, Mokri B. Incidence and outcome of cervical artery dissection. *Neurology* 2006;67:1809-12.
17. Metso TM, Debette S, Grond-Ginsbach C, et al. Age-dependent differences in cervical artery dissection. *Journal of Neurology* 2012:1-9.
18. Haneline M, Lewkovich G. An analysis of the aetiology of cervical artery dissections: 1994 to 2003. *Journal of Manipulative and Physiological Therapeutics* 2005;28:617-22.
19. Boyle E, Cote P, Grier A, Cassidy J. Examining vertebrobasilar artery stroke in two canadian provinces. *Spine* 2008;33:S170-S5.
20. Cassidy J, Boyle E, Cote P, et al. Risk of vertebrobasilar stroke and chiropractic care. *Spine* 2008;33:S176-S83.
21. Rothwell DM, Bondy SJ, Williams JI. Chiropractic manipulation and stroke a population-based case-control study. *Stroke* 2001;32:1054-60.

22. Smith WS, Johnston SC, Skalabrin EJ. Spinal Manipulative Therapy is an Independent Risk Factor for Vertebral Artery Dissection. *Neurology* 2003;60:1424-8.
23. Engelter ST, Grond-Ginsbach C, Metso TM, et al. Cervical artery dissection Trauma and other potential mechanical trigger events. *Neurology* 2013;80:1950-7.
24. Puentedura EJ, March J, Anders J, et al. Safety of cervical spine manipulation: are adverse events preventable and are manipulations being performed appropriately? A review of 134 case reports. *Journal of Manual & Manipulative Therapy* 2012;20:66-74.
25. Haldeman S, Kohlbeck F, McGregor M. Risk factors and precipitating movements causing vertebrobasilar artery dissection after cervical trauma and spinal manipulation. *Spine* 1999;24:785-94.
26. Murphy DR. Current understanding of the relationship between cervical manipulation and stroke: what does it mean for the chiropractic profession. *Chiropractic & Osteopathy* 2010;18:22.
27. Grond-Ginsbach C, Metso TM, Metso AJ, et al. Cervical artery dissection goes frequently undiagnosed. *Medical Hypotheses* 2013;80:787-90.
28. Rushton A, Rivett D, Carlesso L, Flynn T, Hing W, Kerry R. International framework for examination of the cervical region for potential of cervical arterial dysfunction prior to orthopaedic manual therapy intervention. *Manual Therapy* 2014;19:222-8.
29. Kerry R, Taylor AJ, Mitchell J, McCarthy C. Cervical arterial dysfunction and manual therapy: a critical literature review to inform professional practice. *Manual Therapy* 2008;13:278-88.
30. Schievink W. Spontaneous dissection of the carotid and vertebral arteries. *New Eng J Med* 2001;344:898-906.
31. Taylor AJ, Kerry R. Neck pain and headache as a result of internal carotid artery dissection: implications for manual therapists. *Manual Therapy* 2005;10:73.

32. Bin Saeed A, Shuaib A, Al-Sulaiti G, Emery D. Vertebral artery dissection: warning symptoms, clinical features and prognosis in 26 patients. *Can J Neurol Sci* 2000;27:292-6.
33. Schelfaut D, Dhondt E, De Raedt S, Nieboer K, Hubloue I. Carotid artery dissection: three cases and a review of the literature. *European Journal of Emergency Medicine* 2011.
34. Kapoor S. Headache attributed to cranial or cervical vascular disorders. *Current Pain and Headache Reports* 2013;17:1-8.
35. Patel RR, Adam R, Maldjian C, Lincoln CM, Yuen A, Arneja A. Cervical Carotid Artery Dissection: Current Review of Diagnosis and Treatment. *Cardiology in Review* 2012;20:145.
36. Hennings J, Hoehn D, Schumann-Spaeth E, Weber F. Painless Hypoglossal Palsy as an Isolated Symptom of Spontaneous Carotid Dissection. *Journal of Stroke and Cerebrovascular Diseases* 2014.
37. Béjot Y, Aboa-Eboulé C, Debette S, et al. Characteristics and Outcomes of Patients With Multiple Cervical Artery Dissection. *Stroke* 2014;45:37-41.
38. Mokri B, Silbert PL, Schievink WI, Piepgras DG. Cranial nerve palsy in spontaneous dissection of the extracranial internal carotid artery. *Neurology* 1996;46:356-9.
39. Ferlazzo E, Gasparini S, Arcudi L, Versace P, Aguglia U. Isolated hypoglossal nerve palsy due to spontaneous carotid artery dissection: a neuroimaging study. *Neurological Sciences* 2013;34:2043-4.
40. Marin LF, Bichuetti DB, Felício AC, et al. Hypoglossal nerve palsy as the sole manifestation of spontaneous internal carotid artery dissection. *Arquivos de neuro-psiquiatria* 2009;67:107-8.
41. Lyrer PA, Brandt T, Metso TM, et al. Clinical import of Horner syndrome in internal carotid and vertebral artery dissection. *Neurology* 2014;82:1653-9.

42. Haldeman S, Carey P, Townsend M, Papadopoulos C. Clinical perceptions of the risk of vertebral artery dissection after cervical spine manipulation: the effects of referral basis. *The Spine Journal* 2002;2:334-42.
43. Thomas L, Rivett D, Attia J, Parsons M, Levi C. Risk factors and clinical features of craniocervical arterial dissection. *Manual Therapy* 2011;16:351-6.
44. Kelly JC, Safain MG, Roguski M, Edlow AG, Malek AM. Postpartum Internal Carotid and Vertebral Arterial Dissections. *Obstetrics & Gynecology* 2014;123:848-56.
45. Reinhard M, Munz M, Kannen AL, Griesser - Leute HJ, Dittrich R, Engelter S. Risk of recurrent cervical artery dissection during pregnancy, childbirth and puerperium. *European Journal of Neurology* 2014.
46. Norris JW, Beletsky V, Nadareishvili ZG. Sudden neck movement and cervical artery dissection. *Canadian Medical Association Journal* 2000;163:38-40.
47. Arnold M, Bousser MG, Fahrni G, et al. Vertebral artery dissection: presenting findings and predictors of outcome. *Stroke* 2006;37:2499-503.
48. Arnold M, Cumurciuc R, Stapf C, Favrole P, Berthet K, Bousser M-G. Pain as the only symptom of cervical artery dissection. *Journal of Neurology, Neurosurgery & Psychiatry* 2006;77:1021-4.
49. Burke SR, Myers R, Zhang AL. A profile of osteopathic practice in Australia 2010–2011: a cross sectional survey. *BMC Musculoskeletal Disorders* 2013;14:1-10.
50. Orrock P. Profile of members of the Australian Osteopathic Association: Part 2 - The patients. *Int J Osteopath Med* 2009;12:128-39.
51. Jatuzis D, Valaikiene J. Migraine-like presentation of vertebral artery dissection after cervical manipulative therapy. *Perspectives in Medicine* 2012;1:452-4.

52. Maruyama H, Nagoya H, Kato Y, et al. Spontaneous cervicocephalic arterial dissection with headache and neck pain as the only symptom. *The Journal of Headache and Pain* 2012;1-7.
53. Silbert PL, Mokri B, Schievink WI. Headache and neck pain in spontaneous internal carotid and vertebral artery dissections. *Neurology* 1995;45:1517-22.
54. Dallol B, Alsafadi H. Carotid dissection presenting as Horner's syndrome. *New Zealand Medical Journal* 2010;123:88.
55. Tzourio C, Benslamia L, Guillon B. Migraine and the Risk of Cervical Artery Dissection: A Case Controlled Study. *Neurology* 2002;59:435-7.
56. Guillon B, Berthet K, Benslamia L, Bertrand M, Bousser MG, Tzourio C. Infection and the risk of spontaneous cervical artery dissection: a case-control study. *Stroke* 2003;34:e79-e81.
57. Rubinstein SM, Peerdeman SM, MW vT, Riphagen I, Haldeman S. A systematic review of the risk factors for cervical artery dissection. *Stroke* 2005;36:1575-80.
58. Pezzini A, Granella F, Grassi M, et al. History of migraine and the risk of spontaneous cervical artery dissection. *Cephalalgia* 2005;25:575-80.
59. Rist P, Diener H, Kurth T, Schurks M. Migraine, Migraine Aura and Cervical Artery Dissection: a systematic review and meta-analysis. *Cephalalgia* 2011;31:886-96.
60. Metso T, Tatlisumak T, Debette S, et al. Migraine in cervical artery dissection and ischemic stroke patients. *Neurology* 2012;78:1221-8.
61. Metso A, Metso T, Debette S, et al. Gender and cervical artery dissection. *European Journal of Neurology* 2012.
62. Gasparini CF, Sutherland HG, Griffiths LR. Studies on the pathophysiology and genetic basis of migraine. *Current genomics* 2013;14:300.

63. Thomas LC, Rivett D, Attia JR, Levi C. Risk Factors and Clinical Presentation of Cervical Arterial Dissection: Preliminary Results of a Prospective Case Control Study. *J Orthop Sports Phys Ther* 2015;1-27.
64. Gilberti N, Gamba M, Gasparotti R, Padovani A, Magoni M. "Head banging" causing subdural hemorrhage and internal carotid artery dissection. *Neurological Sciences* 2014;1-2.
65. Leys D, Moulin T, Stojkovic T, Begey S, Chavot D. Follow-up of patients with history of cervical artery dissection. *Cerebrovascular Diseases* 1995;5:43-9.
66. Touzé E, Randoux B, Méary E, Arquizan C, Meder J-F, Mas J-L. Aneurysmal forms of cervical artery dissection associated factors and outcome. *Stroke* 2001;32:418-23.
67. Hutting N, Verhagen AP, Vijverman V, Keesenberg MD, Dixon G, Scholten-Peeters GG. Diagnostic accuracy of premanipulative vertebrobasilar insufficiency tests: A systematic review. *Manual Therapy* 2012;18:177-82.
68. Dziewas R, Konrad C, Drager B, et al. Cervical artery dissection - clinical features, risk factors, therapy and outcome in 126 patients. *Journal of Neurology* 2003;250:1179-84.
69. Thomas LC, Rivett DA, Parsons M, Levi C. Risk factors, radiological features, and infarct topography of craniocervical arterial dissection. *International Journal of Stroke* 2012;in Press:10.1111/j.747-4949.2012.00912.x.
70. Herzog W, Leonard T, Symons B, Tang C, Wuest S. Vertebral artery strains during high-speed, low amplitude cervical spinal manipulation. *Journal of Electromyography and Kinesiology* 2012.
71. Symons BP, Leonard T, Herzog W. Internal forces sustained by the vertebral artery during spinal manipulative therapy. *J Manipulative Physiol Ther* 2002;25:504-10.
72. Wuest S, Symons B, Leonard T, Herzog W. Preliminary Report: Biomechanics of Vertebral Artery Segments C1-C6 During Cervical Spinal Manipulation. *Journal of Manipulative and Physiological Therapeutics* 2010;33:273-8.

73. Bowler N, Shamley D, Davies R. The effect of a simulated manipulation position on internal carotid and vertebral artery blood flow in healthy individuals. *Manual Therapy* 2011;16:87-93.
74. Thomas LC, Rivett DA, Bateman G, Stanwell P, Levi CR. Effect of Selected Manual Therapy Interventions for Mechanical Neck Pain on Vertebral and Internal Carotid Arterial Blood Flow and Cerebral Inflow. *Physical Therapy* 2013;93:1563-74.
75. Lin W, Ma X, Deng D, Li Y. Hemodynamics in the Circle of Willis with Internal Carotid Artery Stenosis under Cervical Rotatory Manipulation: A Finite Element Analysis. *Medical Science Monitor* 2015;21:1820.
76. Erhardt JW, Windsor BA, Kerry R, et al. The immediate effect of atlanto-axial high velocity thrust techniques on blood flow in the vertebral artery: A randomized controlled trial. *Manual therapy* 2015.
77. Herzog W, Symons B. The biomechanics of spinal manipulation. *Critical Reviews™ in Physical and Rehabilitation Medicine* 2001;13:191-216.
78. Triano J. The mechanics of spinal manipulation. In: Herzog W, ed. *Clinical biomechanics of spinal manipulation*. Philadelphia, USA: Churchill Livingstone; 2000:92-190.
79. Dittrich R, Rohsbach D, Heidbreder A, et al. Mild mechanical traumas are possible risk factors for cervical artery dissection. *Cerebrovascular Disorders* 2007;23:275-81.
80. Grau AJ, Brandt T, Forsting M, Winter R, Hacke W. Infection-associated cervical artery dissection. *Stroke* 1997;28:453-5.
81. Debette S, Metso T, Pezzini A, et al. Cervical Artery Dissection and Ischemic Stroke Patients (CADISP) Group. Association of vascular risk factors with cervical artery dissection and ischemic stroke in young adults. *Circulation* 2011;123:1537-44.
82. Pezzini A, Caso V, Del Zotto E, et al. Arterial hypertension as risk factor for spontaneous cervical artery dissection. A case-control study. *Journal of Neurology, Neurosurgery and Psychiatry* 2006;77:95-7.

83. Kloss M, Metso A, Pezzini A, et al. Towards understanding seasonal variability in cervical artery dissection (CeAD). *Journal of Neurology* 2012;1-6.
84. Silbert BI, Khangure M, Silbert PL. Vertebral Artery Dissection as a Cause of Cervical Radiculopathy. *Asian Spine journal* 2013;7:335-8.
85. International Framework for Examination of the Cervical Region for Potential of Cervical Arterial Dysfunction Prior to Orthopaedic Manual Therapy Intervention. 2012. at www.ifompt.com.)
86. Taylor AJ, Kerry R. A 'system based' approach to risk assessment of the cervical spine prior to manual therapy. *International Journal of Osteopathic Medicine* 2010;13:85-93.
87. Licht PB, Christensen HW, Hoilund-Carlsen PF. Is there a role for premanipulative testing before cervical manipulation? *Journal of Manipulative and Physiological Therapeutics* 2000;23:175-9.
88. Malo-Urriés M, Tricás-Moreno JM, Lucha-López O, Estébanez-de-Miguel E, Hidalgo-García C, Pérez-Guillén S. Vertebral and internal carotid artery flow during vascular premanipulative testing using duplex Doppler ultrasound measurements: A systematic review. *International Journal of Osteopathic Medicine* 2012.
89. Haldeman S, Kohlbeck FJ, McGregor M. Unpredictability of cerebrovascular ischaemia associated with cervical spine manipulation therapy: a review of sixty-four cases after cervical spine manipulation. *Spine* 2002;27:49-55.

AUTHOR CONTRIBUTION STATEMENT

All authors contributed to the literature review, development of the manuscript and approved the final version.

ACCEPTED MANUSCRIPT

STATEMENT OF COMPETING INTERESTS

Brett Vaughan is an Editor of the International Journal of Osteopathic Medicine but was not involved in review or editorial decisions regarding this manuscript.

Robert Moran is an Editor of the International Journal of Osteopathic Medicine but was not involved in review or editorial decisions regarding this manuscript.

Steven Vogel is the Editor-in-Chief of the International Journal of Osteopathic Medicine but was not involved in review or editorial decisions regarding this manuscript.