

## Agriculture



Utah State University  
COOPERATIVE EXTENSION



[extension.usu.edu](http://extension.usu.edu)

April 2012

AG/Poultry/2012-03pr

# Postmortem Examination of Turkeys

*David D. Frame*, DVM, DACPV

Utah State University Extension Poultry Specialist

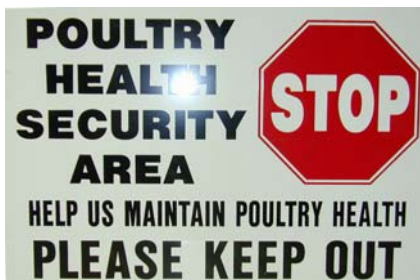1. Examine the outside of birds for parasites, scratches, animal bites, and other signs of injury.
2. Using heavy scissors or tin snips, cut off upper beak and look at sinuses. Gently squeeze sides of beak and check for excess mucus.
3. Using the snips, cut along side of mouth and open the throat to level of where neck enters the body cavity. Observe esophagus for lumps, bumps, atypically colored or textured areas, ulcers, or severe reddening.
4. Cut open the windpipe (trachea) lengthwise and look for excess bloody content, yellowish cheesy material, or abundant mucus.
5. Cut open the crop and look at contents. Is it the normal feed? Is it sour-smelling or dry and impacted? Remove contents and look at the crop lining. Is it thickened? Are there reddened or raised areas present?
6. Peel back the skin and feathers from the breast and check for areas of injury, scant breast musculature (i.e., starvation), uniformly dry and dark muscles (i.e., dehydration), or presence of tumors.
7. Using a knife, cut down the inner side of each leg until the hip joint is reached. Pull the legs away from body and twist sideways to expose the hip joint. Break one of the leg bones to test the bone strength. Is it soft and rubbery? Does it feel brittle and break too easily?
8. Using the snips, cut away skin and muscle along the rear underside of breast bone to expose the internal organs. Continue cutting along each side of the body cavity until the ribs have been cut through between breast and back. Gently raise the breast bone away from the internal organs. Remove the breast by snipping through the bones near the shoulder area, thus exposing the internal organs.
9. Look for cloudy opaque air sacs or cheesy material in the body cavity.
10. Examine heart, liver, lungs, and spleen. Is the heart or liver covered with white or yellowish granular or cheesy material? Is the spleen larger than normal; dark blackish and easily ruptured? Are the lungs bright orange-red and spongy (normal); or are they dark red-brown, hard, or compacted (abnormal)?
11. Look at the outer surface of the intestines. Are nodules or areas of hemorrhage present? Slit open the intestines lengthwise and look for worms, bloody content, excess mucus, thickened lining, or other abnormalities.

12. Open up the proventriculus (stomach) and look for pinpoint red lesions, thickening, or enlargement.

13. Slit open the gizzard. Examine contents. Peel away the inner lining (cuticle) and look for reddened or hemorrhagic areas (dark red patches) underneath the cuticle.

14. Examine other areas of the body cavity for abnormalities.

15. Make notes of any abnormalities encountered. If you think your turkeys have a problem, contact your company representative, local veterinarian, or Extension poultry specialist.



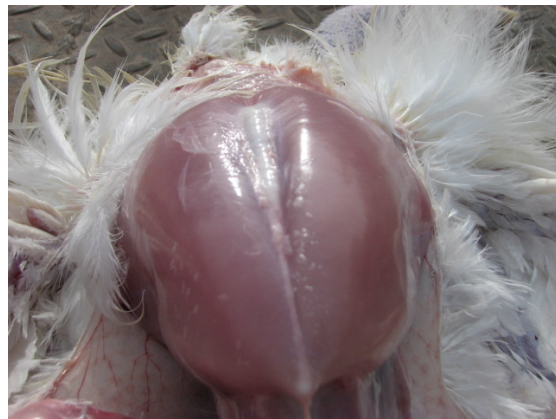**When opening dead or DISEASED TURKEYS, always follow proper biosecurity measures!**

1. Remove and open dead birds away from live bird areas.
  2. Use protective gloves (and face mask if warranted).
  3. Thoroughly wet down feathers with disinfectant solution or soapy water before beginning to open birds.
  4. After examining carcasses, place in large heavy plastic bags or closeable waterproof container for disposal.
  5. Collect and dispose of all stray feathers. Wash away blood and other body fluids with disinfectant solution.
  6. Thoroughly clean off all debris from knives, scissors and other equipment. Rinse or wipe off with disinfectant solution.
  7. Thoroughly wash off arms and hands with soapy water. Rinse. Apply hand sanitizer if available.
-

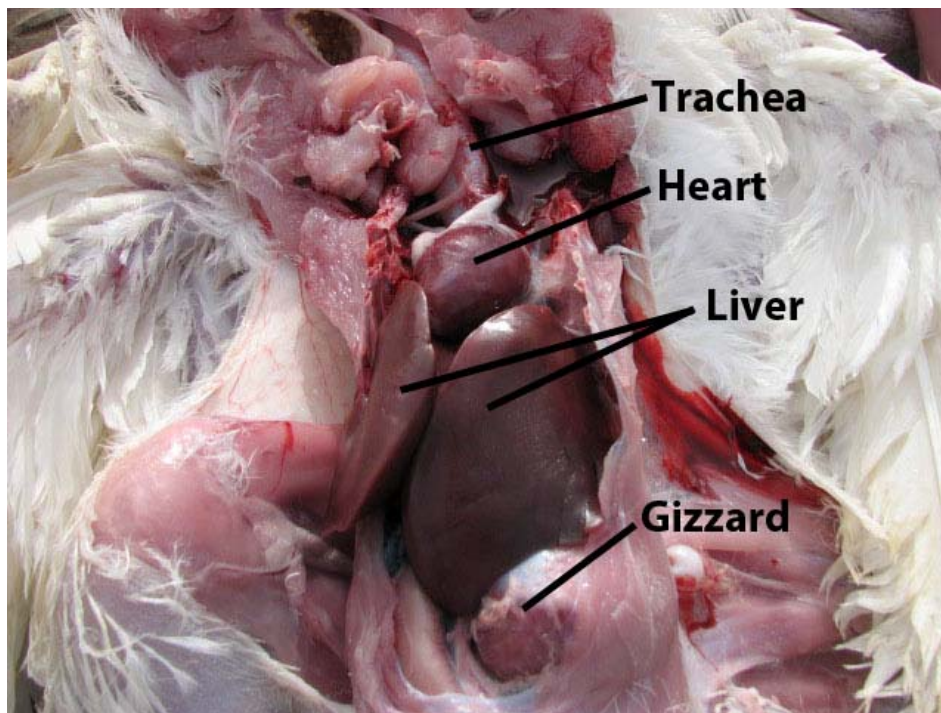
**Figure 1.** External examination of mortality. Examine for parasites, scratches, animal bites, and other signs of injury. Examine eyes, beak, nostrils for unusual growths (i.e., nodules or crusty material) or excess mucus. The application of soapy water helps mat the feathers, keeping them from interfering with the subsequent postmortem examination. Wetting the feathers in this manner also reduces the likelihood of aerosolizing disease-causing agents.



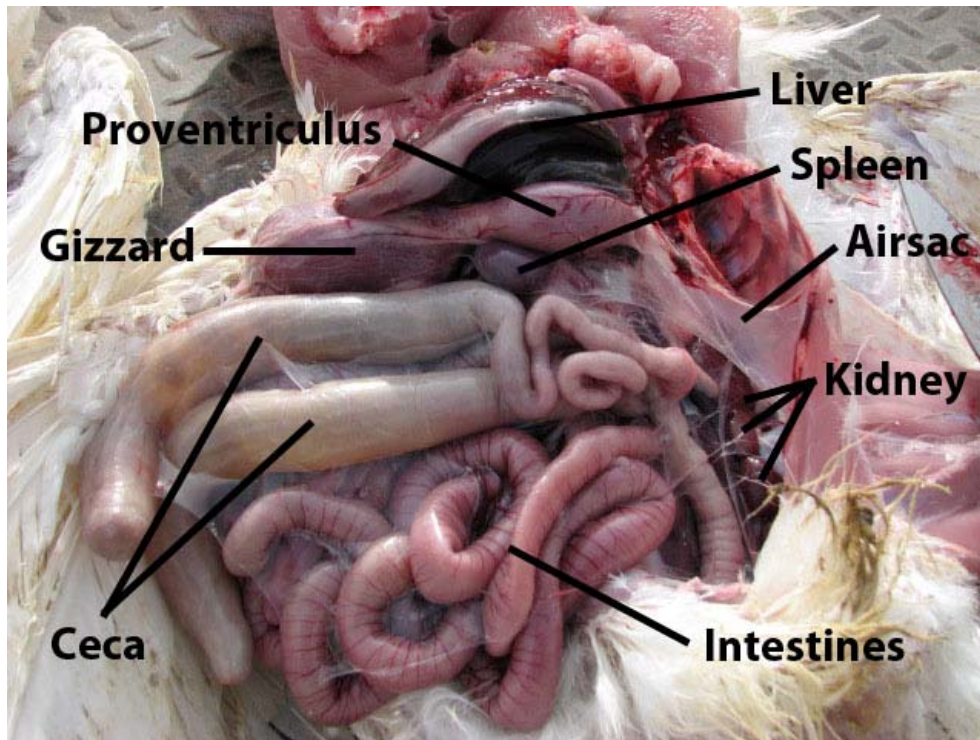
**Figures 2 and 3.** Breast exposed after pulling away skin and feathers. Cuts have been made on the inside of the thighs and the hip joints dislocated by slightly twisting the leg in order to expose the femoral head and allow legs to lie flat.



**Figure 4.** Internal organs in situ. (After removal of the breast.)



**Figure 5.** Internal organs in situ. (After lifting away the gizzard and liver.)



## Reference

Avian Disease Manual, Second Edition. C. E. Whiteman and A. A. Bickford. American Association of Avian Pathologists. 1983

Utah State University is committed to providing an environment free from harassment and other forms of illegal discrimination based on race, color, religion, sex, national origin, age (40 and older), disability, and veteran's status. USU's policy also prohibits discrimination on the basis of sexual orientation in employment and academic related practices and decisions.

Utah State University employees and students cannot, because of race, color, religion, sex, national origin, age, disability, or veteran's status, refuse to hire; discharge; promote; demote; terminate; discriminate in compensation; or discriminate regarding terms, privileges, or conditions of employment, against any person otherwise qualified. Employees and students also cannot discriminate in the classroom, residence halls, or in on/off campus, USU-sponsored events and activities.

This publication is issued in furtherance of Cooperative Extension work, acts of May 8 and June 30, 1914, in cooperation with the U.S. Department of Agriculture, Noelle E. Cockett, Vice President for Extension and Agriculture, Utah State University.