

The normal ischiofemoral distance and its variations

I. Hujazi¹, T. Jones¹, S. Johal¹, P. Bearcroft¹, G. Muniz-Terra¹ and
V. Khanduja^{1,*}

1.Trauma and Orthopaedic Department, Addenbrooke's Hospital, Cambridge University Hospitals NHS Foundation Trust, Box 37, Hill Road,
Cambridge CB2 0QQ, UK

*Correspondence to: V. KhandujaE-mail: vk279@cam.ac.uk or vikaskhanduja@aol.com

Submitted 31 May 2015; Revised 25 November 2015; revised version accepted 11 January 2016

ABSTRACT

The aim of this study is to measure the ischiofemoral distance (IFD) in the normal hip with healthy surrounding soft tissues and describe its variations caused by gender, age and proximal femoral anatomy so that this could serve as a reference for future studies on this subject. This is a retrospective study in which we reviewed the CT scans of 149 patients (298 hips) who had a CT of their pelvis for non-orthopaedic (abdomino-pelvic) pathology. The images were reviewed by two independent observers and the IFD (the smallest distance between the lateral cortex of the ischial tuberosity and the posteromedial cortex of the lesser trochanter), offset (the perpendicular distance from the centre of the femoral head to a line running down the middle of the shaft of the femur) and the neck-shaft angle (the angle between the lines in the middle of the neck to the line forming the axis of the femoral shaft) were measured. The CT scans belonged to 71 males and 78 females (M: 48%, F: 52%), with an average age of 51 ± 19 years (range 18–92). The mean IFD was 18.6 ± 8 mm in the females and 23 ± 7 mm in the males and this difference was statistically significant ($P < 0.001$). The IFD increased by 1.06 mm for each 1 mm of offset and dropped by 0.09 mm with each year of age. However, the neck-shaft angle did not show any significant correlation with the IFD.

INTRODUCTION

Impingement around the hip joint can predominantly occur in three areas. While femoroacetabular impingement is more common, well understood and believed to be responsible for majority of the cases of hip pain [1, 2], Ischiofemoral impingement (IFI) and subspinosus impingement are less common and still not well understood.

In IFI, there is a reduction of the ischiofemoral distance (IFD), i.e. the smallest distance between the lateral cortex of the ischial tuberosity and the posteromedial cortex of the lesser trochanter. This reduction then leads to inflammation and damage of the anatomical structures within this space, which is the quadratus femoris muscle [3, 4].

A reduced IFD may be positional, secondary to a congenital abnormality or acquired [5].

Positional factors that may affect the ischiofemoral space include lower extremity extension/flexion, abduction/adduction and internal/external rotation [4, 6].

A congenital posteromedial position of the proximal femur, a larger cross section of the femur at the level of the lesser trochanter, prominence of the lesser trochanter or the configuration of the female pelvic bony anatomy, which shows greater width and lesser anteroposterior dimensions when compared with males can lead to reduction of the IFD [4, 6].

Acquired ischiofemoral narrowing may be seen as a result of valgus osteotomy of the hip, fractures involving the lesser trochanter, osteoarthritis associated with superomedial migration [3], enthesopathy of the proximal hamstring insertion [7, 8] or an expansile bony lesion in this region [9].

IFI was first reported by Johnson [3] as an iatrogenic complication following total hip arthroplasty. However, more recently, IFI has also been reported in patients with no history of previous hip trauma or surgery [9, 10].

Johnson had estimated the size of the ischiofemoral distance to be 2 cm in his study with the hip in extension,

adduction and external rotation. However, there was no data or evidence to support the accuracy of this measurement. Furthermore, it is quite surprising that most subsequent studies and case reports discussing this subject used Johnson's measurement of 2 cm as a reference for IFD [4, 5, 11]. To the best of our knowledge, a quantitative measurement of the IFD with a large number of patients has not been accurately reported in the English literature. The aim of this study, therefore, was to measure the IFD in the normal hip with healthy surrounding soft tissues and describe its variations caused by gender, age and proximal femoral anatomy so that this could serve as a reference for future studies on this subject.

PATIENTS AND METHODS

Pilot study

A pilot study was carried out prior to the commencement of the main study to assess the correlation between position of the limb and the IFD.

The pilot study was conducted on a healthy 40-year-old female volunteer subject who consented to be a part of the study (height 148 cm). She did not have any history of problems related to the hip and on examination she had a full range of movement of the hip joint with minimal increase in external rotation of the right foot (and therefore the left IFD was measured for the pilot). Impingement test and FABER test were negative. There was no other abnormality detected.

For the purpose of this study, we defined the following:

IFD: the smallest distance between the lateral cortex of the ischial tuberosity and medial cortex of the lesser trochanter using axial MRI views of the region. The measurements were performed on three contiguous axial FSE proton density weighted images through the lesser trochanter. From each group of measurements, the smallest distance was considered to be the IFD.

Heal-to-heal distance: the smallest distance between the inner surfaces of both heels measured in centimetres.

Foot rotation was measured with the subject in supine position; it was defined as the measured angle between an imaginary line crossing the mid ankle in the anterior/posterior axis and vertical line perpendicular to the ground.

The hip and knee were extended in the standard supine position used for the MRI scan. The IFD distance was measured with the foot held in different positions including: the resting position (heal-to-heal distance of 0.5 cm, 14° of external foot rotation in the right and 8° of external foot rotation in the left), feet apposed (heal-to-heal distance of 0 cm, 5° external foot rotation), forced external rotation (50° degrees bilaterally, heal-to-heal distance of

Table I. The measured IFD with the associated foot positions

<i>Position of the feet</i>	<i>IFD</i>
Resting position of the feet	30.9
Feet held next to each other	29.7
Feet in 50° external rotation	19.4
Feet in 40° internal rotation	42.3
45° Hip flexion	46

0 cm) and forced internal rotation (40° bilaterally, heal-to-heal distance of 25 cm) and with the hip in 45° of flexion.

The measured IFD with the associated foot positions is shown in Table I.

The pilot study showed that holding the feet together did not significantly influence the IFD. It also showed that there was little variation between the IFDs in mild internal rotation (feet apposed) compared with the resting position.

However, the IFD was significantly influenced when forced external or internal rotation was applied to the feet. In addition, it is showed that the IFD was smallest when the hip was in extension and forced external rotation. The pilot study also highlighted the difficulty in visualizing the outer cortex of both the ischium and lesser trochanter using MRI.

Following this pilot study, it was decided to use computed tomography (CT) of the hip for accurate measurement of the IFD with the feet in the neutral resting position.

Main study

Between January and April, all the patients who underwent a CT scan of their pelvis at our institution for any pathology unrelated to the hip, proximal femur or associated soft tissue (gastrointestinal, gynaecological and urological pathology) were included in our study. Suitable patients were divided by gender and decade of birth. Subsequently only the first 10 patients by date of the scan in each group were included for the final assessment.

Exclusion criteria included history of recent hip trauma (within 30 days), infection or inflammatory arthritis of the hip, osteoarthritis of the hip, previous hip surgery and history of current hip pain. The above information was retrospectively collected from the medical records of all the patients. All the scans were performed in a standardized fashion with the pelvis square, hips and knees in extension

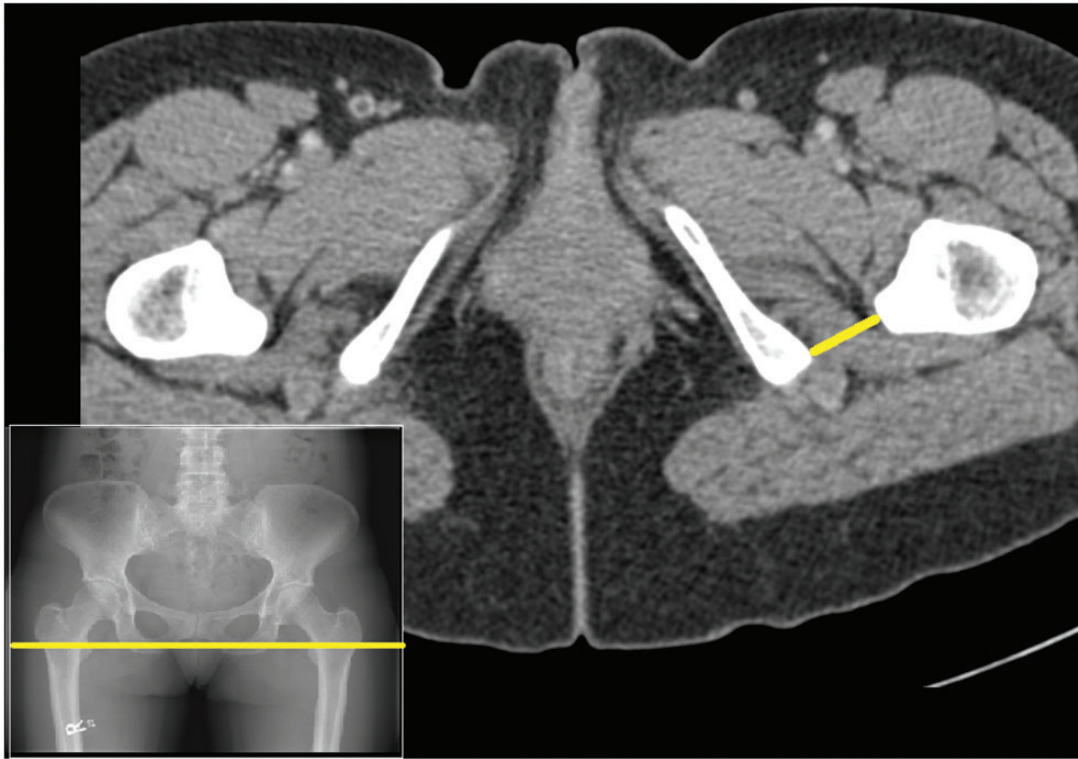


Fig. 1. Axial CT images through the level of the lesser trochanter showing the IFD.

and the feet in the subject's natural resting position without any external deforming force or supporting equipment. The CT data were acquired via axial slices (<3 mm) and then reformatted into sagittal and coronal sections.

The software used to view the CT scan images was General Electric PACS system Version V3.0 (8.0.1400.39). PACS measurement tools (distance and angle) were used to obtain the required measurements.

Two independent observers (Orthopaedic Research Fellow and Orthopaedic Registrar) reviewed the images independently and performed the measurements, which included: IFD (Fig. 1), offset, neck-shaft angle and retroversion angle. These measurements were then repeated 4 weeks later, with the observers blinded to previous measurements.

The neck-shaft angle was defined as the angular difference between the trabeculae in the axis of the neck and the axis of the femoral shaft, offset was defined as the distance from the centre of the femoral head to axis of the femoral shaft and retroversion of the lesser trochanter was defined as the angular difference between the axis of the femoral neck and the axis of the lesser trochanter in the transverse plane.

The neck-shaft angle and the offset were measured using coronal CT images. The lesser trochanteric

retroversion and the IFD were measured using axial CT images. For the purpose of this study, the IFD was measured on three or more adjacent axial images through the lesser trochanter. From each group of measurements, the smallest distance was considered to be the IFD. The same observer performed a second set of measurements after 4 weeks blinded to previous measurements to calculate the interobserver and intraobserver reliability.

Paired *t*-tests were performed to test the differences in IFD measurement performed by the two observers and to examine the precision of the measurement by each of the observers working on the project.

Correlations were calculated to assess the association between the set of measurements considered for analysis. Univariate and multivariate regression analyses were conducted to examine the association between IFD and the other measurements of interest. IFD measurements were considered as the outcome variable in linear univariate and multivariate regression analysis. All regression analyses were adjusted for possible age and gender differences.

RESULTS

A total of 298 hips (149 subjects) were included in the study, there were 71 males and 78 females (M: 48%, F: 52%), with a mean age of 51 ± 19 years (range 18–92).

Eighty-eight subjects had their CT for abdominal pain, two for fever, 11 for gynaecological abnormalities, three for a staging CT and 45 for a urological abnormality.

Assessment for differences between the first and second IFD measurements performed by each of the observers involved in the project indicated that these measurements were not statistically significantly different (paired *t*-test, $P = 0.79$ and $P = 0.68$, respectively, for the first and second observers).

Assessment of interobserver differences in the IFD measurements indicated that there was no significant difference between the observations made by the two observers (paired *t*-tests, $P = 0.63$).

The average IFD in the whole population sample was 20.7 ± 8 mm. The mean IFD was 18.6 ± 8 mm in females and 23 ± 7 mm for males; this difference was statistically significant ($P < 0.001$) (Fig. 2).

Descriptive statistics of the variables measured is shown in Table II. The correlation between measurements is shown in Table III. Among all correlations calculated, the highest was between the offset and IFD and offset and neck-shaft angle. While the correlation between the offset and IFD was positive (0.51), the correlation between offset and the neck-shaft angle was negative (-0.52). In all other cases, the correlations were close to 0, and therefore it would seem that there was little association between these variables.

Results from the multivariate regression are shown in Table IV. These results suggest that per extra year of age, the IFD decreases by 0.09 mm and that women have lower IFD values than men. Further, per extra millimetre of offset, IFD increases by 1.06 mm.

DISCUSSION

There have been previous studies reporting IFI but none have provided detailed measurements of the relevant anatomy in a proportionate population. This, and a lack of standardization of hip positioning, made it very difficult to interpret quoted reference results of previous studies.

Johnson [3] first described IFI in 1977 as a potential cause of hip pain after total hip replacement and proximal femoral osteotomy. The article defined the distance between the lesser trochanter and the ischial tuberosity as ~ 2 cm when the hip is in extension, adduction and external rotation. However, this study did not provide information as to the source of this figure and no measurement data were provided.

In an attempt to measure the normal IFD, Torriani *et al.* [9] used a controlled group consisting of 11 hips from 10 female patients who underwent hip MRI following trauma to exclude a fracture. The hips were positioned in

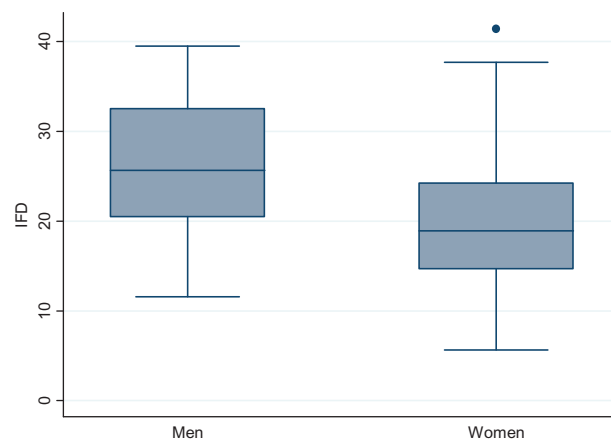


Fig. 2. Correlation between IFD and gender.

internal rotation with feet secured by adhesive taping. They reported that the IFD measured was 23 ± 8 mm. However, most of the scans were being done for hip trauma, which introduces bias. In this study, trauma was an exclusion criterion as this can affect the resting position, flexibility of the hip and the surrounding soft tissue. The exclusively female population studied in Torriani *et al.*'s and the small numbers of patients involved also limited the study's applicability to other cases.

Sussman *et al.* [11] measured the IFD using 16 cadavers (29 hips). The mean IFD was 23.5 ± 4.7 mm. However, their average age was 83.6 years and to measure the IFD they had to resect the gluteus maximus. The storage process of the cadavers could have affected the quality of the soft tissue between the femur and the pelvis, and subsequently the position of the hip. Also, in 51.7% of the cadavers the quadratus femoris muscle was found to be abnormal suggesting previous injury or degenerative changes.

In another case report, Ali *et al.* [5] described IFI following hip trauma causing a snapping hip. They performed a bilateral hip MRI and compared the IFD between the symptomatic and asymptomatic side. Another MRI was performed 7 months following the traumatic episode, which showed no difference between the IFDs and no abnormality of quadratus femoris. Another MRI at 19 months following the injury showed reduction of the IFD, and the 24-month MRI revealed further narrowing to 14.6 mm on the right and 22 mm on the left. They used the measurement published by Torriani as a reference and considered the distance measured in their study abnormally low. However, it is quite likely that the variation in rotation of the hip between Torriani's study and Ali's case study may have significantly affected the results.

Table II. Descriptive characteristics of the sample examined

	Male	Female	Mean ± (SD)	Range
Age	51 (18–92) years	51 (18–83) years	51.2 ± (19) years	18–92 years
Neck-shaft angle	133.5 ± (3.6)°	134.3 ± (3.5)°	134.14 ± (3.56)°	123–147.1°
Offset	35 ± (5.7) mm	35.8 ± (22.5) mm	33.70 ± (4.62) mm	22.39–46.25 mm
Lesser trochanter retroversion angle	28.7 ± (7.5)°	34.5 ± (8)°	33.14 ± (8.23)°	13.4–53.3°
IFD	23 ± (7) mm	18.6 ± (8) mm	21.35 ± (8.15) mm	5.64–41.43 mm

Table III. Correlation matrix of the variables observed

	IFD	Age	Neck-shaft angle	Offset	Lesser trochanteric retroversion
IFD	1.0				
Age	−0.20	1.0			
Neck-shaft angle	−0.14	−0.30	1.0		
Offset	0.51	0.18	−0.52	1.0	
Lesser trochanteric retroversion	−0.11	0.11	−0.13	−0.14	1.00

Patti *et al.* [9] in a case report described IFI in a native hip joint with no history of trauma or surgery. Radiographs and MRI showed severe narrowing of the IFD however no measurement was provided.

Hip positioning

Having considered the differences in hip position between previous studies, we looked at the appropriate way to standardize patient positioning in our own.

A pilot study measuring the IFD in a healthy subject (no history of hip pathology) was performed to assess the correlation between position of the limb and the IFD using MRI. The pilot study showed that holding the feet together did not significantly influence the IFD. However, the IFD was significantly influenced when forced external or internal rotation was applied to the feet. In addition, it is showed that the IFD was small when the hip was in extension and forced external rotation. The pilot study also highlighted the difficulty in visualizing the outer cortex of both the ischium and lesser trochanter using MRI, and it

Table IV. Results from the multivariate regression analysis—likelihood of correlation with IFD

	Beta ± (SE)	P values
Age	−0.09 ± (0.04)	0.01
Sex (1 = women, 0 = men)	−3.29 ± (1.77)	0.06
Neck-shaft angle	0.30 ± (0.24)	0.24
Offset	1.06 ± (0.17)	0.00
Lesser trochanter retroversion	0.07 ± (0.008)	0.42

was therefore decided to use CT for accurate measurements of the IFD.

The pilot and review of other radiography also showed that inter-patient variation in femoral neck anteversion means that standardizing the position of the feet and knees does not standardize the hip position. Adding this to the practical limitations of using a non-standard position to set the standard IFD, we decided that it was both more feasible and useful to assess the IFD in the patient's resting position. Using the resting position of the limb for the measurement makes the results of this study more applicable to pre-existing imaging and future studies alike, as it utilizes the standard position used when imaging the hip.

This study shows that the IFD was larger in males by an average of 4.4 mm, showing a positive correlation with the offset. This is understandable as an increased offset, distances the femur from the pelvis, subsequently increasing the IFD. The above finding correlates with the reported higher incidence of IFI in female patients [4, 6, 12].

In addition, this study showed that the IFD reduces by an average of 0.09 mm per year. This may be related to the loss of articular cartilage volume, which normally decreases by 2–3% per year [13] or possibly reduction in soft tissue volume around the hip joint.

Future direction

Whilst this study gives a more accurate standard reference for the normal IFD, we did not look at the intervening muscle or consider how it was affected by this variation. A future study that would likely be of benefit is an MRI assessment of the level of physiological impingement of the quadratus femoris muscle to allow us to better understand the biomechanics of the situation in patients showing symptoms of IFI [4, 6, 14]. Further understanding of the normal and diseased muscle and its correlation to the distance would likely also guide treatment options for this patient group.

Limitations

Given the population that this study was conducted on is limited, this study did not record or control for racial origin of the patients involved. It is therefore possible that different racial groups may show substantial differences in IFD, and future studies in this area may be warranted.

The difficulties in using an MRI for assessment of the IFD cause a problem. While a CT appears to be by far more practical for assessing the size of the patients' IFD, MRI is the investigation of choice for the most likely effect of this—damage to the quadratus femoris muscle. We anticipate MRI being used more often on these patients and we believe that these results are still applicable in this situation.

Another limitation of this study lies in the assessment of the neck-shaft angle and offset. While we measured these parameters with the information we had available (i.e. CT), they are normally measured on an anteroposterior radiograph with the patient's hips in forced internal rotation. However, we still believe that these results are still useful because of the standardized fashion in which they were measured throughout the cohort.

CONCLUSION

The mean normal IFD in a healthy female in a relaxed hip position is 18.6 ± 8 mm and 23 ± 7 mm in males with the distance reducing by an average of 0.09 mm per year.

FUNDING

This research received no specific grant from any funding agency in the public, commercial or not-for-profit sector.

CONFLICT OF INTEREST

None declared.

REFERENCES

1. Khanduja V, Villar RN. The arthroscopic management of femoroacetabular impingement. *Knee* 2007;**15**:1035–40.
2. Imam S, Khanduja V. Current concepts in the diagnosis and management of femoroacetabular impingement. *Int Orthop* 2011;**35**:1427–35.
3. Johnson KA. Impingement of the lesser trochanter on the ischial ramus after total hip arthroplasty: report of three cases. *J Bone Joint Surg Am* 1977;**59**:268–9.
4. Torriani M, Souto SC, Thomas BJ, et al. Ischiofemoral impingement syndrome: an entity with hip pain and abnormalities of the quadratus femoris muscle. *Am J Roentgenol* 2009;**193**:186–90.
5. Ali AM, Whitwell D, Ostlere SJ. Case report: imaging and surgical treatment of a snapping hip due to ischiofemoral impingement. *Skeletal Radiol* 2011;**40**:653–6.
6. Tosun O, Algin O, Yalcin N, et al. Ischiofemoral impingement: evaluation with new MRI parameters and assessment of their reliability. *Skeletal Radiol* 2012;**41**:575–87.
7. Blankenbaker DG, Tuite MJ. The painful hip: new concepts. *Skeletal Radiol* 2006;**35**:352–70.
8. Stafford GH, Villar RN. Ischiofemoral impingement. *J Bone Joint Surg Br* 2011;**93**:1300–2.
9. Patti JW, Ouellette H, Bredella MA, et al. Impingement of lesser trochanter on ischium as a potential cause for hip pain. *Skeletal Radiol* 2008;**37**:939–41.
10. Kassarian A. Signal abnormalities in the quadratus femoris muscle: tear or impingement? *Am J Roentgenol* 2008;**190**:W379.
11. Sussman WI, Han E, Schuenke MD. Quantitative assessment of the ischiofemoral space and evidence of degenerative changes in the quadratus femoris muscle. *Surg Radiol Anat* 2013;**35**:273–81.
12. Tosun O, Cay N, Bozkurt M, et al. Ischio femoral impingement in an 11-year-old girl. *Diagn Interv Radiol* 2012c;**18**:571–3.
13. Hanna F, Ebeling PR, Wang Y, et al. Factors influencing longitudinal change in knee cartilage volume measured from magnetic resonance imaging in healthy men. *Ann Rheum Dis* 2005;**64**:1038–42.
14. O'Brien SD, Bui-Mansfield LT. MRI of quadratus femoris muscle tear: another cause of hip pain. *Am J Roentgenol* 2007;**189**:1185–9.