

Evolution of design considerations in complex craniofacial reconstruction using patient-specific implants

Sean Peel

Design & Research Engineer, PDR – International Centre for Design & Research, Cardiff Metropolitan University, UK

Mr. Satyajeet Bhatia

Consultant Maxillofacial Surgeon, University Hospital of Wales, Cardiff & Vale University Health Board, UK

Dr. Dominic Eggbeer

Head of Surgical & Prosthetic Design, PDR – International Centre for Design & Research, Cardiff Metropolitan University, UK

Mr. Daniel S. Morris

Consultant Oculoplastic and Orbital Surgeon, University Hospital of Wales, Cardiff & Vale University Health Board, UK

Ms. Caroline Hayhurst

Consultant Neurosurgeon, University Hospital of Wales, Cardiff & Vale University Health Board, UK

Abstract

Previously published evidence has established major clinical benefits from using Computer Aided Design (CAD), Computer Aided Manufacturing (CAM), and Additive Manufacturing (AM) to produce patient-specific devices. These include cutting guides, drilling guides, positioning guides, and implants. However, custom devices produced using these methods are still not in routine use – particularly by the UK National Health Service (NHS). Oft-cited reasons for this slow uptake include: a higher up-front cost than conventionally-fabricated devices, material-choice uncertainty, and a lack of long-term follow-up due to their relatively recent introduction. This paper identifies a further gap in current knowledge – that of design rules, or key specification considerations for complex CAD/CAM/AM devices. This research begins to address the gap by combining a detailed review of the literature with first-hand experience of interdisciplinary collaboration on five craniofacial patient case-studies.

In each patient case, bony lesions in the orbito-temporal region were segmented, excised, and reconstructed in the virtual environment. Three cases translated these digital plans into theatre via polymer surgical guides. Four cases utilised AM to fabricate titanium implants. One implant was machined from PolyEther Ether Ketone (PEEK). From the literature, articles with relevant abstracts were analysed to extract design considerations. 19 frequently-recurring design considerations were extracted from previous publications. 9 new design considerations were extracted from the case studies – on the basis of subjective clinical evaluation. These were synthesised to produce a design considerations framework to assist clinicians with prescribing and design engineers with modelling. Promising avenues for further research are proposed.

Keywords

Implants / Prosthetics, Computer Assisted Surgery, Computer Aided Design, Additive Manufacturing, 3D Printing, Surgical Guides, Orthopaedic Materials,

Introduction

Published evidence has established clinical and technical efficacy for Computer Aided Design (CAD), Additive Manufacturing (AM), and Computer Aided Manufacturing (CAM) in planning and producing patient-specific craniofacial surgical devices. CAD and AM or CAM have been successfully exploited to produce: patient-specific anatomical models [1-6]; pre-operative and intra-operative shaping jigs [7-13]; digital surgical plans [13-23]; custom drilling guides [21, 24-29]; custom cutting guides [17, 18, 20, 23, 26, 30, 31]; custom bone re-positioning guides [18, 19, 21, 32, 33]; and custom implants in titanium [32, 34-42] or polyether ether ketone (PEEK) [22, 34, 38, 43-55]. However, due to the relatively small number of published complex cases; inconsistencies between a broad range of software tools and procurement approaches; and a general trend in the literature to skip detailed device design analysis; commonly agreed design considerations do not yet exist for use by design engineers or surgeons.

This article identifies and evaluates key design considerations when digitally planning and designing complex craniofacial AM / CAM devices. To achieve this, it concludes a narrative literature review with a table which collates and consolidates frequently-cited considerations from previous work. Then, new data from five primary case studies are described, analysed, and concluded for analogous (and unique) considerations. A basic framework is proposed – to synthesise these primary and secondary sources and drive future decision-making. Lastly, the discussion chapter outlines some speculative design considerations which deserve further research. These have emerged from the case studies - but remain as-yet unproven across a wider sample, or in the literature. Incidentally, the term “design considerations” is used in place of “design rules” to reflect the evolving and patient-specific nature of the devices in question – and to allow scope for modifications depending on a patient’s unique needs. Issues of universality and generalisation are a recurring theme in this process.

In this study, complex craniofacial devices are defined as those which replace the geometry of two or more bony surfaces (or of comminuted defects). Geometrically simpler reconstructions such as many orbital floors or cranioplasty plates would be likely to involve fewer critical design considerations, or be more easily fabricated in a hospital laboratory [9-11]. This paper’s featured case studies were divided between cases of meningioma and fibrous dysplasia. Each case required disease excision and alloplastic reconstruction in the orbito-temporal region. The cases varied in four key ways: alloplastic reconstruction material; the degree of digital planning which was undertaken; the use (or not) of surgical guides; and naturally, in specific design details. Guides were produced in an epoxy resin via AM. Four AM implants were produced in Ti6Al4V ELI (grade 23). One implant was produced in PEEK via CAM.

Literature review

Articles were sourced from searches of the PubMed and Google Scholar indexes. Then abstracts were analysed for relevance and qualifying articles saved for full review. This review covers both complex craniofacial reconstructions and simple reconstructions (where a given issue is generalisable across categories) to establish the current state-of-the-art context.

Pathology implications

As noted, the case studies in this article cover fibrous dysplasia and meningioma. Fibrous dysplasia is a benign disorder involving abnormal bone growth - whose slower progression after adolescence usually limits excision and reconstructive surgery to only those patients experiencing severe aesthetic or functional problems [56]. Functional impacts include hearing loss, headaches, diplopia, vision loss, and sinusitis – with cosmetic concerns stemming from abnormal swelling of craniofacial bones [57]. Meningiomas are also usually benign and slow-growing; though some cases can be malignant - dictating a greater degree of urgency and full-excision where possible [58]. In benign cases on the other hand, the speed of pre-operative planning and device design is not generally a concern; with Gerbino et al. [23] reporting 20-35 days to produce patient-specific PEEK implants via an external supplier.

Conventional procedures

Where CAD workflows are not used to produce end-use parts, both simple and complex pre-formed implants and guides rely on laboratory planning and fabrication techniques such as: model surgery [3, 4, 12], carving and sculpting [11], press-forming [9-11, 59], laser welding [60], vacuum forming polymers [26], and shaping stock-plates against medical models [12, 13, 61]. Analogue approaches like these have been characterised as artisanal or unreliable – albeit utilising highly-specialised skills [11, 62, 63]. A further drawback centres on appropriate laboratory support not being universally available [60]. In cases where a pre-operative surgical plan is established, physical guides were (and are) not always used – relying instead on translating plans into theatre via subjective free-hand visual judgement [64, 65] or physical measurements [66].

Despite the acknowledged time-saving [10, 61, 67, 68] and accuracy [68, 69] benefits from pre-forming implants, it was (and is still) not a standardised approach; where intra-operative shaping of titanium mesh [70], polymethyl methacrylate (PMMA) [62, 71], hydroxyapatite [71], and autologous bone grafts [72] are used instead. Indeed, autologous bone grafting is still regularly identified as the gold-standard reconstruction material – at least for simpler reconstructions [44, 73-75]. This is surprising – in light of cited problems with significant bone resorption [76], longer surgeries, higher complication rates, and longer hospital stays [34].

Digital procedures

Surgical procedures undertaken with CAD planning, AM guides, and AM or CAM implants can be shorter, result in better accuracy of implant fit, reduce the likelihood of revisions [77], incorporate tailored implant mechanical properties [78], and improve implant osseointegration [79]. Navigation equipment can be used instead of, or in combination with surgical guides, to achieve high levels of implant placement accuracy [80] and excision confidence [52, 81] – bringing some

previously inoperable tumours into the realms of viability [58]. However, whilst navigation is useful, the hardware and software is expensive – reducing availability to many hospital units [67].

Up-front device cost is usually identified as the major disadvantage of AM and CAM devices [45, 54, 82]. However, given the reduced likelihood of revision surgeries and the reduced duration of in-patient admissions, the overall treatment cost can actually decrease [34]. This driver is in-addition to the numerous clinical outcome improvements noted above. Time-delays also create a barrier to universal adoption of digital workflows across specialties. Due to delays from pre-operative scans, data transfer, data segmentation, device modelling, and device fabrication [11], digital workflows cannot be used in emergency procedures such as immediate post-traumatic surgery.

CAD and AM or CAM techniques have been exploited successfully to repair or replace relatively simple craniofacial geometries such as orbital floor and medial wall fractures [32, 42, 80, 83], craniectomy defects [34, 44, 45, 54, 55, 82, 84] and deficient bone in the mandible [85] and zygoma [39, 50]. Complex procedures where precision is critical such as hemimandibulectomy with a fibula free-flap reconstruction [19, 30, 86-88], or midface osteotomies [18, 89, 90] have benefitted significantly from the digital approach; though usually with stock plate fixation or AM implants designed as highly customised mimics of those stock plates. Bones or grafts are usually held in their new positions by such implants – as opposed to creating an alloplastic bone replacements. Perhaps the greatest value from digital approaches is when implants are used to replace missing or excised bone with highly complex shapes - which would be difficult to accurately reconstruct using conventional techniques. Complex forms have been produced to successfully replace the temporal bone, orbital rim, sphenoid, frontal bone, and zygoma [23, 38, 49, 50, 52, 91].

Implant materials

No consensus exists about the most appropriate alloplastic reconstruction material. Indeed, there is no ideal choice [45, 82]. Instead, publications tend to identify positive and negative characteristics of titanium and PEEK as the two foremost digital options. Biocompatibility of titanium materials has been well established [92]. Indeed, titanium's potential for osseointegration is a major driver for certain beneficial applications [79, 93]. This is in addition to the previously-noted investigations into tailoring mechanical properties of AM implants – by manipulating internal structures.

Medical grade Ti6Al4V is used across the Selective Laser Melting (SLM) class of AM processes [94], and the Electron Beam Melting (EBM) (Arcam, Sweden) alternative [95]. Due to pre-heating each layer of powdered material before full melting occurs, the EBM process experiences fewer problems with residual heat-stresses [96]. The smaller temperature differential also means the process is generally quicker [95]. SLM-derived processes on the other hand, can achieve finer details and smoother surface finishes [97]. Fundamentally, AM production of titanium implants enables greater design freedoms than conventional machining. AM allows virtually any geometry to be reproduced with internal and external details, whereas CAM requires consideration of where the cutting tool can (or cannot) reach [1, 62]. Design for AM still requires expert input – particularly for optimising build orientations, support structures, surface finishing, and hole-reaming [32, 98].

Published digital workflow cases (or case series) demonstrate a slight bias towards the use of PEEK. These devices can exhibit greater similarity to bone strength, stiffness, and elasticity – which can reduce stress shielding [34]. Moreover, PEEK can contribute to devices which promote better patient comfort compared to titanium – by exhibiting lower thermal conductivity, lower density, and a lighter weight [82]. PEEK's radiolucency is often cited as a major benefit – for improved post-operative imaging [38, 48, 91, 99] which is particularly valuable in oncological cases. This material is suited to intra-

operative shape adjustments using burrs – which is reported as being necessary on an infrequent to moderate basis [44, 45, 52, 53, 99, 100]. Details about the precise causes behind the need for these adjustments are not covered in depth – especially in terms of early design process decision-making.

Design considerations

Although mid to low-end AM machines are increasingly affordable to individual hospital units [5, 6], effective patient-specific device design is contingent upon close multidisciplinary collaboration across engineering and clinical specialties [2, 11, 101]. Clinical papers about individual cases (or case series) often overlook detailed reporting of device design specifications, device modelling operations, or device detailing decisions. This could be because the reported production process undertaken by some external implant companies is one of relative detachment from the surgeon (with limited collaboration beyond an initial device request) [48, 49]. Alternatively, this may simply be because the importance of including such details for a wider audience (including design engineers) was overlooked - in favour of detailed descriptions of the pathology and the surgical procedure.

Published cases generally describe and justify material choices, and justify the application of a semi-digital or digital approach. There is often little detail on implant shape (beyond the near-universal recommendation to mirror contralateral healthy anatomy wherever possible) [15, 38, 39, 51, 52, 62, 83, 85, 100]. Where details are described, no effort has yet been made to generalise and synthesise the considerations around CAD and AM or CAM implant production. Table 1 collates and summarises the design considerations sourced from existing literature – by explicit reasoning or obvious inference. Considerations with fewer than three sources were excluded, as were obvious pre-requisites – such as the biocompatibility, good strength, and stiffness of PEEK and titanium.

ID:		Design considerations from literature:	Considered in:
<i>CAD / AM / CAM justification:</i>			
<i>A</i>	Consider overall treatment cost Vs. up-front devices cost. <i>High upfront costs can be offset by savings from reduced surgery time, hospital stays, and revision surgeries.</i>		[99], [38], [77], [76], [34]
<i>B</i>	Consider the CAD / AM / CAM approach when there is a desire to improve the accuracy of the cosmetic outcome. <i>Relative to conventional methods.</i>		[49], [91], [23], [44], [50], [38], [46], [99], [83], [39], [52], [102], [103], [100], [15], [88], [41], [75], [36],
<i>C</i>	Consider the CAD / AM / CAM approach when the defective anatomy is large and / or geometrically complex.		[49], [47], [85], [99], [91], [23], [44], [52], [103], [100], [77],
<i>D</i>	Consider the CAD / AM / CAM approach for reducing operative time.		[47], [99], [83], [91], [23], [50], [53], [38], [46], [39], [52], [22], [102], [104], [15], [88], [77], [41], [75], [36],
<i>E</i>	Consider the CAD / AM / CAM approach to produce implants with a more accurate fit.		[47], [50], [22], [54], [88], [77],
<i>F</i>	Consider the CAD / AM / CAM approach to overcome the downsides of autologous reconstruction. <i>Including: donor site morbidity, longer surgeries, compromised aesthetics, high dependency on surgeon skill, unpredictable resorption, and limited bone graft availability.</i>		[48], [85], [99], [23], [44], [51], [39], [52], [22], [102], [100], [104], [34], [56], [73], [36], [45]
<i>G</i>	Consider CAD / AM / CAM methods when a single-step excision and reconstruction procedure is required.		[48], [23], [44], [38], [52], [102],
<i>Material choice:</i>			
<i>H</i>	Consider PEEK if there is a preference for standard mini-plate fixation.		[49], [47], [48], [23], [51], [38], [52],
<i>I</i>	Consider PEEK for easy intra-operative modifications.		[47], [48], [99], [91], [23], [44], [53], [38], [45],
<i>J</i>	Consider PEEK for an alloplastic material with mechanical properties (and thickness) which are similar to cortical bone.		[48], [23], [44], [43], [52], [74],
<i>K</i>	Consider PEEK when there is a need for radiolucency (for radiotherapy or post-operative imaging).		[48], [99], [23], [46], [52], [54], [91], [38],
<i>L</i>	Consider avoiding titanium where there might be concerns with thermal conductivity or sensitivity.		[34], [54], [105],
<i>Strategy:</i>			
<i>M</i>	Consider the use of surgical guides to accurately translate the digital plan into theatre. <i>As a driver for CAD / AM / CAM use.</i>		[23], [44], [38], [75],
<i>N</i>	Consider navigation for excision guidance and implant placement in place of guides (where available).		[52], [22], [102], [15],

<i>O</i>	Consider basing implant designs on mirrored healthy anatomy wherever possible.	[85], [99], [83], [91], [44], [51], [52], [49], [15], [77], [106], [75], [62], [100], [39], [38],
<i>P</i>	Consider reconstruction-site soft tissue coverage to minimise skin tension and risk of implant exposure. <i>Could be via skin expanders, grafts, reducing implant volume or compromising ideal contours.</i>	[49], [47], [99], [45]
<i>Q</i>	Consider soft tissue contours in addition to bone. <i>Could involve mirroring soft tissues with hard when designing implant contours.</i>	[49], [22], [106], [75],
<i>R</i>	Consider bone cement for adjusting contours or margins.	[47], [38], [102],
<i>Detailed modelling:</i>		
<i>S</i>	Consider adding holes or a mesh pattern into the main implant area. <i>To: provide a foundation for securing the dura and temporalis muscle, preventing epidural hematoma, encouraging better tissue integration and cell growth, reducing weight, and lowering temperature conductivity.</i>	[23], [38], [37], [77], [41], [39],

Table 1: Collated and consolidated design considerations from literature

Materials, methods and results

This section describes the methods employed for device design and fabrication – in the context of their clinical approaches. Results are presented immediately after each case – because they dictated key subsequent method modifications. All devices were prescribed and implanted by the same UK maxillofacial surgeon, in the same hospital, with significant input from a multidisciplinary team including neurosurgery and ophthalmology colleagues. All digital planning and design work was undertaken in collaboration with a university-based design development and research institute. In all cases, the digital workflow was selected to overcome problems experienced by the maxillofacial surgeon in using conventional and semi-digital techniques in prior complex reconstructions. For example, a meningioma patient with failed autologous bone graft reconstruction had undergone revision surgery at the hospital, using titanium mesh which was intra-operatively shaped on an anatomical model. The result was judged only as acceptable - with scope for improvement in aesthetic accuracy, eliminating donor-site morbidity, improving visual functional outcomes, and reducing surgery duration.

The digital workflow involved (to varying degrees) the use of medical models, digital surgical planning, patient-specific guide design, patient-specific implant design, polymer guide fabrication and metallic implant fabrication. Pre-operative Computed Tomography (CT) scanning was utilised for each patient. CT data processing was undertaken by a design engineer at the institute using a standardised procedure and appropriate CE-marked software (Mimics, Materialise, Belgium). All polymer models and guides were fabricated using StereoLithography Apparatus (ProJet 6000HD, 3D Systems, USA) in Accura ClearVue resin (3D Systems, USA) which has been tested to USP 23 Class VI – rendering it suitable for sterilisation and for building transient surgical devices when parts are cleaned appropriately. Polymer devices were prepared for fabrication and had support structures added using Magics (Materialise, Belgium).

Device design was undertaken by institute engineers using FreeForm Plus (3D Systems, USA) in all cases - via its haptic PHANTOM interface. Implants in cases 1-4 were fabricated by Laser Melting (LM) Ti6Al4V-ELI (medical grade 23) by an appropriately accredited supplier (3D Systems LayerWise, Belgium). Titanium was selected by the surgical team on the basis of a long track-record of success in the hospital and the wider maxillofacial specialty – in addition to the titanium benefits highlighted in the literature review chapter. Implant components in case 5 were fabricated by five-axis CAM of PEEK by a similarly qualified supplier (Synthes, Switzerland). PEEK was selected for this case because of a high-degree of confidence that post-operative radiotherapy would be necessary. PEEK's radiolucency was judged to be important – for post-operative imaging and radiotherapy uninterrupted by scatter or artefacts; important for surveillance and treatment.

Case 1 - methods

Patient 1 presented with headaches, a drooping eyelid, eye asymmetry, left-eye exophthalmos, worsening vision, and diplopia on far-left gaze. Following consultation and pre-operative CT imaging, a left speno-orbital intra-osseous meningioma was diagnosed and an anatomical model requested from the institute by the surgeon – in addition to images showing the engineer's interpretation of the tumour via manual segmentation. The model, images, and raw scan data were used at an interdisciplinary clinical meeting to determine the surgical plan and excision margins – which were drawn on to the model in pen. At the institute, the engineers transferred the agreed margins to the virtual model using the haptic design software, deleted the anatomy inside this boundary, and protected the resulting virtual model against further modifications by setting it as a “buck” component. This interpretation was verified by the surgeon via emailed images.

As a basis for accurate implant design, the contralateral healthy anatomy was mirrored to reconstruct the defect in the virtual environment. The resulting shapes were smoothed and blended into the surrounding remaining original anatomy. Material was layered-on to this foundation with a thickness of 0.8mm – indicating the extents of the final titanium implant. As shown in figure 1, the implant was formed of two components which overlaid the excision margin in order to ensure good support around the edges. Two non-interfacing components were judged to be necessary to permit insertion from two separate directions. The implant replaced the outer bony surface of the defects – not the full bone thickness. Fixation tabs for the orbital component were brought out to the rim – to permit screwdriver access. Fixation tabs for the temporal component were extended – with a view towards permitting successful fixation even in the event of a larger-than-anticipated excision. This would have been necessary if the lesion had grown significantly since the scan was undertaken or if the extent of tissue involvement was difficult to judge pre-operatively. Fixation holes of 1.7mm diameter were added (intended for 1.5mm screws). Fluid transfer holes of 2mm diameter were spaced arbitrarily across the orbital component – but kept away from the implant edge. The implant designs were verified by the prescribing surgeon via emailed images and a 3D PDF - and then sent for fabrication. A satin surface finish was requested – as well as post-fabrication reaming for the screw holes.

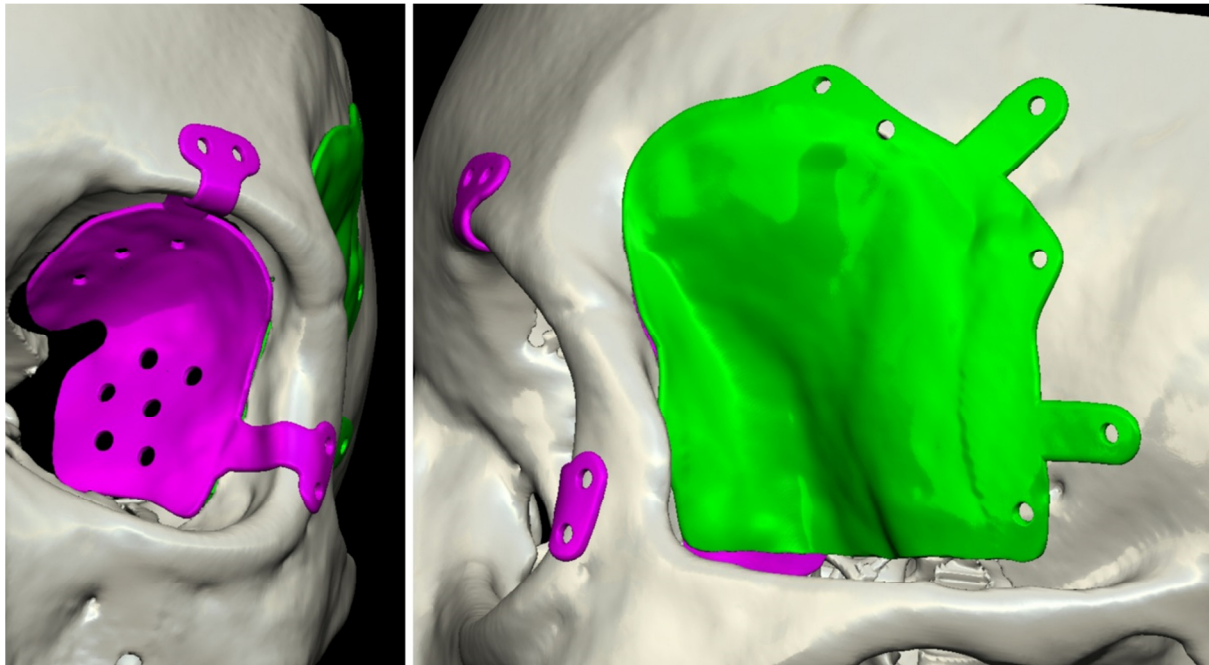


Figure 1: Implant designs for case 1

Prior to surgery, a medical model of the digitally-planned excision was fabricated, and delivered with the finished implant components for sterilisation at the hospital. In theatre, a pre-trecheal approach was used for site exposure – aiming to achieve good post-operative aesthetics by positioning the incision behind the hairline. The tumour excision was performed, and the implants placed successfully. No significant modifications to the pre-operative digital or clinical surgical plans were required.

Case 1 – results

This case had a four year follow-up at the time of writing. The patient's exophthalmos was reduced by 4mm – though was not wholly eliminated. Post-operatively there was a black spot in the patient's visual field at the far left of their gaze – this persists. All other pre-operative symptoms were resolved – with a good initial aesthetic result. Three years-on from the

procedure, the patient complained of soft tissue hollowing around the temporal implant region – this was corrected by transferring fat grafts into the area.

Subjective evaluation by the surgeon deemed the single-piece orbital implant design to have resulted in some difficulty with positioning the device intra-orbitally. The surgeon judged a clear and noticeable reduction in surgery duration versus previous cases undertaken with conventional or semi-digital methods. However, quite obviously there remain no direct comparisons for the same patients. The total cost of the digital surgical planning, anatomical models, and patient-specific implants to the NHS was £1988.00 - excluding Value Added Tax (VAT).

The surgical team highlighted three tentative hypotheses for consideration in subsequent cases: the single-piece design of the orbital component led to the black spot in the visual field (by preventing perfect placement); the on-lay orbital component design caused residual (minimal) post-operative exophthalmos by reducing the orbital volume; and exaggerated fixation tab lengths to permit larger excisions than planned are a worthy inclusion (albeit not required in this case).

Case 2 - methods

Patient 2 presented with left-eye exophthalmos, headaches, seizures, and decreasing vision. Following consultation and pre-operative CT imaging, a left skull-base meningioma was diagnosed – extending to the temporal bone and posterior orbit. An identical method was applied to this case as for patient 1 – up to and including the stage of reconstructing the planned excision by mirroring healthy contralateral anatomy on the virtual model. This time, as shown by figure 2 a three-component implant design was modelled (0.5mm thickness) – on the basis of being in-laid into the defect margin. The three component design was selected with the aims of addressing the orbital component-placement issue from case 1, and to make the overall implant success less dependent on the success of each individual component. The in-lay design was selected to target the orbital volume hypothesis from case 1. A diamond mesh pattern was embossed into the implant components with a speculative aim of improving any future radiotherapy delivery - in case of disease recurrence. Countersinks were designed-in at the points of fixation. Again, the implant design was verified by the prescribing surgeon – with the same post-fabrication finishing processes requested.

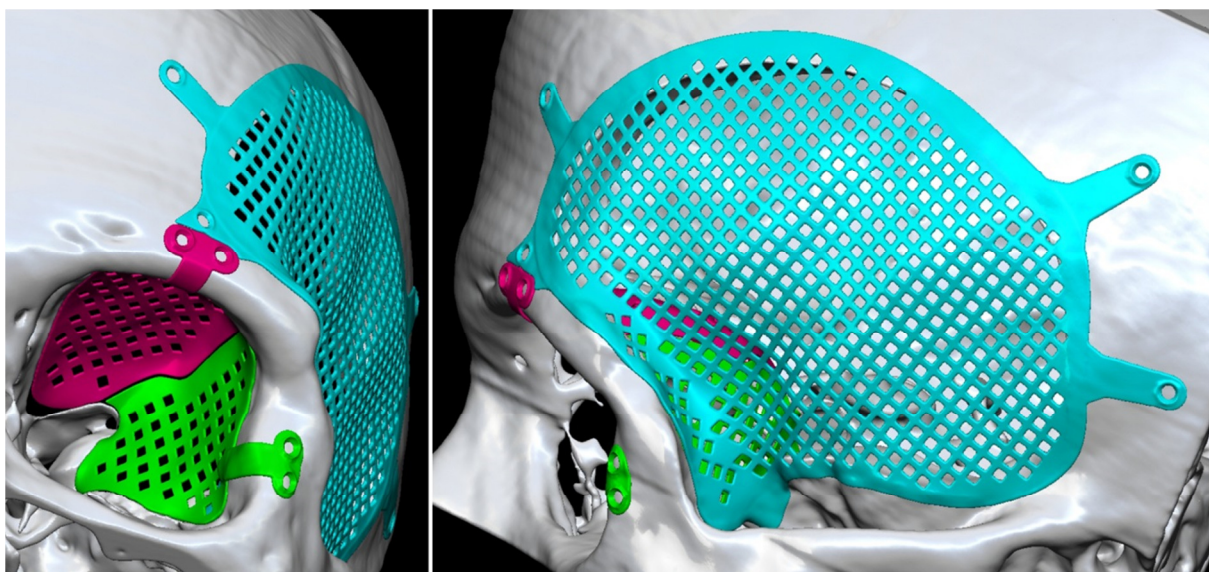


Figure 2: Implant designs for case 2

In theatre, a coronal approach was utilised. The tumour excision was performed – mostly according to the pre-operative clinical and digital plan with one key exception. Excision of bone from the posterior orbit was more difficult than expected – as well as being less critical than considered during the plan. The orbital roof component required intra-operative trimming in order to fit the smaller-than-anticipated defect. This slightly reduced the surgery-duration benefit of using the digital approach, and proved to be a difficult task for the available tools because of the hardness of the implant material.

Case 2 – results

This case had a three year follow-up at the time of writing. The patient’s exophthalmos was reduced –again, not wholly eliminated, but demonstrating a better reduction than for patient 1. Post-operatively there was one further issue - seroma of the soft tissues – which resolved spontaneously over eight weeks. All other pre-operative symptoms were resolved – with a good aesthetic result. There has been no disease recurrence and therefore no need for radiotherapy.

Subjective evaluation by the surgeon deemed splitting the orbital reconstruction into two components to have improved the manoeuvrability of the lateral component relative to case 1. Aside from having to trim the posterior aspect of the orbital roof component, some difficulty was noted with achieving the butt-joint interface between the two orbital components. Independent fixation for the components was highlighted as being of particular importance to minimise the impact of these unexpected challenges – tiny positioning compensations could be made. Again, the surgeon judged a clear and noticeable reduction in surgery duration versus previous cases undertaken with conventional or semi-digital methods – though not as significant a reduction as would be possible without the noted issues. The total cost of the digital surgical planning, anatomical models, and patient-specific implants to the NHS was £2590.00 - excluding VAT.

The surgical team highlighted three tentative hypotheses for consideration in subsequent cases: a lack of built-in margin flexibility reduced the impact from the digital workflow by forcing time-consuming implant modifications; the missing bony surfaces did not need to be replaced entirely to achieve the desired functional results; and designing an in-lay implant rather than an on-lay implant did not fully solve the patient’s exophthalmos – so reconstructing a smaller portion of orbital roof may achieve full orbital volume correction.

Case 3 – methods

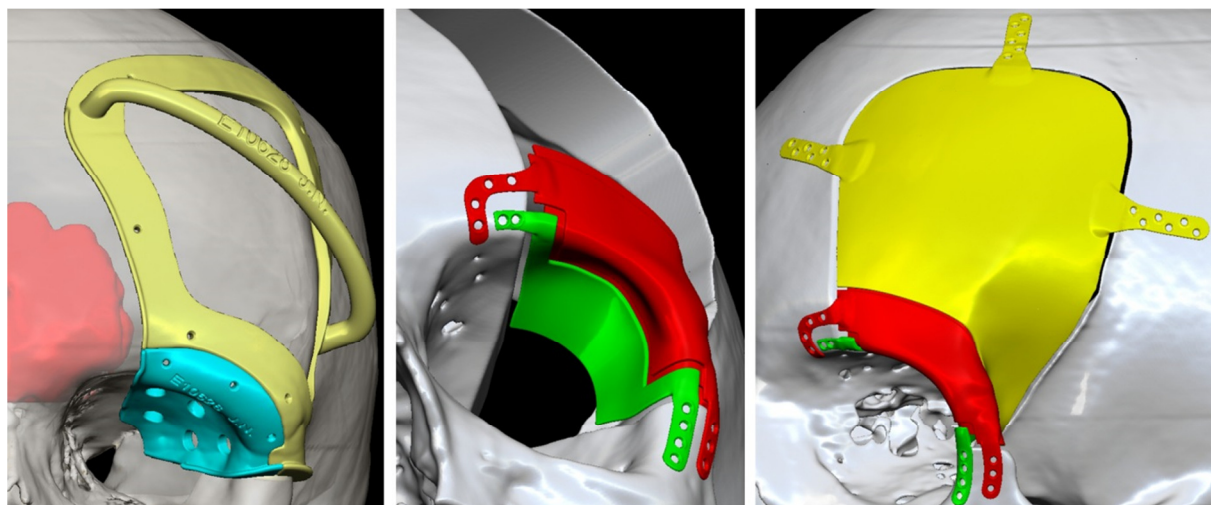


Figure 3: Guides and implants designs for case 3

Patient 3 presented with left-eye exophthalmos, pain, decreasing vision, and a visual field defect. Following consultation and pre-operative CT imaging, fibrous dysplasia was diagnosed in the patient's left cranio-orbital region. An identical method was applied to this case as for patients 1 and 2 – up to and including the stage of reconstructing the planned excision by mirroring healthy contralateral anatomy on the virtual model. This time, as shown by figure 3, the excision margin included the critical aim of avoiding the frontal sinus. As such, patient specific cutting guides were designed after highlighting the frontal sinus volume in the patient's scan data and overlaying it onto the digital plan. The guides were realised by layering a 2.5mm thickness of material onto the foundation of the patient's original anatomy. Care was taken to model a cutting ledge (around the outside edge of the guide) which was perpendicular to the sinus border - in case of being used to guide the saw directly. Holes were added to provide the option of screw fixation. A two-part guide design was deemed necessary in order to fit onto the anatomy without being obstructed by the undercuts of the orbit and sphenoid. The two parts were designed to fit together with a notch feature – aiming to provide confidence in achieving correct positioning. Material was removed from the middle of the frontal guide – to accommodate potential further bone growth since the initial scan. A small handle was modelled for this component – with a view towards providing stability during use.

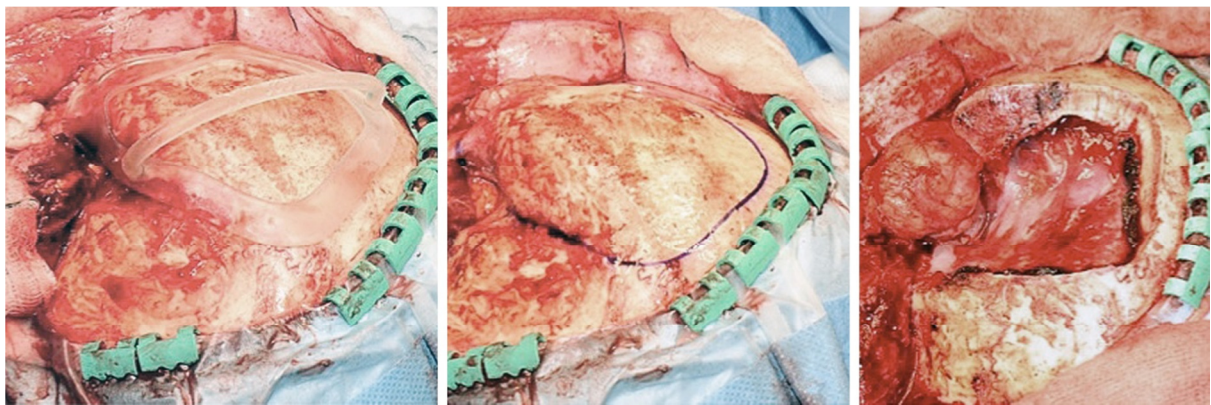


Figure 4: Intra-operative photographs of guided excision

The implant design (0.7mm thickness) consisted of three components with functional independence and both margin and fixation flexibility. A 1mm gap was deliberately left between the implant component edges and the defect edge – aiming to build-in scope for sub-optimal excision and implant location relative to the ideal scenario in the plan. Similarly, a 0.5mm gap was inserted between the implant components for the same reason. The orbital rim implant component incorporated recessed ledges running behind the intra-component gaps – targeting support of the other components without compromising flexibility. Long fixation tabs were used as in the previous cases. With the aim of addressing the residual exophthalmos from case 2, the orbital roof component extended only half-way posteriorly.

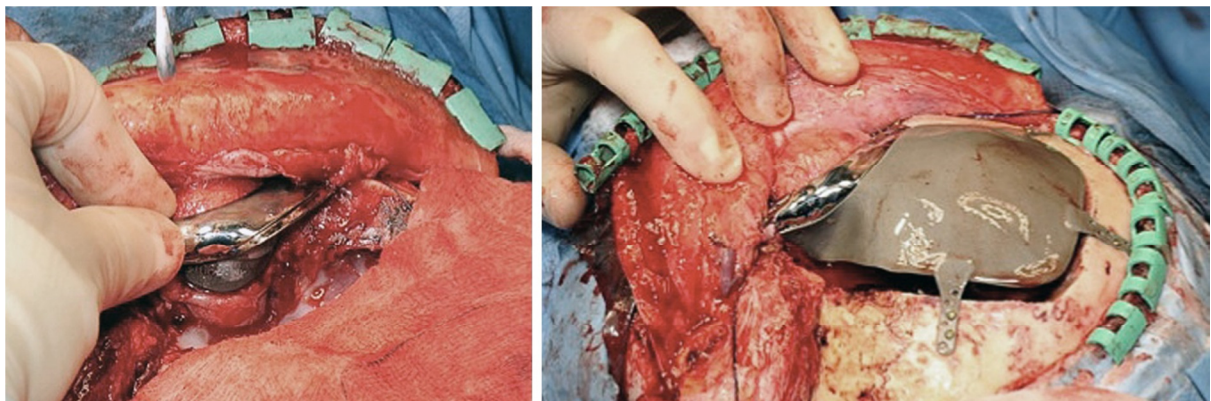


Figure 5: Intra-operative photographs of implant assembly

Identical pre-surgery verification, fabrication, and sterilisation actions were undertaken as for case 1 and 2 – with the exception of requesting a polished finish for the rim and orbital roof implant components. In theatre, a coronal-flap approach was employed for access to the site. In this case, the patient granted permission to publish images of the procedure and of the post-operative scans (figures 4-6). Figure 4 illustrates how the neurosurgeon preferred to use the guide as a template to mark the bone – before cutting along the line with an unobstructed view. The orbital guide was used to guide the saw directly – but from the brain-side of the already partially-completed excision. The frontal sinus was successfully avoided. All of the components performed exactly as planned – and the final implants (figure 5) were fixed quickly and easily.

Case 3 – results

This case had a two year follow-up at the time of writing. All pre-operative symptoms were fully relieved – including exophthalmos. Some post-operative ptosis of the temporalis muscle was noted by the surgeon. Additionally, left upper lid dermatochalasis was present – but no procedures were taken to correct this.

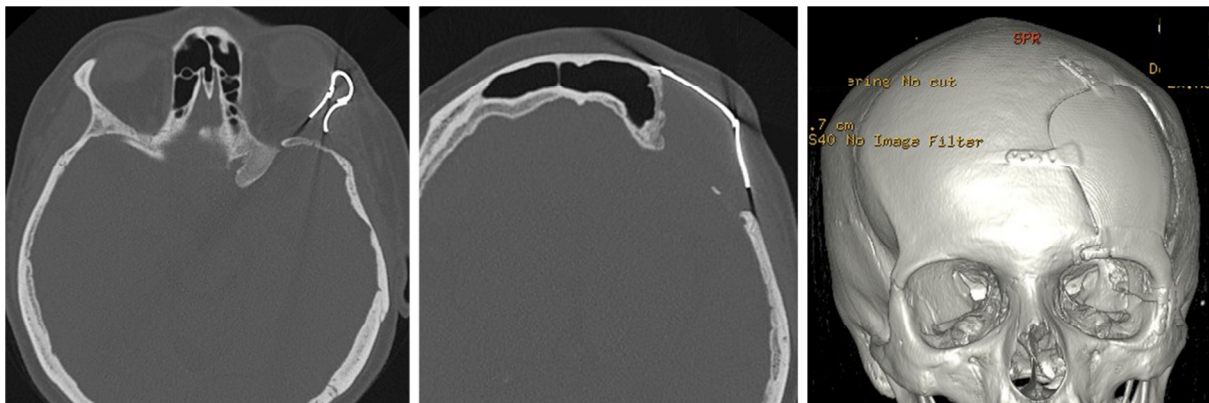


Figure 6: Images from post-operative scan

Subjective evaluation by the surgeon centred on the ease of implant insertion – following guided excision. This achieved an accurate translation of the plan into theatre. Figure 6 shows the successfully-inserted implants in a post-operative scan. The interfacing-but-independent implant components anticipated all reasonable plan deviations (though none were tested here). Again, the surgeon judged a clear and noticeable reduction in surgery duration because of this fully-digital method. The total cost of the digital surgical planning, anatomical models, patient-specific guides, and patient-specific implants to the NHS was £2828.00 - excluding VAT.

The surgical team highlighted four tentative hypotheses for consideration in subsequent cases: a lack of holes in the temporal region of the frontal-cranial implant prevented suturing of the temporalis muscle which led to minor ptosis; good fit and extremely quick fixation of the implant components was achieved by using guides – which should be used to translate virtually planned cuts wherever possible; implant component functional, fixation, and margin flexibility provided confidence in anticipating possible plan deviations and should be employed wherever possible; an in-lay design and restricting the posterior extension of the orbital roof component to the orbit “equator” contributed to a full resolution of exophthalmos in this case.

Case 4 - methods

Patient 4 presented with right-eye exophthalmos. Following consultation and pre-operative CT imaging, a right cranio-temporal-orbital meningioma was diagnosed – with intra-cranial involvement. Identical technical procedures were undertaken as in cases 1-3 to design and fabricate devices. As shown in figure 7, recommendations from those cases were followed: multi-part guides were designed to translate the planned excision margins into theatre; the implants (0.6mm thickness) were designed to leave a 1.5mm gap to the defect edge to address fixation and margin flexibility; the orbital implant components incorporated deliberate gaps so as to remain functionally independent; all components were in-lay designs – with the orbital parts extending only half-way posteriorly; fixation tabs were extended to accommodate larger-than-anticipated excisions; and a mesh pattern was applied to pre-empt potential radiotherapy and provide suture retention options for supporting the temporalis. Uniquely to previous cases, the guides also translated the cutting locations for osteotomising a portion of the lateral orbital rim – which was temporarily removed to improve access. The orbital implant component fixation arms were lengthened to serve a secondary function – fixing the osteotomised bone flap back in its original position. A satin finish was requested for the metal implants – and the same pre-theatre routine undertaken as described for other cases.




Figure 7: Guides and implants designs for case 4

In theatre, a coronal approach was used to access the affected area. The lesion was successfully excised – and the lateral rim bone flap replaced. All components fitted and functioned exactly as planned. No intra-operative complications were experienced.

Case 4 – results

This case had a 22-month follow-up at the time of writing. All pre-operative symptoms were fully relieved. The patient was concerned with palpability of fixation plates used for an extra craniotomy performed for improved access (but not involved in the craniofacial planning). However, no revision procedures were necessary. There has been no disease recurrence – and so no post-operative radiotherapy.

Subjective evaluation by the surgeon noted the particular importance of the guides in this case because of the morphological complexity of the affected area. The total cost of the digital surgical planning, anatomical models, patient-specific guides, and patient-specific implants to the NHS was £2890.00 - excluding VAT.

The surgical team highlighted how this case offered a validation of the considerations taken forward from previous cases.

Case 5 - methods

Patient 5 presented with, discharge from the left ear, swelling of the temporal fossa and decreasing vision. Following consultation and pre-operative CT imaging, a left sphenoidal meningioma was diagnosed – with middle cranial fossa involvement. As noted previously, this case (figure 8) was designed for fabrication from PEEK. Otherwise, identical technical procedures were undertaken as in cases 1-4 to design and fabricate guides and implants. As with case 4, a guide was designed to temporarily osteotomise a bone segment in order to improve access – in this case, from the zygoma. A temporal guide component included small tabs to indicate areas of bone planned for burring away. The PEEK implant was split into two components – one reconstructing the lateral orbit and the temporal bone, and the other reconstructing the potential excision of the glenoid fossa. Generally, an in-lay approach was used across both components - though tabs were designed into the temporal device – to brace against the residual cranium in the areas where guided burring was planned. This was surgeon-preference for a bracing tab-style fixation – rather than relying on mini-plates, which caused concern about implant-brain interference in the event of traumatic impact. 2.1mm diameter holes were added into the tabs for fixation with 2mm screws. Unlike the titanium implants, the PEEK was of a 3-7mm varied thickness to take advantage of the material's lower density and contribute to reconstructing the full bone volume. There were no significant modelling or design freedom restrictions to accommodate CAM limitations versus AM. This can be attributed to using five-axis milling, and the geometry of the implant being naturally sympathetic to this process.

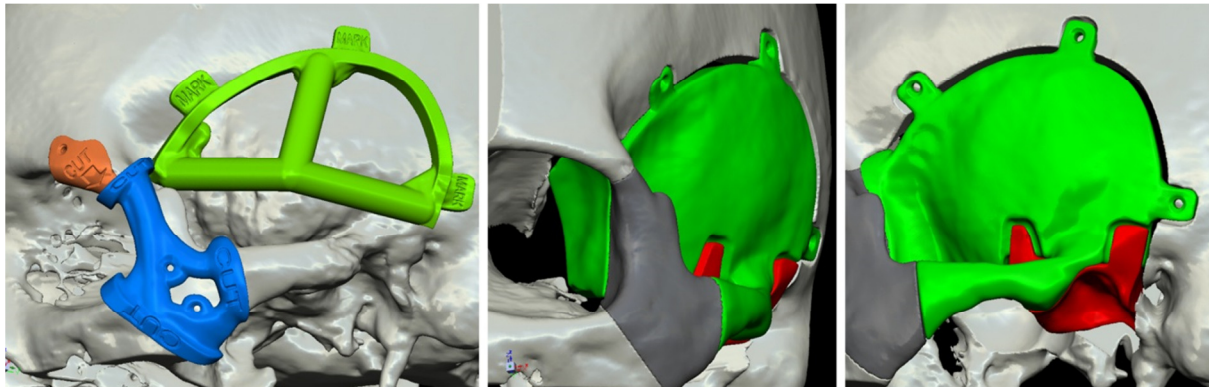


Figure 8: Guides and implants designs for case 5

In theatre, a coronal approach was used to access the affected area. The TMJ was not resected after being judged as too high-risk. The glenoid fossa implant component was left-out without affecting the performance of the temporal component. The bone flap was osteotomised for access and replaced successfully using mini-plates.

Case 5 - results

This case had a one year follow-up at the time of writing. All pre-operative symptoms were relieved though there were significant post-operative complications. The patient experienced expressive dysphasia for 24 hours post-operatively. The clinical team hypothesised ear and brain involvement as the cause – exacerbated by the ear being exposed to the surrounding environment. Additionally, there was a superficial wound infection for which the patient was taken to theatre for drainage

and washing of the wound. The decision was taken to leave the alloplastic reconstruction in place and instigate a long-term antibiotic routine. This was successful and negated secondary reconstruction surgery.

Subjective evaluation by the surgeon highlighted the further validation of the digital process and evolving design considerations provided by this case. The total cost of the digital surgical planning, anatomical models, patient-specific guides, and patient-specific implants to the NHS was £5644.00 - excluding VAT.

The surgical team highlighted two tentative hypotheses for consideration in future cases: choosing PEEK for this category of cases has no demonstrated downside (in this one example) aside from an increase in cost; and using a PEEK-tab fixation model (with guided bone burring) could offer a more stable fixation than relying exclusively on mini-plates.

Summary

The case studies corroborated design considerations B, C, D, E, F, G, K, M, O, and S from Table 1 – and introduced nine new considerations as shown in Table 2.

<i>New design considerations from case studies:</i>
Consider multi-part implant designs – particularly for the lateral orbital wall and orbital roof. <i>To enable easy manipulation of the components into the correct (pre-planned) positions.</i>
Consider robust independent fixation solutions for each implant component. <i>To build-in functional independence in case one component is omitted from the final reconstruction.</i>
Consider exaggerated fixation tab lengths . <i>To provide margin flexibility when excisions are larger than planned.</i>
Consider designing-in a deliberate gap between the planned margin and the main implant body . <i>To provide margin flexibility when excisions are smaller than planned.</i>
Consider designing-in a deliberate gap between interfacing implant components . <i>To provide positioning flexibility and avoid chain-tolerance errors in the event that one or more components is fixed sub-optimally.</i>
Consider using in-lay orbital implant designs. <i>To lower the risk of reducing the orbital volume.</i>
Consider restricting orbital roof component extents to the anterior half of the globe . <i>To lower the risk of reducing the orbital volume.</i>
Consider including fixation tabs in PEEK implant designs – with guided burring of residual bone at the interface points. <i>To offer a more stable fixation option – or when preferred over mini-plates.</i>
Consider using AM titanium where specific PEEK properties are not required. <i>To achieve similar benefits at lower cost.</i>

Table 2: Collated and consolidated design considerations from case studies

Discussion

Design considerations from the literature in Table 1, and from the new primary data in Table 2, together demonstrate a clear progression from macro to micro considerations for successfully designing and using state-of-the-art implants. Generally, considerations from the literature address contextual and materials issues well – and are supported by the new experiences described in this study. Specific design detailing issues are covered in considerably greater detail by the case studies – though with some key limitations as evaluated later in this section.

Design considerations synthesis

All five implants presented in the case studies were evaluated as clinical improvements over conventional methods in terms of: cosmetic accuracy; replicating complex geometries; reducing surgery durations; avoiding the downsides of autologous reconstructions; basing reconstructions on mirrored healthy anatomy; and helping to enable successful single-step procedures. After iterative improvements between cases, outcomes corroborated the literature in four other areas: using guides to accurately translate plans into theatre; achieving a more accurate implant fit; using PEEK for cases requiring radiolucency for post-operative radiotherapy and imaging; and applying holes or a mesh pattern across the main implant surfaces.

Post-operative soft-tissue (including muscle) concerns in cases 1 and 3, echo similar issues from other studies [39, 46, 52]. Currently, virtual soft-tissue predictions are difficult [106] and were not available in any of the cases 1-5. There was a reliance on clinical judgement instead – with no explicit design changes made beyond aiming for good symmetry. Recommendations where available are split between anticipating soft-tissue atrophy by over-correcting contours [106], mirroring soft tissues as well as hard tissues when planning implant forms [49], and noting that soft tissue asymmetry cannot always be dealt with using implants alone [44]. This is an important area for future investigation. The palpability issue in case 4 was not directly related to digitally designed and fabricated devices, but supports a general aim of making implants as small as possible – to avoid this and lower the risk of exposure [15].

The detailed design issues raised by the case studies have flexibility as the major theme – of fit, of function, and of margins. Alternative margin solutions to those summarised in Table 2 appear muddled – including the notion of deliberately designing over-sized implants, before adjusting them in-theatre once the margins are finalised [106]. Whilst this offers an answer to intra-operatively modified margins, it introduces extra time into the procedure as a matter of routine. The solutions from cases 1-4 of using long tabs, and deliberate gaps between the residual anatomy and the main implant components, at least create the probability of instant insertion without sacrificing fit and margin flexibility. The opposite solution has also been proposed – with deliberately-undersized implants having large gaps to the bone filled with cement [102]. This would still under-exploit the time advantages created by using digital surgical planning and custom implants.

Smaller margins than anticipated are difficult to foresee in similar cases – especially with using slice-by-slice analysis of the CT scan data to delineate the lesion at the point of planning [52]. Planning generous excisions [23] is supported, as is the use of guides to translate them into theatre – see Table 1. However, guides are not reported as often as expected (given the previously described benefits) which may indicate why PEEK's intraoperative modifiability is often cited as a significant positive. On the question of modifications versus plans, Table 1 lists seven reports which cited standard mini-plate fixation for PEEK devices. The solution from case 5 is unique in incorporating titanium-device-style tab fixation. The concern about the implant sinking into the skull is shared by Jalbert et al. [52], who chamfer the bone edge and contacting implant

edge to achieve a robust brace. Before judging effectiveness, a comparison would be needed between the time-taken to burr-away tab-acceptance grooves as in case 5, and the time taken to chamfer the bone and implant edges. Simpler edge-overlap approaches are demonstrated by Guevara-Rojas et al. [22] who also add fixation holes to the implant edge. For implant fitting flexibility, experience from the case studies which recommends multiple part devices is supported by Goodson et al. [50] – for aesthetic and insertion-path independence reasons.

Accurate cost assessments across techniques and materials are difficult because of variations between service provision, currencies, and the previously-identified bias towards PEEK devices in the literature – compared to AM titanium. Furthermore, titanium is sometimes identified as the chosen material – without full clarity on the fabrication method. Manrique et al. [99] provide an average cost for PEEK devices of \$8493 from six cases. This is at least somewhat similar to the cost of the PEEK implant in case 5. The AM titanium devices were of a lower cost in cases 1-4. This requires more evidence from future studies, but on the basis of the primary data available to the authors, Table 2 contains a consideration for using AM titanium where specific PEEK properties are not required.

Figure 9 presents a framework for design considerations in complex craniofacial implants – evidenced by literature and new case studies from this article. It does not cover all considerations or stages a clinician or engineer would address in the specification and design processes – just those extracted using the methods in this study. This is to begin to address the evidence-gap which exists in justifying and implementing CAD / AM / CAM devices, without becoming a subjective instructional guide, or prescribing answers to support a given interest. Avoiding specific instructions also has the aim of producing a framework which is generalisable across implant services and design tools where possible. Multi-disciplinary management across specialties is important in complex cases [91] – and translating between competencies (including design or engineering) is difficult [41]. Figure 9 proposes a structure for thinking about key considerations across specialties.

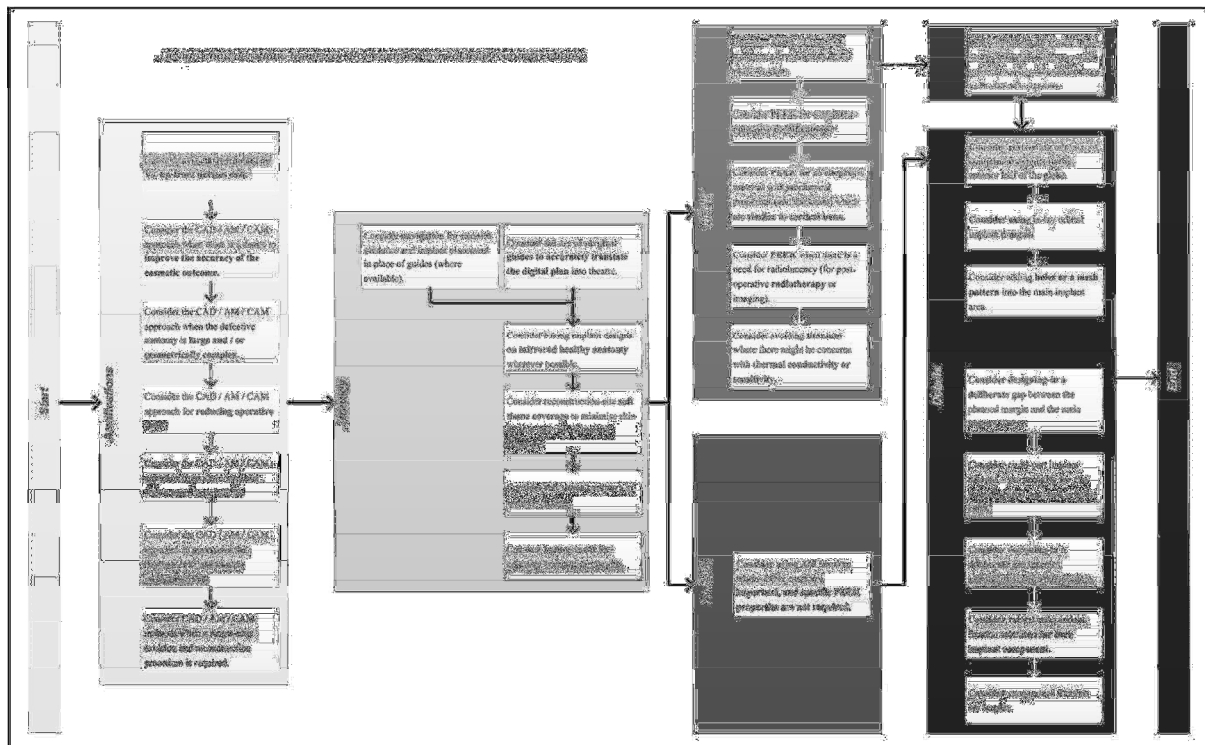


Figure 9: Design considerations framework

Study limitations

Although the findings in this paper are drawn from triple-sourced literature review, from primary-data, or from a combination of both, key limitations persist and should be highlighted explicitly. The primary data comes from a single hospital unit and a single surgeon in collaboration with a single implant design service comprising two design-engineers. The conclusions drawn from this data have only been shown to apply in these cases – or in isolated cases within this series. The primary data is skewed towards titanium implants – and the secondary data review skewed towards PEEK. Further work is required on both fronts to address these imbalances and small sample sizes. Surgery duration evaluations from the primary data relied on subjective estimates – future work on health economics within this and other hospital units is required to build a fuller picture. Finally, it should be noted that the varied AM titanium surface finishes were selected based on surgeon preference – the implications of these choices provide another avenue for future investigations.

Conclusions

This study has extracted 19 design considerations for complex craniofacial implants from secondary sources, and 9 unique design considerations from new case series data. The considerations have been arranged into a structured framework for use across specialties in the procurement and delivery of CAD / AM / CAM implants. It encompasses justifications-for-use, modelling strategies, materials selection, and design detailing.

Future work must involve long-term follow-up of the case series patients, generating and reviewing a larger body of evidence to expand (or contract) the considerations framework, and validation of the case-series-derived considerations across a larger sample. As a general note, the authors recommend describing design considerations and decisions in detail when publishing on CAD / AM / CAM to allow audiences to develop an understanding of key decisions – beyond the choice of technology.

References

- 1 **Mankovich, N., Cheeseman, A. and Stoker, N.** The display of three-dimensional anatomy with stereolithographic models. *Journal of Digital Imaging*, 1990, **3**(3), 200-203.
- 2 **Sugar, A., Bibb, R., Morris, C. and Parkhouse, J.** The development of a collaborative medical modelling service: organisational and technical considerations. *British Journal of Oral and Maxillofacial Surgery*, 2004, **42**(4), 323-330.
- 3 **Petzold, R., Zeilhofer, H.F. and Kalender, W.A.** Rapid prototyping technology in medicine—basics and applications. *Computerized Medical Imaging and Graphics*, 1999, **23**(5), 277-284.
- 4 **Sanghera, B., Naique, S., Papaharilaou, Y. and Amis, A.** Preliminary study of rapid prototype medical models. *Rapid Prototyping Journal*, 2001, **7**(5), 275-284.
- 5 **Friedman, T., Michalski, M., Goodman, T.R. and Brown, J.E.** 3D printing from diagnostic images: a radiologist's primer with an emphasis on musculoskeletal imaging—putting the 3D printing of pathology into the hands of every physician. *Skeletal Radiology*, 2015, **45**(3), 307-321.
- 6 **Chae, M.P., Rozen, W.M., McMenamin, P.G., Findlay, M.W., Spychal, R.T. and Hunter-Smith, D.J.** Emerging Applications of Bedside 3D Printing in Plastic Surgery. *Front Surg*, 2015, **2**, 25.
- 7 **Murray, D.J., Edwards, G., Mainprize, J.G. and Antonyshyn, O.** Advanced technology in the management of fibrous dysplasia. *Journal of Plastic, Reconstructive & Aesthetic Surgery*, 2008, **61**(8), 906-916.
- 8 **Stoodley, M.A., Abbott, J.R. and Simpson, D.A.** Titanium cranioplasty using 3-D computer modelling of skull defects. *Journal of Clinical Neuroscience*, 1996, **3**(2), 149-155.
- 9 **Bartlett, P., Carter, L.M. and Russell, J.L.** The Leeds method for titanium cranioplasty construction. *British Journal of Oral and Maxillofacial Surgery*, 2009, **47**(3), 238-240.
- 10 **Hughes, C.W., Page, K., Bibb, R., Taylor, J. and Revington, P.** The custom-made titanium orbital floor prosthesis in reconstruction for orbital floor fractures. *British Journal of Oral and Maxillofacial Surgery*, 2003, **41**(1), 50-53.
- 11 **Peel, S. and Eggbeer, D.** Additively manufactured maxillofacial implants & guides - achieving routine use *Rapid Prototyping Journal*, 2016, **22**(1), 189 - 199.
- 12 **Rohner, D., Guijarro-Martinez, R., Bucher, P. and Hammer, B.** Importance of patient-specific intraoperative guides in complex maxillofacial reconstruction. *Journal of Cranio-Maxillofacial Surgery*, 2013, **41**(5), 382-390.
- 13 **Gil, R.S., Roig, A.M., Obispo, C.A., Morla, A., Pagès, C.M. and Perez, J.L.** Surgical planning and microvascular reconstruction of the mandible with a fibular flap using computer-aided design, rapid prototype modelling, and precontoured titanium reconstruction plates: a prospective study. *British Journal of Oral and Maxillofacial Surgery*, 2015, **53**(1), 49-53.
- 14 **Olszewski, R., Tranduy, K. and Reychler, H.** Innovative procedure for computer-assisted genioplasty: three-dimensional cephalometry, rapid-prototyping model and surgical splint. *International Journal of Oral and Maxillofacial Surgery*, 2010, **39**(7), 721-724.
- 15 **Mertens, C., Lowenheim, H. and Hoffmann, J.** Image data based reconstruction of the midface using a patient-specific implant in combination with a vascularized osteomyocutaneous scapular flap. *J Craniomaxillofac Surg*, 2013, **41**(3), 219-225.
- 16 **Essig, H., Rana, M., Kokemueller, H., von See, C., Ruecker, M., Tavassol, F. and Gellrich, N.-C.** Pre-operative planning for mandibular reconstruction - A full digital planning workflow resulting in a patient specific reconstruction. *Head & Neck Oncology*, 2011, **3**(1), 1-7.
- 17 **Schepers, R.H., Raghoebar, G.M., Lahoda, L.U., Van der Meer, W.J., Roodenburg, J.L., Vissink, A., Reintsema, H. and Witjes, M.J.** Full 3D digital planning of implant supported bridges in secondarily mandibular reconstruction with prefabricated fibula free flaps. *Head & Neck Oncology*, 2012, **4**(2), 44-44.
- 18 **Li, B., Zhang, L., Sun, H., Yuan, J., Shen, S.G.F. and Wang, X.** A novel method of computer aided orthognathic surgery using individual CAD/CAM templates: a combination of osteotomy and repositioning guides. *British Journal of Oral and Maxillofacial Surgery*, 2013, **51**(8), e239-e244.
- 19 **Ciocca, L., Mazzoni, S., Fantini, M., Persiani, F., Marchetti, C. and Scotti, R.** CAD/CAM guided secondary mandibular reconstruction of a discontinuity defect after ablative cancer surgery. *Journal of Cranio-Maxillofacial Surgery*, 2012, **40**(8), e511-e515.
- 20 **Modabber, A., Legros, C., Rana, M., Gerressen, M., Riediger, D. and Ghassemi, A.** Evaluation of computer-assisted jaw reconstruction with free vascularized fibular flap compared to conventional surgery: A clinical pilot study. *International Journal of Medical Robotics and Computer Assisted Surgery*, 2012, **8**(2), 215-220.
- 21 **Abdel-Moniem Barakat, A., Abou-Elfetouh, A., Hakam, M.M., El-Hawary, H. and Abdel-Ghany, K.M.** Clinical and radiographic evaluation of a computer-generated guiding device in bilateral sagittal split osteotomies. *Journal of Cranio-Maxillofacial Surgery*, 2013(0).
- 22 **Guevara-Rojas, G., Figl, M., Schicho, K., Seemann, R., Traxler, H., Vacariu, A., Carbon, C.C., Ewers, R. and Watzinger, F.** Patient-specific polyetheretherketone facial implants in a computer-aided planning workflow. *J Oral Maxillofac Surg*, 2014, **72**(9), 1801-1812.

- 23 **Gerbino, G., Bianchi, F.A., Zavattoni, E., Tartara, F., Garbossa, D. and Ducati, A.** Single-step resection and reconstruction using patient-specific implants in the treatment of benign cranio-orbital tumors. *J Oral Maxillofac Surg*, 2013, **71**(11), 1969-1982.
- 24 **Bibb, R., Eggbeer, D., Bocca, A., Evans, P. and Sugar, A.** A Custom-fitting Surgical Guide. In Kau, C.H. and Richmond, S., eds. *Three-Dimensional Imaging for Orthodontics and Maxillofacial Surgery*, pp. 243-252 (Wiley-Blackwell, 2010).
- 25 **Vrielinck, L., Politis, C., Schepers, S., Pauwels, M. and Naert, I.** Image-based planning and clinical validation of zygoma and pterygoid implant placement in patients with severe bone atrophy using customized drill guides. Preliminary results from a prospective clinical follow-up study. *International Journal of Oral and Maxillofacial Surgery*, 2003, **32**(1), 7-14.
- 26 **Bibb, R., Eggbeer, D., Evans, P., Bocca, A. and Sugar, A.** Rapid manufacture of custom-fitting surgical guides. *Rapid Prototyping Journal*, 2009, **15**(5), 346-354.
- 27 **Ciocca, L., Fantini, M., De Crescenzo, F., Persiani, F. and Scotti, R.** Computer-aided design and manufacturing construction of a surgical template for craniofacial implant positioning to support a definitive nasal prosthesis. *Clinical Oral Implants Research*, 2011, **22**(8), 850-856.
- 28 **W. Joerd Van der Meer, A.V., Gerry M. Raghoebar, Anita Visser.** Digitally Designed Surgical Guides for Placing Extraoral Implants in the Mastoid Area *The International Journal of Oral & Maxillofacial Implants*, 2012, **27**(3), 703-707.
- 29 **Darwood, A., Collier, J., Joshi, N., Grant, W.E., Sauret-Jackson, V., Richards, R., Dawood, A. and Kirkpatrick, N.** Re-thinking 3D printing: A novel approach to guided facial contouring. *Journal of Cranio-Maxillofacial Surgery*, 2015.
- 30 **Levine, J.P., Bae, J.S., Soares, M., Brecht, L.E., Saadeh, P.B., Ceradini, D.J. and Hirsch, D.L.** Jaw in a day: total maxillofacial reconstruction using digital technology. *Plast Reconstr Surg*, 2013, **131**(6), 1386-1391.
- 31 **Aldekhayel, S., Aljaaly, H., Fouda-Neel, O., Shararah, A.W., Zaid, W.S. and Gilardino, M.** Evolving trends in the management of orbital floor fractures. *J Craniofac Surg*, 2014, **25**(1), 258-261.
- 32 **Bibb, R., Eggbeer, D. and Paterson, A.** *Medical Modelling: The Application of Advanced Design and Rapid Prototyping Techniques in Medicine*. (Woodhead Publishing, Cambridge, UK, 2015).
- 33 **Herlin, C., Koppe, M., Béziat, J.L. and Gleizal, A.** Rapid prototyping in craniofacial surgery: Using a positioning guide after zygomatic osteotomy – A case report. *Journal of Cranio-Maxillofacial Surgery*, 2011, **39**(5), 376-379.
- 34 **Lethaus, B., Bloebaum, M., Koper, D., Poort-Ter Laak, M. and Kessler, P.** Interval cranioplasty with patient-specific implants and autogenous bone grafts—success and cost analysis. *J Craniomaxillofac Surg*, 2014, **42**(8), 1948-1951.
- 35 **van der Meer, W.J., Bos, R.R.M., Vissink, A. and Visser, A.** Digital planning of cranial implants. *British Journal of Oral and Maxillofacial Surgery*, 2013(0).
- 36 **Jardini, A.L., Larosa, M.A., Filho, R.M., Zavaglia, C.A.d.C., Bernardes, L.F., Lambert, C.S., Calderoni, D.R. and Kharmandayan, P.** Cranial reconstruction: 3D biomodel and custom-built implant created using additive manufacturing. *Journal of Cranio-Maxillofacial Surgery*, 2014, **42**(8), 1877-1884.
- 37 **Eufinger, H., Wittkamp, A.R.M., Wehmöller, M. and Zonneveld, F.W.** Single-step fronto-orbital resection and reconstruction with individual resection template and corresponding titanium implant: a new method of computer-aided surgery. *Journal of Cranio-Maxillofacial Surgery*, 1998, **26**(6), 373-378.
- 38 **Eolchiyan, S.A.** [Complex skull defects reconstruction with capital ES, Cyrilliccapital A, CyrillicD/capital ES, Cyrilliccapital A, Cyrilliccapital EM, Cyrillic titanium and polyetheretherketone (PEEK) implants]. *Zh Vopr Neurokhir Im N N Burdenko*, 2014, **78**(4), 3-13.
- 39 **Rotaru, H., Schumacher, R., Kim, S.G. and Dinu, C.** Selective laser melted titanium implants: a new technique for the reconstruction of extensive zygomatic complex defects. *Maxillofac Plast Reconstr Surg*, 2015, **37**(1), 1.
- 40 **Rana, M., Gellrich, M.M. and Gellrich, N.C.** Customised reconstruction of the orbital wall and engineering of selective laser melting (SLM) core implants. *British Journal of Oral and Maxillofacial Surgery*, 2015, **53**(2), 208-209.
- 41 **Salmi, M., Tuomi, J., Paloheimo, K., Björkstrand, R., Paloheimo, M., Salo, J., Kontio, R., Mesimäki, K. and Mäkitie, A.** Patient-specific reconstruction with 3D modeling and DMLS additive manufacturing. *Rapid Prototyping Journal*, 2012, **18**(3), 209-214.
- 42 **Rana, M., Chui, C.H.K., Wagner, M., Zimmerer, R., Rana, M. and Gellrich, N.-C.** Increasing the Accuracy of Orbital Reconstruction With Selective Laser-Melted Patient-Specific Implants Combined With Intraoperative Navigation. *Journal of Oral and Maxillofacial Surgery*, 2015, **73**(6), 1113-1118.
- 43 **Lethaus, B., Poort ter Laak, M., Laeven, P., Beerens, M., Koper, D., Poukens, J. and Kessler, P.** A treatment algorithm for patients with large skull bone defects and first results. *Journal of Cranio-Maxillofacial Surgery*, 2011, **39**(6), 435-440.
- 44 **Alonso-Rodriguez, E., Cebrian, J.L., Nieto, M.J., Del Castillo, J.L., Hernandez-Godoy, J. and Burgueno, M.** Polyetheretherketone custom-made implants for craniofacial defects: Report of 14 cases and review of the literature. *J Craniomaxillofac Surg*, 2015.
- 45 **O'Reilly, E.B., Barnett, S., Madden, C., Welch, B., Mickey, B. and Rozen, S.** Computed-tomography modeled polyether ether ketone (PEEK) implants in revision cranioplasty. *Journal of Plastic, Reconstructive & Aesthetic Surgery*, 2015, **68**(3), 329-338.

- 46 **Scolozzi, P., Martinez, A. and Jaques, B.** Complex orbito-fronto-temporal reconstruction using computer-designed PEEK implant. *J Craniofac Surg*, 2007, **18**(1), 224-228.
- 47 **Kim, M.M., Boahene, K.D.O. and Byrne, P.J.** Use of customized polyetheretherketone (PEEK) implants in the reconstruction of complex maxillofacial defects. *Archives of Facial Plastic Surgery*, 2009, **11**(1), 53-57.
- 48 **Camarini, E.T., Tomeh, J.K., Dias, R.R. and da Silva, E.J.** Reconstruction of frontal bone using specific implant polyether-ether-ketone. *J Craniofac Surg*, 2011, **22**(6), 2205-2207.
- 49 **Marbacher, S., Andereggen, L., Fandino, J. and Lukes, A.** Combined bone and soft-tissue augmentation surgery in temporo-orbital contour reconstruction. *J Craniofac Surg*, 2011, **22**(1), 266-268.
- 50 **Goodson, M.L., Farr, D., Keith, D. and Banks, R.J.** Use of two-piece polyetheretherketone (PEEK) implants in orbitozygomatic reconstruction. *British Journal of Oral and Maxillofacial Surgery*, 2012, **50**(3), 268-269.
- 51 **Scolozzi, P.** Maxillofacial reconstruction using polyetheretherketone patient-specific implants by "mirroring" computational planning. *Aesthetic Plast Surg*, 2012, **36**(3), 660-665.
- 52 **Jalbert, F., Boetto, S., Nadon, F., Lauwers, F., Schmidt, E. and Lopez, R.** One-step primary reconstruction for complex craniofacial resection with PEEK custom-made implants. *J Craniomaxillofac Surg*, 2014, **42**(2), 141-148.
- 53 **Adetayo, O.A., Salcedo, S.E., Borad, V., Richards, S.S., Workman, A.D. and Ray, A.O.** Fibrous dysplasia: an overview of disease process, indications for surgical management, and a case report. *Eplasty*, 2015, **15**, e6.
- 54 **Thien, A., King, N.K., Ang, B.T., Wang, E. and Ng, I.** Comparison of polyetheretherketone and titanium cranioplasty after decompressive craniectomy. *World Neurosurg*, 2015, **83**(2), 176-180.
- 55 **Reddy, S., Khalifian, S., Flores, J.M., Bellamy, J., Manson, P.N., Rodriguez, E.D. and Dorafshar, A.H.** Clinical outcomes in cranioplasty: risk factors and choice of reconstructive material. *Plast Reconstr Surg*, 2014, **133**(4), 864-873.
- 56 **Yetiser, S., Gonul, E., Tosun, F., Tasar, M. and Hidir, Y.** Monostotic craniofacial fibrous dysplasia: the Turkish experience. *J Craniofac Surg*, 2006, **17**(1), 62-67.
- 57 **Lustig, L.R., Holliday, M.J., McCarthy, E.F. and Nager, G.T.** Fibrous dysplasia involving the skull base and temporal bone. *Archives of Otolaryngology-Head & Neck Surgery*, 2001, **127**(10), 1239-1247.
- 58 **Marosi, C., Hassler, M., Roessler, K., Reni, M., Sant, M., Mazza, E. and Vecht, C.** Meningioma. *Critical Reviews in Oncology/Hematology*, 2008, **67**(2), 153-171.
- 59 **Edwards, B.C.** Titanium Cranioplasty Implant Construction Using A Sectional Mould. *The Journal Of Maxillofacial Prosthetics and Technology*, 2007, **10**, 30-33.
- 60 **Thomas, C.V., McMillan, K.G., Jeynes, P., Martin, T. and Parmar, S.** Use of a titanium cutting guide to assist with raising and inset of a DCIA free flap. *British Journal of Oral and Maxillofacial Surgery*, 2013, **51**(8), 958-961.
- 61 **Kozakiewicz, M., Elgalal, M., Loba, P., Komuński, P., Arkuszewski, P., Broniarczyk-Loba, A. and Stefańczyk, L.** Clinical application of 3D pre-bent titanium implants for orbital floor fractures. *Journal of Cranio-Maxillofacial Surgery*, 2009, **37**(4), 229-234.
- 62 **D'Urso, P.S., Effeney, D.J., Earwaker, W.J., Barker, T.M., Redmond, M.J., Thompson, R.G. and Tomlinson, F.H.** Custom cranioplasty using stereolithography and acrylic. *British Journal of Plastic Surgery*, 2000, **53**(3), 200-204.
- 63 **Gelaude, F., Sloten, J.V. and Lauwers, B.** Automated Design and Production of Cranioplasty Plates: Outer Surface Methodology, Accuracies and a Direct Comparison to Manual Techniques. *Computer-Aided Design & Applications*, 2006, **3**(1-4), 193-202.
- 64 **Nickenig, H.-J., Wichmann, M., Hamel, J., Schlegel, K.A. and Eitner, S.** Evaluation of the difference in accuracy between implant placement by virtual planning data and surgical guide templates versus the conventional free-hand method – a combined in vivo – in vitro technique using cone-beam CT (Part II). *Journal of Cranio-Maxillofacial Surgery*, 2010, **38**(7), 488-493.
- 65 **Chrcanovic, B.R., Pedrosa, A.R. and Custódio, A.L.N.** Zygomatic implants: a critical review of the surgical techniques. *Oral and Maxillofacial Surgery*, 2012, **17**(1), 1-9.
- 66 **Suenaga, H., Taniguchi, A., Yonenaga, K., Hoshi, K. and Takato, T.** Computer-assisted preoperative simulation for positioning of plate fixation in LeFort I osteotomy: A case report. *Journal of the Formosan Medical Association*.
- 67 **Mustafa, S.F., Evans, P.L., Bocca, A., Patton, D.W., Sugar, A.W. and Baxter, P.W.** Customized titanium reconstruction of post-traumatic orbital wall defects: a review of 22 cases. *International Journal of Oral and Maxillofacial Surgery*, 2011, **40**(12), 1357-1362.
- 68 **Kozakiewicz, M., Elgalal, M., Piotr, L., Broniarczyk-Loba, A. and Stefancyk, L.** Treatment with individual orbital wall implants in humans – 1-Year ophthalmologic evaluation. *Journal of Cranio-Maxillofacial Surgery*, 2011, **39**(1), 30-36.
- 69 **Andrades, P., Hernandez, D., Falguera, M.I., Millan, J.M., Heredero, S., Gutierrez, R. and Sánchez-Aniceto, G.** Degrees of Tolerance in Post-Traumatic Orbital Volume Correction: The Role of Prefabricated Mesh. *Journal of Oral and Maxillofacial Surgery*, 2009, **67**(11), 2404-2411.
- 70 **Sugar, A.W., Kurlakose, M. and Walshaw, N.D.** Titanium mesh in orbital wall reconstruction. *International Journal of Oral and Maxillofacial Surgery*, 1992, **21**(3), 140-144.
- 71 **Eppley, B.L.** Alloplastic cranioplasty. *Operative Techniques in Plastic and Reconstructive Surgery*, 2003, **9**(1), 16-22.

- 72 **Moreira-Gonzalez, A., Jackson, I.T., Miyawaki, T., Barakat, K. and DiNick, V.** Clinical Outcome in Cranioplasty: Critical Review in Long-Term Follow-Up. *Journal of Craniofacial Surgery*, 2003, **14**(2), 144-153.
- 73 **Klammert, U., Gbureck, U., Vorndran, E., Rödiger, J., Meyer-Marcotty, P. and Kübler, A.C.** 3D powder printed calcium phosphate implants for reconstruction of cranial and maxillofacial defects. *Journal of Cranio-Maxillofacial Surgery*, 2010, **38**(8), 565-570.
- 74 **Lethaus, B., Safi, Y., ter Laak-Poort, M., Kloss-Brandstätter, A., Banki, F., Robbenmenke, C., Steinseifer, U. and Kessler, P.** Cranioplasty with customized titanium and PEEK implants in a mechanical stress model. *Journal of Neurotrauma*, 2012, **29**(6), 1077-1083.
- 75 **Li, J., Li, P., Lu, H., Shen, L., Tian, W., Long, J. and Tang, W.** Digital Design and Individually Fabricated Titanium Implants for the Reconstruction of Traumatic Zygomatico-Orbital Defects. *Journal of Craniofacial Surgery*, 2013, **24**(2), 363-368.
- 76 **Stieglitz, L., Fung, C., Murek, M., Fichtner, J., Raabe, A. and Beck, J.** What happens to the bone flap? Long-term outcome after reimplantation of cryoconserved bone flaps in a consecutive series of 92 patients. *Acta Neurochirurgica*, 2015, **157**(2), 275-280.
- 77 **Singare, S., Lian, Q., Wang, W.P., Wang, J., Liu, Y., Li, D. and Lu, B.** Rapid prototyping assisted surgery planning and custom implant design. *Rapid Prototyping Journal*, 2009, **15**(1), 19-23.
- 78 **Parthasarathy, J., Starly, B. and Raman, S.** A design for the additive manufacture of functionally graded porous structures with tailored mechanical properties for biomedical applications. *Journal of Manufacturing Processes*, 2011, **13**(2), 160-170.
- 79 **Palmquist, A., Snis, A., Emanuelsson, L., Browne, M. and Thomsen, P.** Long-term biocompatibility and osseointegration of electron beam melted, free-form-fabricated solid and porous titanium alloy: Experimental studies in sheep. *Journal of Biomaterials Applications*, 2011, **27**(8), 1003-1016.
- 80 **Gander, T., Essig, H., Metzler, P., Lindhorst, D., Dubois, L., Rucker, M. and Schumann, P.** Patient specific implants (PSI) in reconstruction of orbital floor and wall fractures. *J Craniomaxillofac Surg*, 2015, **43**(1), 126-130.
- 81 **Lübbers, H.-T., Jacobsen, C., Könü, D., Matthews, F., Grätz, K.W. and Obwegeser, J.A.** Surgical navigation in cranio-maxillofacial surgery: an evaluation on a child with a cranio-facio-orbital tumour. *British Journal of Oral and Maxillofacial Surgery*, 2011, **49**(7), 532-537.
- 82 **Shah, A.M., Jung, H. and Skirboll, S.** Materials used in cranioplasty: a history and analysis. *Neurosurgical Focus*, 2014, **36**(4), E19.
- 83 **Stoor, P., Suomalainen, A., Lindqvist, C., Mesimäki, K., Danielsson, D., Westermark, A. and Kontio, R.K.** Rapid prototyped patient specific implants for reconstruction of orbital wall defects. *J Craniomaxillofac Surg*, 2014, **42**(8), 1644-1649.
- 84 **Ko, A.L., Nerva, J.D., Chang, J.J. and Chesnut, R.M.** Traumatic fracture of a polymethyl methacrylate patient-specific cranioplasty implant. *World Neurosurg*, 2014, **82**(3-4), 536.e511-533.
- 85 **Watson, J., Hatamleh, M., Alwahadni, A. and Srinivasan, D.** Correction of facial and mandibular asymmetry using a computer aided design/computer aided manufacturing prefabricated titanium implant. *J Craniofac Surg*, 2014, **25**(3), 1099-1101.
- 86 **Mazzoni, S., Marchetti, C., Sgarzani, R., Cipriani, R., Scotti, R. and Ciocca, L.** Prosthetically guided maxillofacial surgery: Evaluation of the accuracy of a surgical guide and custom-made bone plate in oncology patients after mandibular reconstruction. *Plastic and Reconstructive Surgery*, 2013, **131**(6), 1376-1385.
- 87 **Foley, B.D., Thayer, W.P., Honeybrook, A., McKenna, S. and Press, S.** Mandibular Reconstruction Using Computer-Aided Design and Computer-Aided Manufacturing: An Analysis of Surgical Results. *Journal of Oral and Maxillofacial Surgery*, 2013, **71**(2), 111-119.
- 88 **Derand, P., Rannar, L.E. and Hirsch, J.M.** Imaging, virtual planning, design, and production of patient-specific implants and clinical validation in craniomaxillofacial surgery. *Cranio-Maxillofacial Trauma and Reconstruction*, 2012, **5**(3), 137-144.
- 89 **Gander, T., Bredell, M., Eliades, T., Rucker, M. and Essig, H.** Splintless orthognathic surgery: A novel technique using patient-specific implants (PSI). *Journal of Cranio-Maxillofacial Surgery*, 2015, **43**(3), 319-322.
- 90 **Lin, H.-H., Chang, H.-W. and Lo, L.-J.** Development of customized positioning guides using computer-aided design and manufacturing technology for orthognathic surgery. *International Journal of Computer Assisted Radiology and Surgery*, 2015, 1-13.
- 91 **Rudman, K., Hoekzema, C. and Rhee, J.** Computer-assisted innovations in craniofacial surgery. *Facial Plast Surg*, 2011, **27**(4), 358-365.
- 92 **Blake, G.B., MacFarlane, M.R. and Hinton, J.W.** Titanium in reconstructive surgery of the skull and face. *British Journal of Plastic Surgery*, 1990, **43**(5), 528-535.
- 93 **Acero, J., Calderon, J., Salmeron, J.I., Verdaguer, J.J., Concejo, C. and Somacarrera, M.L.** The behaviour of titanium as a biomaterial: microscopy study of plates and surrounding tissues in facial osteosynthesis. *J Craniomaxillofac Surg*, 1999, **27**(2), 117-123.
- 94 **Vandenbroucke, B. and Kruth, J.-P.** Selective laser melting of biocompatible metals for rapid manufacturing of medical parts. *Rapid Prototyping Journal*, 2007, **13**(4), 196-203.

- 95 Parthasarathy, J., Starly, B., Raman, S. and Christensen, A.** Mechanical evaluation of porous titanium (Ti6Al4V) structures with electron beam melting (EBM). *Journal of the Mechanical Behavior of Biomedical Materials*, 2010, **3**(3), 249-259.
- 96 Harrysson, O., Cansizoglu, O., Marcellin-Little, D.J., Cormier, D.R. and West li, H.A.** Direct metal fabrication of titanium implants with tailored materials and mechanical properties using electron beam melting technology. *Advanced Processing of Biomaterials Symposium, Materials Science and Technology Conference and Exhibition*, pp. 366-373 Cincinnati, Ohio, USA, 2008).
- 97 Harrysson, O., Cansizoglu, O. and Marcellin-Little, D.** Comparison of Direct Metal Fabrication Technologies for Production of Medical Implants. *RAPID 2009 CONFERENCE & EXPOSITION* (Society of Manufacturing Engineers, Schaumburg, IL, USA, 2009).
- 98 Winder, J. and Bibb, R.** Medical Rapid Prototyping Technologies: State of the Art and Current Limitations for Application in Oral and Maxillofacial Surgery. *Journal of Oral and Maxillofacial Surgery*, 2005, **63**(7), 1006-1015.
- 99 Manrique, O.J., Lalezaradeh, F., Dayan, E., Shin, J., Buchbinder, D. and Smith, M.** Craniofacial reconstruction using patient-specific implants polyether ether ketone with computer-assisted planning. *J Craniofac Surg*, 2015, **26**(3), 663-666.
- 100 Pritz, M.B. and Burgett, R.A.** Spheno-orbital Reconstruction after Meningioma Resection. *Skull Base*, 2009, **19**(2), 163-170.
- 101 Huotilainen, E., Jaanimets, R., Valášek, J., Marcián, P., Salmi, M., Tuomi, J., Mäkitie, A. and Wolff, J.** Inaccuracies in additive manufactured medical skull models caused by the DICOM to STL conversion process. *Journal of Cranio-Maxillofacial Surgery*, 2013(0).
- 102 Rosen, C.L., Sedney, C. and Sivak, J.** Single-stage complex reconstruction for fibrous dysplasia: a case report. *Skull Base*, 2008, **18**(4), 275-279.
- 103 Patel, A.J. and Duckworth, E.A.** Management of infections complicating the orbitocranial approaches: Report of two cases and review of literature. *Surg Neurol Int*, 2015, **6**, 89.
- 104 Sunderland, I.R., Edwards, G., Mainprize, J. and Antonyshyn, O.** A technique for intraoperative creation of patient-specific titanium mesh implants. *Plast Surg (Oakv)*, 2015, **23**(2), 95-99.
- 105 Eufinger, H., Rasche, C., Lehm Brock, J., Wehmöller, M., Weihe, S., Schmitz, I., Schiller, C. and Epple, M.** Performance of functionally graded implants of polylactides and calcium phosphate/calcium carbonate in an ovine model for computer assisted craniectomy and cranioplasty. *Biomaterials*, 2007, **28**(3), 475-485.
- 106 Pfaff, M.J. and Steinbacher, D.M.** Plastic Surgery Applications Using Three-Dimensional Planning and Computer-Assisted Design and Manufacturing. *Plast Reconstr Surg*, 2016, **137**(3), 603e-616e.