

Swiss clinical practice guidelines on field cancerization of the skin

Günther Hofbauer^a, Mark Anliker^b, Wolf-Henning Boehncke^c, Christoph Brand^d, Ralph Braun^a, Olivier Gaide^e, Jürg Hafner^a, Robert Hunger^f, Peter Itin^g, Gina Kaeuper^h, Stephan Lautenschlagerⁱ, Carlo Mainetti^j, Markus Streit^k

^a Dermatologische Klinik, UniversitätsSpital Zürich, Switzerland; ^b Klinik für Dermatologie/Allergologie, Kantonsspital St. Gallen, Switzerland; ^c Service de Dermatologie et Vénérologie, Hôpitaux Universitaires de Genève, Switzerland; ^d Dermatologische Abteilung, Kantonsspital Luzern, Switzerland; ^e Service de Dermatologie et Vénérologie, Centre Hospitalier Universitaire Vaudois, Lausanne, Switzerland; ^f Universitätsklinik für Dermatologie, Inselspital Bern, Switzerland; ^g Dermatologie, Universitätsspital Basel, Basel, Switzerland; ^h Knoxville, Tennessee, USA; ⁱ Dermatologisches Ambulatorium, Stadtspital Triemli, Zürich, Switzerland; ^j Dermatologia, Ospedale Regionale di Bellinzona e Valli, Bellinzona, Switzerland; ^k Dermatologie/Allergologie, Kantonsspital Aarau, Switzerland

Summary

Actinic keratosis (AK) affects millions of people worldwide, and its prevalence continues to increase. AK lesions are caused by chronic ultraviolet radiation exposure, and the presence of two or more AK lesions along with photodamage should raise the consideration of a diagnosis of field cancerization. Effective treatment of individual lesions as well as field cancerization is essential for good long-term outcomes.

The Swiss Registry of Actinic Keratosis Treatment (REAKT) Working Group has developed clinical practice guidelines for the treatment of field cancerization in patients who present with AK. These guidelines are intended to serve as a resource for physicians as to the most appropriate treatment and management of AK and field cancerization based on current evidence and the combined practical experience of the authors. Treatment of AK and field cancerization should be driven by consideration of relev-

ant patient, disease, and treatment factors, and appropriate treatment decisions will differ from patient to patient. Prevention measures and screening recommendations are discussed, and special considerations related to management of immunocompromised patients are provided.

Key words: *Actinic keratosis; field cancerization of the skin; non-melanoma skin cancer; management recommendations; clinical practice guidelines*

Introduction

Actinic keratoses (AKs) are caused by chronic ultraviolet (UV) radiation exposure. Two or more AKs on photodamaged skin signal field cancerization and an increased risk for invasive non-melanoma skin cancer (NMSC). Switzerland has one of the highest rates of NMSC in Europe. Treatment of AK is thus an important Swiss public health issue.

The Swiss Registry of Actinic Keratosis Treatment (REAKT) Working Group (referred to herein as the REAKT Working Group) was formed under a mandate of the Swiss Society for Dermatology and Venereology (SGDV). The REAKT Working Group determined that guidelines for the treatment of field cancerization in AK were needed, as existing guidelines have focused primarily on the treatment of discrete AK lesions. The REAKT group developed the clinical practice guidelines herein based on available data and a consensus of best practices in field treatment. Current and emerging therapies were considered in order to support optimum patient care now and as new options become available.

These guidelines present the consensus of the REAKT Working Group regarding the desired approach to field cancerization based on disease presentation and patient and treatment considerations. These recommendations are not intended to be followed rigidly, but to serve as a guide for clinical care. It must be noted that although field can-

Abbreviations

5-FU	5-fluorouracil
AK	actinic keratosis
ALA	5-aminolevulinic acid
AZA	azathioprine
BCC	basal cell carcinoma
CLL	chronic lymphocytic leukaemia
COX-2	cyclooxygenase-2
LSRs	local skin reactions
MAL	methyl aminolevulinate
MMF	mycophenolate
NMSC	non-melanoma skin cancer
OTR	organ transplant recipients
PDT	photodynamic therapy
REAKT	Swiss Registry of Actinic Keratosis Treatment
RCT	randomised controlled trial
SA	salicylic acid
SCC	squamous cell carcinoma
UV	ultraviolet
UVA	ultraviolet-A

cerization is associated with other forms of NMSC-including Bowen's disease, squamous cell carcinoma (SCC), and basal cell carcinoma (BCC)-these forms are outside the scope of these guidelines for detailed discussion of treatment modalities.

About these guidelines

Methodology

The Swiss Clinical Practice Guidelines on Field Cancerization of the Skin have been developed by an expert panel of Swiss dermatology-oncology physicians (members of the REAKT Working Group) to guide other dermatologists in their approach to care for patients who have clinically apparent photodamage, AK lesions, or field cancerization, or who are at risk for NMSC. Prof. Dr. Gunther Hofbauer was asked to initiate the creation of the guidelines by drafting an initial manuscript and treatment algorithm based on his knowledge of the general treatment consensus and practice approaches of the other members of the REAKT Working Group. All members of the REAKT Working Group reviewed the draft manuscript and treatment algorithm in the month of June 2013 and convened in Bern, Switzerland on 1 July 2013 to discuss and revise the guidelines. The guidelines and treatment algorithm were revised following the meeting and the group convened again in Bern, Switzerland in December 2013 to review and discuss the revised guidelines. Further revisions were made and the final version was approved on 9 March 2014.

Evidence basis

The REAKT Working Group considered all currently available treatments for AK in the development of the guidelines. The treatments specifically recommended within the guidelines are those that the REAKT Working Group members agreed have the most clinical experience, the best evidence to consider for treatment of AK, or are of high interest currently based on factors such as clinical trial data or mechanism of action. The recommendations for use of each treatment are evidence-based where possible, and are based on the quality of evidence as well as disease, patient, and treatment considerations.

The 2011 Oxford Centre for Evidence Based Medicine (OCEBM) Levels of Evidence (LOE) were used to characterise the strength of the efficacy evidence for field cancerization available for each treatment [1]. The OCEBM LOE are intended to help guide clinical decision-making. They do not provide definitive judgment of the quality of evidence, nor do they provide a recommendation for treatment. Clinical judgment must be applied when considering the LOE for an individual treatment in order to determine its appropriate use.

Disclaimers and cautions

These guidelines for treatment of field cancerization have been prepared for dermatologists who treat patients who have or are at risk for NMSC. The general principles that underlie the guidelines are applicable to dermatologists in many different regulatory environments. However, the treatment algorithm and guidance is provided to address

the specific needs of the Swiss dermatology oncologist and it is not our intent to provide specific recommendations that counter established practices in other countries.

In addition, these guidelines have been developed based on the consensus of the REAKT Working Group members as to the preferred treatment approaches based on evidence available as of the manuscript submission date. Caution should be exercised in interpreting our recommendations in the context of newer data, as advances in knowledge and expansion in treatment options may require reconsideration of these recommendations.

Finally, the intention behind the development of the Swiss Clinical Practice Guidelines on Field Cancerization of the Skin was to aid dermatology physicians in the decision-making process by highlighting significant considerations that should guide treatment and providing expert perspective on the evidence to date on the range of treatments available for AK and associated field cancerization. The guidelines and algorithm are not intended to replace a physician's best judgement on the most appropriate path for each individual patient. The REAKT Working Group members hope that these guidelines will support and strengthen reader decisions on appropriate patient care.

Actinic keratosis and field cancerization background

AKs are UV light-induced discrete intraepidermal lesions typically presenting as rough, scaly, keratotic macules, papules or plaques. AK is an indicator of cumulative UV exposure, and lesions typically appear on skin that has been subject to chronic exposure--the so-called "sun terraces" of the skin, including the face, chest, ear lobes, balding scalp, and backs of arms and hands. Patients may present with a single lesion, but the typical clinical presentation is multiple lesions across an area of sun-damaged skin. A seminal Australian study of more than 1,000 people over the age of 40 found an average of 7.7 lesions per person with AK [2]. AKs are now understood as part of a disease continuum initiated by UV radiation. Photodamage represents the earliest stage in the continuum, with the formation of AKs, and ultimately SCC, demonstrating increasing progression. Before invasive SCC develops, intraepithelial changes occur in the clinical forms of AK and Bowen's disease. While only the latter is traditionally called carcinoma in-situ due to its total loss of regular architecture of the epidermis, we believe that AK is part of the continuum of SCC development based on histological and molecular changes common to AK, Bowen's disease, and invasive SCC [3]. While we realise that not all of the community shares this strict parlance based solely on biological parameters, for clarity's sake we will address AK and Bowen's disease in this paper as SCC in situ.

Histologically, AK is characterised by atypia or dysplasia of the keratinocytes in the basal layer of the epidermis and with progression in epidermal layers above. Disordered maturation of the superficial layers results in alternating areas of parakeratosis and hyperkeratosis [4]. Several histological subtypes have been described, including lichenoid, hypertrophic, bowenoid, pagetoid, and pigmented [5,

6]. Histologically, AK and SCC are indistinguishable in the epidermis [3].

A significant advance leading to more effective treatment of AK is acceptance of field cancerization as an underlying condition driving disease pathology and progression. UV exposure is believed to generate field cancerization via several actions: multiple individual foci of cellular transformation, broad immunosuppression and reduced immunosurveillance, and additional mutations leading to the development of invasive tumours [7]. It is widely accepted that visible AK lesions (whether few or many) are a manifestation of pervasive damage and that the surrounding area (“field”) of sun-damaged skin contains subclinical lesions and cellular changes. Bowen’s disease, SCC, and BCC are also visible indicators of this damage. The presence of any of these NMSC lesions (to include AK) represents evidence of field cancerization.

The current focus of AK treatment is to target field cancerization, rather than limiting treatment to clinically apparent individual lesions. This approach may help delay or prevent the development of new lesions [8, 9], and is suggestive of a reduced future risk for SCC, although as yet there is little evidence demonstrating these beneficial outcomes. It may be helpful to envision this treatment approach as analogous to the use of hypertensive medication to prevent endpoint events such as stroke and myocardial infarction. Stroke and myocardial infarction are significant events that require immediate, focused medical attention, but treatment limited to the individual event does not adequately promote optimum long-term outcomes. The view of AK must similarly be broadened to understand that treatment of field cancerization should address underlying risk factors and may promote better long-term health outcomes and improved quality of life.

Epidemiology and risk factors

AKs occur more frequently in regions with higher UV exposure and in fair-skinned populations. A 2006 report from the World Health Organization noted a clear relationship between latitude and AK prevalence as well as the likelihood of multiple AKs at lower latitudes [10]. Prevalence rates of 40%–60% in adults in Australia and 11%–25% in various northern hemisphere populations have been reported [11]. Prevalence rates are greater in males than in females and increase with age [11].

The most notable risk factor for development of AK is accumulated chronic UV radiation exposure, whether through occupational or recreational means, and the person with AK typically presents with characteristic signs of photodamage, including freckles and solar lentigines. Recently published results from a multicentre study across eight European countries provides additional information about a number of risk factors [12]. Differences in risk were noted among hair and eye coloration: red hair conferred a seven times higher risk than black hair; brown eyes about a 40% reduced risk when compared to blue. The presence of even a few freckles on the face was found to confer greater risk. Outdoor occupation, history of sunburns as a child, and residency in a tropical country were all associated with increased risk, whereas higher education levels were as-

sociated with a significantly reduced risk. This study also noted potentially significant increased risks in patients taking photosensitising thiazide diuretics and cardiac drugs, and a possible protective effect from nonsteroidal anti-inflammatory drugs (NSAIDs).

Patients who are immunocompromised are at significant increased risk for development of NMSC, as are patients with genetic disorders such as xeroderma pigmentosum.

AK progression to SCC

Although not all AKs will progress to SCC – and, indeed, some AKs will regress – there is a clear relationship between AK and SCC. A review of the evidence supporting this relationship found that approximately 90% of SCCs may have contiguous AKs, consistent with the concept that AKs are pre-invasive forms of SCC [4]. One study found that up to 60% of SCCs arise directly from an AK [13]. Another study found that 136 of 165 cutaneous SCCs examined were closely associated with AKs; of these, 26.7% of the SCCs were found to have arisen directly from an existing AK lesion, and another 55.7% were in close proximity to an AK lesion [14].

The proportion of AK lesions that progress to invasive SCC is not conclusively known, with published progression estimates ranging widely from 0.075% to 16% or even more [2, 13, 15, 16]. A recent systematic review concluded that annual rates of progression of a single AK into SCC range from 0% to 0.53%, but cautioned that these remain uncertain estimates [17]. A large majority of lesions remain

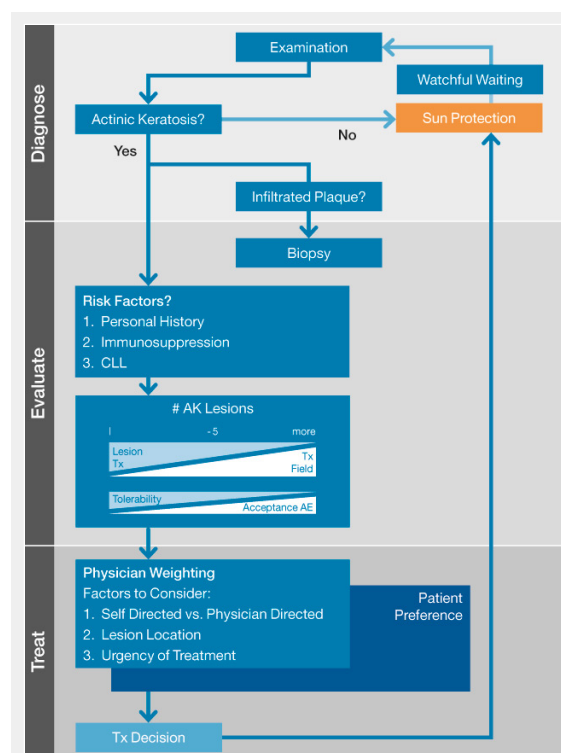


Figure 1

Actinic keratosis and field cancerization treatment algorithm
The algorithm is intended to aid in the treatment decision process for actinic keratosis and field cancerization and is not intended to replace a physician’s best judgement on the most appropriate treatment path for each individual patient.

stable and others will regress. The review found that annual rates of regression for single lesions ranged between 15% and 63%, with recurrence rates of 15%–53% [17]. At present, it is not possible to determine which AK lesions will progress to SCC, or regress, or when.

The uncertainty of the timing and likelihood of AK progression has stimulated much discussion regarding the best treatment approach to AK, with some advocating watchful waiting and others a more aggressive approach. It is the perspective of the REAKT Working Group that we must consider AK a serious precursor to more invasive disease and treat promptly. Switzerland has one of the highest skin cancer rates in Europe, with an incidence of around 15,000 new cases of NMSC each year and steadily rising [18]. Improved treatment approaches to AK as well as comprehensive public education efforts are needed to help slow the rising incidence and improve long-term outcomes for our population. Rigorous NMSC prevention efforts, both individually and community-wide, may have financial benefits. A German study of hospitalisation costs associated with melanoma and NMSC skin cancers found that while NMSC mortality is low, annual hospitalisation costs related to NMSC are approximately 100% greater than with melanoma skin cancer, representing a significant public health burden that is perhaps not well understood when viewed solely in the context of death rates [19]. The treatment algorithm presented with these guidelines will present the REAKT Working Group's recommendations on appropriate treatment path based on patient presentation and risk factors, balancing health, fiscal, and quality-of-life concerns (fig. 1).

Prevention

As stated, chronic UV radiation exposure is understood to play an essential role in the development of AK and other forms of NMSC. Childhood and adolescence are pivotal periods for prevention efforts, which should focus on reducing overall exposure (minimising the incidence of childhood sunburn) and helping to establish life-long self-care habits. Steadily increasing rates of NMSC highlight the need for primary prevention measures starting in childhood to reduce overall population-based risk for AK and NMSC. Prevention measures focus on limiting UVA (ultraviolet-A) photodamage through avoidance of unnecessary exposure to UV light (including artificial sources) and the use of sunscreen when exposure is unavoidable. A study of the sun protection knowledge and behaviours of 887 children and adolescents (ages ranging from 8–17 years) in North-west Switzerland revealed that, despite wide ranging skin cancer education and prevention campaigns, an opportunity remains to improve child and adolescent knowledge and behaviour in this regard [20]. The study authors identified needs for continued education about the potential long-term effects of excessive sun exposure, proper sunscreen application, and the effectiveness of clothing and shade as protective measures. They also noted the need for continued efforts on changing societal values related to tanned skin.

In adult patients, including those who have a history of AKs or other NMSC, randomised clinical trials have

demonstrated that the use of sunscreen reduces the incidence of AKs and SCC. A randomised, controlled trial spanning 4.5 years demonstrated reduction in SCC (but not BCC) through the regular use of sunscreen [21]. An eight year follow-up study evaluated the long-term effects of sunscreen application during the trial [22]. SCC rates were significantly reduced by almost 40% during the entire follow-up period. Most of this effect was attributed to latency of effect of sunscreen intervention during the trial. However, the study authors also noted that the intervention group continued to use sunscreen at a higher rate than the control group after the initial trial. A 2009 analysis in Australia found that regular sunscreen use was a cost-effective approach to skin cancer prevention, saving almost US \$90,000 in total healthcare costs over a 5 year period for approximately 800 patients studied [23].

High-risk populations may also benefit from sunscreen use. Ulrich and colleagues studied the protective effects of regular sunscreen use on the development of NMSC in organ transplant recipients (OTR) [24]. At the conclusion of a 24 month study, the intent-to-treat sunscreen group had notably more favourable outcomes, with reduction in lesion count from baseline and fewer lesions overall than the control group.

Judicious use of systemic chemoprevention strategies may also be of benefit in very high-risk patients. Evidence suggests that the use of acitretin may have some benefit [25]. Two small, open-label studies demonstrated some protective benefits of oral capecitabine in OTR [26, 27]. Studies are currently underway to evaluate the efficacy of afamelanotide, a first-in-class photoprotective drug, for use as a photoprotective agent for OTR patients.

Actinic keratosis and field cancerization management

Table 1 outlines the REAKT Working Group's recommendations for screening and management of AK and field cancerization based on patient and disease factors. Absent specific risk factors, we recommend encouraging patients to perform skin self-examination every 3 months, with clinical examination if new lesions are noted. Certain risk factors require more frequent self and clinical exams, as noted in the table. In any patient type, suspicious lesions necessitate timely professional inspection.

Professional screening for AK and field cancerization offers several important benefits. It enables the patient and physician to establish a baseline (at first screening) or note changes to the patient's skin since the last visit, thereby potentially promoting earlier identification of new or changing lesions. It also offers the opportunity to evaluate for other skin cancers, such as melanoma. Skin examinations should be comprehensive, including areas such as the scalp, palms, oral cavity, and genitalia. For patients at high risk for invasive skin cancer (e.g., those with history of melanoma or who have large lesions) it is recommended that the examination include palpation of the lymph nodes. Clinician visits also offer the opportunity to introduce or reinforce prevention and self-care habits, whether through consultation or the provision of written materials. Patients are the ultimate drivers of their care; however, they are typ-

ically noncompliant with screening recommendations, and continued education is needed to emphasise the importance of regular at-home self-examination as well as clinical examination of new lesions. Patient education on the importance of screening and the types of changes that need to be watched versus the changes that require immediate professional evaluation is key to a successful management programme. As part of this education, patients should be trained on how to effectively perform skin self-examination.

Patients with chronic lymphocytic leukaemia (CLL) as well as OTR and other patients on long-term immunosuppression require special consideration for screening. These patients should be treated as at high risk for invasive NMSC. Annual clinical exams by a dermatology specialist and monthly skin self-examinations are encouraged for these patients; OTR should be screened by a dermatologist for NMSC prior to transplantation [28]. The extent and, particularly, the invasiveness of skin lesions can be clinically underestimated in OTR and patients with CLL, and lesions in these patients should be viewed with a high degree of clinical suspicion.

Clinical assessment/diagnosis

AK lesions are typically clinically diagnosed. AK has varied presentations, but broadly presents as a scaly, ill-defined macule, papule, or plaque, commonly flesh-coloured, pink or reddish-brown. A classic feature of many AKs is a rough “sandpaper” feel that is as important to diagnosis as visual inspection. AK lesions may be solitary, but more commonly present as multiple lesions in a photodamaged field. Clinical variants of AK have specific distinct characteristics that must be noted for differential diagnosis. Firm, raised lesions are at greater risk for invasive carcinoma and should be biopsied.

Dermoscopy is very effective in helping to diagnose AK. A prospective study of 178 patients compared diagnostic results obtained with dermoscopy to histopathological findings [29]. Independent blinded comparison of the results obtained through both methods resulted in a concordance

of 0.917. The sensitivity of dermoscopy for the diagnosis of AK was 98.7%, with a specificity of 95.0%. The value of dermoscopy as a diagnostic tool is reliant on the expertise of the physician, and recognition of the dermatoscopic characteristics of AK lesions is necessary for accurate diagnosis. A red pseudo-network is a widely cited characteristic dermatoscopic finding of AK and is significantly associated with AK [30, 31]. Other features include a pattern of linear wavy vessels in facial non-pigmented lesions and multiple gray or brown dots and globules around the follicular ostia in pigmented lesions [30]. Dermoscopy is increasingly used to evaluate the outcomes of NMSC treatment, and should be viewed as a helpful management tool beyond the initial diagnosis.

Field cancerization should be considered when multiple lesions of epithelial skin cancer (including in situ SCC such as AK and Bowen’s disease or invasive tumours such as SCC and BCC) occur. Moreover, chronic sun damage defined by the presence of one or more clinical signs such as skin atrophy, inhomogeneous pigmentation, dermatochalasis, Purpura senilis Bateman, or Pseudocicatrices stellaires should be assessed. Once two or more lesions of AK, Bowen’s disease, invasive SCC, or BCC with accompanying photodamaged skin have been diagnosed in a single patient, a diagnosis of field cancerization is warranted.

Treatment considerations

Although at this time it is not possible to predict which AKs will progress to invasive SCC, early diagnosis and treatment is believed to be key for minimising disease progression and severity. It is the REAKT Working Group’s recommendation that each patient with AK receive treatment that addresses both visible lesions as well as the subclinical damage across the broader field. Although not yet well documented, we believe that timely and effective treatment of field cancerization has the potential to improve long-term health prognosis, may reduce the economic burden associated with treatment of more progressive disease, and may maximise cosmetic outcomes by reducing

Table 1: Management recommendations for actinic keratosis and field cancerization.

Patient presentation	Recommended management	Suggested timing	Additional information
Photodamage; no other risk factors	Clinical skin examination	If new lesions occur	
	Patient-directed self-examination	Every 3 months	
Fewer than five lesions; no other risk factors	Clinical skin examination	Every 12 months	
	Patient-directed self-examination	Every 3 months	
Recurrent lesions and recalcitrant lesions	Clinical skin examination	Every 3, 6, and 12 months following treatment At least every 6 months thereafter	Recalcitrant lesion requires biopsy by dermatologist
	Patient-directed self-examination	Every 3 months	
History of skin cancer	Clinical skin examination	Every 3, 6, and 12 months following treatment At least every 12 months thereafter	Lymph node exam by dermatology specialist in high-risk patients
	Patient-directed self-examination	Every 3 months	
CLL/OTR	Clinical skin examination by dermatology specialist	For CLL: Every 12 months For OTR: One screening exam pretransplantation Clinical exam at least every 12 months following transplantation	Invasiveness of skin lesions can be clinically underestimated in CLL/OTR.
	Patient-directed self-examination	Every month	

the need for more invasive treatments associated with more invasive skin cancers [8, 9].

Based on the patient's presentation and risk characteristics, the treatment strategy may differ (table 2). Treatment success is dependent on selecting an appropriate therapy within the context of a range of influencing disease, treatment, and patient-specific factors. Treatment decisions must ultimately balance efficacy, tolerability, and usage considerations. Regardless of the treatment path selected, the goals of AK treatment remain fundamentally the same: to clinically and histologically cure the lesions, minimise pain and adverse events, and reduce recurrence. When working toward these goals, clinical trial and other study data must be considered within the context of "real world" practice. Measures of efficacy in clinical trials include complete clearance, reduction in lesion count, and sustained clearance rates [32]. Most studies rely exclusively on a clinical count of AKs; counts conducted even by experienced dermatologists show marked heterogeneity [33]. Perhaps the most significant measure of efficacy is sustained clearance of the total treatment field. Sustained field clearance enables longer disease-free windows for patients, enhancing quality of life and possibly reducing overall treatment burden.

Treatment decisions must also be weighed against tolerability data and the burden presented by the treatment regimen in the context of the patient's disease considerations. For example, in a patient with no known risk factors and a single clinical lesion the treatment path may appropriately be quite different from that of the patient with many visible lesions in a damaged field and a history of prior NMSC. Lesion location is an important factor, as lesions located in difficult-to-treat areas (e.g., the back) may prove too burdensome for patient-directed home-based treatment. The treatment algorithm we provide herein as a guide to treatment decisions provides different general paths dependent on the patient's disease severity and unique risk profile. Ultimately, your professional judgement of what is best for your patient should drive your final decision.

Specific considerations related to the patient's lifestyle, competence, and attitude toward treatment should significantly influence the treatment decision, as they are all important contributors to the patient's adherence behaviours. Patient nonadherence to therapy is a pervasive problem in healthcare and is a complex issue influenced by many social, economic, disease, patient, and treatment factors [34].

Because treatment adherence is the foundation of good outcomes, it is essential to anticipate common factors associated with poor adherence and effectively work to overcome patient barriers. Some barriers to treatment adherence are somewhat easier to overcome by choosing therapeutic regimens that are less complex or those that better reflect patient preferences for administration or vehicle, as appropriate. Other barriers are more difficult, such as sustained commitment required for certain treatment plans. A treatment path must be selected that considers the patient's ability and willingness to adhere to therapy, and in some circumstances these factors will outweigh the other considerations in favour of a particular therapy. For example, certain treatments are physician directed by design and may be appropriate choices for patients that you believe may be less adherent to therapy because of such issues as health, lesion location, or willingness to adhere to long-term therapeutic regimens. Topical therapies are typically patient driven and thus may be more convenient for patients who are able to manage their own treatment. However, many topical therapies require longer-term treatment administration of several weeks or more, which raises the possibility of poor adherence attributable to treatment fatigue and dissatisfaction due to side effects.

Treatment options

Treatment approaches to AK can be broadly divided into lesion-directed or field-directed. Lesion-directed therapies work by physically destroying individual clinically apparent lesions and are best reserved for use in patients who have only a few isolated lesions and no elevated risk for development of invasive NMSC. Field-directed therapies target both clinically visible lesions as well as preclinical lesions and other changes in keratinocytes in the skin surrounding the visible lesion. Because AK is a visible marker of more extensive damage caused by chronic UV radiation exposure, the REAKT Working Group recommends field-directed therapy as the optimal treatment approach for most patients.

As discussed in more detail below, each treatment option has a unique profile. We do encourage the use of treatments that have shown greater efficacy in treating field cancerization; however, it is not the intention of the REAKT Working Group to preferentially promote the use of one modality or product over another, except within the context of spe-

Table 2: Factors that influence treatment decisions for actinic keratosis and field cancerization.

<i>Disease-specific factors</i>
Progression/development of disease
Number of lesions
Localisation and severity of disease
Location of lesions
Recurrence
<i>Patient-specific factors</i>
Age
Mental condition
Ability and willingness to adhere to therapy
History of skin cancer
Risk factors, especially immunosuppression

cific patient or disease factors. It should be noted that we considered the body of evidence available for each treatment when assessing the treatment's efficacy and when making recommendations for each treatment's best use. Clinical characteristics of AKs vary from study to study and the reader should be aware that efficacy rates are not comparable in a head-to-head manner because of differences in disease presentation, patient characteristics, and study design, among other factors. Despite these inherent limitations, the body of evidence does allow us to conclude that there are a number of safe and effective treatment approaches, and efficacy rates among various treatments largely overlap [36]. Each physician should select the ap-

proach that works best for each patient's needs. Fig. 1 presents a visual guide designed to assist physicians with the important decision points inherent to determining the best treatment approach for each individual patient.

Sunscreen

Several studies have demonstrated benefit with regular sunscreen use for prevention of new AK lesions and mitigation of field cancerization progression to SCC and other invasive skin cancers [21, 24, 37, 38]. One randomised, placebo-controlled study (n = 588) in Australia also examined AK lesion remission rates from daily sunscreen use [38]. In this study, the group using sunblock (broad spectrum, SPF 17) had more lesion remissions than in the control group (OR = 1.53; 95% CI, 1.29–1.80). The authors noted a clear dose-response relationship that applied to both the formation of new lesions and remission of existing lesions.

It is clear that sunscreen use offers some benefit to patients with field cancerization, probably by removing the tumour promotion via UV light. Because of this benefit and low barriers to sunscreen's use, we recommend that all patients presenting with field cancerization be encouraged to use sunscreen frequently (daily is recommended). Education is recommended to ensure that patients use an appropriate dose; under-dosing is a common mistake.

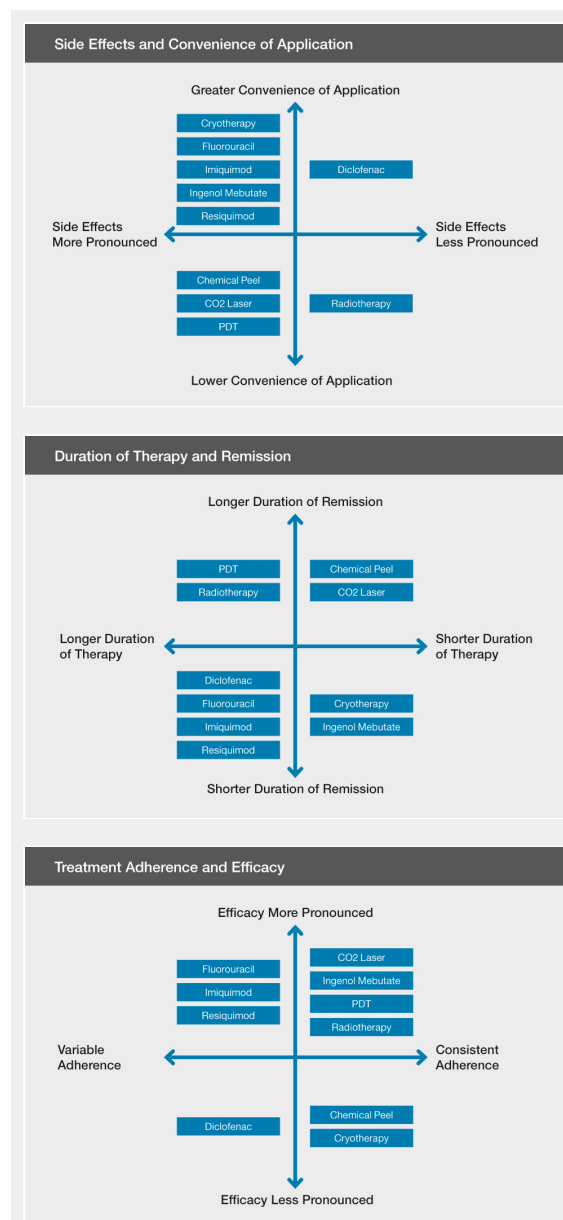
Curettage

Curettage is not a first-line therapy for treatment of AKs; however, some clinicians still advocate its use, as it is a quick and effective method for clearing visible, discrete lesions. The treatment requires local anaesthesia and is best reserved for treating a small number of AKs and/or thick, hyperkeratotic lesions. Curettage is commonly followed by electrodesiccation to destroy any remaining abnormal tissue and to reduce bleeding. Any potential benefits of curettage must be balanced against common adverse outcomes, including infection, scarring, and pigmentary changes. Curettage has no benefit in treating subclinical lesions or the broader damaged field.

Cryotherapy

Cryotherapy is the most widely used nonsurgical technique for treatment of a broad range of skin cancers and remains the most common treatment for AKs [39]. It is procedurally simple, widely available in both specialist and generalist offices, and is a quick and effective approach to clinically apparent lesions. Despite its popularity as a treatment, few studies have attempted to determine the true efficacy of cryotherapy in practice, and there is no standardised approach to frequency, duration, intensity, or temperature of cryotherapy. This leads to a variety of physician-specific approaches with resulting differences in outcomes.

A prospective, multicentre study of 90 patients in Australia recruited expert physicians and allowed them to treat each patient using the freeze time they felt was appropriate and adequate based on their clinical experience [40]. Results from this study revealed a broad range of freeze times (from 2 s to 1 min 30 s) and complete response rates (on the face and scalp) from 39% for treatment durations shorter than 5 seconds to 83% for treatments in excess of 20



Figures 2A, 2B, 2C:

Summary of treatment-related considerations for actinic keratosis and field cancerization

Treatments have been assessed according to the subjective opinions of the authors based on their collective practical experiences and not necessarily supported by objective data. Treatments are listed in alphabetical order. It is not the intention of the REAKT Working Group to preferentially promote the use of one modality or product over another.

seconds. The study authors noted that the cure rates obtained by these expert physicians were as a whole much lower than previously reported cure rates with cryotherapy. In general, higher efficacy rates were linked to longer freeze times; longer freeze times, in turn, were associated with higher incidence of undesirable adverse effects. Cosmetic response was rated “good” or “excellent” in 94% of the patients who had a 100% response rate at 3 months following treatment. Hypopigmentation was noted in 29% of the complete response lesions.

In a study of the comparative safety and efficacy of methyl aminolevulinate (MAL)-photodynamic therapy (PDT) versus cryotherapy as treatment of AKs on the extremities of 121 patients, the complete response rate for cryotherapy at 24 weeks was 88% [41]. The cosmetic outcome was assessed as “excellent” in 56% of patients who received cryotherapy. A randomised comparative study of imiquimod 5%, 5-fluorouracil (5-FU), and cryotherapy for treatment of AKs in 75 patients documented initial and 12 month clearance rates for each therapy [42]. Cryotherapy was associated with a 68% initial clearance rate, a 32% histological clearance rate, and 12 month sustained clearance rate for initially cleared lesions of 28%. This study also measured sustained clearance across the total treatment field; the sustained field clearance rate for cryotherapy was 4%.

A recent meta-analysis of complete clearance rates associated with eight common interventions for AK (including common topical treatments and PDT) found that the efficacy outcomes from cryotherapy were superior only to diclofenac and placebo [43]. The authors did note that the analysis may have tended to favour field-directed treatments over those that were lesion-directed.

Pain, redness, oedema and blistering are common side effects of treatment with cryotherapy. In addition, significant local adverse events, such as hyper- or hypopigmentation, scarring, and hair loss have been observed [40, 44].

Cryopeeling (diffuse cryotherapy) has been suggested as a possible approach for treating individual AKs as well as the broader damaged field [45]. Evidence for this treatment is limited, and no standardisation in approach or methods exists. More effective and well-tested options are available.

5-Fluorouracil

Topical 5-FU has a long history in dermatology and has been extensively used as treatment for AK. The drug interferes with deoxyribonucleic (DNA) and ribonucleic (RNA) synthesis in rapidly dividing cells, preventing cell proliferation and resulting in cell death. Clinical study of 5-FU has reported field clearance rates of 42% to 96%, with recurrence rates up to 55% [42, 46, 47].

5-FU is associated with an almost 100% incidence of local skin reactions. Currently, a 5% formulation of fluorouracil is available in Switzerland for treatment of senile and actinic keratosis, requiring application once or twice daily for 3–4 weeks, or longer in some cases. A 0.5% fluorouracil formulation, not yet available in Switzerland, has demonstrated similar efficacy rates as the 5% formulation, but appears to cause less severe adverse events and is associated with improved patient satisfaction [47–49]. A recent meta-analysis of complete clearance rates ranked both the 5% and 0.5% formulations of 5-FU as superior to the oth-

er interventions evaluated, including common topical treatments, PDT and cryotherapy [43]. These results should be interpreted with caution as the definition of the efficacy outcome “complete clearance” varied between the studies included in the analysis.

A combination product of 5-FU 0.5% plus salicylic acid (SA) 10% solution is approved in Switzerland for once-daily application, with clinical trial data available for experiences over 12 weeks of therapy. A randomised multicentre study compared the combination product to the study drug vehicle and diclofenac 3% [50]. Patients treated with the combination 5-FU + SA demonstrated significantly greater histological clearance (72%) and complete clearance (55.4%) rates at 20 weeks than either the vehicle or diclofenac. Application-site reactions were more common with the 5-FU + SA product, but were mostly mild to moderate.

Diclofenac

Diclofenac sodium 3% gel in a hyaluronic acid vehicle is approved in Switzerland for treatment of AK with a twice-daily administration for 60–90 days. Diclofenac is a nonsteroidal anti-inflammatory cyclooxygenase-2 (COX-2) inhibitor. Activation of COX-2 has been implicated in UV-induced skin cancers; inhibition of the COX-2 pathway has been shown to significantly reduce UV-induced tumorigenesis [51]. Diclofenac sodium 3% gel in hyaluronic acid also induces apoptosis, which is believed to play an important role in its effectiveness as an AK treatment [52].

Phase 3 studies of topical treatment with diclofenac demonstrated complete clearance rates of 33% following 60 days of treatment [53] and 50% following 90 days of treatment (clearance was assessed 30 days post-treatment in both studies) [54]. A 2005 meta-analysis of three randomised trials reported an overall complete clearance rate of 40% (364 patients) [55]. A phase 4 open-label study of diclofenac in patients with five or more AK lesions demonstrated similar results, with 41% complete clearance at day 90 of treatment and 58% at the 30-day follow-up visit [56]. A 12 month extension from this study demonstrated 79% complete clearance of target lesions and 30% for cumulative lesions approximately 1 year post-treatment [57]. Diclofenac is typically associated with mild-to-moderate application-site reactions.

The results of one case series [58] and a randomised controlled trial [59] suggest that diclofenac sodium 3% gel is effective and well tolerated as a treatment of AKs in OTR. The complete clearance rate in the randomised controlled trial was 41% and overall lesion counts decreased; importantly in this high-risk patient group, there were no cases of invasive SCC or aggressive AK in the 24 month follow-up period [59].

Imiquimod

Imiquimod is an immune-response modifier that is well studied for treatment of AK. It is approved in Switzerland for treatment of clinically typical, nonhyperkeratotic, nonhypertrophic AKs on the face or scalp. The approved course of therapy is 3 times per week for 16 weeks. Complete clearance rates from clinical trials of this protocol range from 48.3% to 57.1% [60, 61]. Long-term follow-up

data from four phase 3 clinical trials in the US and Canada revealed that 24.7% of patients who applied imiquimod three times weekly had a recurrence of AK in the original treatment area after a median follow-up period of 16 months [62].

Several studies have evaluated the safety and efficacy of a 4 week treatment protocol. In one vehicle-controlled, randomised, double-blind study, complete clearance rates were 26.8% after the first cycle (4 weeks) and 53.7% overall following a second cycle in patients with lesions remaining after the first cycle [63]. The 12-month sustained clearance rate was 61%. Another study showed similar results with an overall complete clearance rate of 55% [64].

Topical imiquimod causes local skin reactions (LSRs), including severe erythema, scabbing, and ulceration. In addition, it has been associated with fairly significant adverse events, including rare reports that in some patients its use caused flares of previously controlled auto-immune diseases [65–68]. Despite these potential side effects, imiquimod is typically well tolerated.

In 2012, a 3.75% imiquimod formulation was approved in Europe. Clinical trial data demonstrates high clearance rates and potentially improved patient tolerance with the lower concentration. Imiquimod was tested in two concentrations – 2.5% and 3.75% – applied daily to the full face or scalp in a 2/2/2 protocol (treatment daily for 2 weeks, followed by 2 weeks without treatment, and then another 2 weeks with daily treatment) [69]. The complete clearance rate associated with imiquimod 3.75% 2/2/2 administration was 35.6% and the partial clearance rate was 59.4% [69]. Two additional placebo-controlled trials evaluated a 3/3/3 regimen (treatment daily for 3 weeks, followed by 3 weeks without treatment, and then another 3 weeks with daily treatment) with imiquimod 2.5% and 3.75%, with similar results [70]. Although most subjects experienced LSRs (up to 55% of which were considered severe in the 3/3/3 protocol group), patient adherence rates exceeded 90% in the trials [69, 70].

Resiquimod (emerging therapy)

Resiquimod is an investigational toll-like receptor 7 and 8 antagonist currently in phase 3 trials in Switzerland for treatment of AK. Resiquimod's immunomodulatory effects are comparable to imiquimod, but it has greater potency in inducing cytokine expression [71, 72]. A phase 2 dose-ranging study evaluated the safety and efficacy of four different concentrations of resiquimod gel (0.01%, 0.03%, 0.06%, and 0.1%), applied once daily three times per week for four weeks [73]. Studied patients had 4 to 8 AK lesions on the face or balding scalp. Complete clearance rates after one course of treatment ranged from 40% (0.01% concentration) to 74.2% (0.03% concentration). After an eight week treatment-free interval, patients with remaining lesions received a second course of treatment. Overall complete clearance rates ranged from 77.1% (0.01% concentration) to 90.3% (0.03% concentration). The most common adverse events were application-site reactions. In the dose-ranging study higher concentrations were associated with a greater incidence of adverse events and more severe adverse events. The lower concentrations (0.01% and 0.03%) were better tolerated.

Ingenol mebutate

Ingenol mebutate is the most recent entry to the AK treatment armamentarium. It has been available for use in the US and European Union since 2012, and was approved in Switzerland in June 2013 for treatment of nonhyperkeratotic, nonhypertrophic AKs. Ingenol mebutate is a novel drug that appears to have two distinct and complementary mechanisms of action: initial rapid lesion necrosis within hours of application followed by specific neutrophil-mediated, antibody-dependent cellular cytotoxicity within days [74].

Ingenol mebutate gel is available in two strengths: 150 mcg/g, administered once daily for 3 consecutive days to the face and/or scalp; 500 mcg/g, administered once daily for 2 consecutive days to the trunk and/or extremities. A pooled analysis of 2 phase 3 studies of ingenol mebutate 150 mcg/g for the face/scalp indicated that ingenol mebutate is significantly more effective than placebo, with a complete clearance rate of 42.2% versus 3.7% for placebo ($p < 0.001$) [35]. A pooled analysis of 2 additional phase 3 studies of the 500 mcg/g concentration for the trunk/extremities revealed similar efficacy, with a complete clearance rate of 34.1% with ingenol mebutate versus 4.7% with placebo ($p < 0.001$) [35].

LSRs were the most common adverse events in the phase 3 studies [35]. For the 150 mcg/g concentration, LSRs peaked at day 4 following treatment initiation, rapidly decreased by day 8, and then continued to decrease until returning to baseline around day 29. For the 500 mcg/g concentration, LSRs peaked between days 3 and 8, and then followed a similar pattern as with the 150 mcg/g concentration, returning to baseline by about day 29. Fewer than 2% of subjects who received ingenol mebutate experienced more serious adverse events. More than 98% of patients in the 4 trials completed the treatment protocol, thus showing adherence rates similar to those expected with physician-directed treatments [35].

A total of 171 patients who had achieved complete clearance by day 57 in the ingenol mebutate phase 3 trials completed a 12 month observational follow-up study [75]. The patients were seen at 3, 6, 9, and 12 months following their day-57 visit from their original study. During each visit the target treatment area was evaluated for presence of AK lesions, and total lesions were counted. The primary endpoint was recurrence of AK in the target treatment area, with an additional endpoint of the percentage reduction in total AK lesions from the patient's original baseline in their original study. At 12 months, there was a 46% sustained clearance rate (face and scalp lesions) and an 87% reduction in the number of AK lesions compared to baseline.

A pharmacokinetic study investigated the potential for systemic absorption of ingenol mebutate and two of its metabolites following topical administration of ingenol mebutate gel [76]. Approximately 1 gram of ingenol mebutate gel 0.05% was applied once daily for two consecutive days to a contiguous 100 cm² treatment area on the dorsal forearm of 13 patients; 3 patients received vehicle gel in identical administration. All patients had multiple AK lesions in the treated area. Whole blood samples were taken pre-dose on days 1 and 2, and 7 additional samples were taken in the 24 hours following the day-2 dose. No system-

ic exposure of ingenol mebutate or its metabolites was detected in any sample (lower limit of quantification = 0.1 ng/mL).

Photodynamic therapy

PDT involves the irradiation of AK lesions with light to cause cell death. Prior to light exposure, a photosensitising agent is applied; neoplastic cells accumulate more of the agent than normal cells and are thus subject to greater thermal and chemical effects. The most frequently used photosensitising agents are 5-aminolevulinic acid (ALA) and its methyl ester MAL. MAL-PDT is approved in Switzerland for treatment of thin or nonhyperkeratotic AKs on the face or scalp. ALA-PDT is approved for treatment of mild AKs with a maximum diameter of 1.8 cm on the face and hairless regions of the scalp. In addition to topical creams, an ALA patch is also available and demonstrates similar efficacy as the creams. Treatment protocols for PDT are not yet standardised; incubation times, wavelength, and dose differ in both trial and practice. Recent efforts have been made to issue guidelines to help clarify the most successful approaches for various dermatology conditions, including AK and field cancerization [77–81].

Studies of ALA-PDT and MAL-PDT reveal similar efficacy. One study of ALA-PDT demonstrated 66% lesion clearance at 8 weeks (following single treatment) and 85% at 16 weeks (following retreatment) [82]. Another study of ALA-PDT demonstrated complete clearance rates of 66% at week 8 and 73% at week 12 [83]. A study of MAL-PDT demonstrated complete (lesion) response rates of up to 89% with retreatment [84]. Pretreatment curettage is often used in conjunction with PDT and probably enhances the efficacy rates. PDT is associated with pain (more significant with ALA) and hypersensitivity to light. However, PDT can be used over large areas in a single session and has been associated with favorable cosmetic results. A recent study demonstrated that MAL-PDT was associated with reduced keratinocyte atypia on photodamaged skin (supporting its efficacy in field cancerization) as well as an increase of new collagen deposition (perhaps explaining its beneficial cosmetic effect) [85].

In patients with thin AK lesions in large field-cancerized areas, daylight-mediated PDT may provide an effective and less painful treatment option [86]. Several small randomised clinical studies of daylight-mediated PDT for treatment of mostly thin AK lesions on the face and scalp have demonstrated 3-month lesion response rates of 75%–79%, with significantly less pain than reported with conventional PDT [87–89]. This treatment approach is still in development.

Radiotherapy

Radiotherapy (or radiation therapy) is an effective approach for treatment of AK and field cancerization in patients who require treatment of a large field with a multiplicity of lesions [90–92]. In addition, physicians have reported excellent results using radiotherapy in patients with lesions that have not been responsive to other treatments [90, 91].

Radiotherapy allows irradiation of large fields (the size of two outstretched hands) of damaged skin at each session, and is most commonly used for treatment of the face and balding scalp. Recommended treatment is six sessions over three weeks, although some case reports have reported more sessions [91]. Cosmetic outcomes are typically excellent, and effects of treatment last up to two decades. Radiotherapy treatment for cutaneous neoplasms on the trunk and limbs has been associated with poorer cosmetic outcomes [93], but radiotherapy may be used to treat the lower arms and legs if indicated.

Grenz ray therapy is the preferred modality, as soft X-ray therapy may induce permanent alopecia. Side effects and adverse events are typically limited to some mild discomfort and reddening of the skin for two weeks following the treatment. Because there is a small increased risk for development of a secondary malignancy due to treatment, radiotherapy is contraindicated for treatment of AK in immunosuppressed patients. In addition, radiotherapy is best reserved for older patients (60 years +) in order to maximise the typically long-term results of treatment while minimising the risk for secondary malignancy, which also has a typically long-term latency period.

Other therapies

Other treatments for AK are available, but the evidence behind their use is less robust in comparison to effective options already presented. We briefly review these other treatment options and their potential place in the current armamentarium.

Excision of AK lesions is not a first-line treatment approach. Shave or punch excision is occasionally used to treat individual lesions, typically to obtain a specimen for histologic examination in cases of suspected invasive SCC [94]. A multicentre, hospital-based case-control study of dermatology departments in eight European countries obtained information about physician treatment preferences for skin cancer and found that surgical approaches were the most common choice for the treatment of most tumours, with a notable exception in the treatment of AK, where nonsurgical treatment was recommended in 91.4% of cases [39].

Skin grafting may have some benefit in high-risk patients. A retrospective study of eleven kidney transplant patients who underwent surgical resurfacing of the entire dorsum of the hand as a treatment for multiple skin cancers demonstrated no recurrences of skin cancer over a mean follow-up time of 4.7 years [95]. Cosmetic appearance was acceptable. The study authors suggested this surgical approach as a possible prophylactic treatment in patients with severely actinically damaged skin.

Topical retinoids have been studied for treatment of AK, but are seldom used by contemporary physicians. Results from a few studies indicate some limited benefit compared to placebo; however, recent results from a large randomised chemoprevention trial in high-risk patients demonstrated no differences in NMSC development or AK counts between the tretinoin group and the control group [96].

Skin resurfacing with chemical peels or lasers has shown some good results. A small, randomised, prospective study comparing carbon dioxide (CO₂) laser resurfacing, 30%

trichloroacetic acid (TCA) peels, and 5-FU administration (3 weeks) demonstrated similar efficacy results among the three treatment groups [97]. The efficacy of chemical peels is dependent on the agent used, and reported efficacy rates vary. Similarly, reported efficacy results from laser resurfacing have varied, as these results are highly dependent on the skill and technique of the treating physician. More study of the optimum approach is required to assess where laser may fit into the AK treatment armamentarium.

Small studies have reported some benefits from dermabrasion for treatment of AK. However, these study results are not compelling. In addition, dermabrasion requires local anaesthesia and has the potential for significant side effects, including bleeding and scarring.

Table 3 summarises the available treatments for AK discussed throughout this section and their efficacy in the treatment of field cancerization. Fig. 2 presents the REAKT Working Group's assessment of each available treatment within the context of important considerations related to selecting the optimum treatment for specific patients.

Combination therapy: concomitant and sequential approaches

Combination therapy is appropriate for most patients with AK, and may be especially helpful when treating patients with many lesions. Although lesion-directed therapy is not recommended for treatment of field cancerization, judicious use of lesion-directed therapy in combination with field-directed therapy may prove to be the most beneficial approach in some patients. Combining the use of two or more modalities or complementary topical agents has several theoretical advantages, including the possibility of enhanced therapeutic effect and improved utility in recalcitrant disease. Although the potential benefits of combination therapy are significant, there is much to learn about optimum approaches. The body of evidence in support of combination therapy is growing, but is currently sparse. Lack of guidelines or standardised treatment protocols for use of various modalities or topical agents in combination also hampers efforts to identify the most useful combinations in practice. The myriad possible combinations also present added risks for synergistic adverse events, with potential for increased treatment-related pain and LSRs.

PDT in combination

One study of 24 patients demonstrated greater efficacy resulting from sequential therapy with ALA-PDT + imiquimod 5% versus ALA-PDT + placebo [98]. A randomised pilot study compared the use of MAL-PDT monotherapy, imiquimod 5% monotherapy, and sequential therapy with MAL-PDT + imiquimod 5% in patients with AK on the face and scalp [99]. Sequential therapy provided a better response than either therapy alone, with "significantly less intense local reactions" and greater patient satisfaction than imiquimod 5% monotherapy [99].

Studies have also investigated sequential treatment strategies using topicals as the initial therapy, followed by PDT. A small controlled study indicated that pretreatment with tazarotene may enhance the effects of ALA-PDT

across the entire treatment field [100]. A prospective case-based assessment of sequential application of 5% 5-FU + PDT indicated enhanced results over PDT alone [101]. A randomised, placebo-controlled, double-blind pilot study of 10 patients investigated whether pretreatment with diclofenac would improve the results obtained from PDT [102]. Pretreatment with diclofenac was found to significantly reduce lesion count at 12 months, but was associated with more pain during PDT.

Cryotherapy in combination

A number of studies have investigated the use of cryotherapy in combination with other therapies. In one randomised, double-blind, placebo-controlled study, patients with AK were treated with cryotherapy followed by application of imiquimod 3.75% or placebo cream daily for two 2-week cycles [103]. The results demonstrated that the use of imiquimod 3.75% post-cryotherapy resulted in subject complete clearance rates of 60% versus 30% in subjects who received placebo ($p < 0.001$). The combined therapy was well tolerated. An open-label study of imiquimod 5% versus vehicle postcryotherapy found improved efficacy with the combination in regard to 12 week lesion counts, although target AK clearance was similar for imiquimod and vehicle [104].

Similarly, the results of an open-label phase 4 study of 714 enrolled patients found that cryotherapy followed by application of diclofenac for 90 days was significantly more effective at clearing lesions than cryotherapy alone: 64% achieved complete clearance with sequential therapy versus 32% with cryotherapy alone [105]. However, more patients assigned to sequential therapy discontinued treatment because of adverse events. A small case series of patients who received diclofenac gel for 12 weeks followed by cryotherapy when needed for recalcitrant lesions demonstrated a substantial reduction in lesion count and a mean lesion-free period of 10 months [106]. No treatment discontinuations due to adverse events were noted.

A randomised controlled trial of the effect of treatment with 0.5% 5-FU followed by cryotherapy to residual lesions at 4 weeks following treatment initiation found that the combination was significantly more effective in lowering 6 month lesion count when compared to cryotherapy alone [107].

A phase 3 study is currently in progress comparing the safety and efficacy of a sequential treatment regimen of cryotherapy followed by field treatment with ingenol mebutate gel 0.015% versus cryotherapy followed by vehicle gel for treatment of AKs on the face and scalp [108]. Complete clearance rates at 11 weeks following sequential treatment with cryotherapy + ingenol mebutate were significantly higher than the rates observed with cryotherapy + vehicle gel (60.5% vs 49.4%; $p = 0.04$) [109]. Adverse events and LSRs were comparable to those observed in other studies.

Combining topical therapies

Combinations of topical therapies may also be beneficial. One study of 64 patients tested the combination of two established topicals, imiquimod 5% and 5-FU [110]. 48 patients completed the study and achieved clearance of their

Table 3: Summary of treatments for actinic keratosis and efficacy in the treatment of field cancerization.				
Treatment	LD/FD	Efficacy in treatment of field cancerization		Comments
		Evidence of treatment benefits	OCEBM LOE	
Sunscreen	FD	Use of sunscreen improves lesion remission and reduces lesion progression.	2	Use is encouraged adjunctively for all patients. May be used as sole treatment in some patients. Should be applied to all sun-exposed areas.
Curettage/ electrodesiccation	LD	Undocumented	N/A	May be beneficial in hyperkeratotic lesions and in combination with field therapy. Localised use preferred over field application.
Cryotherapy	LD	Some field cancerization benefit reported in a review of charts from a single practice where patients were treated with a cryopeeling technique.	4	Widely used lesion-directed treatment. Physician-directed treatment. Approach is not standardised, leading to wide range of outcomes. Localised use preferred over field application.
5-Fluorouracil	FD	Complete clearance rates for 5% 5-FU: • 42%-96%, 4 weeks post treatment • Sustained clearance rate at 12 months: 33% (one RCT) Complete clearance rate for 0.5% 5-FU + SA at 8 weeks following treatment: 55.4%	1	Treatment of large areas possible with occlusion (Unna boot). This use is physician directed.
Diclofenac	FD	Complete clearance rate 30 days following treatment: approximately 40% (meta-analysis of 3 RCTs with treatment duration either 60 or 90 days)	1	Good cosmesis. Larger areas can be treated depending on side effects and patient tolerance.
Imiquimod	FD	Complete clearance rates after 16 week course: 48.3% to 57.1% Complete clearance rates after 4 week short course treatment: 26.8% after one course; 53.7% after two courses	1	Unmasking of subclinical lesions. Systemic reactions rarely. Larger areas can be treated depending on side effects and patient tolerance.
Resiquimod (currently in Phase 3)	FD	Complete clearance rates 8 weeks following treatment: • After one course of treatment: 40% to 74.2% (dose dependent) After second course of treatment: 77.1% to 90.3% (dose dependent)	3	Treatment aimed at biological response (inflammation). Inflammation may be early or late. Larger areas can be treated depending on side effects and patient tolerance.
Ingenol mebutate	FD	Complete clearance rates 57 days following treatment: • 37%-47% (face) • 28%-42% (body) Sustained clearance rates at 12 months following treatment (patients who had achieved complete clearance at 57 days): • 46.1% (face) • 44% (body)	1	Strong local reaction with short administration time. Larger areas can be treated depending on side effects and patient tolerance.
Topical retinoids	FD	Varied efficacies reported. Recent RCT reported no observed difference in lesion counts between topical tretinoin and placebo.	2	Not recommended due to low efficacy.
ALA/MAL + PDT	LD and FD	Lesion clearance rates range from 66% to 89% depending on photosensitising agent and treatment regimen. Small studies indicate benefit for treatment of field cancerization.	3	Physician-directed treatment. Pain is a consideration, and will limit the size of treatment field depending on patient preference and previous experience. Daylight PDT in development.
Radiotherapy (Grenz ray)	FD	13 out of 16 patients had complete clearance 2 weeks following treatment completion.	4	Physician-directed treatment. Recommended that its use be limited to patients over 60 years of age. 1 treatment cycle per field per lifetime. Grenz ray is recommended. Soft X-ray may induce alopecia. Larger areas can be treated depending on side effects and patient tolerance.
Excision	LD	Undocumented	N/A	Not a first-line treatment. Appropriate only for localised use. Typically reserved for lesions highly suspicious for invasive SCC.
Skin grafting	FD	11 out of 11 patients had complete clearance out to 4.7 years.	4	Rarely used; may be helpful in singular cases involving areas of pronounced field cancerization, such as the back of the hands.
Chemical peels	FD	AK lesion reduction of up to 89% reported.	3	May be helpful in select patients. Larger areas can be treated depending on side effects and patient tolerance.
Laser	FD	AK lesion reduction of up to 92% reported.	3	May be helpful in select patients. Larger areas can be treated depending on side effects and patient tolerance.

Dermabrasion	FD	Some sustained benefit observed in small case series.	4	May be helpful in select patients. Larger areas can be treated depending on side effects and patient tolerance.
--------------	----	---	---	--

Note: The level of evidence has been noted based on evidence of each treatment's efficacy for field cancerization. Treatment comments and recommendations for use are based on a consideration of available evidence as of the article submission date regarding treatment of field cancerization, in conjunction with the subjective opinions of the authors based on their collective practical experiences. It is not the intention of the REAKT Working Group to preferentially promote the use of one modality or product over another except within the context of evidence and experience that supports better efficacy for a patient's unique presentation.

AKs after 3 treatment cycles; the combination was judged to be relatively faster and more convenient than either therapy alone. A case-control study of 10 patients confirmed the potential efficacy of this combination in patients with treatment-refractory AK [111].

As the therapeutic armamentarium for AK continues to expand, targeted combination treatment plans will likely play a larger role in treating AKs and field cancerization. However, more evidence is needed to determine the combinations that provide the best balance of efficacy and safety in practice.

Management considerations for the immunocompromised

Patients who are immunocompromised require diligent monitoring for AKs and other NMSC and aggressive treatment if lesions are noted. Patients with CLL are at significant elevated risk for development of cutaneous neoplasms; multiple instances or aggressive forms of skin cancer could raise suspicion of CLL.

OTR are an important and growing subset of patients at increased risk for the development of NMSC. Advances in organ transplantation management have increased the survival time of OTR to 20 years or more following transplantation [112]. OTR are subject to the same risk factors as the general population, but with the added burden of immunosuppressive therapy. It has been estimated that up to 40% of OTR patients develop pre-malignant tumours within the first five years of immunosuppression [112, 113]. OTR also bear increased risk for developing lesions with unusual presentation and aggressive progression rates.

A Swiss study of 243 renal transplant recipients on immunosuppressive therapy confirmed an increased risk for the development of AKs and NMSC, especially SCC (ratio of BCC: SCC was 1:7) [114]. Older age, male sex, and fair skin were factors associated with higher risk for developing AKs and/or SCC. Increasing duration of immunotherapy was also a significant factor, although no specific immunosuppressive therapy was noted as a distinct risk factor in this study.

The increased risk of skin cancer may result from decreased immunosurveillance as well as drug-specific properties [115]. A Swiss study of 48 kidney transplant patients who were receiving either azathioprine (AZA) or mycophenolate (MMF) evaluated the skin photosensitivity effects of changing from AZA to MMF [116]. The study results revealed that changing from AZA to MMF did reduce skin photosensitivity to UVA, but not UVB, in the patient population tested (primarily skin types II and III). The results from two small UK studies also indicate increased UVA photosensitivity in patients taking therapeutic doses of AZA [117, 118].

The use of calcineurin inhibitors has also been associated with an increased risk for NMSC. One study noted a 2.8 times greater risk of NMSC when cyclosporine was added to an immunosuppressive protocol of AZA and prednisolone [119]. Another study found that replacing calcineurin inhibitors with sirolimus reduced the incidence of SCC and lengthened the time to onset, although adverse events were significantly greater with sirolimus therapy [115].

Other studies have found no specific connection between types of immunosuppressive therapy and NMSC risk, and it is possible that the level of immunosuppression is a more critical factor than the type [120]. Further comparative research into the association between immunosuppressive drugs and the incidence of skin cancer will enhance our understanding of possible risks and may provide valuable strategies for managing and reducing this risk in the future. For now, it is important that physicians are aware of these considerations.

A retrospective analysis of the cost of dermatologic care in one Swiss clinic found that dermatology care costs for OTR are high, with the majority of costs due to occurrence of SCC [121]. Once SCC occurs, the costs of care "increase in a pronounced and sustained fashion" [121]. Interventions that limit progression of early lesions to invasive SCC can result in considerable cost savings.

The immunosuppressed population requires specific targeted surveillance to help ensure early diagnosis and management of skin cancers. The REAKT Working Group recommends that OTR and other patients who are immunocompromised receive yearly comprehensive screening to ensure early diagnosis of SCC in-situ and timely and aggressive treatment to limit progression. This approach is likely to improve long-term prognosis as well as reduce the costs associated with SCC in these populations. Concern has been raised about the safety of immune stimulators such as imiquimod. However, there is now a body of evidence suggesting that these substances are safe in OTR [122].

Funding / potential competing interests: LEO Pharma has provided financial support for the authors' meetings and for medical writing services in preparation of these guidelines. Gina Kaeuper was the medical writer for these guidelines and was compensated by LEO Pharma. GH and WHB are consultants to LEO Pharma. OG is member of scientific advisory boards for LEO and Galderma and has received speaker honoraria from Leo, Galderma and Alimrall. CM is member of advisory board dermatology for LEO Pharma.

Correspondence: Professor Günther Hofbauer, MD, Dermatologische Klinik, UniversitätsSpital Zürich, Gloriastrasse 31, CH-8091 Zürich, Switzerland, [hofbauer\[at\]usz.ch](mailto:hofbauer[at]usz.ch)

References

- 1 OCEBM Levels of Evidence Working Group. The Oxford 2011 Levels of Evidence. Oxford Centre for Evidence-Based Medicine. Available at: <http://www.cebm.net/index.aspx?o=5653>. Accessed October 15, 2013.
- 2 Marks R, Foley P, Goodman G, Hage BH, Selwood TS. Spontaneous remission of solar keratoses: the case for conservative management. *Br J Dermatol.* 1986;115:649–55.
- 3 Anwar J, Wrone DA, Kimyai-Asadi A, Alam M. The development of actinic keratosis into invasive squamous cell carcinoma: evidence and evolving classification schemes. *Clin Dermatol.* 2004;22:189–96.
- 4 Roewert-Huber J, Stockfleth E, Keri H. Pathology and pathobiology of actinic (solar) keratosis—an update. *Br J Dermatol.* 2007;157:18–20.
- 5 Rossi R, Mori M, Lotti T. Actinic keratosis. *Int J Dermatol.* 2007;46:895–904.
- 6 Ackerman AB, Mones JM. Solar (actinic) keratosis is squamous cell carcinoma. *Br J Dermatol.* 2006;155:9–22.
- 7 Tabor MP, Brakenhoff RH, van Houten VM, Kummer JA, Snel MH, Snijders PJ, et al. Persistence of genetically altered fields in head and neck cancer patients: biological and clinical implications. *Clin Cancer Res.* 2001;7:1523–32.
- 8 Wennberg AM, Stenquist B, Stockfleth E, Keohane S, Lear JT, Jemec G, et al. Photodynamic therapy with methyl aminolevulinate for prevention of new skin lesions in transplant recipients: a randomized study. *Transplantation.* 2008;86:423–9.
- 9 Wulf HC, Pavel S, Stender I, Bakker-Wensveen CA. Topical photodynamic therapy for prevention of new skin lesions in renal transplant patients. *Acta Derm Venereol.* 2006;86:25–8.
- 10 Lucas R, McMichael T, Smith W, Armstrong B. Solar ultraviolet radiation: global burden of disease from solar ultraviolet radiation. World Health Organization. Environmental Burden of Disease Series, No. 13. 2006.
- 11 Frost CA, Green AC. Epidemiology of solar keratoses. *Br J Dermatol.* 1994;131:455–64.
- 12 Traianou A, Ulrich M, Apalla Z, De Vries E, Bakirtzi K, Kalabalikis D, et al. EPIDERM Group. Risk factors for actinic keratosis in eight European centres: a case-control study. *Br J Dermatol.* 2012;167:36–42.
- 13 Marks R, Rennie G, Selwood TS. Malignant transformation of solar keratoses to squamous cell carcinoma. *Lancet.* 1988;1:795–97.
- 14 Mittelbronn MA, Mullins DL, Ramos-Caro FA, Flowers FP. Frequency of pre-existing actinic keratosis in cutaneous squamous cell carcinoma. *Int J Dermatol.* 1998;37:677–81.
- 15 Dodson JM, DeSpain J, Hewett JE, Clark DP. Malignant potential of actinic keratoses and the controversy over treatment. A patient-oriented perspective. *Arch Dermatol.* 1991;127:1029–31.
- 16 Glogau RG. The risk of progression to invasive disease. *J Am Acad Dermatol.* 2000;42:23–4.
- 17 Werner RN, Sammain A, Erdmann R, Hartmann V, Stockfleth E, Nast A. The natural history of actinic keratosis: a systematic review. *Br J Dermatol.* 2013;169:502–18.
- 18 Bulliard JL, Panizzon RG, Levi F. [Epidemiology of epithelial skin cancers]. *Rev Med Suisse.* 2009;5:882,884–8. Article in French.
- 19 Stang A, Stausberg J, Boedeker W, Kerek-Bodden H, Jockel KH. Nationwide hospitalization costs of skin melanoma and non-melanoma skin cancer in Germany. *J Eur Acad Dermatol Venereol.* 2008;22:65–72.
- 20 Reinau D, Meier C, Gerber N, Hofbauer G, Surber C. Sun protective behavior of primary and secondary school students in North-Western Switzerland. *Swiss Med Wkly.* 2012;142:w13520.
- 21 Green A, Williams G, Neale R, Hart V, Leslie D, Parsons P, et al. Daily sunscreen application and betacarotene supplementation in prevention of basal-cell and squamous-cell carcinomas of the skin: a randomised controlled trial. *Lancet.* 1999;354:723–9.
- 22 Van der Pols JC, Williams GM, Pandeya N, Logan V, Green AC. Prolonged prevention of squamous cell carcinoma of the skin by regular sunscreen use. *Cancer Epidemiol Biomarkers Prev.* 2006;15:2546–8.
- 23 Gordon LG, Scuffham PA, van der Pols JC, McBride P, Williams GM, Green AC. Regular sunscreen use is a cost-effective approach to skin cancer prevention in subtropical settings. *J Invest Dermatol.* 2009;129:2766–71.
- 24 Ulrich C, Jürgensen JS, Degen A, Hackethal M, Ulrich M, Patel MJ, et al. Prevention of non-melanoma skin cancer in organ transplant patients by regular use of a sunscreen: a 24 months, prospective, case-control study. *Br J Dermatol.* 2009;161:78–84.
- 25 Kadakia KC, Barton DL, Loprinzi CL, Sloan JA, Otley CC, Diekmann BB, et al. Randomized controlled trial of acitretin versus placebo in patients at high risk for basal cell or squamous cell carcinoma of the skin (North Central Cancer Treatment Group Study 969251). *Cancer.* 2012;118:2128–37.
- 26 Endrizzi BT, Lee PK. Management of carcinoma of the skin in solid organ transplant recipients with oral capecitabine. *Dermatol Surg.* 2009;35:1567–72.
- 27 Jirakulaporn T, Endrizzi B, Lindgren B, Mathew J, Lee PK, Dudek AZ. Capecitabine for skin cancer prevention in solid organ transplant recipients. *Clin Transplant.* 2011;25:541–48.
- 28 Hofbauer GF, Anliker M, Arnold A, Binet I, Hunger R, Kempf W, et al. SGDV working group for organ transplant recipients. Swiss clinical practice guidelines for skin cancer in organ transplant recipients. *Swiss Med Wkly.* 2009;139:407–15.
- 29 Huerta-Brogeras M, Olmos O, Borbujo J, Hernández-Núñez A, Castaño E, Romero-Maté A, et al. Validation of dermoscopy as a real-time non-invasive diagnostic imaging technique for actinic keratosis. *Arch Dermatol.* 2012;148:1159–64.
- 30 Peris K, Micantonio T, Piccolo D, Fargnoli MC. Dermoscopic features of actinic keratosis. *J Dtsch Dermatol Ges.* 2007;5:970–6.
- 31 Zalaudek I, Giacomel J, Schmid K, Bondino S, Rosendahl C, Cavicchini S, et al. Dermatoscopy of facial actinic keratosis, intraepidermal carcinoma, and invasive squamous cell carcinoma: a progression model. *J Am Acad Dermatol.* 2012;66:589–97.
- 32 Wolf JE Jr, Rigel DS. Understanding efficacy end-points in studies of field-directed therapy for actinic keratosis. *Int J Dermatol.* 2013;52:1063–70.
- 33 Chen SC, Hill ND, Veledar E, Swetter SM, Weinstock MA. Reliability of quantification measures of actinic keratosis. *Br J Dermatol.* 2013;169:1219–22.
- 34 Elliott R. Non-adherence to medicines: not solved but solvable. *J Health Serv Res Policy.* 2009;14:58–61.
- 35 Lebwohl M, Swanson N, Anderson LL, Melgaard A, Xu Z, Berman B. Ingenol mebutate gel for actinic keratosis. *N Engl J Med.* 2012;366:1010–19.
- 36 Nashan D, Meiss F, Müller M. Therapeutic strategies for actinic keratosis—a systematic review. *Eur J Dermatol.* 2013;23:14–32.
- 37 Darlington S, Williams G, Neale R, Frost C, Green A. A randomized controlled trial to assess sunscreen application and beta carotene supplementation in the prevention of solar keratoses. *Arch Dermatol.* 2003;139:451–5.
- 38 Thompson SC, Jolley D, Marks R. Reduction of solar keratoses by regular sunscreen use. *N Engl J Med.* 1993;329:1147–51.
- 39 Ferrandiz L, Ruiz-de-Casas A, Trakatelli M, de Vries E, Ulrich M, Aquilina S, et al. EPIDERM Group. Assessing physicians' preferences on skin cancer treatment in Europe. *Br J Dermatol.* 2012;167:29–35.
- 40 Thai KE, Fergin P, Freeman M, Vinciullo C, Francis D, Spelman L, et al. A prospective study of the use of cryosurgery for the treatment of actinic keratoses. *Int J Dermatol.* 2004;43:687–92.
- 41 Kaufmann R, Spelman L, Weightman W, Reifenberger J, Szeimies RM, Verhaeghe E, et al. Multicentre intraindividual randomized trial of topical methyl aminolevulinate-photodynamic therapy vs. cryotherapy for multiple actinic keratoses on the extremities. *Br J Dermatol.* 2008;158:994–9.
- 42 Krawtchenko N, Roewert-Huber J, Ulrich M, Mann I, Sterry W, Stockfleth E. A randomised study of topical 5% imiquimod vs. topical 5-fluorouracil vs. cryosurgery in immunocompetent patients with actinic keratoses: a comparison of clinical and histological outcomes including 1-year follow-up. *Br J Dermatol.* 2007;157:34–40.

- 43 Gupta AK, Paquet M. Network meta-analysis of the outcome 'participant complete clearance' in nonimmunosuppressed participants of eight interventions for actinic keratosis: a follow-up on a Cochrane review. *Br J Dermatol*. 2013;169:250–9.
- 44 Zouboulis CC. Cryosurgery in dermatology. *Eur J Dermatol*. 1998;8:466–74.
- 45 Chiarello SE. Cryopeeling (extensive cryosurgery) for treatment of actinic keratoses: an update and comparison. *Dermatol Surg*. 2000;26:728–32.
- 46 Gupta AK. The management of actinic keratoses in the United States with topical fluorouracil: a pharmacoeconomic evaluation. *Cutis*. 2002;70:30–6.
- 47 Loven K, Stein L, Furst K, Levy S. Evaluation of the efficacy and tolerability of 0.5% fluorouracil cream and 5% fluorouracil cream applied to each side of the face in patients with actinic keratosis. *Clin Ther*. 2002;24:990–1000.
- 48 Jorizzo J, Stewart D, Bucko A, Davis SA, Espy P, Hino P, et al. Randomized trial evaluating a new 0.5% fluorouracil formulation demonstrates efficacy after 1-, 2-, or 4-week treatment in patients with actinic keratosis. *Cutis*. 2002;70:335–9.
- 49 Weiss J, Menter A, Hevia O, Jones T, Ling M, Rist T, et al. Effective treatment of actinic keratosis with 0.5% fluorouracil cream for 1, 2, or 4 weeks. *Cutis*. 2002;70:22–9.
- 50 Stockfleth E, Kerl H, Zwingers T, Willers C. Low-dose 5-fluorouracil in combination with salicylic acid as a new lesion-directed option to treat topically actinic keratoses: histological and clinical study results. *Br J Dermatol*. 2011;165:1101–8.
- 51 Rundhaug JE, Fischer SM. Cyclo-oxygenase-2 plays a critical role in UV-induced skin carcinogenesis. *Photochem Photobiol*. 2008;84:322–9.
- 52 Fecker LF, Stockfleth E, Nindl I, Ulrich C, Forschner T, Eberle J. The role of apoptosis in therapy and prophylaxis of epithelial tumours by nonsteroidal anti-inflammatory drugs (NSAIDs). *Br J Dermatol*. 2007;156:25–33.
- 53 Rivers JK, Arlette J, Shear N, Guenther L, Carey W, Poulin Y. Topical treatment of actinic keratoses with 3.0% diclofenac in 2.5% hyaluronan gel. *Br J Dermatol*. 2002;146:94–100.
- 54 Wolf JE Jr, Taylor JR, Tschen E, Kang S. Topical 3.0% diclofenac in 2.5% hyaluronan gel in the treatment of actinic keratoses. *Int J Dermatol*. 2001;40:709–713.
- 55 Pirard D, Vereecken P, Melot C, Heenen M. Three percent diclofenac in 2.5% hyaluronan gel in the treatment of actinic keratoses: a meta-analysis of the recent studies. *Arch Dermatol Res*. 2005;297:185–9.
- 56 Nelson C, Rigel D, Smith S, Swanson N, Wolf J. Phase IV, open-label assessment of the treatment of actinic keratosis with 3.0% diclofenac sodium topical gel (Solaraze). *J Drugs Dermatol*. 2004;3:401–7.
- 57 Nelson C, Rigel D. Long-term follow up of diclofenac sodium 3% in 2.5% hyaluronan acid gel for actinic keratosis: one-year evaluation. *J Clin Aesthet Dermatol*. 2009;2:20–5.
- 58 Ulrich C, Hackethal M, Ulrich M, Howorka A, Forschner T, Sterry W, et al. Treatment of multiple actinic keratoses with topical diclofenac 3% gel in organ-transplant recipients: a series of six cases. *Br J Dermatol*. 2007;156:40–2.
- 59 Ulrich C, Johannsen A, Rówert-Huber J, Ulrich M, Sterry W, Stockfleth E. Results of a randomized, placebo-controlled safety and efficacy study of topical diclofenac 3% gel in organ transplant patients with multiple actinic keratoses. *Eur J Dermatol*. 2010;20:482–8.
- 60 Korman N, Moy R, Ling M, Matheson R, Smith S, McKane S, et al. Dosing with 5% imiquimod cream 3 times per week for the treatment of actinic keratosis: results of two phase 3, randomized, double-blind, parallel-group, vehicle-controlled trials. *Arch Dermatol*. 2005;141:467–73.
- 61 Szeimies RM, Gerritsen MJ, Gupta G, Ortonne JP, Serresi S, Bichel J, et al. Imiquimod 5% cream for the treatment of actinic keratosis: results from a phase III, randomized, double-blind, vehicle-controlled, clinical trial with histology. *J Am Acad Dermatol*. 2004;51:547–55.
- 62 Lee PK, Harwell WB, Loven KH, Phillips TJ, Whiting DA, Andres KL, et al. Long-term clinical outcomes following treatment of actinic keratosis with imiquimod 5% cream. *Dermatol Surg*. 2005;31:659–64.
- 63 Jorizzo J, Dinehart S, Matheson R, Moore JK, Ling M, Fox TL, et al. Vehicle-controlled, double-blind, randomized study of imiquimod 5% cream applied 3 days per week in one or two courses of treatment for actinic keratoses on the head. *J Am Acad Dermatol*. 2007;57:265–8.
- 64 Alomar A, Bichel J, McRae S. Vehicle-controlled, randomized, double-blind study to assess safety and efficacy of imiquimod 5% cream applied once daily 3 days per week in one or two courses of treatment of actinic keratoses on the head. *Br J Dermatol*. 2007;157:133–41.
- 65 Benson E. Imiquimod: potential risk of an immunostimulant. *Australas J Dermatol*. 2004;45:123–4.
- 66 Patel U, Mark NM, Machler BC, Levine VJ. Imiquimod 5% cream induced psoriasis: a case report, summary of the literature and mechanism. *Br J Dermatol*. 2011;164:670–2.
- 67 Fanti PA, Dika E, Vaccari S, Miscial C, Varotti C. Generalized psoriasis induced by topical treatment of actinic keratosis with imiquimod. *Int J Dermatol*. 2006;45:1464–5.
- 68 Wolfe CM, Tafuri N, Hatfield K. Exacerbation of myasthenia gravis during imiquimod treatment. *J Drugs Dermatol*. 2007;6:745–6.
- 69 Swanson N, Abramovits W, Berman B, Kulp J, Rigel DS, Levy S. Imiquimod 2.5% and 3.75% for the treatment of actinic keratoses: results of two placebo-controlled studies of daily application to the face and balding scalp for two 2-week cycles. *J Am Acad Dermatol*. 2010;62:582–90.
- 70 Hanke CW, Beer KR, Stockfleth E, Wu J, Rosen T, Levy S. Imiquimod 2.5% and 3.75% for the treatment of actinic keratoses: results of two placebo-controlled studies of daily application to the face and balding scalp for two 3-week cycles. *J Am Acad Dermatol*. 2010;62:573–81.
- 71 Dockrell DH, Kinghorn GR. Imiquimod and resiquimod as novel immunomodulators. *J Antimicrob Chemother*. 2001;48:751–5.
- 72 Fujisawa H, Shivji GM, Kondo S, Wang B, Tomai MA, Miller RL, et al. Effect of a novel topical immunomodulator, S-28463, on keratinocyte cytokine gene expression and production. *J Interferon Cytokine Res*. 1996;16:555–9.
- 73 Szeimies RM, Bichel J, Ortonne JP, Stockfleth E, Lee J, Meng TC. A phase II dose-ranging study of topical resiquimod to treat actinic keratosis. *Br J Dermatol*. 2008;159:205–10.
- 74 Rosen RH, Gupta AK, Tyring SK. Dual mechanism of action of ingenol mebutate gel for topical treatment of actinic keratoses: rapid lesion necrosis followed by lesion-specific immune response. *J Am Acad Dermatol*. 2012;66:486–93.
- 75 Lebwohl M, Shumack S, Stein Gold L, Melgaard A, Larsson T, Tyring SK. Long-term follow-up study of ingenol mebutate gel for the treatment of actinic keratoses. *JAMA Dermatol*. 2013;149:666–70.
- 76 Jarret M, Katsamas J, Cawkill K, Henderson L, Welburn P. A pharmacokinetic study using a highly sensitive and specific method to determine systemic exposure of ingenol mebutate and its two main metabolites, PEP015 and PEP025 in human whole blood after topical administration. *J Am Acad Dermatol*. 2013;68:AB156.
- 77 Braathen LR, Szeimies RM, Basset-Seguín N, Bissonnette R, Foley P, Pariser D, et al. International Society for Photodynamic Therapy in Dermatology. Guidelines on the use of photodynamic therapy for non-melanoma skin cancer: an international consensus. International Society for Photodynamic Therapy in Dermatology, 2005. *J Am Acad Dermatol*. 2007;56:125–43.
- 78 Morton CA, Brown SB, Collins S, Ibbotson S, Jenkinson H, Kurwa H, et al. Guidelines for topical photodynamic therapy: report of a workshop of the British Photodermatology Group. *Br J Dermatol*. 2002;146:552–67.
- 79 Morton CA, McKenna KE, Rhodes LE; British Association of Dermatologists Therapy Guidelines and Audit Subcommittee and the British Photodermatology Group. Guidelines for topical photodynamic therapy: update. *Br J Dermatol*. 2008;159:1245–66.
- 80 Morton CA, Szeimies RM, Sidoroff A, Braathen LR. European guidelines for topical photodynamic therapy part 1: treatment delivery and current indications—actinic keratoses, Bowen's disease, basal cell carcinoma. *J Eur Acad Dermatol Venereol*. 2013;27:536–44.
- 81 Morton CA, Szeimies RM, Sidoroff A, Braathen LR. European guidelines for topical photodynamic therapy part 2: emerging indications—field cancerization, photorejuvenation, and inflammatory/infective dermatoses. *J Eur Acad Dermatol Venereol*. 2013;27:672–9.

- 82 Jeffes EW, McCullough JL, Weinstein GD, Kaplan R, Glazer SD, Taylor JR. Photodynamic therapy of actinic keratoses with topical aminolevulinic acid hydrochloride and fluorescent blue light. *J Am Acad Dermatol.* 2001;45:96–104.
- 83 Piacquadro DJ, Chen DM, Farber HF, Fowler JF Jr, Glazer SD, Goodman JJ, et al. Photodynamic therapy with aminolevulinic acid topical solution and visible blue light in the treatment of multiple actinic keratoses of the face and scalp: investigator-blinded, phase 3, multicenter trials. *Arch Dermatol.* 2004;140:41–6.
- 84 Tarstedt M, Rosdahl I, Berne B, Svanberg K, Wennberg AM. A randomized multicenter study to compare two treatment regimens of topical methyl aminolevulinate (Metvix) — PDT in actinic keratosis of the face and scalp. *Acta Derm Venereol.* 2005;85:424–8.
- 85 Szeimies RM, Torezan L, Niwa A, Valente N, Unger P, Kohl E, et al. Clinical, histopathological and immunohistochemical assessment of human skin field cancerization before and after photodynamic therapy. *Br J Dermatol.* 2012;167:150–9.
- 86 Wiegell SR, Wulf HC, Szeimies RM, Basset-Seguín N, Bissonnette R, Gerritsen MJ, et al. Daylight photodynamic therapy for actinic keratosis: an international consensus: International Society for Photodynamic Therapy in Dermatology. *J Eur Acad Dermatol Venereol.* 2012;26:673–9.
- 87 Wiegell SR, Haedersdal M, Phillipsen PA, Eriksen P, Enk CD, Wulf HC. Continuous activation of PpIX by daylight is as effective as and less painful than conventional photodynamic therapy for actinic keratoses; a randomized, controlled, single-blinded study. *Br J Dermatol.* 2008;158:740–6.
- 88 Wiegell SR, Haedersdal M, Eriksen P, Wulf HC. Photodynamic therapy of actinic keratoses with 8% and 16% methyl aminolevulinate and home-based daylight exposure: a double-blinded randomized clinical trial. *Br J Dermatol.* 2009;160:1308–14.
- 89 Wiegell SR, Fabricius S, Stender IM, Berne B, Kroon S, Andersen BL, et al. A randomized, multicentre study of directed daylight exposure times of 1½ vs. 2½ h in daylight-mediated photodynamic therapy with methyl aminolevulinate in patients with multiple thin actinic keratoses of the face and scalp. *Br J Dermatol.* 2011;164:1083–90.
- 90 Barta U, Gräfe T, Wollina U. Radiation therapy for extensive actinic keratosis. *J Eur Acad Dermatol Venereol.* 2000;14:293–5.
- 91 Dinehart SM, Graham M, Maners A. Radiation therapy for widespread actinic keratoses. *J Clin Aesthet Dermatol.* 2011;4:47–50.
- 92 Pipitone MA, Gloster HM. Superficial squamous cell carcinomas and extensive actinic keratoses of the scalp treated with radiation therapy. *Dermatol Surg.* 2006;32:756–9.
- 93 Caccialanza M, Piccinno R, Beretta M, Gnechi L. Results and side effects of dermatologic radiotherapy: a retrospective study of irradiated cutaneous epithelial neoplasms. *J Am Acad Dermatol.* 1999;41:589–94.
- 94 Emmett AJ, Broadbent GD. Shave excision of superficial solar skin lesions. *Plast Reconstr Surg.* 1987;80:47–54.
- 95 Van Zuuren EJ, Pasma AN, Scholtens RE, Vermeer BJ, van der Woude FJ, Bouwes Bavinck JN. Resurfacing the back of the hand as treatment and prevention of multiple skin cancers in kidney transplant recipients. *J Am Acad Dermatol.* 1994;31:760–4.
- 96 Weinstock MA, Bingham SF, DiGiovanna JJ, Rizzo AE, Marcolivio K, Hall R, et al. Veterans Affairs Topical Tretinoin Chemoprevention Trial Group. Tretinoin and the prevention of keratinocyte carcinoma (basal and squamous cell carcinoma of the skin): a Veterans Affairs randomized chemoprevention trial. *J Invest Dermatol.* 2012;132:1583–90.
- 97 Hantash BM, Stewart DB, Cooper ZA, Rehmus WE, Koch RJ, Swetter SM. Facial resurfacing for nonmelanoma skin cancer prophylaxis. *Arch Dermatol.* 2006;142:976–82.
- 98 Shaffelburg M. Treatment of actinic keratoses with sequential use of photodynamic therapy and imiquimod 5% cream. *J Drugs Dermatol.* 2009;8:35–39.
- 99 Serra-Guillén C, Nagore E, Hueso L, Traves V, Messeguer F, Sanmartín O, et al. A randomized pilot comparative study of topical methyl aminolevulinate photodynamic therapy versus imiquimod 5% versus sequential application of both therapies in immunocompetent patients with actinic keratosis: clinical and histologic outcomes. *J Am Acad Dermatol.* 2012;66:e131–e7.
- 100 Galitzer BI. Effect of retinoid pretreatment on outcomes of patients treated by photodynamic therapy for actinic keratosis of the hand and forearm. *J Drugs Dermatol.* 2011;10:1124–32.
- 101 Martin G. Prospective, case-based assessment of sequential therapy with topical fluorouracil cream 0.5% and ALA-PDT for the treatment of actinic keratosis. *J Drugs Dermatol.* 2011;10:372–8.
- 102 Van der Geer S, Krekels GA. Treatment of actinic keratoses on the dorsum of the hands: ALA-PDT versus diclofenac 3% gel followed by ALA-PDT. A placebo-controlled, double-blind, pilot study. *J Dermatolog Treat.* 2009;20:259–65.
- 103 Jorizzo JL, Markowitz O, Lebwohl MG, Bourcier M, Kulp J, Meng TC, et al. A randomized, double-blinded, placebo-controlled, multicenter, efficacy and safety study of 3.75% imiquimod cream following cryosurgery for the treatment of actinic keratoses. *J Drugs Dermatol.* 2010;9:1101–8.
- 104 Tan JK, Thomas DR, Poulin Y, Maddin F, Tang J. Efficacy of imiquimod as an adjunct to cryotherapy for actinic keratoses. *J Cutan Med Surg.* 2007;11:195–201.
- 105 Berlin JM, Rigel DS. Diclofenac sodium 3% gel in the treatment of actinic keratoses postcryosurgery. *J Drugs Dermatol.* 2008;7:669–73.
- 106 Mastrolonardo M. Topical diclofenac 3% gel plus cryotherapy for treatment of multiple and recurrent actinic keratoses. *Clin Exp Dermatol.* 2009;34:33–5.
- 107 Jorizzo J, Weiss J, Furst K, VandePol C, Levy SF. Effect of a 1-week treatment with 0.5% topical fluorouracil on occurrence of actinic keratosis after cryosurgery. *Arch Dermatol.* 2004;140:813–6.
- 108 ClinicalTrials.gov website. A sequential treatment regimen of cryotherapy and Picato® for the treatment of actinic keratosis on the face and scalp. Available at: <http://clinicaltrials.gov/ct2/show/NCT01541553?term=ingenol+mebutate+cryotherapy&rank=2>. Accessed June 4, 2013.
- 109 Swanson N, Berman B, Goldenberg G, Hanke W, Tyring S, Werschler WP, et al. Evaluation of topical treatment with ingenol mebutate gel 0.015%, 3 weeks after cryosurgery of actinic keratosis on the face and scalp. In: Proceedings from 22nd Congress of the European Academy of Dermatology and Venereology; October 2–6, 2013; Istanbul, Turkey. Abstract P532.
- 110 Price NM. The treatment of actinic keratoses with a combination of 5-fluorouracil and imiquimod creams. *J Drugs Dermatol.* 2007;6:778–81.
- 111 Ondo AL, Padilla RS, Miedler JD, Cockerell CJ, Kemer JD, Steiner RL, et al. Treatment-refractory actinic keratoses successfully treated using simultaneous combination topical 5-fluorouracil cream and imiquimod cream: a case-control study. *Dermatol Surg.* 2012;38:1469–76.
- 112 Ulrich C, Christophers E, Sterry W, Meyer T, Stockfleth E. [Skin diseases in organ transplant patients]. *Hautarzt.* 2002;53:524–33.
- 113 Stockfleth E, Ulrich C, Meyer T, Christophers E. Epithelial malignancies in organ transplant patients: clinical presentation and new methods of treatment. *Recent Results Cancer Res.* 2002;160:251–8.
- 114 Keller B, Braathen LR, Marti HP, Hunger RE. Skin cancers in renal transplant recipients: a description of the renal transplant cohort in Bern. *Swiss Med Wkly.* 2010;140:w13036.
- 115 Euvrard S, Morelon E, Rostaing L, Goffin E, Brocard A, Tromme I, et al. TUMORAPA Study Group. Sirolimus and secondary skin-cancer prevention in kidney transplantation. *N Engl J Med.* 2012;367:329–39.
- 116 Hofbauer GF, Attard NR, Harwood CA, McGregor JM, Dziunycz P, Iotzova-Weiss G, et al. Reversal of UVA skin photosensitivity and DNA damage in kidney transplant recipients by replacing azathioprine. *Am J Transplant.* 2012;12:218–25.
- 117 O'Donovan P, Perrett CM, Zhang X, Montaner B, Xu YZ, Harwood CA, et al. Azathioprine and UVA light generate mutagenic oxidative DNA damage. *Science.* 2005;309:1871–4.
- 118 Perrett CM, Walker SL, O'Donovan P, Warwick J, Harwood CA, Karan P, et al. Azathioprine treatment photosensitizes human skin to ultraviolet A radiation. *Br J Dermatol.* 2008;159:198–204.
- 119 Jensen P, Hansen S, Møller B, Leivestad T, Pfeffer P, Geiran O, et al. Skin cancer in kidney and heart transplant recipients and different

- long-term immunosuppressive therapy regimens. *J Am Acad Dermatol.* 1999;40:177–86.
- 120 Tessari G, Girolomoni G. Nonmelanoma skin cancer in solid organ transplant recipients: update on epidemiology, risk factors, and management. *Dermatol Surg.* 2012;38:1622–30.
- 121 Rüegg CP, Graf N, Mühleisen B, Szucs TD, French LE, Surber C, et al. Squamous cell carcinoma of the skin induces considerable sustained cost of care in organ transplant recipients. *J Am Acad Dermatol.* 2012;67:1242–49.
- 122 Ulrich C, Bichel J, Euvrard S, Guidi B, Proby CM, van de Kerkhof PC, et al. Topical immunomodulation under systemic immunosuppression: results of a multicentre, randomized, placebo-controlled safety and efficacy study of imiquimod 5% cream for the treatment of actinic keratoses in kidney, heart, and liver transplant patients. *Br J Dermatol.* 2007;157:25–31.

Figures (large format)

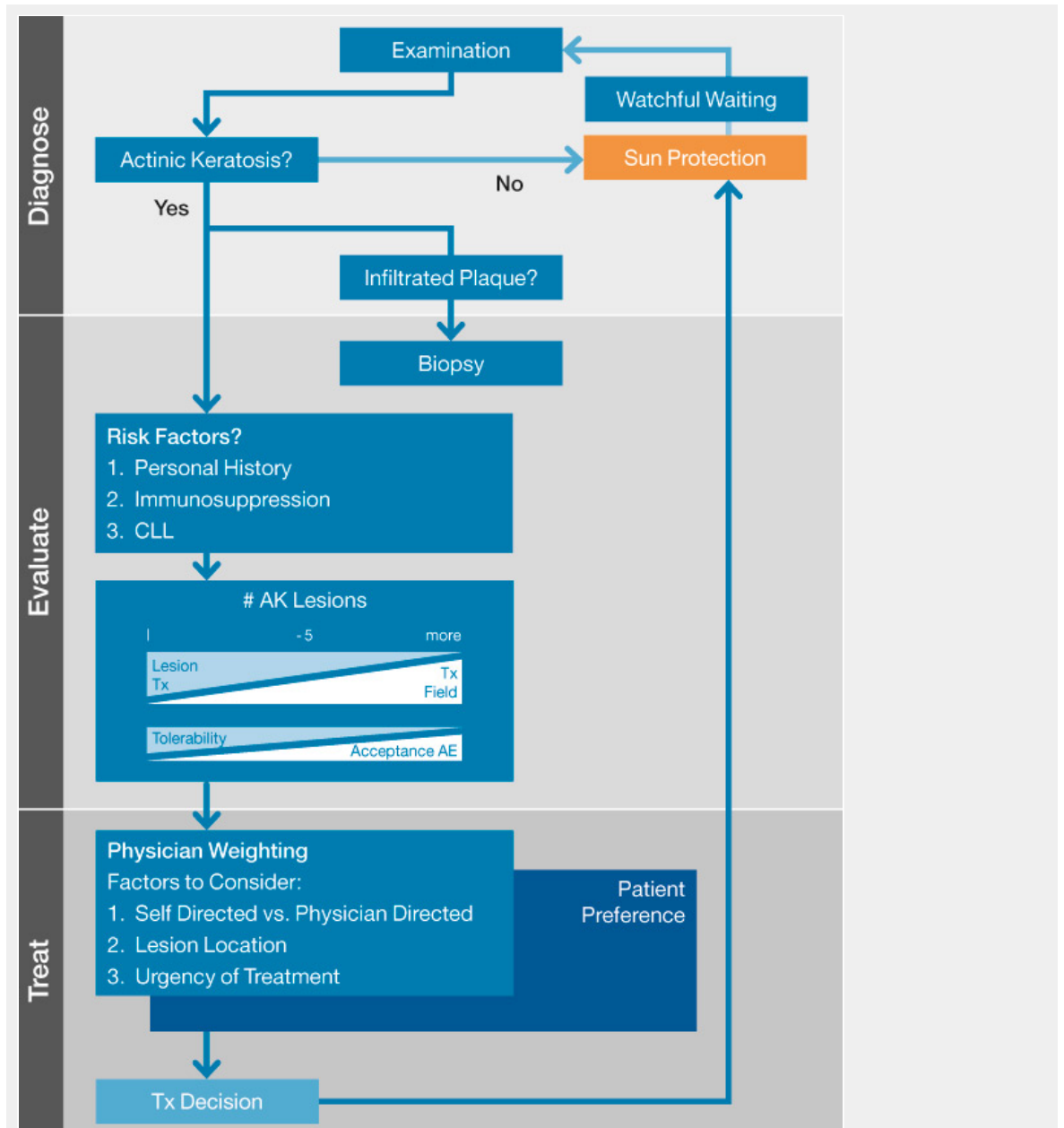
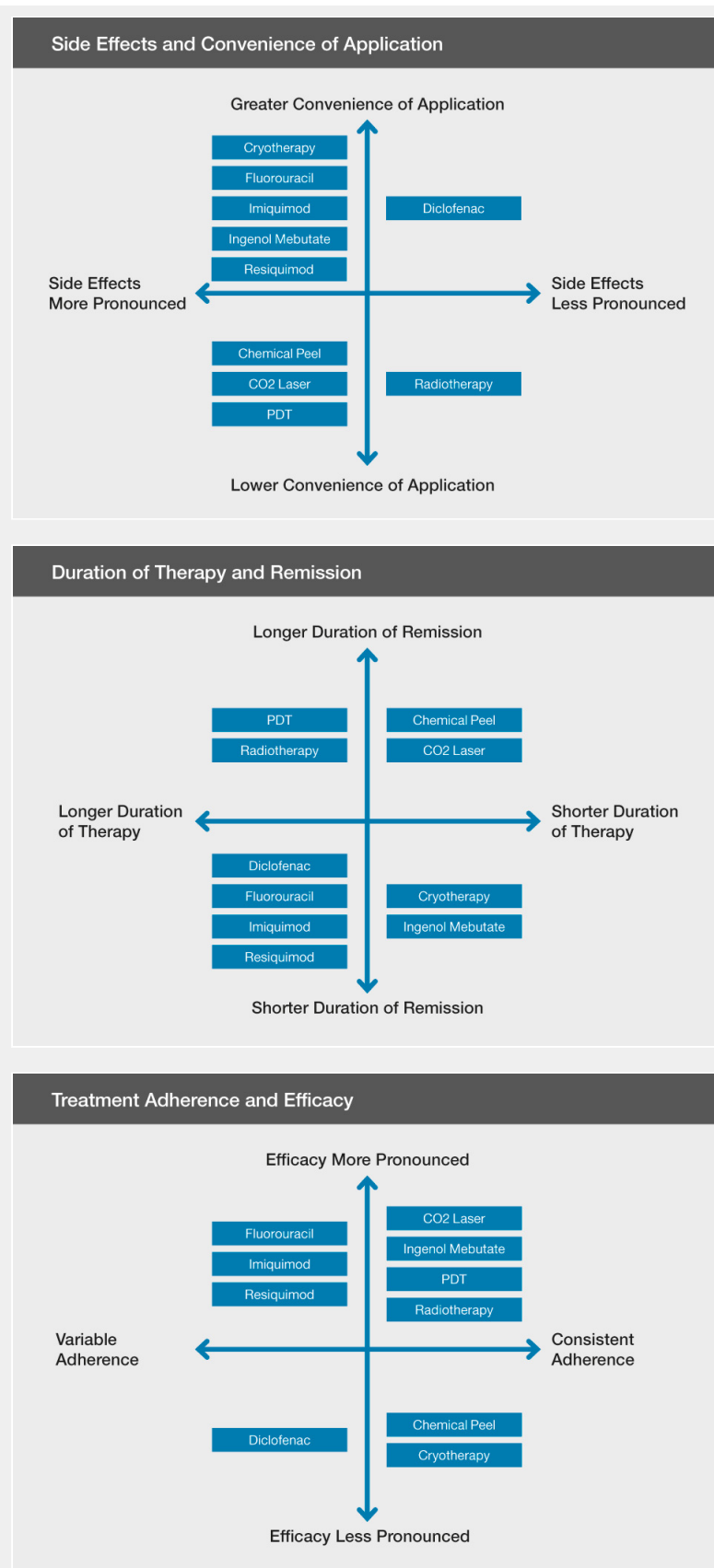


Figure 1

Actinic keratosis and field cancerization treatment algorithm

The algorithm is intended to aid in the treatment decision process for actinic keratosis and field cancerization and is not intended to replace a physician's best judgement on the most appropriate treatment path for each individual patient.



Figures 2A, 2B, 2C:

Summary of treatment-related considerations for actinic keratosis and field cancerization

Treatments have been assessed according to the subjective opinions of the authors based on their collective practical experiences and not necessarily supported by objective data. Treatments are listed in alphabetical order. It is not the intention of the REAKT Working Group to preferentially promote the use of one modality or product over another.