

OPEN

# SPIRONOLACTONE FOR NONRESOLVING CENTRAL SEROUS CHORIORETINOPATHY

## A Randomized Controlled Crossover Study

ELODIE BOUSQUET, MD,\*† TALAL BEYDOUN, MD,\* PIERRE-RAPHAËL ROTHSCHILD, MD,\*†  
CIARA BERGIN, PhD,‡ MIN ZHAO, MD, PhD,† RUI BATISTA, PHARM,D,§  
MARIE-LAURE BRANDELY, PHARM,D,§ BENEDICTE COURAUD,\* NICOLETTE FARMAN, MD, PhD,¶  
ALAIN GAUDRIC, MD, PhD,\*\* FRANÇOIS CHAST, PHARM,D, PhD,§  
FRANCINE BEHAR-COHEN, MD, PhD†‡

**Purpose:** To evaluate the effect of spironolactone, a mineralocorticoid receptor antagonist, for nonresolving central serous chorioretinopathy.

**Methods:** This is a prospective, randomized, double-blinded, placebo-controlled crossover study. Sixteen eyes of 16 patients with central serous chorioretinopathy and persistent subretinal fluid (SRF) for at least 3 months were enrolled. Patients were randomized to receive either spironolactone 50 mg or placebo once a day for 30 days, followed by a washout period of 1 week and then crossed over to either placebo or spironolactone for another 30 days. The primary outcome measure was the changes from baseline in SRF thickness at the apex of the serous retinal detachment. Secondary outcomes included subfoveal choroidal thickness and the ETDRS best-corrected visual acuity.

**Results:** The mean duration of central serous chorioretinopathy before enrollment in study eyes was  $10 \pm 16.9$  months. Crossover data analysis showed a statistically significant reduction in SRF in spironolactone treated eyes as compared with the same eyes under placebo ( $P = 0.04$ ). Secondary analysis on the first period (Day 0–Day 30) showed a significant reduction in subfoveal choroidal thickness in treated eyes as compared with placebo ( $P = 0.02$ ). No significant changes were observed in the best-corrected visual acuity. There were no complications related to treatment observed.

**Conclusion:** In eyes with persistent SRF due to central serous chorioretinopathy, spironolactone significantly reduced both the SRF and the subfoveal choroidal thickness as compared with placebo.

RETINA 35:2505–2515, 2015

Central serous chorioretinopathy (CSC) incidence is estimated at 1 per 10,000,<sup>1</sup> affecting predominantly men (~72–88%).<sup>2,3</sup> Central serous chorioretinopathy is considered chronic when subretinal fluid (SRF) does not reabsorb spontaneously and/or if multifocal recurrent detachments with diffuse retinal pigment epithelium (RPE) alterations are observed.<sup>4</sup> Chronic CSC has been shown to severely impact vision. Choroidal thickness varies as a function of age, axial length, and circadian rhythm.<sup>5</sup> In patients with CSC, pachychoroid (a thick choroid)<sup>6</sup> has been reported not only in the affected eye but also in the fellow eye,<sup>7</sup> which is consistent with bilateral choroidal hyperpermeability.<sup>8,9</sup>

Corticosteroids, that are produced endogenously<sup>10</sup> or that are delivered as therapeutic agents,

have been shown to promote the occurrence and aggravate CSC,<sup>11,12</sup> suggesting that corticoid metabolism may be involved in the disease pathogenicity. On binding to the glucocorticoid receptor or to the mineralocorticoid receptor (MR), glucocorticoids exert different effects. Preclinical studies have shown in the retina and choroid, that the glucocorticoid receptor, MR, and HSD-2 (hydroxysteroid dehydrogenase Type 2) are coexpressed.<sup>13,14</sup> Therefore, glucocorticoid-induced effects may result in part from MR activation in the retina and choroid. Indeed, the activation of MR pathway in rodents with its specific ligand aldosterone or following high dose of glucocorticoids resulted in choroid vessel dilation and leakage, effects that were

shown to be reversible with MR antagonists.<sup>14</sup> Our group has previously identified a molecular target for MR activation in the choroid, namely KCa2.3, which is an endothelial hyperpolarizing calcium-dependent potassium channel involved in vasorelaxation. Mineralocorticoid receptor antagonist reversed the upregulation of KCa2.3 in the choroid demonstrating its local molecular action.<sup>14</sup> Our hypothesis is that excessive occupancy of MR by glucocorticoids and/or excessive MR sensitivity or endogenous activation may increase choroidal thickness and susceptibility to CSC.

Different MR antagonists are available in the market and have been approved for congestive heart failure and for primary hyperaldosteronism. Spironolactone, the oldest drug of this class, can exert hormonal effects at high dose and with prolonged use (>3 months), including gynecomastia, reduced libido, and menstrual disturbance.<sup>15</sup> Eplerenone, with an increased specificity does not induce hormonal effects but has in vivo a 50-fold reduced efficacy on MR blockage.<sup>16</sup> In a previous prospective pilot but uncontrolled study, we treated 13 patients with CSC for 3 months with oral eplerenone. The results showed a significant treatment effect on SRF and central macular thickness.<sup>17</sup> Eplerenone is not available as a medical grade pure substance, such that treatment and placebo can be

manufactured in identical galenic formulation, as is required to conduct a controlled, double-masked prospective study; therefore, spironolactone was chosen for this investigation.

This study set out to evaluate the clinical effect of the MR-antagonist spironolactone in a prospective, double-blinded, randomized placebo-controlled crossover study.

## Methods

### Study Patients

Eligibility criteria included the following: 1) patients aged  $\geq 18$  and  $\leq 70$  years; 2) patients with the best-corrected visual acuity between 20/200 and 20/32; 3) SRF involving the fovea on optical coherence tomography (OCT); 4) the presence of angiographic leakage caused by CSC on fluorescein angiography; 5) visual symptoms and OCT follow-up consistent with CSC for more than 3 months of duration with no spontaneous reduction of SRF (proven on an OCT at least 3 months before entering the study); and 6) women included were required to use oral contraception during the study. Exclusion criteria disqualified the following subjects: 1) previous treatment with photodynamic therapy or anti-VEGF intravitreal injection; 2) any evidence of choroidal neovascularization, polypoidal choroidal vasculopathy, or pseudo vitelliform lesions; 3) history of other macular abnormalities; 4) systemic contraindication for spironolactone treatment: liver or kidney failure, hyperkalemia  $>5.5$  mmol/L, 5) treatment with non steroidal anti-inflammatory or concomitant drugs that increase potassium level; 6) known allergy to the study drug or to lactose or to fluorescein; and 7) pregnancy.

### Study Design

This was a prospective, double-blinded, randomized placebo-controlled crossover study. From January 2012 to October 2012, 16 patients who met the inclusion criteria and consented to partake in the study were enrolled from the Ophthalmology Department of Hôtel Dieu of Paris Hospital, France.

### Ethics Statement

Written informed consent was obtained from all participants. This study was approved by the Paris Centre Ethical Committee on January 7, 2012. It was declared and authorized by AFSSAPS (Food and Drug Administration in France) under identification number # 2011-003046-40a and declared on Clinical Trials.gov Identifier under # NCT01552044 (February 14,

---

From the \*Department of Ophthalmology, Hôtel-Dieu of Paris, Assistance Publique Hôpitaux de Paris, Paris, France, Université Sorbonne Paris Cité; †INSERM U1138, Team 17, Université Sorbonne Paris Cité, Université Pierre et Marie Curie, Centre de Recherche des Cordeliers, Paris, France; ‡Department of Ophthalmology, University of Lausanne, Jules Gonin Ophthalmic Hospital, Fondation Asile des aveugles, Switzerland; §Department of Pharmacy Hôtel-Dieu of Paris, Assistance Publique Hôpitaux de Paris, Université Sorbonne Paris Cité, Paris, France; ¶INSERM, U1138, Team 1, Université René Descartes Sorbonne Paris Cité, Université Pierre et Marie Curie Paris, Centre de Recherche des Cordeliers, Paris, France; and \*\*Department of Ophthalmology, Hôpital Lariboisière, Assistance Publique Hôpitaux de Paris, Université Paris Diderot, Paris, France.

INSERM provided financial support for the statistical analysis and was promoter of the study.

F. Behar-Cohen and N. Farman are inventors on a patent protecting the use of MR antagonists for retinal edema. The patent rights belong to INSERM. None of the remaining authors have any conflicting interests to disclose.

Conception and design: F. Behar-Cohen, F. Chast, M.-L. Brandely, and R. Batista. Analysis and interpretation: F. Behar-Cohen, E. Bousquet, P.-R. Rothschild, A. Gaudric, and M. Zhao. Written/revision/final approval of the article: F. Behar-Cohen, E. Bousquet, C. Bergin, and A. Gaudric. Data collection: F. Behar-Cohen, T. Beydoun, and B. Couraud. Statistical expertise: C. Bergin.

This is an open-access article distributed under the terms of the Creative Commons Attribution-Non Commercial-No Derivatives License 4.0 (CCBY-NC-ND), where it is permissible to download and share the work provided it is properly cited. The work cannot be changed in any way or used commercially.

Reprint requests: Francine Behar-Cohen, MD, PhD, INSERM U1138 eq. 17, Centre de Recherche des Cordeliers, 15, rue de l'École de Médecine, 75006 Paris, France; e-mail: francine.behar@gmail.com

2012). The study was conducted in accordance with the tenets of the Declaration of Helsinki. INSERM (the National Institute for Health and Research in France) has promoted and monitored this study.

### Study Drug

Spirolactone is a steroid with a strong antagonist effect on the MR. At the dosage of 50 mg/day for 30 days utilized within this study protocol, spironolactone is not expected to induce any significant effect on blood pressure nor androgenic or progesterone receptor interference.<sup>18</sup> Tablets containing either the treatment drug of 50 mg spironolactone (Piramal Healthcare UK), or placebo tablet (comprised of lactose) were administered orally during the study period. Tablets had identical galenic presentation; these were prepared by the Department of Pharmacy of Hôtel-Dieu of Paris Hospital.

### Study Protocol

After signing the informed consent, each patient was randomized to one of the two treatment sequences: sequence treatment/placebo (TP) or sequence placebo/treatment (PT). Sequence TP was where patients received spironolactone 50 mg/day for 30 days, then a washout period, where no treatment was administered for 7 days, followed by placebo for 30 days. In the treatment sequence, PT patients received placebo for 30 days, then a washout period for 7 days, followed by spironolactone 50 mg/day for a further 30 days. The duration of the washout period was calculated taking into account that after oral administration, the mean post-steady-state half-life for spironolactone and its active metabolites are 1.4 hours and 16 hours (for spironolactone and canrenone, respectively).<sup>19</sup> After 112 hours, 4.6 days (which corresponds to 7 half-lives), no active spironolactone or active metabolites should be measurable.

The primary end point is reduction in SRF. Based on pilot data, the treatment effect was estimated to be 70  $\mu\text{m}$  on average.<sup>17</sup> The repeatability of measures on SRF has been estimated to be 30  $\mu\text{m}$ . The power calculation was based on the first period of this study (i.e., a parallel study design and two-sample *t*-test). To have 95% power of detecting a reduction in SRF of 40% (at a statistically significant level of  $\alpha = 5\%$ ) between the TP and PT sequences after the first treatment period, 7 patients are required in each group. Allowing for a 10% dropout during follow-up, a total of 16 patients were required. The crossover design has greater power than a parallel design, since each patient acts as their own control. Therefore, 16 patients were sufficient here also.

Randomization of treatment sequence, placebo followed by treatment (PT) or treatment followed by placebo (TP), was assigned by the pharmacist. The randomization was done using online statistical computing web programming ([www.graphpad.com/quickcalcs](http://www.graphpad.com/quickcalcs) or [www.randomization.com](http://www.randomization.com)) to generate the randomization schedule. The labels providing the batch number were placed by the pharmacist and were in line with the Commission Directive 2003/94/EC. Detail of the sequence remained unknown to all members of the trial team until recruitment, data collection, and analysis were complete.

### Baseline and Follow-up Examinations

At Day 0 ( $D_0$ ), the end of the first period ( $D_{30}$ ) and the second period ( $D_{67}$ ), the best-corrected visual acuity using the Early Treatment Diabetic Retinopathy Study charts at 4 m (by certified orthoptist), indocyanin and fluorescein angiography (Heidelberg HRA; Heidelberg Engineering, Heidelberg, Germany), and spectral domain optical coherence tomography (SD-OCT, Spectralis v5.4.7.0; Heidelberg Engineering). Angiography and spectral domain OCT using the Spectralis device were performed at Lariboisière hospital (where this device was available) by certified technicians under A. Gaudric supervision. In addition, SD-OCT (OPKO/OTI, Miami, FL) was also performed at  $D_{-7}$  (screening),  $D_0$  (inclusion),  $D_{30}$ ,  $D_{37}$ , and  $D_{67}$  at Hôtel-Dieu by a certified technician.

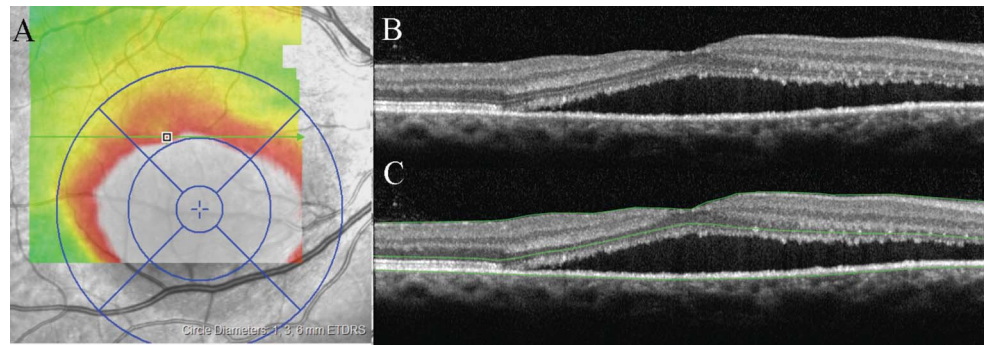
Treatment tolerance was assessed by blood pressure measurements, blood analyses (kaliemia, natremia and creatinine), performed at the study entry,  $D_{30}$  and  $D_{67}$ . The treatment was to be stopped in case of kaliemia increase ( $>5$  mmol/L) or creatinine clearance rate decrease ( $<60$  mL/minute).

### Spectralis Spectral Domain Optical Coherence Tomography Acquisition and Analysis

The scanning protocol included a volume scan centered on the fovea and comprising 25 horizontal B-scans, 240  $\mu\text{m}$  apart covering a  $20^\circ \times 20^\circ$  field. Each B-scan resulted from 11 averaged images. Image analysis was then performed using the commercially available Heidelberg Eye explorer software version 1.7.1.0 (Heidelberg Engineering). The automated segmentation algorithm delineates the internal limiting membrane and the RPE-Bruch layer. The “retinal thickness map” mode was used to center the scan on the point of maximum retinal thickness from baseline images corresponding to the apex of the subretinal detachment (Figure 1A). We collected the automatically generated point center thickness. The upper segmentation line was manually adjusted by 2 trained



**Fig. 1.** OCT segmentation. **A.** ETDRS grid center displaced at the apex of the DSR. **B.** OCT image without segmentation. **C.** OCT image with segmentation at the level of inner limiting membrane, external limiting membrane and RPE.



operators (E.B. and P.-R.R.) to delineate the external limiting membrane (Figure 1, B and C) in 5 B scan using the methodology as described by Tan et al.<sup>20</sup> The SRF thickness was automatically generated by the software after segmentation. Measures from the external limiting membrane to the Bruch layer integrates both SRF and outer segment length and avoiding over estimation of SRF reduction due to outer segment elongation, observed in long-lasting CSC.

Choroid thickness, defined as the distance separating the outer border of the RPE from the hyper-reflective inner surface of the sclera (lamina fusca) can be reproducibly measured using enhanced depth imaging.<sup>21</sup> Cross line scans of 30°, composed of 100 averaged images, across the fovea, were obtained automatically. The procedure was repeated until acceptable quality was achieved. Choroidal thickness was measured at the fovea and at 500  $\mu\text{m}$  nasally and temporally from the fovea.

#### *OPKO Spectral Domain Optical Coherence Tomography Acquisition and Analysis*

All subjects included in the study underwent study measurements by using an OPKO spectral domain OCT/SLO instrument (OPKO Instrumentations). The system provides up to 27,000 A-scans per second with a 5- $\mu\text{m}$  axial resolution. We used the radial lines acquisition protocol after centering the scans on the fovea. Manual measure was performed using the caliper tool from the external limiting membrane to the Bruch layer at the top of SRD by two independent ophthalmologists (F.B.-C. and E.B.). The measures of the two operators were compared if there was a discrepancy of greater than 5%, then the measures were recalculated by both operators. The average of the two measures was used for in the analysis.

#### *Main Outcome Measures*

The primary outcome measure was the change from baseline in SRF thickness (external limiting membrane

to Bruch layer) at the apex of the subretinal detachment evaluated as described above using the Spectralis SD-OCT device.

Secondary outcome measures included change from baseline in SRF thickness evaluated by OPKO SD-OCT, subfoveal, 500  $\mu\text{m}$  temporal and nasal choroidal thickness as measured on enhanced depth imaging Spectralis SD-OCT and best-corrected visual acuity.

#### *Statistical Analysis*

The crossover data were analyzed using the linear mixed fixed-effects model framework. Linear mixed fixed-effects model assumptions (covariance matrix structure, normal distribution of random effects, and residuals) were checked before analysis, using graphical methods and appropriate tests: usual normality tests on random effects and residuals and testing variance-covariance matrix structures. In the crossover trial, since each patient acts as their own control, patient heterogeneity is addressed. For the primary analysis, an analysis of variance table was calculated on the fitted model. The fitted model was the standard model with treatment, and period effects examined as covariants.

The linear model used to analyze the Spectralis SD-OCT data is given in Equation 1. The covariants are given explicitly below. The baseline measure at  $D_0$  was used to recover degrees of freedom for error by adjusting the of estimate within-patient variance as described by Senn (i.e., baseline measures are used to update the estimate of the variability used in the model).<sup>22</sup>  $X$  denotes the ocular characteristic examined, for example, SRF; treatment (TTT) was none, placebo, or spironolactone; period was  $D_0$ ,  $D_{30}$ , or  $D_{67}$ .

$$X \sim \text{ID} + \text{TTT} + \text{Period}. \quad (1)$$

From the OPKO SD-OCT data, a second baseline measure for SRF was available after the washout period, at  $D_{37}$ . With these data, a baseline measurement was available for all end point measures and as such

could be added to the analysis as a covariant to better estimate the within-patient variance (i.e., account for individual trends improving/worsening of the eye due to period not related to treatment).<sup>22</sup> Therefore, a different linear model was examined (Equation 2):  $X$  denotes the ocular characteristic examined; treatment ( $TTT^0$ ): placebo or spironolactone; period  $D_{30}$  or  $D_{67}$ ; and the baseline of the ocular parameter examined ( $B_x$ ): baseline at  $D_0$  or baseline at  $D_{37}$ .

$$X \sim ID + TTT^0 + \text{Period}^0 + B_x. \quad (2)$$

A secondary analysis considering only the first period was performed, measures on the relative difference between  $D_0$  and  $D_{30}$  were used in the analysis to account for patient heterogeneity. These differences were compared between the placebo and the treated groups, using Student's  $t$ -test or Mann-Whitney test, according to the results of the normality tests. Difference between the 2 groups was considered significant for  $P < 0.05$ . Analysis was performed with R Version 2.15.1.<sup>23</sup>

## Results

### Patient Baseline Characteristics

Sixteen eyes of 16 patients met the screening criteria for this study. One patient in the study underwent a dramatic reduction of SRF before Day 0, (Patient 4, SRF 485  $\mu\text{m}$  at  $D_{-90}$ , 450  $\mu\text{m}$  at  $D_{-7}$ , 125  $\mu\text{m}$  at  $D_0$ ); therefore, this patient no longer fulfilled the inclusion criteria and was excluded before commencing this trial; the analysis of data from 15 patients are reported, 8 patients in the TP sequence and 7 in the PT sequence.

Nine patients had bilateral disease and 14 patients had multiple RPE alterations in at least one eye. In all

bilateral cases, only one eye met the inclusion criteria. Characteristics of the study eyes are summarized in Table 1. The mean duration of CSC before enrollment in study eyes was  $10 \pm 16.9$  months. The mean age of the patients was  $46.5 \pm 8$  years (range, 37–58 years) and 80% were male. Five patients (33.3%) reported a history of steroid intake. The mean SRF thickness at the top of SRD was  $344 \pm 103 \mu\text{m}$ , and the mean subfoveal choroidal thickness (SFCT) was  $417 \pm 117 \mu\text{m}$ . There was no statistical difference in patient baseline characteristics between the 2 groups (Table 1). However, both SFCT and temporal thickness at 500  $\mu\text{m}$  were borderline significant ( $P = 0.07$ ; Table 1).

### Crossover Analysis Using Spectralis Spectral Domain Optical Coherence Tomography Data

Crossover analysis showed that there were no significant period effect ( $P = 0.31$ ; Table 2), whereas there was a significant treatment effect observed ( $P = 0.04$ ) with respect to reduction in SRF thickness, showing the significant effect of spironolactone as compared with placebo. Figure 2A shows the comparisons of SRF changes (from Spectralis data) in the 2 sequence treatment groups and during the 2 periods (Months 1 and 2) and the clear crossing effect between the 2 periods (Months 1 and 2). Although there was a significant treatment effect observed on choroidal thickness parameters ( $P = 0.01$  nasal 500  $\mu\text{m}$ ), there was also a significant period and carryover effect observed on ( $P = 0.04$ , carryover effect SFCT;  $P = 0.03$ ; period effect temporal 500  $\mu\text{m}$  choroidal thickness).

### First Period Analysis

Since there was evidence of some carryover effects on choroidal thickness in the crossover analysis, supplementary analysis of the first period has also been

Table 1. Baseline Characteristics of the Study Population

Baseline Characteristics	Full Group (n = 15)	TP Sequence (n = 8)	PT Sequence (n = 7)	P-value
Gender, males (%)	12 (80)	7 (87.5)	5 (71.4)	0.6*
Age, mean ( $\pm$ SD) years	46.5 ( $\pm$ 8)	48 ( $\pm$ 8.9)	44.7 ( $\pm$ 6.4)	0.5**
Previous steroids, n (%)	5 (33.3)	3 (37.5)	2 (28.6)	1*
Duration symptoms, mean ( $\pm$ SD) month	10 ( $\pm$ 16.9)	12.3 ( $\pm$ 22.6)	7.4 ( $\pm$ 4.1)	0.4*
Visual acuity ETDRS, mean ( $\pm$ SD) letter	73.7 ( $\pm$ 9.8)	74.3 ( $\pm$ 10.9)	73.1 ( $\pm$ 9.4)	0.8***
OCT Spectralis baseline measures				
SRF ELM-Bruch thickness, $\mu\text{m}$	344 ( $\pm$ 103)	348 ( $\pm$ 125)	340 ( $\pm$ 87)	0.88**
SFCT, $\mu\text{m}$	417 ( $\pm$ 117)	358 ( $\pm$ 67)	468 ( $\pm$ 131)	0.07**
500 $\mu\text{m}$ nasal choroid thickness, $\mu\text{m}$	412 ( $\pm$ 110)	372 ( $\pm$ 89)	447 ( $\pm$ 120)	0.20**
500 $\mu\text{m}$ temporal choroid thickness, $\mu\text{m}$	404 ( $\pm$ 115)	348 ( $\pm$ 62)	453 ( $\pm$ 131)	0.07**
OCT OPKO baseline measures				
SRF thickness, $\mu\text{m}$	348 ( $\pm$ 101)	349 ( $\pm$ 100)	348 ( $\pm$ 112)	0.99**
Macular thickness, $\text{mm}^3$	9.9 ( $\pm$ 1.9)	9.8 ( $\pm$ 1.2)	9.9 ( $\pm$ 2.5)	0.98

ETDRS, Early Treatment Diabetic Retinopathy Study; ELM, external limiting membrane.

\*Fisher's exact test, \*\*student  $t$ -test, \*\*\*Wilcoxon non-paired test.

Table 2. Crossover Analysis of OCT Data

	P-values of associated anova analysis Treatment Effect	Period Effect
Spectralis data		
SRF ELM-Bruch thickness, $\mu\text{m}$	<b>0.04</b>	0.31
Choroidal thickness, $\mu\text{m}$		
Sub foveal	<b>&lt;0.01</b>	0.06
Nasal 500 $\mu\text{m}$	<b>&lt;0.02</b>	0.87
Temporal 500 $\mu\text{m}$	0.10	0.03
Opko data		
SRF ELM-Bruch thickness, $\mu\text{m}$	<b>0.04</b>	0.41

ELM, external limiting membrane; ILM, inner limiting membrane.

reported. A significant reduction in the SFCT was observed in the treatment group, where SFCT reduced by 6% in the TP sequence while it increased by 4% in the TP sequence ( $P < 0.02$ , Figure 2C; Table 3).

In addition, a first period analysis was also performed on SRF thickness as measured on Spectralis and on OPKO devices. As shown on Table 3, the SRF thickness was significantly reduced in the TP as compared with the PT with more than 30% of change from baseline.

*Crossover Analysis on Additional Time Point Measures Using OPKO Spectral Domain Optical Coherence Tomography Data*

No carryover effects were observed in the SRF measures as measured with the OPKO OCT device.

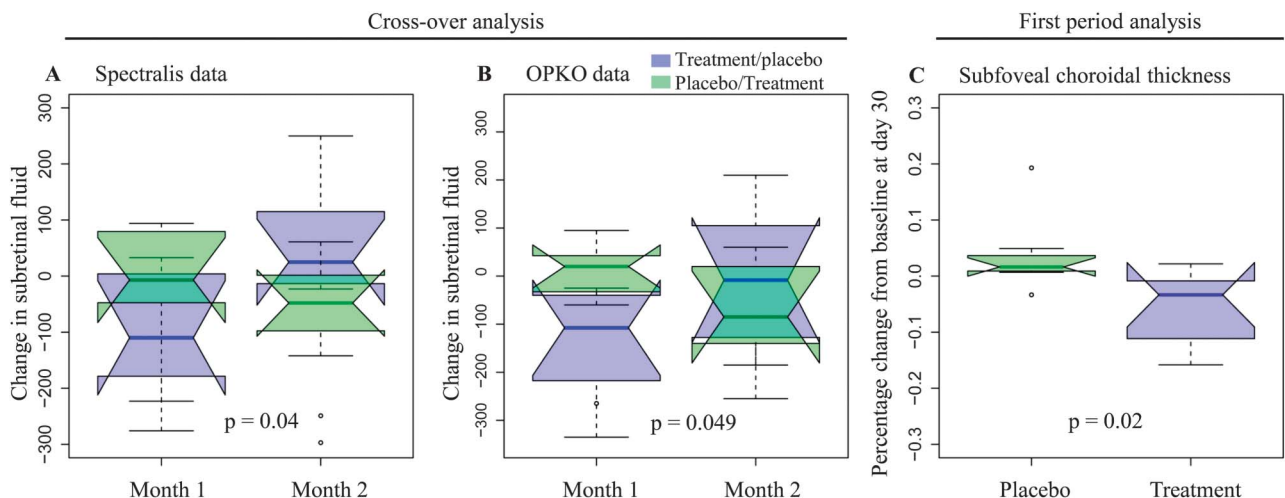
The crossover analysis on OPKO data confirmed the results observed in the Spectralis measurements demonstrating no significant period effect ( $P = 0.41$ ; Table 2) in the presence of a significant treatment effect ( $P = 0.04$ ) with respect to the reduction in SRF. Figure 2B represents the comparison of SRF changes (from OPKO data) in the 2 sequence treatment groups and during the 2 periods and the clear crossing effect between the 2 periods (Months 1 and 2).

*Visual Acuity Analysis*

The median ETDRS BVCA at baseline was 76 letters with an interquartile range of 71 to 81 letters. The treatment did improve the best-corrected visual acuity in the TP sequence after the first period (74.2 letters at  $D_0$ , 77.4 letters at  $D_{30}$ ), whereas the PT sequence showed no change (73.1 letters at  $D_0$ , 72.6 at  $D_{30}$ ), but this improvement did not reach statistical significance ( $P > 0.30$ ) (Table 3). Directly after treatment in both sequences ( $D_{30}$  in the TP sequence and  $D_{67}$  in the PT sequence), median ETDRS BVCA increased to 78 letters with an interquartile range of 74 to 80 letters. This was not a statistically significant difference ( $P = 0.48$ , paired Wilcoxon’s test).

*Angiographic and Optical Coherence Tomography Findings*

Most patients followed the expected treatment trajectories of switch on response to treatment and the switch off response when treatment was stopped. The majority of eyes (67%; 10/15) experienced a reduction in both retinal and choroidal thickness



**Fig. 2.** **A.** Relative changes in SRF thickness measured from external limiting membrane (ELM) to Bruch membrane with Spectralis OCT. The spironolactone effect was significant against placebo ( $P = 0.04$ ). **B.** Relative changes in SRF thickness measured from ELM to Bruch membrane with OPKO OCT. The significant treatment effect is confirmed ( $P = 0.049$ ). **C.** Relative changes in choroidal thickness during the first period. A significant decrease of SFCT is observed in spironolactone group as compared with placebo group ( $P = 0.02$ ). For each group, at each time point, the data have been summarized using box and whisker plots, the upper and lower 95% CIs (confidence interval) are marked with the whiskers, the box represents the interquartile range, and the median is represented by the bold horizontal line bisecting the box.



Table 3. First Period Analysis

	Mean Change From Baseline		Mean % Change From Baseline		<i>P</i> -value: Wilcoxon Nonpaired Test
	PT	TP	PT	TP	
Spectralis data					
SRF ELM-Bruch thickness, $\mu\text{m}$	-10.29	-101.50	-3.9	-34.5	<0.05
Choroidal thickness, $\mu\text{m}$					
Sub foveal	13.9	-28.6	3.8	-5.5	<0.02
Nasal 500 $\mu\text{m}$	-4.7	-18.9	-0.2	-4.3	>0.26
Temporal 500 $\mu\text{m}$	3.7	-17.0	0.2	-3.5	>0.16
OPKO data					
SRF ELM-Bruch thickness, $\mu\text{m}$	-18.57	-136.25	-0.8	-38.2	<0.03
Visual acuity measures					
BCVA (increase in letters)	-0.6	3.14	-0.6	4.7%	>0.30

ELM, external limiting membrane.

when under treatment (TP sequence at D<sub>30</sub> 5/8eyes; PT sequence at D<sub>67</sub> 5/7eyes).

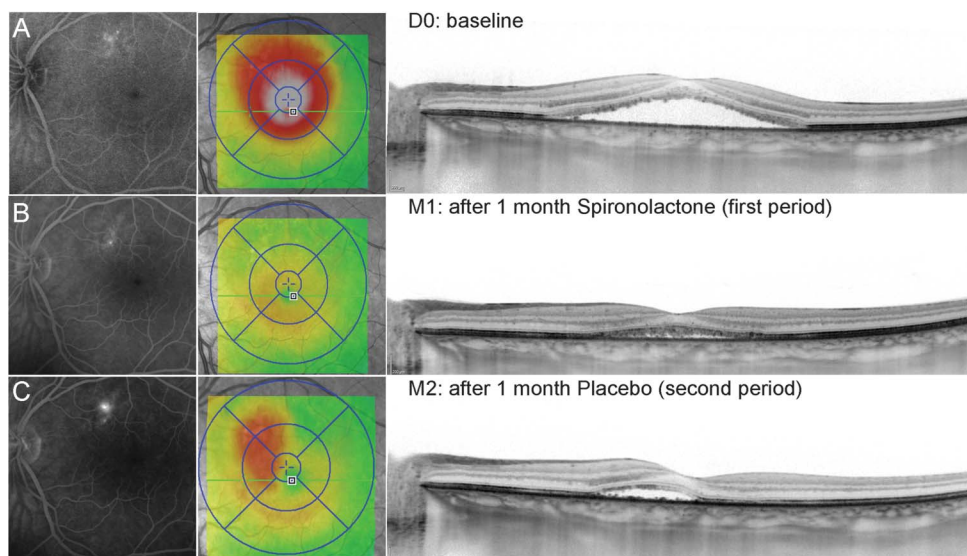
#### *In the Sequence Treatment/Placebo*

The immediate on-off effect of the treatment was observed in four of the eight patients in this sequence. An example of this was Patient 1, this patient presented with CSC 6 months after their primary episode, this second episode showed no resolution of SRF for 4 months (Figure 3A). After 30 days of spironolactone (M1), SRF had completely resolved (Figure 3B), however, after switching to placebo for 30 days, the SRF had reformed presenting with increased fluorescein leakage at the initial RPE leak site (Figure 3C). The off effect can be disguised by a carryover effect; this was observed in three patients. For example Patient 6 presented with bilateral disease as shown on autofluorescent images (Figure 4A) and 2 active RPE leaks were observed

(Figure 4B). Central serous chorioretinopathy persisted for 3.5 months before enrollment here after 30 days of spironolactone, SFCT decreased from 610  $\mu\text{m}$  to 548  $\mu\text{m}$  and SRF had largely resolved with some segments remaining elongated (Figure 4, B and C). The following while under placebo, the anatomical structure of the fovea continued to normalize although SFCT returned to 608  $\mu\text{m}$  (Figure 4D).

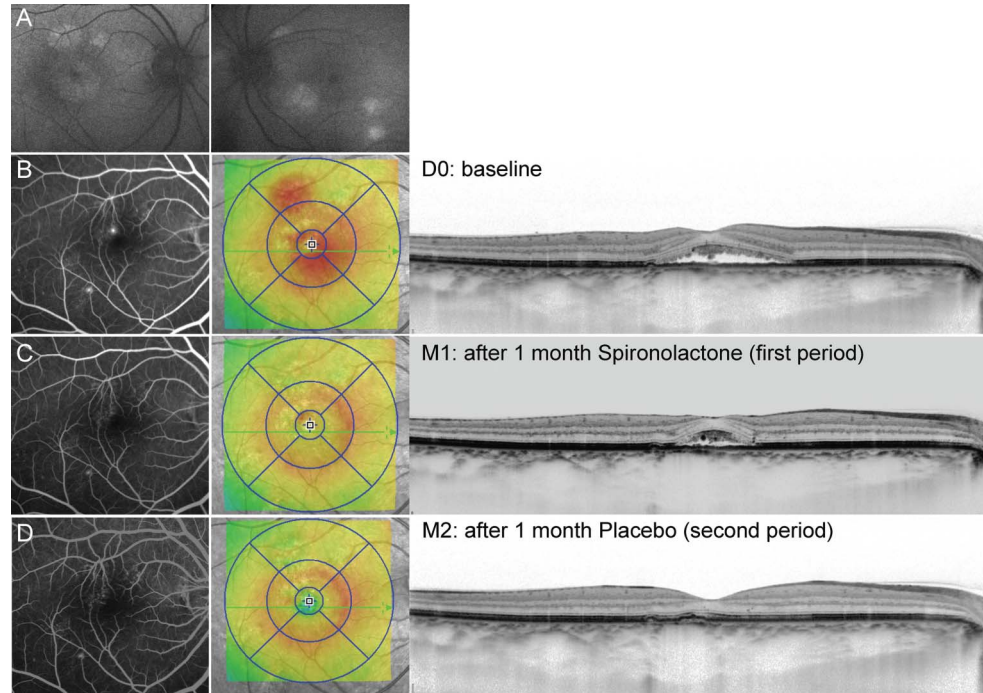
#### *In the Sequence Placebo/Treatment*

The five of the seven of eyes in the PT sequence showed the expected off/on response. Patient 8 for example presented with history of CSC episodes in both eyes and a persistent CSC for more than 6 months with a faint RPE leak (Figure 5A). Under the first placebo period, no change was observed (Figure 5B), followed by a significant improvement on D<sub>67</sub> after 1 month of spironolactone, with reduction



**Fig. 3.** Patient 1 treated first by spironolactone and presented a decrease of SRF at 1 month as compared with Day 0 (A and B). After a 7-day washout period, he was treated during 1 month by placebo and the SRF increased (C). For each time point, fluorescein angiography images taken at late stage (5 minutes) (left panel) are shown, together with the ETDRS grid (middle panel) and an enhanced depth imaging scan (right panel).

**Fig. 4.** Follow-up of Patient 6 treated with spironolactone on the first period. Autofluorescent images of both eyes show bilateral disease (A). After 1 month of spironolactone, the SRF almost completely resolved and decreased intensity of focal leaks was observed on fluorescein angiography (B and C). Under placebo for a month, retinal detachment completely resolved (D). For each time point, fluorescein angiography images taken at late stage (5 minutes) (left panel) are shown, together with the ETDRS grid (middle panel) and an enhanced depth imaging scan (right panel).



of both SRF and leakage on fluorescein angiography (Figure 5C); likewise, subfoveal thickness did not change from D<sub>0</sub> to D<sub>30</sub> (460  $\mu$ m to 464  $\mu$ m) but decreased after 30 days of spironolactone treatment (D<sub>67</sub> = 419  $\mu$ m). There were 2 eyes, in which placebo treatment coincided with a large reduction of SRF, so while the choroidal thickness reduced in these eyes during D<sub>67</sub>, the retinal thickness increased marginally.

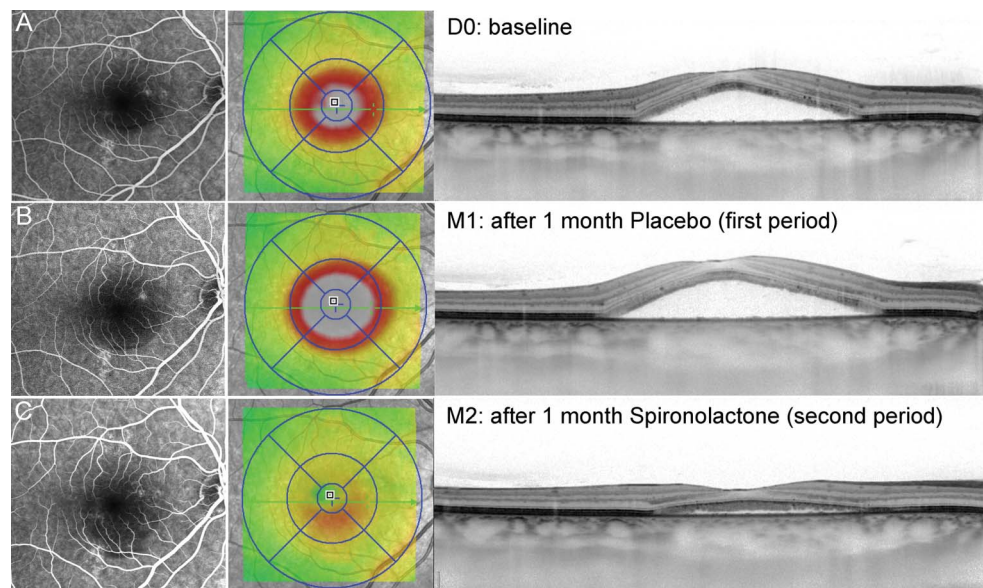
Patient 2 is one of the 3 women of the study, presenting with a long lasting CSC (>1 year) and several RPE leaky points (Figure 6A). She

showed minimal improvement under placebo at M1 (Figure 6B) and slight SRF increase after 1 month of spironolactone treatment (Figure 6C). She is representative of absence of response to treatment as observed in another patient of the study.

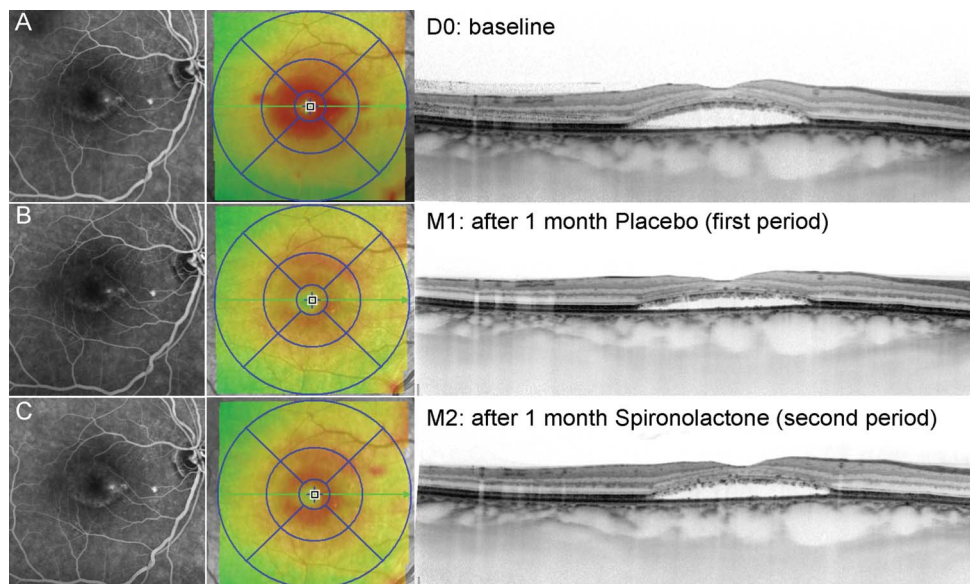
*Safety*

None of the patients experienced any severe side effects from the treatment; in particular, no protocol violations occurred due to adverse side effect, as blood

**Fig. 5.** Follow-up of Patient 8 treated with placebo on the first period. Under the first placebo period, no change was observed (A and B), followed by a significant improvement on D<sub>67</sub> after 1 month of spironolactone, with reduction of SRF and leakage on fluorescein angiography (C). For each time point, fluorescein angiography images taken at late stage (5 minutes) (left panel) are shown, together with the ETDRS grid (middle panel) and an enhanced depth imaging scan (right panel).







**Fig. 6.** Follow-up of Patient 2, treated with placebo on the first period. She showed a decrease of SRF under placebo at D<sub>30</sub> (A and B) and a slight SRF increase after 1 month of spironolactone treatment (C). For each time point, fluorescein angiography images taken at late stage (5 minutes) (left panel) are shown, together with the ETDRS grid (middle panel) and an enhanced depth imaging scan (right panel).

pressure and blood analyses (kaliemia and creatinine clearance) remained in the normal range for all patients.

### Discussion

Although several medical treatments have been proposed for persistent CSC,<sup>24,25</sup> very few controlled studies have evaluated medical treatment modalities for this condition. Based on the observed association of CSC with corticosteroid exposure, mifepristone, a specific glucocorticoid antagonist has been evaluated for 12 weeks against placebo and showed potential effects but with a low tolerance.<sup>26</sup> Taking into account the high endogenous fluctuation of this disease and the strong psychological impact in its evolution, it is clear that no benefit of a medical treatment can be established without a placebo-controlled study. Having previously found encouraging results with oral eplerenone on persistent SRF in patient with CSC,<sup>17</sup> the purpose of this study was to evaluate the effect of another MR antagonist spironolactone administered orally, against placebo on SRF in nonresolving CSC. This study was designed to evaluate the optimal treatment conditions (regimen, duration, dose) but provide evidence of the potential biological effect of MR antagonist on SRF. The crossover study design to reduces confounding covariates because each crossover patient serves as his or her own control.

The results demonstrated a significant reduction of SRF in treated eyes. The analysis on retinal thickness and SRF on measures taken with the two SD-OCT devices, Spectralis and OPKO devices, detected no

significant carryover or period effects in the presence of a statistically significant treatment effect on SRF. However, there were significant carryover effects observed in choroidal thickness. In the presence of these carryover effects, a subanalysis of the data from only the first period (D<sub>0</sub>–D<sub>30</sub>) of this trial (similar to a randomized, double blinded, parallel clinical trial) reaffirmed the significant treatment effect of spironolactone on SFCT, SRF, and retinal thickness.

The pharmacokinetics of spironolactone and its active metabolites (canrenone) showed that the treatment drug had a half-live inferior to 7 hours.<sup>27</sup> Given the 7-day washout period used here, the significant carryover effects observed in choroidal thickness cannot be attributed directly to the active drug. These carryover effects may be due to secondary biological events after spironolactone treatment. As such, future studies should consider such possible biological effects in terms of study design. In addition, there was a borderline significant difference observed in the baselines measures of choroidal thickness between the TP sequence and the PT sequence groups. This may have contributed to the observed carryover effect. A larger sample would have reduced the likelihood of such an imbalance occurring in a randomized trial.

The available data indicates that other contributory factors could induce RPE leaks; since in most study patients, both eyes presented with a dilated choroid yet CSC was monocular. Whether MR antagonists have an effect on these possible additional factors remains to be explored. In the field of vascular diseases, MR overactivation is a recognized pathogenic factor mediating endothelial dysfunction, vascular inflammation, and remodeling; furthermore, it is

recognized that MR antagonists reverse these effects.<sup>28</sup> In our experimental studies, we have identified KCa2.3 as a potential molecular target of MR activation in the choroid. There are other potential molecular targets that are regulated by MR/glucocorticoid receptor complexes, and there may be additional potential therapeutic pathways.

The trial design and the short treatment period were chosen to further demonstrate the treatment effect since recurrence after treatment withdrawal is also supportive evidence. Clinically, the strong recurrence observed in some cases after 1 month of treatment indicates that either more prolonged use or ongoing treatment is required to maintain the absence of SRF in these eyes. However, since the MR antagonists used have low toxicity and tolerable adverse side effects, prolonged use of these treatments should not be a limiting factor.

No statistically significant changes were observed in the visual acuity, this is likely related to the small sample size (a sample of >100 eyes would be required to detect a change of 3 letters between the groups) and limitations on achievable visual acuity recovery due to the high baseline BVCA (>70 letters in 12 of the 15 cases enrolled).

The optimal dose or duration of spironolactone required to treat the patient will be the subject of further study. Recent preclinical studies have indicated that females are less sensitive to the effects of spironolactone than men, and that there are racial differences in spironolactone sensitivity (with Afro-American being less sensitive),<sup>28,29</sup> which indicates that further dose–response studies are required. Also, since spironolactone is a target of efflux protein, its ocular penetration might therefore be reduced when outer retinal barrier is restored, suggesting that oral administration may not be optimal for long-term treatment therefore, alternative delivery pathways also require investigation.

The limitations of this study are the nonoptimal dosage per patient, the small sample size, the short treatment period, and the unforeseen carryover effect in choroidal thickness from M1 into M2. The non-optimal dosage per patient may be correlated with the different treatment response observed between patients and with reduced efficacy. The short treatment period may have limited the treatment efficacy in patients with more advanced/prolonged disease. The estimation of the washout period was based on the half-life of the drug; however, since significant carryover effects were observed in choroidal thickness of these patients, this would suggest that the washout period was not sufficient to study this parameter using the crossover design. Future studies should select more restricted

phenotypic characteristics in addition to SRF duration to study a more homogenous population.

Although very large sample sizes are required to demonstrate equivalence (less than 5% difference) on parameters with poor repeatability (e.g., visual acuity), this study was designed to detect a large treatment effect (>40%) using an objective scale with good repeatability (OCT). This translated into small number of patients being required to attain the same degree of statistical power. A statistically significant treatment effect was observed, whereas in some parameters, it was marginal, considering the sample size, this indicates a very large treatment effect. As with all clinical trials, there is a low probability that these results have occurred randomly, however, trials with small sample sizes are more vulnerable to bias and random effects than those with larger samples. These results should therefore be verified at other centers, and separate research groups.

In conclusion, this study aimed to validate the hypothesis, deriving from our experimental preclinical work, that MR antagonists influence SRF and choroid thickness in CSC. Other studies are now required to confirm these results, to determine the optimal treatment dose and duration, and to evaluate clinical factors predicting response to MR antagonists. Other MR antagonists, under development, and/or other routes of administration could also be proposed for optimized therapeutic index.

**Key words:** central serous chorioretinopathy, choroidal thickness, choroidal vessels, mineralocorticoid receptor, spironolactone, treatment.

## References

1. Kitzmann AS, Pulido JS, Diehl NN, et al. The incidence of central serous chorioretinopathy in Olmsted County, Minnesota, 1980-2002. *Ophthalmology* 2008;115:169-173.
2. Wang M, Munch IC, Hasler PW, et al. Central serous chorioretinopathy. *Acta Ophthalmol* 2008;86:126-145.
3. Liew G, Quin G, Gillies M, Fraser-Bell S. Central serous chorioretinopathy: a review of epidemiology and pathophysiology. *Clin Experiment Ophthalmol* 2013;141:201-214.
4. Spaide RF, Campeas L, Haas A, et al. Central serous chorioretinopathy in younger and older adults. *Ophthalmology* 1996;103:2070-2079.
5. Brown JS, Flitcroft DI, Ying G, et al. In vivo human choroidal thickness measurements: evidence for diurnal fluctuations. *Invest Ophthalmol Vis Sci* 2009;50:5-12.
6. Warrow DJ, Hoang QV, Freund KB. Pachychoroid pigment epitheliopathy. *Retina* 2013;33:1659-1672.
7. Kim YT, Kang SW, Bai KH. Choroidal thickness in both eyes of patients with unilaterally active central serous chorioretinopathy. *Eye (Lond)* 2011;25:1635-1640.
8. Spaide RF, Hall L, Haas A, et al. Indocyanine green videoangiography of older patients with central serous chorioretinopathy. *Retina* 1996;16:203-213.

9. Iida T, Kishi S, Hagimura N, Shimizu K. Persistent and bilateral choroidal vascular abnormalities in central serous chorioretinopathy. *Retina* 1999;19:508–512.
10. Bouzas EA, Karadimas P, Pournaras CJ. Central serous chorioretinopathy and glucocorticoids. *Surv Ophthalmol* 2002;47:431–448.
11. Haimovici R, Koh S, Gagnon DR, et al. Risk factors for central serous chorioretinopathy: a case-control study. *Ophthalmology* 2004;111:244–249.
12. Tittl MK, Spaide RF, Wong D, et al. Systemic findings associated with central serous chorioretinopathy. *Am J Ophthalmol* 1999;128:63–68.
13. Zhao M, Valamanesh F, Celerier I, et al. The neuroretina is a novel mineralocorticoid target: aldosterone up-regulates ion and water channels in Müller glial cells. *FASEB J* 2010;24:3405–3415.
14. Zhao M, Célérier I, Bousquet E, et al. Mineralocorticoid receptor is involved in rat and human ocular chorioretinopathy. *J Clin Invest* 2012;122:2672–2679.
15. Delyani JA. Mineralocorticoid receptor antagonists: the evolution of utility and pharmacology. *Kidney Int* 2000;57:1408–1411.
16. De Gasparo M, Joss U, Ramjoué HP, et al. Three new epoxy-spirolactone derivatives: characterization in vivo and in vitro. *J Pharmacol Exp Ther* 1987;240:650–656.
17. Bousquet E, Beydoun T, Zhao M, et al. Mineralocorticoid receptor antagonism in the treatment of chronic central serous chorioretinopathy: a pilot study. *Retina* 2013;33:2096–2102.
18. Guyonnet J, Elliott J, Kaltsatos V. A preclinical pharmacokinetic and pharmacodynamic approach to determine a dose of spironolactone for treatment of congestive heart failure in dog. *J Vet Pharmacol Ther* 2010;33:260–267.
19. Krause W, Karras J, Seifert W. Pharmacokinetics of canrenone after oral administration of spironolactone and intravenous injection of canrenoate-K in healthy man. *Eur J Clin Pharmacol* 1983;25:449–453.
20. Tan CSH, Li KZ, Lim TH. A novel technique of adjusting segmentation boundary layers to achieve comparability of retinal thickness and volumes between spectral domain and time domain optical coherence tomography. *Invest Ophthalmol Vis Sci* 2012;53:5515–5519.
21. Margolis R, Spaide RF. A pilot study of enhanced depth imaging optical coherence tomography of the choroid in normal eyes. *Am J Ophthalmol* 2009;147:811–815.
22. Senn S. Cross-over trials in clinical research. *Statistics in practice*. 2nd Edition. Wiley 2002 pg 1–140.
23. R Core Team. *A Language and Environment for Statistical Computing*. Vienna, Austria: Foundation for Statistical Computing; 2012; ISBN 3-900051-07-0. Available at: <http://www.R-project.org/>. Accessed January 6, 2014.
24. Forooghian F, Meleth AD, Cukras C, et al. Finasteride for chronic central serous chorioretinopathy. *Retina* 2011;31:766–771.
25. Rahbani-Nobar MB, Javadzadeh A, Ghojzadeh L, et al. The effect of *Helicobacter pylori* treatment on remission of idiopathic central serous chorioretinopathy. *Mol Vis* 2011;17:99–103.
26. Nielsen JS, Jampol LM. Oral mifepristone for chronic central serous chorioretinopathy. *Retina* 2011;31:1928–1936.
27. Gardiner P, Schrode K, Quinlan D, et al. Spironolactone metabolism: steady-state serum levels of the sulfur-containing metabolites. *J Clin Pharmacol* 1989;29:342–347.
28. McGraw AP, McCurley A, Preston IR, Jaffe IZ. Mineralocorticoid receptors in vascular disease: connecting molecular pathways to clinical implications. *Curr Atheroscler Rep* 2013;15:340.
29. Vardeny O, Cavallari LH, Claggett B, et al. Race influences the safety and efficacy of spironolactone in severe heart failure. *Circ Heart Fail* 2013;6:970–976.
30. Michaelis M, Hofmann PJ, Götz F, et al. Sex-specific effects of spironolactone on blood pressure in gonadectomized male and female Wistar rats. *Horm Metab Res* 2012;44:291–295.