

Sandrine de Ribaupierre
Kathleen Meagher-Villemure
Siviero Agazzi
Benedict Rilliet

Meningeal solitary fibrous tumour in a child

Received: 7 July 2005
Revised: 22 July 2005
Published online: 14 January 2006
© Springer-Verlag 2006

S. de Ribaupierre (✉) · S. Agazzi ·
B. Rilliet
Neurosurgery Department,
Centre Hospitalier Universitaire
Vaudois (CHUV),
Rue du Bugnon,
1011 Lausanne, Switzerland
e-mail: s_derib@hotmail.com

K. Meagher-Villemure
Institut Universitaire de Pathologie,
Centre Hospitalier
Universitaire Vaudois,
Lausanne, Switzerland

Abstract *Introduction:* Meningeal solitary fibrous tumour is a relatively recent pathological entity that has rarely been described in children.

With radiological techniques, it cannot be distinguished from meningiomas, and the diagnosis has to be confirmed histologically. *Case report:* We discuss the possible histogenesis of this tumour and the need for recognizing this lesion as a separate entity. We report the case of a 12-year-old boy who developed a meningeal solitary fibrous tumour; the main clinical symptoms were progressive headaches for a long period

and recent transient hemiparesis.

Conclusion: This child presents an uneventful evolution without additional therapy 3.5 years after surgery.

Keywords Solitary fibrous tumour · Pediatric neurosurgery

Introduction

Meningeal solitary fibrous tumour is a relatively recent pathological entity that can occur in every organ of the body. The first description of a meningeal location was recorded in 1996 by Carneiro et al. [1]. To our knowledge, already 64 cases found in the central nervous system have been reported but only two presentations within childhood [2–4]. The diagnosis of this tumour is mainly done by histological examination of the surgical material, as the radiological investigation does not reveal any specific criteria to differentiate it from a meningioma [5]. We report the case of a 12-year-old boy who developed such a tumour in the meninges.

Materials and methods

A 12-year-old boy known to have bilateral frontal migraines for a few years progressively developed a transient right hemiparesis associated with these migraines.

The physical examination was normal except for hyperreflexia with clonus of the lower extremities. An EEG performed was normal. A cerebral MRI was motivated after the child presented a stronger episode including dysarthria and a transient facial paresis that lasted for 2 h. The radiological examination revealed an extra-axial left parietal mass in continuity with the falx, the superior sagittal sinus and the dural convexity (Fig. 1). The lesion was surrounded by a significant perilesional oedema. The cerebral CT scan did not reveal any other feature, in particular, no calcification. A spinal MRI was interpreted within normal limit.

At surgery, a parietal craniotomy was performed. It revealed an extra-axial mass attached to the falx, well separated from the parenchyma anteriorly but strongly adherent to the brain posteriorly. Total resection was achieved. The surgical material was processed for routine histopathological study, immunohistochemistry, electron microscopy and cytometry.

The postoperative course was uneventful, and the child returned home 6 days later in a good neurological status.

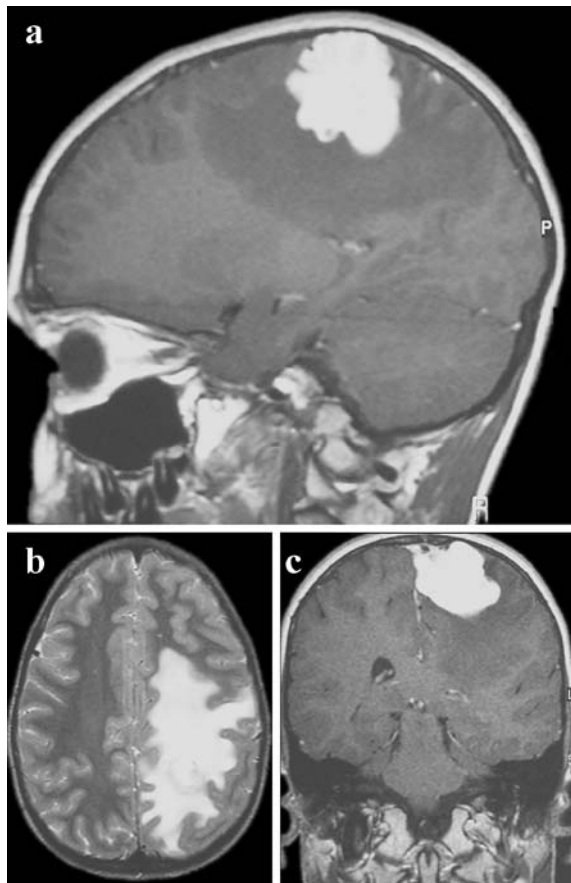


Fig. 1 **a** Sagittal T1-weighted image with gadolinium showing a homogenous enhancing lesion, with important perilesional oedema. **b** Axial T2-weighted image demonstrating the importance of the perilesional oedema. **c** Coronal T1-weighted image with gadolinium, where the convexity dural attachment can be noted

The child is still doing well 3.5 years later, with no further symptom and no recurrence seen in his latest MRI.

Pathology

The main surgical material received for histological examination consisted of a piece of roundish beige tissue, partly covered on one side by dura. It measures 2.5×2 cm and had a multilobulated configuration (Fig. 2a). On cross-section, the tissue was firm and appeared fascicular. On frozen section, the tumour was reported as compatible with a meningioma. On study of the permanent section, however, the tumour revealed a more complex type of growth. It was made by a proliferation of small cells with regular oval nuclei and small fusiform or fibrillary cytoplasm. Different areas were seen: some with larger cells arranged in sheets in which thick bands of collagen were forming stellate or large spider configuration (Fig. 2b). Other areas were more cellular, arranged in nodular pattern in which numerous small vessels were bordered by one layer of endothelial cells (Fig. 2c).

These areas reflected a hemangiopericytoma pattern. Other areas had a more myxoid pattern in which the cells were aligned in small rows suggesting a chondroid or a chordoid aspect. There were no significant mitotic figures seen, and no necrosis was visualized. On immunohistochemistry, the tumour cells were strongly positive for vimentin and desmin, negative for the epithelial markers (C11, EMA) and negative for S-100 protein and GFAP. The CD34 was focally positive within the tumour cells, and the CD99 was strongly positive. The proliferation index seen on Mib-I was minimal. An ultrastructure study of a well-representative zone of the tumour revealed that the cells were of fusiform shape with bipolar processes. The nuclei were slightly cerebriform with pale chromatin. The cytoplasm contained the usual organelles, a well-developed rough endoplasmic reticulum, a strong amount of intermediate filaments and occasional dense bodies running parallel with the cytoplasmic membrane. Few micropinocytic vesicles were seen as well as focal basement membrane material at the cytoplasmic border, but no cellular junction and no glial or neuronal feature could be seen. On static cytometry, the tumour had a sharp diploid peak.

The histology, immunohistochemistry results and ultrastructure findings excluded the diagnosis of a meningioma, neurofibroma, schwannoma or hemangiopericytoma and were compatible with the diagnosis of a solitary fibrous tumour.

Discussion

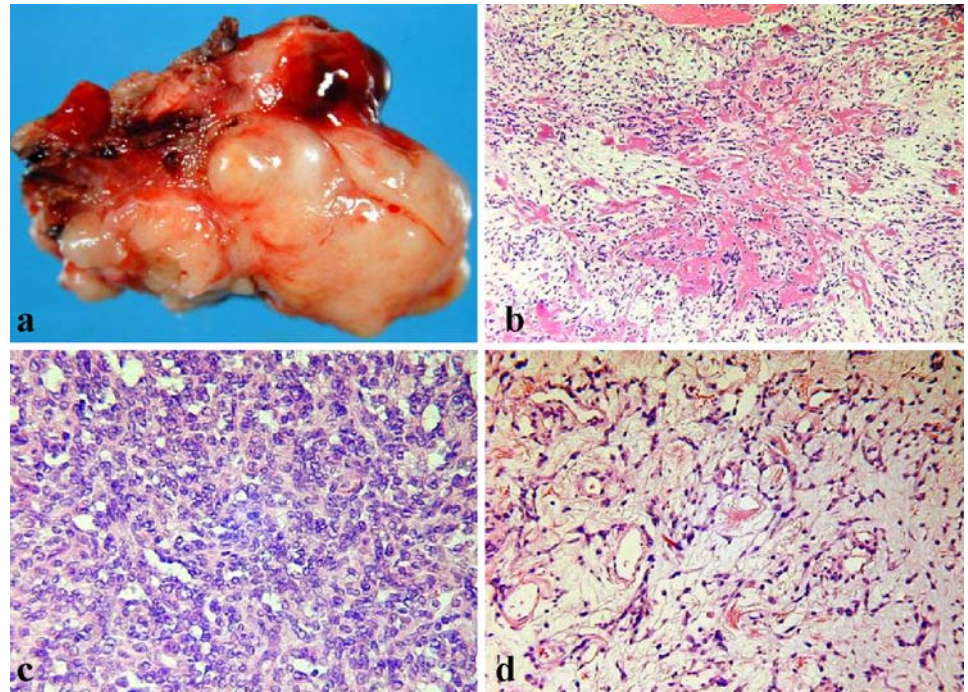
Solitary fibrous tumours located in the meninges are rare: 64 cases have been described in the literature [2, 6, 7] but only two cases in the pediatric population [3, 4].

Radiologically and macroscopically, they are not distinguishable from meningiomas, but histologically, the difference between meningiomas and solitary fibrous tumour is easily shown by immunohistochemistry [1, 8–10]. Solitary fibrous meningeal tumours are a proliferation of fusiform cells positive for vimentin, desmin and CD34, while meningiomas are positive for S-100 protein, vimentin and, especially, epithelial marker like EMA. The case described has the typical pathological features including the various patterns seen on histology, particularly the hemangiopericytoma pattern, the dense collagen fibres arrangement and the chondroid appearance focally. On immunohistochemistry, the reaction to vimentin, desmin and CD99 was strong, but the CD34 was not as diffusely positive as it is often seen, and no epithelial markers were reactive.

The histogenesis of this tumour is not clear. Two theories have been elaborated in considering the leptomeningeal presentation.

- The first theory is that the growth is a proliferation from pluripotential glial cells [11], the argument being

Fig. 2 **a** Multilobulated mass of beige colour, moderately firm in consistency. **b** Dense collagen fibres in spider arrangement. H & E, $\times 40$. **c** Cellular zone with hemangiopericytoma pattern. H & E, $\times 400$. **d** Loose cords or rows of cells within a myxoid background. H & E, $\times 400$



the focal positivity for gliofibrillary acidic protein (GFAP) in some of the cases. GFAP is an intermediate filament found in the cytoskeleton of glial cells and is therefore found in astrocytes, ependymal cells, especially in maturing glia. Not all the cases described had a positive reaction to GFAP. This theory is then concerning only the cases where the tumour cells may arise from this pluripotent glial cells. Another argument in favour of this theory would be the positivity to CD34. As Rodriguez et al. stated [3], CD34 is a glycoprotein found in endothelial cells, myeloid progenitor cells and immature mesenchymal cells, and therefore, its positivity would tend to associate this tumour cells to the pluripotent glial cells.

- The second theory suggests that this fibrous meningeal tumour is a proliferation from meningotheial cells or perivascular fibrous tissue [6] and therefore of an extra-axial origin. While on immunohistochemistry vimentin is positive, it is also an intermediate filament used as a marker for mesenchymal cells and found as well in immature astrocytes; this marker is positive both in solitary fibrous tumours and in meningiomas, while other markers, like epithelial markers such as EMA and CD11, are negative in solitary fibrous meningeal tumours but are positive in meningiomas.

In our case, CD34 was only slightly positive, while another marker, CD99, revealed to be strongly positive. CD99, being a peripheral neuroectodermal marker, was

found especially in Ewing's sarcoma/PNET and a reflection of the 11,22 translocation.

Our case, in comparison with the other pediatric cases described in the literature, had a long-standing presentation. This child suffered for a very long period (5 years) of progressive episodes of headache and transient hemiparesis. Other cases described had a shorter history: 1-week history of worsening headache in a 9-year-old child, 29 months after chemotherapy and radiotherapy for a mixed germ cell tumour of the pineal gland; the second one is a 14-year-old-girl who presented intense headaches for 5 months. The long-term follow-up of these children is not known, and therefore, prognosis cannot be extrapolated on the presenting symptoms.

In the majority of the reported cases, the natural behaviour of the tumour was benign after surgical resection; nevertheless, more aggressive growths have been reported [12, 13], including one case of recurrence [1] and one of metastatization [14]. Will that reveal to be different in childhood cases?

Conclusion

Solitary fibrous meningeal tumours represent a unique pathological entity that is increasingly recognized with the use of ancillary techniques in routine histopathological examination. Until a broader body of knowledge is acquired, the only guideline transpiring from the few

cases reported in the literature is a careful radiological follow-up for all patients diagnosed to have such a tumour. It should be kept in mind that although the majority of cases present a benign postoperative course, aggressive behaviour, including recurrence and metastatization, has also been reported.

The occurrence of such a tumour in the pediatric age group, although seldom reported, certainly represents a valuable experience in determining the long-term natural history of these lesions.

References

1. Carneiro SS, Scheithauer BW, Nascimento AG, Hirose T, Davis DH (1996) Solitary fibrous tumor of the meninges: a lesion distinct from fibrous meningioma. A clinicopathologic and immunohistochemical study. *Am J Clin Pathol* 106:217–224
2. Caroli E, Salvati M, Orlando ER, Lenzi J, Santoro A, Giangaspero F (2004) Solitary fibrous tumors of the meninges: report of four cases and literature review. *Neurosurg Rev* 27:246–251
3. Rodriguez L, Lopez J, Marin A, Cardozo D, Molina O, Cardozo J (2000) Solitary fibrous tumor of the meninges. *Clin Neuropathol* 19:45–48
4. Slavik T, Bentley RC, Gray L, Fuchs HE, McLendon RE (1998) Solitary fibrous tumor of the meninges occurring after irradiation of a mixed germ cell tumor of the pineal gland. *Clin Neuropathol* 17:55–60
5. Guillou L, Fletcher DM, Fletcher CDM, Mandahl N (2002) Extraleural solitary fibrous tumour and haemangiopericytoma. In: Fletcher CDM, Unni KK, Mertens F (eds) *Pathology and genetics: tumours of soft tissue and bone*. IARC, Lyon, pp 86–88
6. Alston SR, Francel PC, Jane JA Jr (1997) Solitary fibrous tumor of the spinal cord. *Am J Surg Pathol* 21: 477–483
7. Martin AJ, Fisher C, Igbaseimokumo U, Jarosz JM, Dean AF (2001) Solitary fibrous tumours of the meninges: case series and literature review. *J Neurooncol* 54:57–69
8. Gold JS, Antonescu CR, Hajdu C, Ferrone CR, Hussain M, Lewis JJ et al (2002) Clinicopathologic correlates of solitary fibrous tumors. *Cancer* 94:1057–1068
9. Martin AJ, Summersgill BM, Fisher C, Shipley JM, Dean AF (2002) Chromosomal imbalances in meningeal solitary fibrous tumors. *Cancer Genet Cytogenet* 135:160–164
10. Suzuki S, Fukui M, Nishio S, Iwaki T (2000) Clinicopathological features of solitary fibrous tumor of the meninges: an immunohistochemical reappraisal of cases previously diagnosed to be fibrous meningioma or hemangiopericytoma. *Pathol Int* 50:808–817
11. Mooney JE, Papasozomenos SC (1996) Leptomeningeal fibroma. *Clin Neuropathol* 15:92–95
12. Ahn JY, Shim JY, Yang WI, Kim TS (2001) Meningeal solitary fibrous tumor as an unusual cause of exophthalmos: case report and review of the literature. *Neurosurgery* 48: 1362–1366
13. Castilla EA, Prayson RA, Stevens GH, Barnett GH (2002) Brain-invasive solitary fibrous tumor of the meninges: report of a case. *Int J Surg Pathol* 10:217–221
14. Ng HK, Choi PC, Wong CW, To KF, Poon WS (2000) Metastatic solitary fibrous tumor of the meninges. Case report. *J Neurosurg* 93:490–493