

Images in cardio-thoracic surgery

Pitfall in the computed-tomography-diagnosis of postcardiotomy infection: iodine accumulation after irrigation mimicking retrosternal abscess

Robert Bauernschmitt^{a,*}, Stefan Martinoff^b, Michael Poerner^b, Ruediger Lange^a

^aClinic for Cardiovascular Surgery, German Heart Center Munich, Lazarettstr. 36, 80636 Munich, Germany

^bInstitute for Radiology and Nuclear Medicine, German Heart Center Munich, Munich, Germany

Received 10 November 2004; received in revised form 22 November 2004; accepted 26 November 2004

Keywords: Computed tomography; Mediastinitis; Closed-chest irrigation

A patient, after surgical debridement and closed chest iodine solution irrigation, was reoperated for urgent suspicion of retrosternal abscess displayed by an intravenous contrast enhanced CT-scan. No signs of infection were found during surgery and at microbiological analyses. The abscess-like collection turned out to be local iodine solution accumulation (Fig. 1).

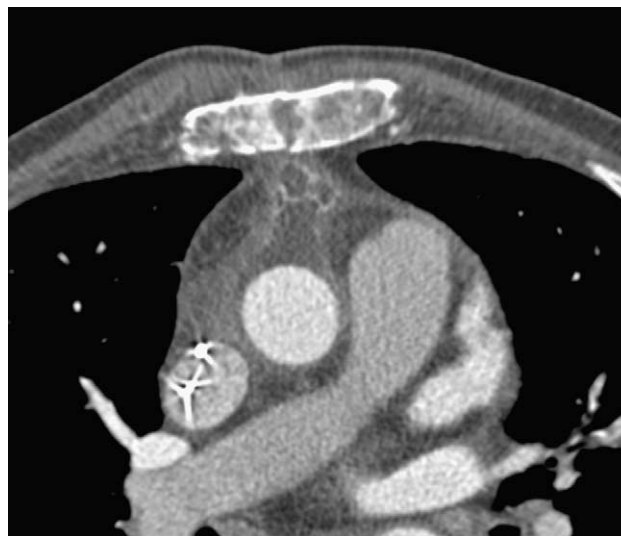

Fig. 1. Contrast enhanced CT-scan following second look surgery displays a retrosternal mass which patterns are consistent with an abscess: high attenuation rim, which circumscribes a low attenuation multilocated collection.

Appendix A. Editorial comment

Bauernschmitt et al. "Pitfall in the computed-tomography-diagnosis of postcardiotomy infection: iodine accumulation after irrigation mimicking retrosternal abscess"

Vassilios P. Argitis^{a,*}, Pierre Schnyder^b,
Ludwig K. von Segesser^a

^aDepartment of Cardio-vascular Surgery, Centre Hospitalier Universitaire
Vaudois, Rue du Bugnon 46, CH-1011 Lausanne, Switzerland

^bDepartment of Radiology, Centre Hospitalier Universitaire Vaudois,
CH-1011 Lausanne, Switzerland

Bauernschmitt and colleagues [1] present an interesting experience, which been underreported until now. As a matter of fact there are numerous reports of mediastinal irrigation with iodine solution for mediastinitis [2-5]. Everybody knows that many contrast media used for angiography or computed tomography are based on water-soluble iodinated solutions.

The authors have to be congratulated for pointing out that post-operative mediastinal irrigation with an iodinated solution must be readily differentiated from an anterior mediastinal infection.

We have looked at this problem in systematic fashion by analyzing CT findings based on various concentrations of iodine solutions, as they are typically used for mediastinal irrigation in post cardiotomy infections, and elsewhere.

* Corresponding author. Tel.: +49 89 1218 4062; fax: +49 89 1218 4093.
1010-7940/\$ - see front matter © 2004 Elsevier B.V. All rights reserved.
doi: 10.1016/j.ejcts.2004.11.029

Solutions of povidone iodine (Betadine®, Mundipharma Medical Company, Basel, Switzerland) with different concentrations 0, 2, 5, 10, 20, 50, and 100% were scanned as shown in Fig. 1, and the corresponding attenuation values are displayed in Fig. 2. Our investigation clearly shows that povidone iodine at 50% concentration provides an identical contrast attenuation as the contrast enhancement of the aorta.

Post-cardiotomy infection develops in 3% [3] of all patients who had cardiac surgical procedures with extracorporeal circulation and is of major concern to cardiac surgeons. If an aortic graft prosthesis or other implants are present, the problem becomes even more striking due to the difficult management of such complications and their high mortality rates.

A review of the literature reveals that when a radical surgical approach is contraindicated for treatment of mediastinitis, conservative methods can be attempted, with intensive debridement of the infected tissue, local antiseptic irrigation and/or omental transposition [5-7]. Physical examination, clinical and laboratory data as well as CT findings are used to optimize the treatment. The value of CT for the diagnosis of mediastinitis is expressed by a sensitivity of 67% and a specificity of 83% [4].

The use of iodine solutions can improve the validity of CT for the diagnosis of post-cardiotomy infections in terms of

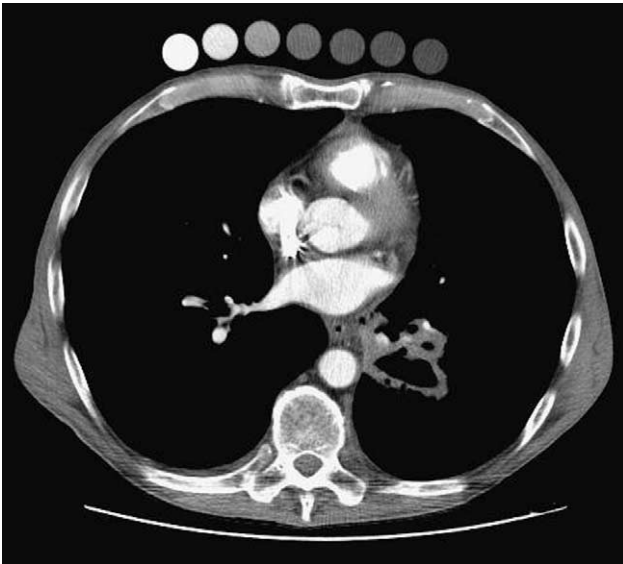


Fig. 1. Seven specimens of Betadine® solutions at concentrations of 100, 50, 20, 10, 5, 2, and 0% (from left to right) have been taped onto the anterior chest wall of a patient prior to an intravenous contrast enhanced helical CT survey of the chest and abdomen for a 5 cm excavated carcinoma of the left lower lobe. It appears on this 5 mm CT section obtained at 120 kV and 120 mAs, that Betadine® solution at a concentration of 50% provides an attenuation value of 240 Hounsfield units, which is close to the one in the contrast enhanced lumen of the descending thoracic aorta.

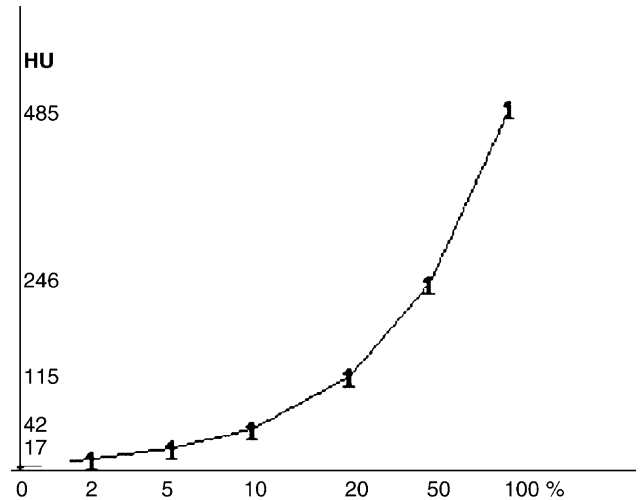


Fig. 2. Betadine® concentrations (%) and corresponding attenuation values (HU), as measured on 5 mm CT sections obtained at 120 kV and 120 mAs.

sensitivity and specificity. However, CT findings in patients receiving iodine solutions for irrigation are prone to misinterpretation as demonstrated by Bauernschmitt et al. [1]. Hence, in the presence of contrast enhancement at a CT after irrigation, the diagnosis of a water-soluble iodine collection originating from the irrigation has to be ruled out, in order to avoid a false positive diagnosis of an abscess which could lead to an unfounded treatment of a such life-threatening complication.

References

- [1] Bauernschmitt R. Pitfall in the computed-tomography-diagnosis of postcardiotomy infection: iodine accumulation after irrigation mimicking retrosternal abscess. *Eur J Cardiothorac Surg* 2005;27:707.
- [2] Knight CD. Treatment of aortic graft infection with povidone-iodine irrigation. *Mayo Clin Proc* 1983;58:472-5.
- [3] Misawa Y. Infectious mediastinitis after cardiac operations: computed tomographic findings. *Ann Thorac Surg* 1998;65:622-4.
- [4] Yamaguchi H. Diagnostic validity of computed tomography for mediastinitis after cardiac surgery. *Ann Thorac Cardiovasc Surg* 2001;Apr7(2): 94-8.
- [5] Luciani N. Mediastinitis following graft replacement of the ascending aorta: conservative approach by omental transposition. *Eur J Cardiothorac Surg* 2001;20(2):418-20.
- [6] Klesius AA. Successful treatment of deep sternal infections following open heart surgery by bilateral pectoralis major flaps. *Eur J Cardiothorac Surg* 2004;25:218-23.
- [7] Misawa Y. Which is better for treatment of mediastinitis following heart surgery, omental or muscle flap transfer? *Eur J Cardiothorac Surg* 2004;26: 232-3.

*Corresponding author. Tel.: +41 21 314 26 95; fax: +41 21 314 22 79.
E-mail address: vassiliosargitis@hotmail.com
doi:10.1016/j.ejcts.2005.01.010