

Rheumatology 2015;54:2291–2292
doi:10.1093/rheumatology/kev325
Advance Access publication 28 August 2015

High level of anti-drug antibodies after intra-articular injection of anti-TNF

Rheumatology key message

- Anti-drug antibodies against anti-TNF monoclonal agents can appear even after a single intra-articular infiltration.

SIR, Intra-articular injection of anti-TNF agents is not scientifically validated but has been used empirically to treat chronic synovitis. In the cases reported to date, the indication was recurrent inflammatory non-specific mono-arthritis or mono-arthritis occurring in the context of axial spondyloarthritis [1–4]. Infliximab, etanercept or adalimumab has been administered, either in anti-TNF-naïve patients or in patients treated with a different biologic agent [4]. In most cases, the response was described as satisfactory and sustained for several months. To our knowledge, there have been few cases of repeated intra-articular injections of anti-TNF agents [4] and no data on the induction of anti-drug antibodies (ADABs) after intra-articular injection. The measurement of ADABs against anti-TNF blockers has become more widespread in recent years. ADABs were found to be specific, and their levels correlated with a residual drug level and the loss of clinical response [5, 6].

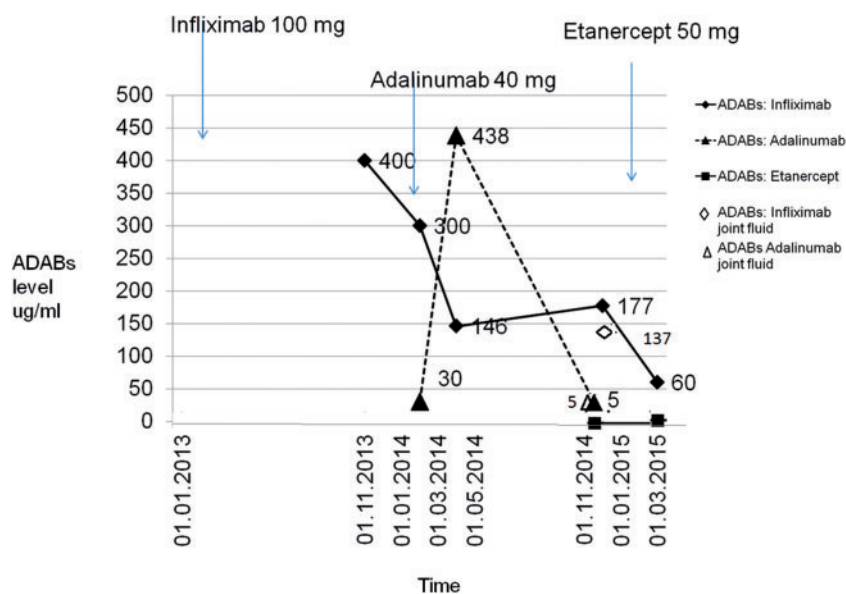
We report the case of a 35-year-old patient with a non-specific inflammatory mono-arthritis of the right knee that did not respond to three consecutive intra-articular steroid injections. The search for a specific rheumatic disease was negative. It was decided, based on our own experience and the data in the literature, to inject the knee joint

with an anti-TNF. In March 2013, he received an intra-articular injection of 100 mg of infliximab. The clinical response was excellent, with rapid disappearance of joint effusion for at least 6 months.

He returned 9 months later to request a second infiltration. We measured ADABs before the injection and found very high ADABs to infliximab but not to adalimumab. He injected the knee with the latter agent (40 mg) and once again obtained an excellent result. Two months later, there was a recurrence of effusion in the knee. Joint fluid aspiration was performed and ADABs were measured in the SF and serum. Serum ADABs against infliximab were still present but at a lower concentration than the previous measurement, but this time ADABs against adalimumab were also detected. The level of ADABs against both medications was similar in the serum and the SF (Fig. 1). He relapsed 10 months later. On this occasion, etanercept (50 mg) was injected into the knee, and once again an excellent response was obtained for 3 months. At that time, he did not develop ADABs against this etanercept.

The case highlights the fact that ADABs can appear even after a single intra-articular infiltration with an anti-TNF agent and that ADABs diffuse from the joint to the blood and vice versa. Moreover, the intra-articular exposure to a second anti-TNF agent can also be followed by the appearance of ADABs directed against this new agent. Usually, ADABs in the blood do not appear after a single contact with a new biologic. Some studies have suggested that s.c. administration could enhance the risk of developing ADABs because of the presence of antigen-presenting cells in the skin [7]. Such cells are present in even larger numbers within an inflamed synovial tissue. The route of administration could therefore be responsible for the rapid appearance ADABs leading to a rapid loss of

Fig. 1 Evolution of blood and joint fluid anti-drug antibodies against the different agents injected into the knee



ADABs cut-off for infliximab, adalimumab and etanercept: $<10 \mu\text{g/ml}$. ADAB: anti-drug antibodies.

efficacy after repeated injections. It has also been suggested that low dose and irregular injections may predispose to ADABs and allergic reactions. This is consistent with the findings in our case (long interval between the injections and low dose of infliximab). Moreover, as allergic reactions are known to be more frequent in the presence of ADABs [6], repeating such injections could enhance the risk of an allergic reaction.

Rheumatologists should therefore be cautious about the use of isolated intra-articular injections of TNF blockers. The authors think that measurement of ADABs should be recommended after such a procedure, especially when it is about to be repeated. The generation of ADABs following intra-articular monoclonal anti-TNF agents could theoretically reduce the efficacy and enhance the toxicity of subsequent systemic anti-TNF therapy.

Funding: No specific funding was received from any funding bodies in the public, commercial or not-for-profit sectors to carry out the work described in this manuscript.

Disclosure statement: The authors have declared no conflicts of interest.

Pascal Zufferey¹, Mathieu Perreau² and Alexander So¹

¹*Service de rhumatologie, département de l'appareil locomoteur* and ²*Service d'immunologie, Centre hospitalier universitaire vaudois, Lausanne, Switzerland*

Revised version accepted 4 August 2015

Correspondence to: Pascal Zufferey, Service de rhumatologie, département de l'appareil locomoteur, centre hospitalier universitaire vaudois, Avenue Pierre Decker 5, 1010 Lausanne, Switzerland. E-mail: pascal.zufferey@chuv.ch

References

- 1 Haroon M, O'Gradaigh D. Efficacy and safety of combining intra-articular methylprednisolone and anti-TNF agent to achieve prolonged remission in patients with recurrent inflammatory monoarthritis. *Joint Bone Spine* 2010;77:232–4.
- 2 Fisher BA, Keat A. Should we be using intraarticular tumor necrosis factor blockade in inflammatory monoarthritis? *J Rheumatol* 2006;33:1934–5
- 3 Sakellariou GT, Anastasilakis AD, Bisbinas I, Gketsos A, Berberidis C. Efficacy of anti-TNF agents as adjunctive therapy for knee synovitis refractory to disease-modifying antirheumatic drugs in patients with peripheral spondyloarthritis. *ISRN Rheumatol* 2013;2013:907085.
- 4 Roux CH, Breuil V, Valerio L *et al*. Etanercept compared to intraarticular corticosteroid injection in rheumatoid arthritis: double-blind, randomized pilot study. *J Rheumatol* 2011;38:1009–11.
- 5 Berner J, Perreau M, Aubry-rozier B, So A, Zufferey P. Antibodies against biologic agents (ADABs) in a real life rheumatology cohort: immunogenicity is not similar among all the biologic agents. *Swiss Medical Weekly* 2014;144 (Suppl):5s.
- 6 Vincent FB, Morand EF, Murphy K *et al*. Antidrug antibodies (ADAb) to tumour necrosis factor (TNF)-specific neutralising

agents in chronic inflammatory diseases: a real issue, a clinical perspective. *Ann Rheum Dis* 2013;72:165–78.

- 7 Fathallah AM, Bankert RB, Balu-Iyer SV. Immunogenicity of subcutaneously administered therapeutic proteins—a mechanistic perspective. *AAPS J* 2013;15:897–900.

Rheumatology 2015;54:2292

doi:10.1093/rheumatology/kev369

Advance Access publication 10 October 2015

Comment on: High-risk pregnancy and the rheumatologist

SIR, We read with great interest the recent paper by May Ching Soh and Catherine Nelson-Piercy evaluating the role of the rheumatologist for pregnant women with rheumatic diseases [1]. Fertility, pregnancy, and management of high-risk pregnancy are important topics for patients and their doctors alike. The paper offers a concise overview of current basic and clinical research evidence on the subject. However, we are concerned by the authors' claim regarding the use of cyclooxygenase-2 (COX-2) selective NSAIDs: 'Data on the safety of COX-2 inhibitors in pregnancy are emerging, with a single population-based study demonstrating no increased risk of foetal malformation' [1]. The quoted study [2] indeed revealed that intrauterine exposure to NSAIDs in the first trimester was not associated with an increased risk of major congenital malformations. However, it did reveal an increased risk for musculoskeletal malformations following exposure to COX-2 selective NSAIDs, with an adjusted odds ratio of 3.39 (95% CI 1.37–8.34) [2]. Although this finding might be open to discussion due to the small size of the exposed cohort, it might be prudent, until more evidence arises, to exercise caution when prescribing COX-2 selective NSAIDs in pregnant women.

Funding: No specific funding was received from any funding bodies in the public, commercial or not-for-profit sectors to carry out the work described in this manuscript.

Disclosure statement: The authors declare no conflict of interest.

Sonja Praprotnik¹, Ziga Rotar¹ and Matija Tomšič¹

¹*Department of Rheumatology, University Clinical Centre, Ljubljana, Slovenia*

Accepted 3 September 2015

Correspondence to: Sonja Praprotnik, University Clinical Centre, Department of Rheumatology, Vodnikova 62, 1000 Ljubljana, Slovenia. E-mail: sonja.praprotnik@kclj.si

References

- 1 Soh MC, Nelson-Piercy C. High-risk pregnancy and the rheumatologist. *Rheumatology* 2015;54:572–87.
- 2 Daniel S, Matok I, Gorodischer R *et al*. Major malformations following exposure to nonsteroidal antiinflammatory drugs during the first trimester of pregnancy. *J Rheumatol* 2012;39:2163–9.