

Urgent reoperative transapical valve-in-valve shortly after a transapical aortic valve implantation

Enrico Ferrari^{a,*}, Didier Locca^b, Carlo Marcucci^c and Xavier Jeanrenaud^b

^a Department of Cardiac Surgery, University of Lausanne, Lausanne, Switzerland

^b Department of Cardiology, University of Lausanne, Lausanne, Switzerland

^c Department of Cardiac Anesthesia, University of Lausanne, Lausanne, Switzerland

* Corresponding author: Department of Cardiac Surgery, CHUV, Rue du Bugnon 46, CH-1011 Lausanne, Switzerland. Tel: +41-79-310-1386; fax: +41-21-314-2278; e-mail: enricoferrari@bluewin.ch (E. Ferrari).

Received 9 September 2013; received in revised form 17 October 2013; accepted 22 October 2013

Abstract

Urgent reoperative transapical aortic valve-in-valve has never been proposed as a treatment option in case of a failed transcatheter aortic valve implantation (TAVI) or in case of worsening of an existing paravalvular leak, if this complication occurs right after, or a few days after, the primary transapical aortic valve implantation. Experienced surgeons should argue that after a transapical TAVI, the apex is damaged and fragile, with a high risk of irreparable ventricular tears and life-threatening bleeding if a second transapical procedure is scheduled during the acute phase. Nevertheless, if the patient is inoperable and the vascular status, including the ascending aorta, limits alternative accesses, the urgent reoperative transapical valve-in-valve becomes an alternative. We illustrate, for the first time ever, our experience with an 81-year old female patient who underwent a transapical (TA) TAVI with a Sapien™ XT 23 mm. The day after the procedure, the patient haemodynamically worsened in combination with a worsening of a known (grade 1–2) paravalvular leak. Thus, on postoperative day two, an urgent transapical valve-in-valve was performed, and a second Sapien™ XT 23 mm was placed, with an excellent haemodynamic result and absence of leak. The redo apical access did not appear very complicated and the postoperative recovery was uneventful.

Keywords: Transcatheter aortic valve implantation • Redo cardiac surgery • Aortic valve regurgitation

INTRODUCTION

Transapical transcatheter aortic valve implantation (TA-TAVI) is performed in high-risk patients with severe vascular disease. However, leaflet calcifications, valve malpositioning or a wrong valve sizing can be at the origin of post-deployment paravalvular leaks (single or multiple jets) severely affecting the patient outcome (if equal or above grade 2) [1–4]. In the future, stent-valves will be specifically designed to prevent this complication, whereas today, we can only proceed with repeated valvuloplasties or valve-in-valve procedures during the same session [1]. Leftover grade 1 paravalvular regurgitation is widely accepted in the TAVI community, but sometimes, and for uncertain reasons, this can worsen postoperatively. Alternatively, the degree of the regurgitation was underestimated and the patient presented a worsening of his haemodynamic status during the recovery. Thus, if a repeated valvuloplasty was already performed intraoperatively, other options are welcome. Redo transapical valve-in-valve for worsening of a paravalvular leak occurring right after, or a few days after, the primary TA-TAVI is traditionally not recommended and, consequently, the patient is sent to high-risk standard surgery. In fact, if a second TA-TAVI is performed in the acute phase, the apex is supposed to be damaged and fragile, with a high risk of irreparable ventricular tear and life-threatening bleeding. However, if the patient is inoperable and the vascular status impedes alternative accesses, the urgent transapical is the

only option. We illustrate for the first time ever, a case of redo TA-TAVI performed two days after the first procedure.

CASE REPORT

We report the case of an 81-year old female patient suffering from severe symptomatic aortic valve stenosis and at high risk of standard surgery (logistic EuroSCORE 1: 23% with vascular disease, chronic pulmonary disease, age and female gender), with a clinical fragile profile. The annulus and the valve were heavily calcified (annulus diameter: 21.5 mm at CT scan and 21.5–22 mm at transoesophageal echocardiogram). The preoperative assessment also showed a severe calcified aorta with stenosis at the iliac bifurcation and presence of calcifications in the ascending aorta and aortic arch. The TAVI team performed a transapical TAVI and a ‘stiff’ 23 mm Sapien™ XT was correctly placed under fluoroscopic and echocardiographic guidance (Fig. 1A). Then, the transoesophageal echocardiogram revealed the presence of a grade 2 paravalvular regurgitation (near the mitral leaflet) that was treated with a valvuloplasty (with 1 ml more of contrast): this procedure was at risk of aortic rupture because of the heavy calcifications, and the regurgitation did not disappear but ameliorated (grade 1–2). Thus, we accepted the persistence of a mild leak. The patient was extubated and transferred to the intermediate care unit with stable haemodynamic status. The day after, the haemodynamic status

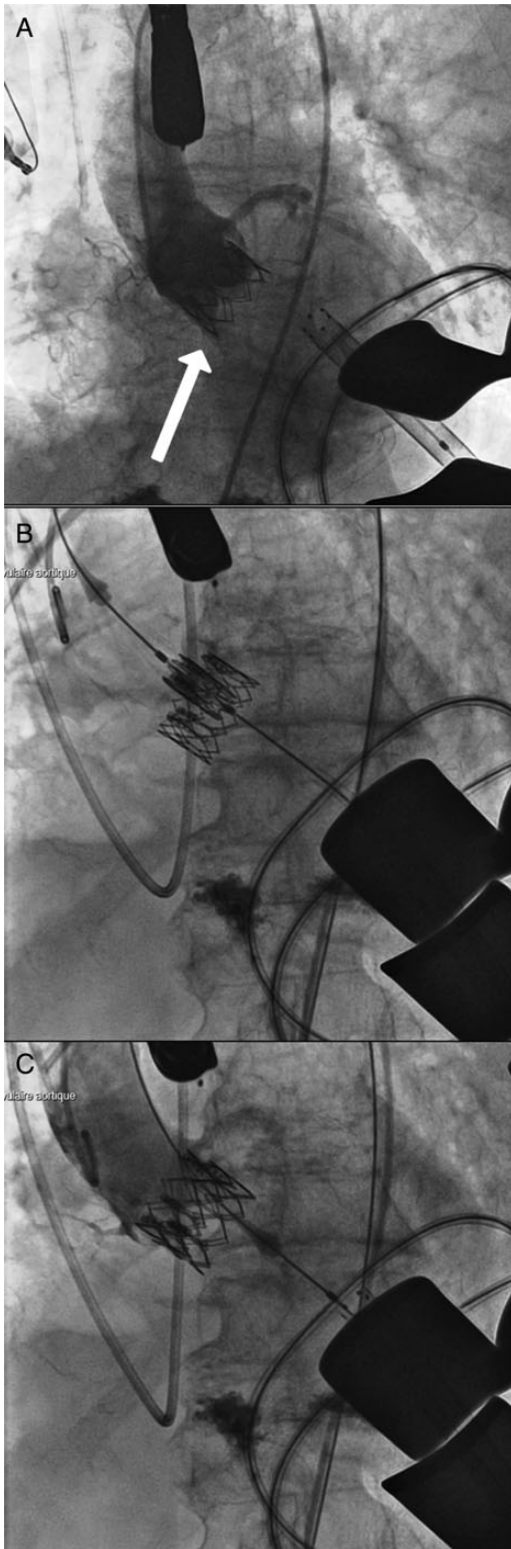


Figure 1: Intraoperative fluoroscopic images: (A) at the time of the first transapical TAVI, the paravalvular leak grade 1 (arrow) is the result of a repeated valvuloplasty with an additional 1 ml of contrast in the balloon; (B) the repeated urgent transapical-TAVI valve-in-valve for worsening of the paravalvular leak (grade 2); (C) the final result.

deteriorated with a concomitant lowering of the diastolic pressures. Owing to this worsening of haemodynamic parameters, an echocardiographic control was performed and showed a second

jet and the worsening of the first one with suspicion of an underestimated moderate paravalvular leak caused by heavy calcifications and a stent-valve position slightly 'too low' (but the valve did not migrated, apparently) (Fig. 2A). Considering the patient's critical status and her frailty, the standard valve surgery was not a valid option. Therefore, we decided to perform a reoperative TA-TAVI for valve-in-valve: two days after the first procedure, we re-performed the TA-TAVI through the same intercostal space and the same apical access: a second 23-mm Sapien™ XT was successfully deployed within the first one, 4 mm higher (Fig. 1B). The result was excellent (14/7 mmHg of gradient) without relevant leak (Fig. 1C). From a surgical point of view, the apex presented unexpected solid tissues and we safely prepared two new purse-string sutures (Fig. 2C) around the old ones. When the first sutures were catted, there was no bleed and, therefore, we placed the needle, the guidewires and the Ascendra+™ delivery system as in standard TA-TAVI (Fig. 2D and E). This was unexpected but it can represent the result of the routine use of fibrin glue applied on top of the apex at the end of all TA-TAVI performed in our institution. At the end of the procedure, the purse-string sutures were tied without complications (Fig. 2F). The postoperative recovery was uneventful and the patient left the hospital 8 days later.

DISCUSSION

A case of transapical redo for valve-in-valve has already been described after a period of 3 years from the first TA-TAVI procedure [5]. However, if this performance is required during the acute phase following the primary TA-TAVI procedure, the redo transapical TAVI is traditionally not recommended and, to the best of our knowledge, no clinical reports are available in the literature. In fact, the tissues are supposed to be very fragile with a concrete risk of apical rupture and poor patient outcome. Thus, in case of failed or defective TA-TAVI with persistent leak, the percutaneous re-valvuloplasty of the stent-valve represents the first treatment option, whereas the standard open-heart surgery (still at high risk) can be performed in urgency if the haemodynamic status deteriorates rapidly. With the present clinical report we present, for the first time ever, a successful redo TA-TAVI for valve-in-valve performed two days after the primary TA-TAVI in a fragile patient.

What we learnt is that a TA-TAVI can be re-performed in urgency, already a couple of days after the first transapical procedure, with low surgical risk and excellent results. In our experience, the fragile lady was at high risk for standard surgery and, therefore, we were obliged to explore this option: the apical tissue was unexpectedly normal and the apical access was already sealed. In this scenario, we believe that the use of the fibrin glue on the top of the apex at the end of all TA-TAVI helps in securing the access site and, therefore, in preventing bleedings and the pseudoaneurysm formation. With regard to the tissue quality, the manipulated apical wall accepted two new purse-string sutures that were gently tied at the end of the procedure without need for rapid cardiac pacing. In conclusion, the urgent redo TA-TAVI for valve-in-valve is a valid transcatheter option after a failed TA-TAVI if alternatives are unavailable or at too high risk.

Conflict of interest: none declared.

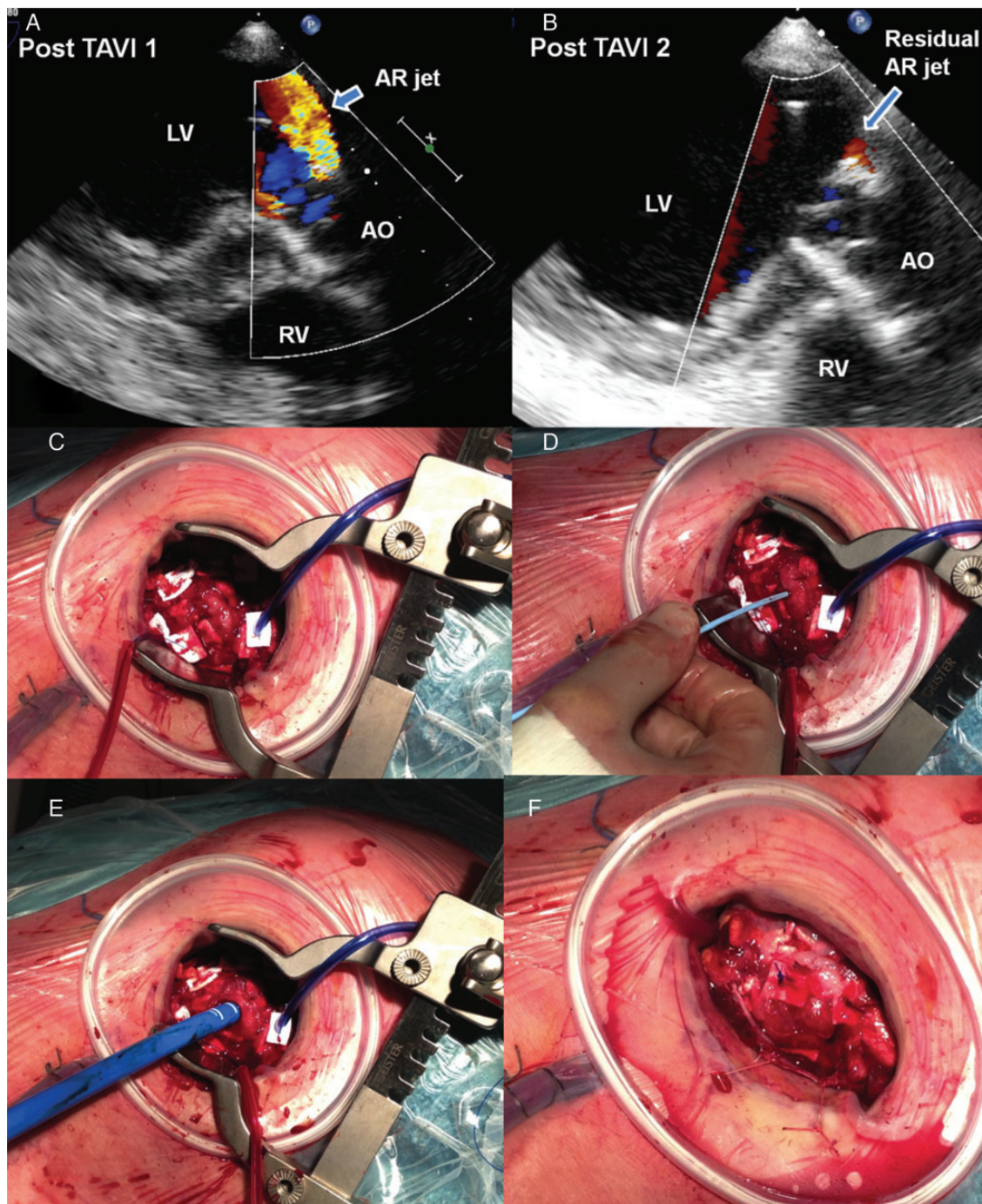


Figure 2: (A and B) Echocardiographic views of the paravalvular leak after the first TA-TAVI (A) and after the redo TA-TAVI (B) (intra-gastric LVOT views: 130°. LV: left ventricle, RV: right ventricle, AO: aorta); (C, D and E) the surgical field with the insertion of the guidewire, the pigtail and the delivery system; (F) the final result.

REFERENCES

- [1] von Segesser LK, Gerosa G, Borger MA, Ferrari E. Prevention and management of potential adverse events during transapical aortic valve replacement. *J Heart Valve Dis* 2013;22:276–86.
- [2] Abdel-Wahab M, Zahn R, Horack M, Gerckens U, Schuler G, Sievert H *et al.* German transcatheter aortic valve interventions registry investigators. Aortic regurgitation after transcatheter aortic valve implantation: incidence and early outcome. Results from the German transcatheter aortic valve interventions registry. *Heart* 2011;97:899–906.
- [3] Gotzmann M, Pljakic A, Bojara W, Lindstaedt M, Ewers A, Germing A *et al.* Transcatheter aortic valve implantation in patients with severe symptomatic aortic valve stenosis—predictors of mortality and poor treatment response. *Am Heart J* 2011;162:238–45.
- [4] Généreux P, Head SJ, Hahn R, Daneault B, Kodali S, Williams MR *et al.* Paravalvular leak after transcatheter aortic valve replacement: the new Achilles' heel? A comprehensive review of the literature. *J Am Coll Cardiol* 2013;61:1125–36.
- [5] Kiefer P, Seeburger J, Chu MW, Ender J, Vollroth M, Noack T *et al.* Reoperative transapical aortic valve implantation for early structural valve deterioration of a SAPIEN XT valve. *Ann Thorac Surg* 2013;95:2169–70.