

## CASE REPORT

# Aorto-subclavian thromboembolism: a rare complication associated with moderate ovarian hyperstimulation syndrome

Marc Germond, Daniel Wirthner, Dominique Thorin<sup>1</sup>, Patrick Ruchat<sup>2</sup>, Axel Essinger<sup>3</sup> and Pierre De Grandi

Fertility Unit, Department of Gynaecology and Obstetrics, <sup>1</sup>Service of Anesthesiology, <sup>2</sup>Service of Cardiovascular Surgery and <sup>3</sup>Department of Radiology, CHUV, 1011 Lausanne, Switzerland

**The case of an arterial aorto-subclavian thromboembolism associated with a moderate ovarian hyperstimulation syndrome (OHSS) and following ovulation induction for in-vitro fertilization in a young woman is reported. Because of the lack of response to systemic thrombolysis, a left postero-lateral thoracotomy was performed on day 8 after embryo transfer. A fibrinocruoric embolus situated at the junction of the left subclavian artery from the aorta was removed through a left subclavian arteriotomy. The distal axillary embolus was removed by a retrograde balloon catheter embolectomy. A moderate OHSS was observed. The ovarian stimulation and OHSS-related risks of thromboembolism are discussed. We conclude that, in the absence of risk factors, counselling about possible complications resulting from stimulation must be emphasized.**

**Key words:** arterial thromboembolism/IVF/menotrophin/ovarian hyperstimulation syndrome

## Introduction

Ovarian hyperstimulation syndrome (OHSS) is the most frequent and worrying complication following ovulation induction. The incidence of this side-effect has increased since gonadotrophin releasing hormone analogues (GnRHa) have been used. For many authors, the different protocols which associate follicle stimulating hormone (FSH) and/or human menopausal gonadotrophin (HMG) with GnRHa seem to be related to a significantly higher rate of moderate or severe OHSS (Rizk and Smitz, 1992). Some authors (Rabau *et al.*, 1967) have classified ovarian response in three clinical categories (mild, moderate and severe) and six grades (two per category) based on the severity of the signs, symptoms and laboratory findings. The more recent definition of OHSS proposed by Golan *et al.* (1989) has offered a more clinical approach to this syndrome. Severe complications of this iatrogenic syndrome include thromboembolism, adult respiratory distress syndrome, acute hydrothorax (Daniel *et al.*, 1995) and, occasionally, death (Schenker and Ezra, 1994). During ovarian stimulation for in-vitro fertilization (IVF) and embryo

transfer, the risk of moderate or severe OHSS after GnRHa/HMG stimulation is evaluated as 0.6–14.0% (Rizk and Smitz, 1992). We report the case of an arterial aorto-subclavian thromboembolism associated with a moderate OHSS in a young woman.

## Case report

A non-Caucasian 32 year old woman was treated in our IVF and embryo transfer programme for a secondary infertility associated with a male factor and a bilateral tubal obstruction. Her past medical history reported a right salpingectomy for an ectopic pregnancy and a proximal left tubal occlusion. A mild essential hypertension was easily corrected with labetalol (200 mg/day).

The treatment procedure consisted of a long protocol (Figure 1). After pituitary desensitization with GnRHa (0.1 mg Decapeptyl; Ferring, Zürich, Switzerland) administered from day 23, multiple follicular development was induced using 225 IU HMG (Pergonal; Serono, Aubonne, Switzerland) daily. Follicular growth was monitored with serial ultrasound scans and repeated estimations of oestradiol blood concentrations. On day 10 of stimulation, the HMG dose was reduced to 150 IU because of the high oestradiol concentration (10.5 nmol/l). By day 12, 11 follicles >16 mm in diameter and 16 smaller follicles were observed. The oestradiol concentration reached 17.8 nmol/l when 10 000 IU human chorionic gonadotrophin (HCG; Profasi; Serono) were administered. Oocyte recovery took place 36 h later. In all, 18 oocytes were collected; 12 oocytes fertilized, three embryos were transferred to the uterus 2 days later and nine embryos were frozen. A dose of 1000 IU HCG was given i.m. on the day of embryo transfer and 48 h later for luteal phase support. This support was stopped because the patient complained of nausea and abdominal tension. No diarrhoea or vomiting was noticed. Abdominal ultrasonography showed enlarged ovaries (9 cm). As expected, multiple ovarian cysts and a small quantity of ascites were found. The haemoglobin concentration was 139 g/l, with a haematocrit of 0.44. Electrolytes and creatinine concentrations were within the normal range. A diagnosis of moderate OHSS was made, based on clinical, laboratory and echographic findings. On day 6 after transfer, the patient began to complain of pain and paraesthesia in the left arm which she had noticed 36 h earlier. Examination revealed pulseless radial and humeral arteries and a cold left arm. The aetiology of the acute ischaemia was determined by an arteriography, which showed a large clot in the left subclavian artery (Figure 2)

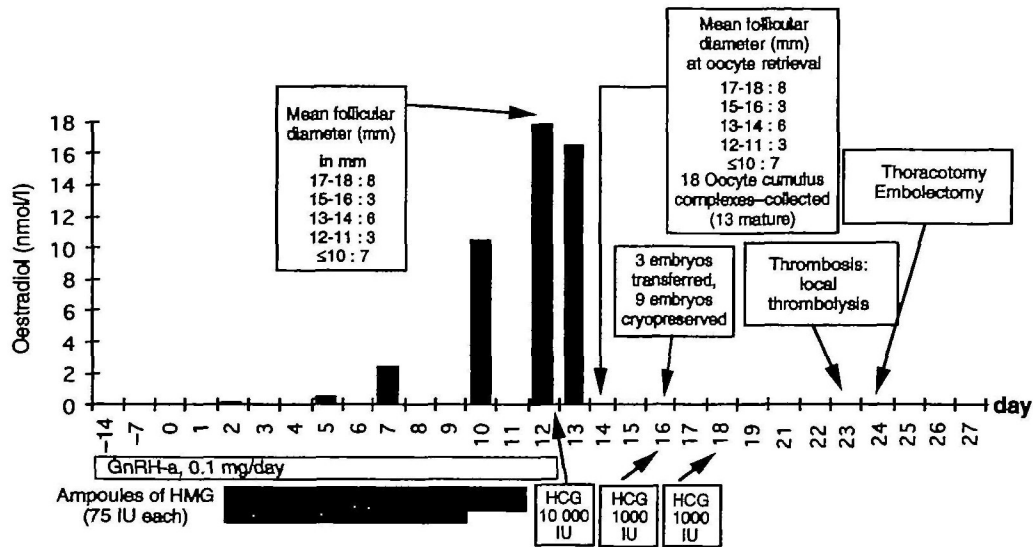


Figure 1. Chronology of events.

and an occlusion of the left axillary artery. Signs of slight haemoconcentration were present (haemoglobin 151 g/l, haematocrit 0.46). Clotting function tests were within the normal range [quick time (PT), partial thrombin time (PTT)]. As thrombolysis was initiated as an emergency procedure, more specific thrombosis risk factors such as protein C, protein S, Leiden V factor and antithrombin III deficiencies were not checked. Immediate local thrombolysis was attempted with 100 000 and 200 000 IU urokinase without success. Anti-coagulation using i.v. heparin and oral aspirin was initiated. Given the lack of response, a left postero-lateral thoracotomy was performed on day 7 after transfer. Surgical exploration revealed a fibrinocruoric embolus situated at the junction of the left subclavian artery with the aorta. The embolus was removed through a left subclavian arteriotomy. The distal axillary embolus was removed by a retrograde balloon catheter embolectomy. The presence of a patent foramen oval (paradoxical emboli) was excluded during the operation by using a transoesophageal echocardiography with microbubbles test. The choice of this surgical strategy was motivated by the danger of left carotid arterial emboli after the use of retrograde balloon catheter embolectomy from the left humeral artery. At the end of the operation, the left radial artery was again palpable. Heparin administration was discontinued and dicoumarol administration introduced after the existence of a pregnancy had been excluded.

## Discussion

Arterial thromboembolism is a rare complication of OHSS. Only 11 cases of arterial thrombosis have been described following gonadotrophin stimulation: two cases of right middle cerebral artery thrombosis (Neau *et al.*, 1989; Rizk *et al.*, 1990), one of cerebral anterior artery thrombosis (Dumont *et al.*, 1980), one of vertebral artery thrombosis (Humbert *et al.*, 1973), three of internal carotid artery thrombosis (Mozes *et al.*, 1965; Kermodé *et al.*, 1993; Arousseau *et al.*, 1995), one of humeral artery thrombosis (Arousseau *et al.*, 1995), one of unilateral femoral artery thrombosis (Mozes *et al.*,

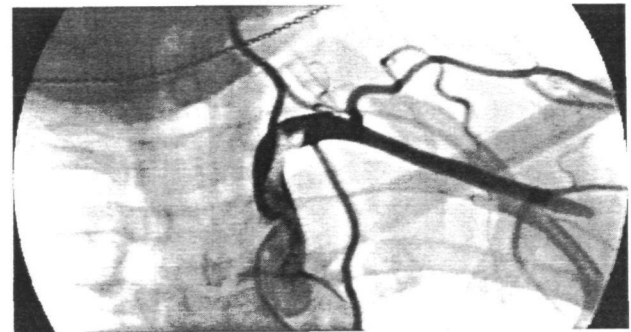


Figure 2. Selective angiogram of left subclavian artery showing proximal occlusion by a fibrinocruoric embolus and distal axillary obstruction. A radiological steal subclavian syndrome occurred.

1965), one of bilateral femoral artery thrombosis (Choktanasiri and Rojanasakul, 1995) and one of popliteal artery thrombosis (Arousseau *et al.*, 1995). Most of these occlusions are characterized by their position in the superior limb or in the cerebral territory. The case reported here shows an unusual location of thrombosis occurring during a moderate OHSS.

No risk factor for thromboembolism had been detected, either by clinical observation or by cardiological and laboratory investigations performed before the treatment. Three OHSS risk factors were present: a high oestradiol concentration induced by the simultaneous administration of GnRH $\alpha$  with HMG, ovulation induction with HCG and the use of HCG as a luteal phase support. Only one of the previously described cases of arterial thrombosis presents all these risk factors (Table I).

In our reported case, OHSS risk was, in our opinion, not sufficient to cancel HCG administration or to avoid embryo transfer. In our practice, the cycle is cancelled when the oestradiol concentration is  $>20$  nmol/l or when the number of follicles  $>16$  mm in diameter is  $>12$ . This attitude is supported by Morris *et al.* (1995). Our patient did not develop severe OHSS, although the retrospectively calculated prediction rate according to Delvigne *et al.* (1993) was 78.9%.

Many factors contribute to thrombogenesis during the evolu-

**Table I.** Menotropins and gonadotrophin-releasing hormone analogue (GnRH<sub>a</sub>) use in the 11 reviewed cases of arterial thrombosis associated with ovarian hyperstimulation syndrome

References	Thrombosis location	HMG	GnRH <sub>a</sub>	HCG	
				Ovulation induction	Luteal support
Rizk <i>et al.</i> (1990)	Middle cerebral artery	Yes	Yes	Yes	No
Kermode <i>et al.</i> (1993)	Internal carotid artery	Yes	Yes	Yes	No
Mozes <i>et al.</i> (1965)	Internal carotid artery	Yes	No	Yes	No
Mozes <i>et al.</i> (1965)	Unilateral femoral artery	Yes	No	Yes	No
Aurousseau <i>et al.</i> (1995)	Internal carotid artery	Yes	ND	ND	ND
Aurousseau <i>et al.</i> (1995)	Humeral artery	Yes	ND	ND	ND
Aurousseau <i>et al.</i> (1995)	Popliteal artery	Yes	ND	ND	ND
Dumont <i>et al.</i> (1980)	Cerebral anterior artery	Yes	No	Yes	Yes
Neau <i>et al.</i> (1989)	Middle cerebral artery	Yes	No	Yes	No
Humbert <i>et al.</i> (1973)	Vertebral artery	Yes	No	Yes	Yes
Choktanasiri and Rojanasakul (1995)	Bilateral femoral artery	Yes	Yes	Yes	Yes

HCG = human chorionic gonadotrophin; HMG = human menopausal gonadotrophin; ND = not described.

tion of an OHSS. Some of these seem to be relatively non-specific and related to fluid shifting from the vascular space to the extracellular space. As demonstrated by McClure *et al.* (1994), capillary permeability increases during spontaneous or induced ovulation, mainly caused by a vascular endothelial growth factor (VEGF). Usually, the angiogenesis of spontaneous ovulation is self-limited to one follicle. In the context of induced hyperstimulation, the neovascularization involves multiple follicles. In this case, VEGF production may overflow the ovarian capillary bed, spill over into the peritoneal cavity and promote the formation of ascites. This phenomenon explains the moderate to extreme haemoconcentration and hyperviscosity observed in severe OHSS. As suggested previously (McClure *et al.*, 1994), the measurement of VEGF in the plasma or urine of patients at risk of OHSS would probably improve the safety of IVF and related procedures. Moreover, the stasis of venous blood flow in the pelvic brim and the lower limb is favoured by abdominal distension.

At present, many research groups are focusing their attention on endothelial cell changes and cascade coagulation. Stress-induced leukocytosis is a common finding during severe OHSS. As shown in the umbilical vein, endothelial monolayer cells may be injured by the activation of polymorphonuclear leukocytes, releasing a protease which could impair the fibrinolytic potential of the endothelium (Pintucci *et al.*, 1993). These lesions favour the exposition of a highly thrombogenic extracellular matrix. Blood flow in the damaged vessels promotes adhesion and the spreading of platelets on the surface of this matrix (Kolpakov *et al.*, 1994).

The extrinsic coagulation pathway is triggered by endothelial cell procoagulant activity. This activity is involved in thrombogenesis associated with OHSS and seems to be independent of oestradiol and progesterone plasma concentrations.

Independent of the endothelium-blood interface, humoral modifications of haemostasis factors are associated with high plasma concentrations of oestradiol. When the coagulation cascade is triggered, an oestrogen-induced hypercoagulable state is generated by increased activities of several factors (factor VIII, von Willebrand factor and fibrinogen) and by decreased activities of antithrombin III and protein C (Massafra *et al.*, 1993). The decreased activity of factor VII may be

interpreted as a relative protective mechanism operating at very high plasma concentrations of oestrogen (Bremme *et al.*, 1994). Currently used laboratory tests such as Quick time, accelerated partial thrombin time, fibrinogen or platelet count have all failed to identify a hypercoagulable state. Whole blood clotting time and whole blood clot lysis time, as used by Aune *et al.* (1993), are not available for routine investigation. In-vitro clot-based methods, testing the visco-elastic properties of the thrombus, are sensitive methods which are used to investigate the blood hypercoagulability associated with ovarian stimulation. However, they have failed to describe the platelet and vascular endothelium interface.

In conclusion, whether thrombogenesis is dependent upon important hormonal changes induced by stimulation, vascular damage, haemostasis modifications or all these factors is not clear.

### Conclusion

In our reported case, arterial thrombosis occurred even though a moderate OHSS was present. Although a moderate OHSS was predictable, the risk of arterial thrombosis was not. This emphasizes the importance of informing patients about possible complications associated with stimulation.

### References

- Aune, B., Oian, P. and Østerud, B. (1993) Enhanced sensitivity of the extrinsic coagulation system during ovarian stimulation for in-vitro fertilization. *Hum. Reprod.*, **8**, 1349-1352.
- Aurousseau, M.H., Samana, M.M., Belhassen, A., Herve, F. and Hugues, J.N. (1995) Risk of thromboembolism in relation to an in-vitro fertilization programme: three case reports. *Hum. Reprod.*, **10**, 94-97.
- Bremme, K., Wramsby, H., Andersson, O., Wallin, M. and Blomback, M. (1994) Do lowered factor VII levels at extremely high endogenous oestradiol levels protect against thrombin formation? *Blood Coagul. Fibrinolysis*, **5**, 205-210.
- Choktanasiri, W. and Rojanasakul, A. (1995) Acute arterial thrombosis after gamete intrafallopian transfer: a case report. *J. Assist. Reprod. Genet.*, **12**, 335-337.
- Daniel, Y., Yaron, Y., Oren, M., Peyser, M.R. and Lessing, J.B. (1995) Ovarian hyperstimulation syndrome manifests as acute bilateral hydrothorax. *Hum. Reprod.*, **10**, 1684-1685.
- Delvigne, A., Dubois, M., Batheu, B. *et al.* (1993) The ovarian hyperstimulation syndrome in in-vitro fertilization: Belgian multicentric

- study. II. Multiple discriminant analysis for risk prediction. *Hum. Reprod.*, **8**, 1361–1366.
- Dumont, M., Combet, A. and Domechini, Y. (1980) Thrombose artérielle cérébrale à la suite d'une hyperstimulation ovarienne: grossesse sextuple, avortement thérapeutique. *Nouv. Presse Med.*, **9**, 3628–3631.
- Golan, A., Ron-El, R., Herman, A. *et al.* (1989) Ovarian hyperstimulation syndrome: an update review. *Obstet. Gynecol. Surv.*, **44**, 430–440.
- Humbert, G., Delaunay, P., Leroy, J. *et al.* (1973) Accident vasculaire cérébral au cours d'un traitement par les gonadotrophines. *Nouv. Presse Med.*, **2**, 28–30.
- Kermode, A.G., Churchyard, A. and Carroll, W.M. (1993) Stroke complicating severe ovarian hyperstimulation syndrome. *Aust. N.Z. J. Med.*, **23**, 219–220.
- Kolpakov, V., Adamo, M.C., Salvatore, L. *et al.* (1994) Neutrophil derived cathepsin G induces potentially thrombogenic changes in human endothelial cells: a scanning electron microscopy study in static and dynamic conditions. *Thromb. Haemost.*, **72**, 140–145.
- Massafra, C., Butini, P., Cavion, M.A. *et al.* (1993) Evaluation of risk of thrombosis during use of low-dose ethinylestradiol–desogestrel oral contraceptive. *Adv. Contracept.*, **9**, 195–203.
- McClure, N., Healy, D.L., Rogers, P.A.W. *et al.* (1994) Vascular endothelial growth factor as capillary permeability agent in ovarian hyperstimulation syndrome. *Lancet*, **344**, 235–236.
- Morris, R.S., Paulson, R.J., Sauer, M.V. and Lobo, R.A. (1995) Predictive value of serum oestradiol concentrations and oocyte number in severe ovarian hyperstimulation syndrome. *Hum. Reprod.*, **10**, 811–814.
- Mozes, M., Bogokowsky, H. and Antebi, E. (1965) Thromboembolic phenomena after ovarian stimulation with human gonadotrophins. *Lancet*, **2**, 1213–1215.
- Neau, J.P., Marechaud, M., Guitton, P. *et al.* (1989) Occlusion de l'artère cérébrale moyenne lors d'une induction de l'ovulation par les gonadotrophines. *Rev. Neurol.*, **145**, 859–861.
- Pintucci, G., Iacoviello, L., Castelli, M.P. *et al.* (1993) Cathepsin G-induced release of PAI-1 in the culture medium of endothelial cells: a new thrombogenic role for polymorphonuclear leukocytes? *J. Lab. Clin. Med.*, **122**, 69–79.
- Rabau, E., David, A., Serr, D.M., Mashiach, S. and Lunefeld, B. (1967) Human menopausal gonadotropins for anovulation and sterility. *Am. J. Obstet. Gynecol.*, **98**, 92–98.
- Rizk, B. and Smitz, J. (1992) Ovarian hyperstimulation syndrome after superovulation using GnRH agonists for IVF and related procedures. *Hum. Reprod.*, **7**, 320–327.
- Rizk, B., Meagher, S. and Fischer, A.M. (1990) Severe ovarian hyperstimulation syndrome and cerebrovascular accidents. *Hum. Reprod.*, **5**, 697–698.
- Schenker, J.G. and Ezra, Y. (1994) Complications of assisted reproductive techniques. *Fertil. Steril.*, **61**, 411–422.

Received on October 3, 1995; accepted on April 14, 1996