



Master Thesis of Medicine N° 1735

Computational brain anatomy in patients with temporal lobe epilepsy

Student

Gaëlle Weatherill

Tutor

Pr Bogdan Draganski

Laboratoire de Recherche en Neuroimagerie, LREN

Département des Neurosciences Cliniques, CHUV

Expert

Dr Ueli Kramer

Institut Universitaire de Psychothérapie

Département de Psychiatrie, CHUV

Lausanne, February 2015

Table of contents

Table of contents	2
Abstract	3
1. Introduction	4
1.1. Epilepsy - clinical phenotype	4
1.2. Temporal lobe, hippocampus and limbic system.....	5
1.3. Temporal lobe epilepsy	6
1.3.1. Clinical presentation.....	6
1.3.2. Mesial temporal sclerosis	6
1.3.3. Focal cortical dysplasia.....	8
1.4. <i>Where are we now?</i> Updates on brain imaging in temporal lobe epilepsy.....	9
1.5. Objectives and hypotheses	9
2. Material and methods	10
2.1. Subjects and clinical data.....	10
2.2. MRI acquisition	11
2.3. MRI preprocessing.....	11
2.4. MRI Statistical analysis.....	12
2.5. Clinical features	12
3. Results	13
3.1. Grey matter analysis.....	13
3.2. White matter analysis	15
3.3. Clinical features analysis	18
4. Discussion	19
4.1. Findings in the limbic system	19
4.1.1. Findings in mesio-temporal lobe sclerosis	19
4.1.2. Findings in cryptogenic epilepsy.....	20
4.1.3. Findings in focal cortical dysplasia.....	21
4.2. Findings within the prefrontal cortex.....	22
4.3. Findings in the parietal and occipital lobes.....	23
4.4. Findings in the cerebellum	24
5. Conclusion	25
5.1. Summary and perspectives	25
5.2. Limitations and outlook.....	25
6. Bibliography	26

Abstract

BACKGROUND

Temporal lobe epilepsy (TLE) is a frequent type of focal epilepsy that constitutes 30% to 50% of all epileptic syndromes. This medical condition is often associated with hippocampal sclerosis, however it can be due to cortical dysplasia, brain tumour, vascular malformation or without any evidence for pathology (cryptogenic). Even though the main symptoms are the seizures, epilepsy sometimes interferes with cognitive functions such as visual or verbal memory, language or attention. TLE is frequently pharmaco-resistant and only a hippocampal resection helps patients to become seizure-free. Temporal lobe epilepsy is also described as a progressive disorder that causes chronic brain tissue damages. History of febrile seizures and status epilepticus, frequency of seizures and age at onset of seizure, as well as epilepsy duration or years of anti-epileptic drugs use are all factors that impact the gravity of the brain structure's damage. Magnetic resonance imaging (MRI) has undergone a considerable development and, nowadays, has become an essential clinical tool in the diagnosis of TLE. It is currently used to reveal precisely cerebral abnormalities that may induce seizures.

PURPOSE

The aim of this cross-sectional study is to investigate the pattern of microstructural brain tissue characteristics (grey and white matter volumes) occurring in three *clinically* distinctive TLE entities: mesial temporal sclerosis (MTS), focal cortical dysplasia (FCD) and cryptogenic epilepsy. By comparing them to each other, we want to acquire in-depth knowledge of their pathological mechanism. We use well-established computational anatomy methodology - voxel-based morphometry (VBM) to investigate brain anatomy changes related to the present clinical phenotype.

CONTRIBUTION OF THE STUDY

In the past few years, there has been a lot of controversy concerning structural MRI findings in TLE. Most of the studies looked for informative brain changes in epilepsy with MTS compared with healthy controls. This study is the first to take into consideration all clinical aspects of TLE together - mesial temporal sclerosis, focal cortical dysplasia and cryptogenic epilepsy.

MATERIAL AND METHODS

In-vivo anatomical brain imaging data (MRI at 1.5T) was acquired in patients with clinical diagnosis of temporal lobe epilepsy. TLE patients were divided in three groups according to radiological description of brain MRI findings - mesial temporal sclerosis [MTS_group], focal cortical dysplasia [Dysplasia_group] and cryptogenic epilepsy [NoMRI_group] and compared with healthy volunteers. VBM technique was used to identify brain tissues alterations (GM and WM).

RESULTS

We demonstrate that MTS showed similar grey and white matter volumes reduction in the hippocampus, thalamus and cerebellum ipsilateral to the epileptogenic focus when compared with cryptogenic epilepsy patients and healthy controls. The focal cortical dysplasia patients showed grey matter volume loss restricted to the thalamus.

Key Words: VBM - Temporal lobe epilepsy – MRI - Mesial temporal sclerosis

1. Introduction

1.1. Epilepsy - clinical phenotype

Epilepsy is a common neurological condition characterized by recurrent seizures in response to a disproportionate neuronal activity in a group of neural cells that are localised in a part, or more dispersed throughout the brain. This abnormal neuronal excitability induces a partial or general cerebral network disruption, clinically affecting motor control, sensory perceptions, behaviour and autonomic functions. Seizures are always spontaneous and unprovoked, even though some substantial triggers can facilitate their appearance by increasing the seizure threshold such as sleep deprivation, alcohol, flashlights or loud music expositions, or even strong emotions (1).

Epileptic disorders affect nearly 1% of the population worldwide, and there is no evidence of gender predominance (2). Prevalence is increased in children, young adults and elderly people, but the underlying causes differ with age. As an example, vascular or brain tumour aetiologies are more common in the elderly population, whereas seizures related to genetic syndromes or cryptogenic epilepsy are frequent in the young. However, it remains often difficult to give an exact diagnosis; indeed an identifiable cause of epilepsy is found in only less than fifty per cent of the cases, especially in children and young adults (2).

Considering the fact that numerous aetiologies lead to an epileptic condition, the International League Against Epilepsy Task Force and Terminology (ILAE) proposed a classification of epileptic disorders whose last version was published in 2010 (3). Based on the presented clinical phenotype, they are classified into three major types – i) generalized seizures with subgroups depending on the type of the seizure (tonic, clonic, absence, tonic-clonic, atonic and myoclonic); ii) focal seizures and iii) seizures of unknown origin. Sometimes, focal seizures can evolve and become secondary generalized (4). The ILAE classification determines the potential aetiology of this condition, namely if it is genetic, structural, metabolic or if the real cause is unknown. Thus, focal seizures are more common and an identifiable cause is often discovered with the combination of a magnetic resonance imaging (MRI) and an electroencephalogram (EEG). Finally, it is important to mention if the epileptic disorder is a part of an electro-clinical or surgical syndrome.

In order to classify the epileptic disorder correctly and to have an adequate patient management, the first seizure has to be thoroughly investigated. The diagnostic assessment starts usually with a full medical history, which contains a detailed description of the seizure (before, at the time and after) by a witness and the patient himself. It is also imperative to explore the general history of the patient such as his current medication, a positive history of febrile seizures, his familial background of epilepsy or his past medical history (2). When unprovoked seizures are suspected, the first-line paraclinical exams will always involve brain imaging, usually a brain MRI, to rule out structural abnormalities. Finally, an EEG should complete the exploration.

Protocol for MRI investigations according to Up-to-date (5):

One acquisition should consist of contiguous, thin (<1.5mm) slices covering the entire brain in two orthogonal plans and with one of the orientations involving the oblique coronal image in order to see the hippocampus clearly. Ideally, five sequences should be included in the exam namely the T1-weighted, T2-weighted fast spin-echo sequences, the gradient echo (T2) and the FLAIR sequences. Finally 3D volume images will allow an easier detection of the cortical dysplasia.

1.2. Temporal lobe, hippocampus and limbic system

The hippocampal formation is located in the mesial temporal lobe and constitutes two main structures: the dentate gyrus and the hippocampus proper (6). It has its origins in the archicortex, which features three primitive layers (7). The laminar structure includes four distinct layers (6):

- The alveus with outgoing axons
- The stratum oriens with interneurons
- The stratum pyramidal with pyramidal cells
- The stratum lacunosum and moleculare with dendrites and interneurons

The dentate gyrus is characterised by a three-layer-organisation: the granular, the molecular and the polymorphic cells layers. In the hippocampus proper the stratum pyramidal is furthermore divided into four subfields called the Ammon's horn: The CA1 is the largest region and is in continuity with the subiculum, the CA2 is narrower and has dense neurons, the CA3, forms the curvature of the hippocampus, and the CA4 is located near the dentate gyrus (6). The structures adjacent to the hippocampus, which also belong to the mesial temporal lobe, are the amygdala, the subiculum and the parahippocampal gyrus with the entorhinal cortex. The definition of the hippocampal formation is still disputed and several authors include the subiculum or the entorhinal cortex to the definition.

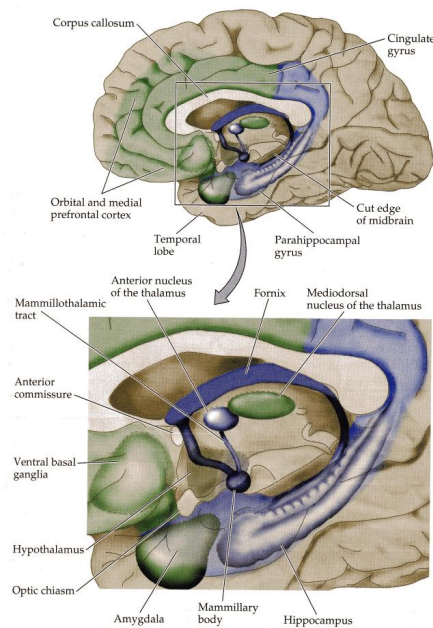


Figure 1 A schematic outline of the limbic system (From *Neurosciences, Purves et al., 2005, p. 695*)

Regardless which definition of the hippocampal formation is used, all these mesial temporal structures form the limbic lobe with the cingulate gyrus and are integrated to the limbic system with the amygdala and the mammillary bodies, in the posterior part of the hypothalamus (8). In addition, few other cortical and subcortical structures are functionally connected to this system - medial prefrontal and orbitofrontal cortices, the anterior and the medio-dorsal thalamic nuclei, and finally the ventral striatum (8). This entire limbic complex plays thereby an important role in the control of the autonomic functions, the emotions and the behaviour (9). However, the main function of the hippocampal formation remains the memory such as the explicit episodic memory, which is the most altered function in case of mesial temporal lobe epilepsy (MTLE) (10). Indeed, a few histological studies discovered that granular cell abnormalities are correlated with learning dysfunction (11).

White matter fibers of the entorhinal region, the cingulum and the fornix form the main afferent tracts of the hippocampus, which receives information from the olfactory areas, the amygdala and a few other neocortical regions. The efferent tracts are mainly located in the fornix, which is separated in pre- and post-commissural fornix, and the stria longitudinalis (7). Other white matter tracts are implicated in the limbic system, enabling thus the structures to be strongly interconnected among them and to form few distinctive brain circuits.

An important circuit of the limbic system is the Papez circuit, described in the mid-20th century and mostly involved in the emotions. Papez demonstrated that the hippocampus sends projections to the mammillary bodies throughout the fornix. The latter connects to the anterior

thalamic nucleus, which is in turn also connected to the cingulate cortex. Finally, fibers from the cingulate cortex reach back the hippocampus via the cingulum (7), (8).

1.3. Temporal lobe epilepsy

1.3.1. Clinical presentation

Temporal lobe epilepsy (TLE) is the most frequent focal epilepsy diagnosed in the adult and mesial temporal sclerosis (MTS) is its most common underlying lesion (12). Focal cortical dysplasia (FCD), also called neocortical epilepsy, is the other frequent anatomical abnormality causing focal epilepsy. Even though TLE is rarely hereditary, it can sometimes be part of a familial genetic syndrome. Besides, the only characteristic that differentiates the familial type from the acquired TLE is a positive family history of epilepsy (13).

1.3.2. Mesial temporal sclerosis

MTS is described as a progressive condition that begins with a precipitating injury and seizures appearing generally in the late childhood, after a few years of latency (11). This first injury can be a traumatism, an intracranial infection (meningitis), or the consequence of a history of complex febrile seizures (FS). In this disorder, events occur with an episode of fever without evidence of intracranial infection. Febrile seizures affect 2 to 5% of children between three months and five years (14). Some MRI studies revealed that several FS are associated with anatomical hippocampal alterations, evolving from an acute hippocampal oedema to atrophy (14). Only 2 to 10% of the children with complex FS will develop epilepsy (14), but most of the patients with diagnosis of MTS had a history of prolonged or complex FS in their childhood. The risk to develop epilepsy is higher in the case of complex FS, when there is a family history of epilepsy, or a neurological impairment is diagnosed before the FS period (14). The use of anti-epileptic drugs is often beneficial at the beginning of the disease and may offer a temporary seizures control but most of the patients become in due course resistant to pharmacological treatment, meaning a loss of seizure control despite the setting up of two distinct and adequate treatment schedules (11). Here, a surgical resection of the epileptogenic focus in the temporal lobe is the last option to help patients to become seizure-free (13).

Clinically, patients with MTLE have a typical pattern of symptoms during the seizure; hence the diagnosis can be established after description of the seizure by a witness and the patient himself. Seizures often start with characteristic sensitive or psychiatric phenomena like epigastric sensation, déjà vu, fear etc. (11), (12). In association with these symptoms, complex partial seizures usually continue with a motor arrest, a motionless stare with pupillary dilatation and impairment of awareness and responsiveness. Automatism could also occur during seizures, whose semiology informs about the location of the focus. Thus, unilateral automatisms, usually involving the hands, are ipsilateral to the seizure focus while the dystonic posturing tends to be contralateral (12). Other signs could inform about the side of the seizure focus, like an alteration of the ictal speech involve rather the non dominant temporal lobe (TL) whereas ictal anomia or postictal dysphasia usually mean an alteration of the dominant TL (11). A relative long period of postictal confusion usually follows the seizures (6). Even if recurrent seizures are the main characteristic occurring in the epilepsy, some cognitive impairment such as language or memory alterations (including the declarative and episodic memories), or even attention deficits are reported as the most important comorbidities related to this condition (11), (15). *Bell et al.* (2011) speculated that heterogeneous cognitive impairments are related to a global alteration of the brain structural integrity involving both the grey and white matter (15). Finally, patients with epilepsy often suffer from mood disorders, particularly anxiety, depression and suicidal ideation. This makes the screening for depression as pertinent part of the follow-up (4).

These past years, MRI has become an important tool in the evaluation of patients with epilepsy, especially in the detection of brain structural abnormalities causing epileptic condition. Standard MRI protocol to detect mesial temporal sclerosis includes coronal slices perpendicular to the long axis of the hippocampus (6). A diagnosis of MTS is suspected if the hippocampal volume is considerably reduced, if the signal intensity is increased on T2-weighted images, or else if the internal architecture is altered (6). Unfortunately, the MRI diagnosis of MTS is in part expert-dependant and 20 to 30% of the patients with chronic focal epilepsy are undiagnosed, meaning that their MRI shows no structural abnormalities (6).

Macroscopically, atrophy of the hippocampus is the main mechanism that occurs in MTS. The histopathology of the epileptic hippocampus is indeed associated with different patterns of neuronal alterations, including the most important abnormality, the loss of pyramidal neurons. The latter is mainly localised in the CA1 and CA4 subfields, with variable loss from CA3 and a relative sparing of the CA2 region and granule cells of the dentate gyrus (6). Furthermore, frequent subsequent pathological phenomena, like chronic fibrillary gliosis in the pyramidal cells layer, could also explain macroscopic hippocampal tissue atrophy and hardening (6). A careful distinction should be made between the hippocampal sclerosis and the MTS, depending on whether the adjacent structures of the hippocampus are affected or not.

Histologically, *Wyler et al.* proposed a grading system to evaluate the severity of the neuronal loss (11). It contains four different grades:

- Grade 1, mild mesial temporal damage (MTD): gliosis with <10% or no neuronal cell loss in CA1, CA3 and/or CA4
- Grade 2, moderate MTD: gliosis with 10 to 50% neuronal cell loss in CA1, CA3 and/or CA4
- Grade 3, moderate to marked MTD: gliosis with more than 50% neuronal dropout in CA1, CA3 and CA4, with sparing of CA2 (this grade is also called the classical Ammon's horn sclerosis),
- Grade 4, marked MTD: gliosis with more than 50% neuronal cell loss in all sectors of the hippocampus. The extra-hippocampal mesial temporal lobe can also be involved (this grade is the equivalent to the total Ammon's horn sclerosis).

A second pathophysiological mechanism involved in the mesial temporal sclerosis is the propensity of the neurogenesis to increase in the acute phase of the disease. That is a throughout life mechanism involving new stem cells (NSCs) proliferation, mainly residing in the subgranular zone of the dentate gyrus. Phases of differentiation and migration into the granule cells layer of the dentate gyrus allow the newly dentate granule cells (DGCs) to become functionally integrated into the hippocampal circuitry in nearly four weeks (16), (17), (18). To date, the implication of the hippocampus, more specifically the dentate gyrus, is well known in the learning process and memory acquisition and neurogenesis tends to play a major role to maintain these functions throughout life (16), (18). Physiological stimuli, like physical exercises, could positively influence this neuronal production. But pathological phenomena as seizures activity could also induce abnormal hippocampal neurogenesis, essentially in the

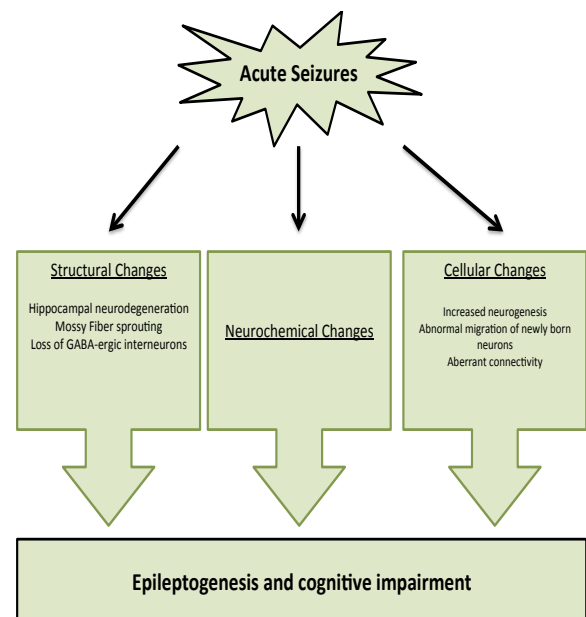


Figure 2 A schematic outlines of pathological mechanism in Mesial Temporal Sclerosis, inspired from the report of *Kuruba et al.* (2010)

early stage of the disease (18). Indeed, after a latency of a few days, acute seizures increase not only the NSCs proliferation but also accelerate their differentiation and induce aberrant migration through the dentate hilus or the dentate molecular layer (17), (18). Even though this abnormal activity is temporary and only lasts few weeks before the NSCs proliferation goes back to baseline level, this pathological mechanism is sufficient to permanently alter the neuronal interconnectivity through the hippocampal complex (18). Indeed, two main cell alterations remain persistent: the ectopic granule cells, resulting from the aberrant migration, and the persistence of the hilar basal dendrites in the newly granule cells, a feature of immature DGCs (17). Both of these alterations raise the propensity of an aberrant circuitry, leading to a future chronic epileptogenic network.

In the chronic stage of the epilepsy, neurogenesis is drastically decreased (19). Although the real pathological mechanism explaining this reduction remains still unknown, several potential reasons were mentioned these last few years: the chronic inflammatory conditions, neural stem cells depletion, decreased number of neural stem cell mitogenic or growth factors leading then to an altered neuronal differentiation (18), (19). Aside from maintaining spontaneous seizures activity, neurogenesis depletion in the chronic stage of epilepsy is also suspected to drastically impair the hippocampal-dependant cognitive functions such as learning and memory acquisition (16), (17).

Mossy fibers' sprouting is another seizure-induced mechanism bringing the hippocampus to an epileptic condition. Mossy fibers are axons from glutamatergic dentate gyrus cells that usually project into the pyramidal cells and interneurons of the CA3 and the CA4 subfields (6), (17). In epileptic condition, mossy fibers from adult-born DGCs at the time of the acute seizure will sprout some axonal collaterals, whose synapses will directly connect other granule cells into the dentate molecular layer, inducing then a recurrent excitatory network and increasing the seizures susceptibility (17). MTS is often associated with other pathological alterations such as a low-grade tumour, but also vascular or cortical malformations (6). Among these lesions, the focal cortical dysplasia could also be present with the hippocampal atrophy.

To summarize, all these pathophysiological mechanisms lead to an anatomical and functional neuronal reorganisation, not only in the hippocampal formation but also in the mesial temporal lobe and regions beyond. As the mesial temporal lobe epilepsy is a progressive disorder, damages mainly follow different steps, including a progression of the hippocampal atrophy and the presence or not of some collateral alterations. This reorganisation usually leads to epileptogenesis, meaning an increasing of the epileptic threshold.

1.3.3. Focal cortical dysplasia

Focal cortical dysplasia arises from a disruption of the cortical development consisting of three main stages: proliferation of undifferentiated cells, neuroblasts migration and cells differentiation into mature neurons or glia (20). Depending on when the disruption occurs in the development, a pattern of cortical malformations could appear, ranging from abnormalities of cortical lamination to alterations of the neuronal maturation, or even neuronal differentiation (20). This could affect only a small cortical region or be much more expended and affect several lobes. According to the International League Against Epilepsy's (ILAE) classification established in 2010, focal cortical dysplasia is separated in three main types. The first one refers to an isolated malformation mainly due to the dyslamination while the second type includes the presence of dysmorphic neurons following an abnormal cell development and maturation. The third type contains all the focal cortical dysplasia associated with another pathology that occurs during development such as the hippocampal sclerosis, gangliomas, adjacent vascular malformations or other acquired epileptogenic lesions (21).

The histo-pathological changes in focal cortical dysplasia follow a broad spectrum, going from a cortical disorganization to cytological abnormalities such as balloon cells, large dysmorphic neurons or gliosis (22). On MRI, the presence of a visible abnormality is associated with the degree of histo-pathological derangement. The two main alterations found in a standard MRI with T1-weighted images would be a thickening of the cortex and an erasure of the grey-white matter boundary. Whereas the signal of the subjacent white matter is often decreased, no changes were found in the grey matter. Finally, the intensity of the grey matter is often increased on the T2-weighted images (22).

1.4. Where are we now? Updates on brain imaging in temporal lobe epilepsy

To date, neuroimaging plays a major role in the establishment of accurate diagnosis, the clinical evaluation and the therapeutic management of drug-resistant epilepsy. Noninvasive and safe, MRI is a highly sensitive and specific tool for identification of mesial temporal sclerosis or focal cortical dysplasia. It is also the modality of choice in the diagnosis of first epileptic seizure (11). Indeed, MRI determines the potential focus inducing the epileptic conditions and, by allowing the complete resection of the epileptic zone, renders the post surgical outcome more favourable (22). But MRI imaging misses significant pathology in 20 to 30% of the patients with chronic focal epilepsy (6). Thus, the qualitative character of neuro-radiological MRI assessment is not sufficient to diagnose focal epilepsy alone and has to be performed with other paraclinical exams where clinical features are also taken into consideration.

Computational anatomy describes a plethora of well-established automated tools for assessment of brain anatomy and allowing a better comprehension of the different epileptic conditions. To date, two main methods have been used to perform a morphometric analysis. The first one consisted in comparing tissue abnormalities in an *a priori* region of interest (ROI) between two groups of subjects. Indeed, most of these studies focused their analyses to regions that were already known to be strongly involved in TLE such as the hippocampus and areas nearby. Voxel-based morphometry studies (VBM), a whole brain automatic quantitative technique, were thereafter increasingly used, up to be the method of choice to analyse grey and white matter alterations at a voxel level. This technique could first confirm the tissues alterations in regions previously described in the ROI works. But VBM studies also reported many extra-hippocampal and extra-temporal areas of focal structural changes throughout the brain. Most of the VBM studies perform comparison between a group of patients with drug-resistant MTS and a group of healthy volunteers and only few studies included patients with cryptogenic TLE or patients with focal cortical dysplasia.

1.5. Objectives and hypotheses

With this study, we aimed to characterize the distribution of brain structural abnormalities between the three most frequent entities of temporal lobe epilepsy namely, the mesial temporal sclerosis, the focal cortical dysplasia and epilepsy without MRI significant alterations. We also want to characterize potential links between these three entities in order to better understand the pathological mechanisms underlying these conditions. Our two hypotheses are:

- MTS is a progressive disease, starting from a clinical diagnosis of temporal lobe epilepsy without any significant brain alteration on standard MRI, and evolving to hippocampal atrophy in the chronic stage of the disease. Thus, we suspect that the group of patients without any pathological MRI has actually a diagnosis of mesial temporal sclerosis but are in the early stage of the disease.
- Subjects with a diagnosis of mesial temporal sclerosis will rather show alterations in regions strongly connected to the limbic system than patients with focal cortical dysplasia. This would thus suggest a disruption of the limbic network, starting from the epileptic hippocampus.

2. Material and methods

2.1. Subjects and clinical data

We acquired data in 153 patients with diagnosis of unilateral temporal lobe epilepsy and 120 healthy volunteers (age- and sex-matched). Criteria of TLE used for this study were taken from the classification and terminology of the ILAE (version from 1989), which set up its diagnostic scheme into five axes: ictal phenomenology, seizure type, syndrome, etiology and impairment (23). Clinical description included seizure's phenomenology, age of epilepsy onset and its duration, drug-resistance and progressive nature of the disease. A long-term video electroencephalography monitoring and MRI images supplemented the investigations in order to find the epileptogenic zone and its lateralization. Patients with an unclear laterality of seizure onset were excluded from the study as well as people with history of brain trauma, drug/alcohol abuse, history of ischemic lesions or brain tumours.

Patients with TLE were separated into three main groups according to their MRI criteria at the time of diagnosis. The first group included 57 patients with signs of hippocampal atrophy, namely **the MTS_group** for Mesial Temporal Sclerosis. (34 men and 23 women; mean age 39.77 years \pm 10.54, range 19-58 years). Two subgroups were then formed regarding the side of the epileptogenic focus, 27 right-sided and 30 left-sided patients.

Then, 26 patients with abnormal MRI findings that could explain the seizures but without MRI evidence of MTS formed the second group (11 men and 15 women; mean age 34.81 years \pm 10.58, range 25-65 years). This group essentially concerned patients with focal cortical dysplasia, the second most frequent aetiology in temporal lobe epilepsy, reason why we named it **the Dysplasia_group**. These patients were also split in two subgroups, 14 right-sided and 12 left-sided ones.

Finally, 70 patients without any detected abnormalities in the clinical MRI were assigned to the third group, **the NoMRI_group** (35 men and 35 women; mean age 36.87 years \pm 11.08, range 19-63 years). 29 right-sided and 41 left-sided patients composed the last two subgroups.

These three groups were also compared to the **Control_group**, composed of 120 healthy subjects (57 men and 63 women, mean age 36.00 years \pm 9.93, range 17-60 years).

A summary of distinctive features such as mean age, mean age of epilepsy onset, mean disease duration and crisis frequency repartition of each group is detailed in the table below:

	Control_group	MTS_group	Dysplasia_group	NoMRI_group
Number of subjects	120	57	26	70
Number Men/Women	57 / 63	34 / 23	11 / 15	35 / 35
Mean age, years (Mean \pm SD)	36.01 \pm 9.93	39.77 \pm 10.54	34.81 \pm 10.58	36.87 \pm 11.08
Mean age of epilepsy onset, years (Mean \pm SD)		15.61 \pm 13.35	13.86 \pm 10.89	21.96 \pm 14.70
Mean disease duration, years (Mean \pm SD)		24.16 \pm 13.47	20.95 \pm 11.82	14.91 \pm 11.80
Crisis frequency, Weekly/Monthly/Yearly (%)		17.5% / 70.2% / 12.3%	34.6% / 57.7% / 7.7%	28.6% / 50% / 21.4%
Number R-sided/L-sided		27 / 30	14 / 12	29 / 41

2.2. MRI acquisition

All MRI data was acquired on a 1.5T MRI scanner (Philips INTERA system, Philips Medical Systems, Best, Netherlands). 150 contiguous slices in a T1-weighted sequence were obtained as follows: TE / TR = 4.6ms / 30ms, flip angle of 30°, FOV = 250mm, matrix = 256x256, voxel size = 1x1x1mm.

2.3. MRI preprocessing

Voxel-based morphometry is a computational anatomy method using the voxel wise spatial precision and allowing statistical analysis of the entire brain without the need to define a specific region of interest. In this study, all MRI analyses were executed with the Statistical Parametric Mapping software, version SPM8 (<http://www.fil.ion.ucl.ac.uk/spm>), running under Matlab R2013a (MathWorks Inc., Sherborn, MA).

In order to allow statistical comparisons VBM necessitates the exact spatial match of all MRI data in a common stereotactic space. Here, all images are registered to the same template image. In other terms, all MRI images are laid on an identical coordinates' system previously chosen, usually the montreal neurological institute (MNI) space. This step assures that the spatial localisation of given structure in one subject's brain is corresponding to the same location in another subjects'. Two distinct steps are needed to perform this normalisation. The first step consists in matching the images with a template by estimating the optimum 12-parameter affine transformation. In order to accomplish that, a Bayesian framework allows to estimate a maximum *a posteriori* spatial transformation from an *a priori* information of the normal brain size variability (24). The second step considers the global nonlinear shape differences modelled by a linear combination of smooth spatial basis functions. The purpose of this nonlinear registration is to minimize the residual squared difference between the image and the template, and to maximize the smoothness of the deformations (24).

Previously, SPM used ca. 1000 coefficients to model accurately the shape of the brain. To perform an optimal inter-subject alignment, we used the DARTEL registration (diffeomorphic anatomical registration through exponentiated lie algebra), which includes more than 6'000'000 parameters per voxel (25).

The intertwined step parallel to spatial registration - segmentation enables us to classify brain anatomy into three main tissue compartments - grey matter, white matter and cerebro-spinal fluid (CSF). This segmentation part is usually done with two distinct tasks (24). First, an *a priori* probability map is used to encode information about the spatial distribution of different tissues in normal subjects. A mixture model cluster analysis allows to recognize voxel intensity distribution of particular tissue types in a second time (24), suggesting that voxels are assigned to a tissue class depending on their intensity. By studying these compartments independently, one obtains a straightforward interpretation of the underlying anatomical substrate without the risk of compromising results by noise from other tissue classes.

Because normalisation generates local volume compressions and expansions in order to match with the template (26), all grey matter and white matter values are multiplied by the Jacobian determinants, which restores the same voxel intensity as in the original image. This optional step is called "modulation" and allows the interpretation of statistical results as volume differences in a particular tissue. In that case, the absolute volume needs to be preserved by multiplying the spatially normalised tissue class with its relative volume before and after the spatial normalisation. Otherwise, results without any modulation would be interpreted as relative concentration differences of structures components between two groups of images(26).

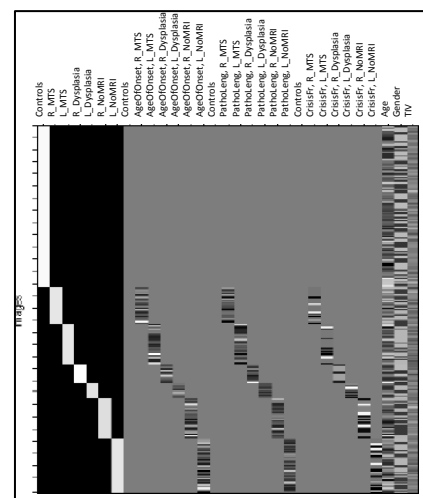
MRI images are finally spatially smoothed such that the intensity of a voxel is changed by the weighted average of the surrounding voxels; the size of the region is then defined by the size of the smoothing kernel (27). This last step consists in convolving with an isotropic Gaussian Kernel, usually with a 12-mm FWHM kernel, to bring the data closer to the Gaussian field model (27). Smoothing also renders the data more normally distributed by the central limit theorem with a better validity of statistical tests as a consequence (24). This step finally reduces the variance between subjects and therefore increases the capacity to detect structural changes across them (28).

Once all images were pre-processed, masks delimiting the grey or the white matter were applied to be sure to exclude all the voxels without any significant interest for our statistical analysis. Throughout this process, analyses tend to be more and more sensitive (29).

2.4. MRI Statistical analysis

Based on the general linear model (GLM), the voxel-wise statistical analysis is essentially used for groups comparisons or to detect regions of altered grey matter or white matter volume that are related with some covariates characterizing the data (30).

This full factorial analysis integrated a total of six subgroups of patients (right and left-MTS, -Dysplasia and -noMRI) plus one control group in a one-designed matrix. Age, gender and trans-intracranial volume (TIV) were then added in this model as covariates. These three covariates enabled all groups to match together by minimising their influence on the volume's differences. Finally, three other covariates were incorporated in the matrix: age of epilepsy onset, disease duration and seizures frequency.



Once the comparison tests performed, each result came in the form of a parametric map showing the location of the grey and white matter alterations, one group in regard to the other. All comparisons were done with a threshold at a P-value of <0.001 FWE corrected. Results were then superimposed on a T1-weighted template. Several atlases were used to specify the exact spatial location of altered brain regions: the Anatomical Automatic Labeling (AAL) for the grey matter (31), the JHU (Johns Hopkins University) white-matter tractography atlas and the SUIT toolbox for the cerebellum (32).

2.5. Clinical features

Last part of our study consisted in analysing the clinical features between the three groups and the healthy volunteers. The statistical software Stata (version 12) was used to perform these comparisons. Two-sample *t* test with equal variance were done with a significance level of $P < 0.05$ to analyse this data.

3. Results

3.1. Grey matter analysis

In this study, we first compared the three groups of patients with TLE together, and with a group of healthy volunteers. These analyses were then repeated, but considering the distinction of seizure focus in the three groups of patients this time. Regions with significant reduced grey matter volume (GMV), with a threshold of $P < 0.001$ corrected for multiple comparisons, are summarized in the table 2 below.

All_groups tests	Cluster		Anatomical location			Voxel Wise			MNI coordinates (mm mm mm)		
	Size	Pfwe_corr	location	Ipsi/Contra	Sided	Pfwe_corr	T	Z-score	X	Y	Z
Control > MTS	5417	0.000	Hippocampus		Right	0.000	8.74	Inf	32	-20	-12
			Thalamus		Right	0.000	6.86	6.55	6	-11	2
	1701	0.007	Cerebellum		Left	0.097	4.40	4.31	-10	-71	-57
Control < MTS	1415	0.015	Cerebellum		Right	0.302	4.04	3.97	22	-65	-43
	169	0.720	Caudate		Left	0.046	4.61	4.51	-15	-3	27
Control > rMTS	6986	0.000	Hippocampus	Ipsi	Right	0.000	12.62	Inf	31	-18	-13
Control > IMTS	178	0.702	Inferior temporal gyrus	Ipsi	Right	0.000	7.11	6.78	15	-21	8
	1040	0.043	Hippocampus	Ipsi	Left	0.004	5.22	5.08	-27	-18	-18
	1030	0.045	Thalamus	Ipsi	Left	0.057	4.55	4.45	-6	-11	3
	4762	0.000	Cerebellum	Contra	Right	0.070	4.49	4.40	-26	-56	-63
rMTS > IMTS	1954	0.004	Parahippocampal gyrus	Ipsi	Left	0.002	5.36	5.21	-22	-35	-3
			Hippocampus	Ipsi	Left	0.002	5.34	5.19	-26	-18	-19
rMTS < IMTS	799	0.091	Middle temporal gyrus	Ipsi	Left	0.016	4.88	4.76	-57	-35	-7
			Hippocampus	Ipsi	Right	0.000	9.69	Inf	31	-17	-15
	5266	0.000	Thalamus	Ipsi	Right	0.268	4.08	4.01	8	-8	17
Dysplasia > MTS	2367	0.001	Hippocampus		Right	0.000	6.56	6.29	31	-17	-15
	rDysplasia > rMTS	3640	0.000	Hippocampus	Ipsi	Right	0.000	8.75	Inf	33	-17
NoMRI > MTS	4741	0.000	Hippocampus		Right	0.000	8.36	7.82	33	-17	-15
rNoMRI > rMTS			Thalamus		Right	0.093	4.41	4.32	10	-29	-1
	5284	0.000	Hippocampus	Ipsi	Right	0.000	9.58	Inf	31	-18	-15
lNoMRI > IMTS			Thalamus	Ipsi	Right	0.057	4.55	4.45	10	-30	3
	2177	0.002	Hippocampus	Ipsi	Left	0.000	6.32	6.08	-26	-17	-21
	10746	0.000	Parahippocampal gyrus	Ipsi	Left	0.267	4.08	4.01	-22	-35	-1
Control > Dysplasia			Cerebellum VIII	Contra	Right	0.104	4.38	4.29	14	-42	-55
			Cerebellum VII	Contra	Right	0.147	4.28	4.20	32	-62	-46
	1011	0.047	Thalamus		Right	0.245	4.11	4.04	8	-11	6
Control > rDysplasia			Thalamus		Left	0.268	4.08	4.01	-3	-12	8
	1114	0.035	Thalamus	Ipsi	Right	0.115	4.35	4.26	8	-11	8
	1136	0.033	Superior temporal gyrus	Ipsi	Right	0.218	4.15	4.08	52	-27	15
Control > NoMRI			Insula	Ipsi	Right	0.315	4.03	3.96	46	-12	15
	268	0.533	Inferior frontal gyrus		Left	0.047	4.60	4.50	-44	24	20
Control < NoMRI	1038	0.044	Hippocampus		Left	0.090	4.42	4.33	-22	-2	-16
Control > lNoMRI	992	0.050	Superior motor area	Ipsi	Left	0.466	3.87	3.81	-15	-6	72
Control < lNoMRI			Hippocampus	Ipsi	Left	0.002	5.43	5.27	-21	-3	-15
	6778	0.000	Hippocampus	Contra	Right	0.089	4.42	4.34	22	0	-15
			Mammillary bodies	Contra	Right	0.159	4.25	4.17	4	4	-13

* Borderline results with $P < 0.06$

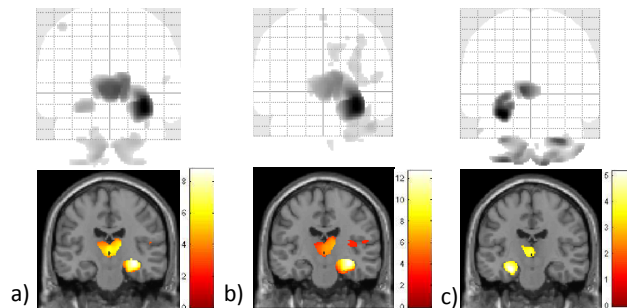


Figure 3 GMV reduction in MTS compared to healthy subjects: a) Right-sided and left-sided MTS together b) Right-sided MTS c) Left-sided MTS

A significant GMV reduction was found in the right hippocampal formation and parahippocampal gyrus when the MTS_group was compared to the three other groups (Fig. 3a-4a-5a). When the threshold was extended to a $P < 0.05$ corrected, GMV in the left hippocampus was also decreased in the MTS_group in all the three comparisons. This was the unique region observed with a significant grey matter volume reduction between patients with MTS and patients with FCD (Fig. 4) whereas a reduction in the bilateral thalamus was also detected in MTS when compared to the Control_group or the NoMRI_group. Finally, cerebellum was also decreased in the MTS_group related to the Control_group (Fig. 3-5).

Each patients' group was then separated in two subgroups regarding the side of seizure focus. When comparing patients with diagnosis of right MTS to the Control_group or the right NoMRI subgroup, a GMV reduction was detected in the ipsilateral hippocampal formation and thalamus (Fig. 3b-5b), whereas only the ipsilateral hippocampus was decreased in comparison with the right Dysplasia_subgroup (Fig. 4b).

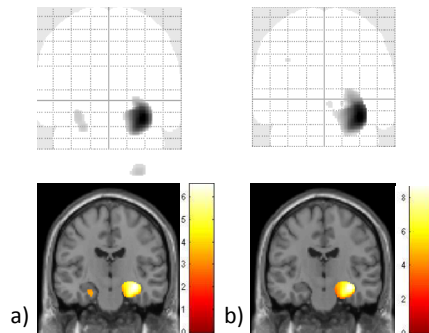


Figure 4 GMV reduction in MTS compared to the Dysplasia_group: a) Right-sided and left-sided subgroups together
b) Right-sided subgroups only

When the left-sided subgroups were considered, significant regions of the bilateral cerebellum were also reduced in addition with the ipsilateral hippocampal formation in patients with MTS compared to the Control_group and the left NoMRI subgroup (Fig. 3c-5c). Finally, a significant reduction of the ipsilateral thalamus was also identified in the left MTS_subgroup in comparison with the group of volunteers (Fig. 3c). The comparison between patients with left-sided dysplasia and with left-sided MTS showed no significant differences.

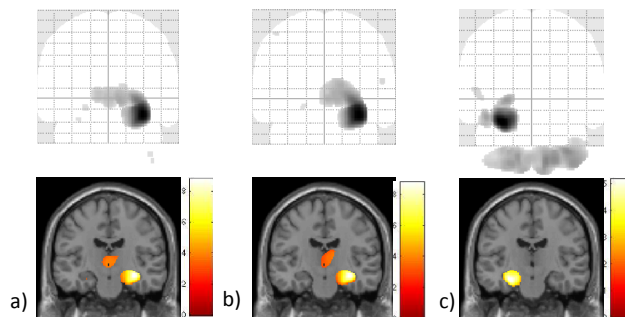


Figure 5 GMV reduction in MTS compared to the NoMRI_group: a) Right-sided and left-sided subgroups together
b) Right-sided subgroups only c) Left-sided subgroups only

When the two MTS_subgroups were compared together, a GMV reduction in the ipsilateral hippocampal formation and the thalamus was found in the right-sided MTS_subgroup. GMV reduction was also detected in the ipsilateral hippocampal and extra-hippocampal temporal regions in patients with left MTS.

When patients with FCD were compared to the Control_group, a significant GMV reduction was discovered in the bilateral thalamus. This same location was affected ipsilaterally when right-sided subgroup was taken into consideration (Fig. 6). Extra-hippocampal regions of the temporal lobe (i.e superior temporal gyrus and insula) were also reduced in this comparison.

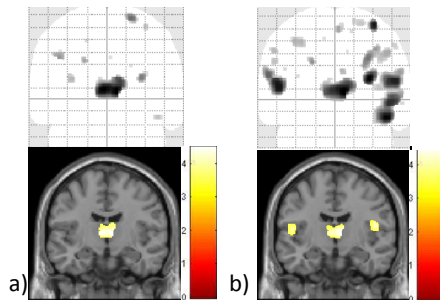


Figure 6 GMV reduction in the Dysplasia_group compared to the healthy volunteers: a) Right-sided and left-sided subgroups together b) Right-sided subgroup only

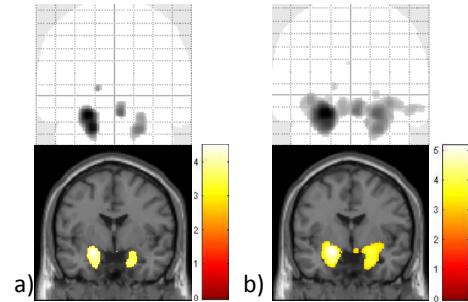


Figure 7 GMV increase in the NoMRI_group compared to the healthy volunteers: a) Right-sided and left-sided subgroups together b) Left-sided subgroup only

Control_group had also a small region of significant GMV increase in the left frontal lobe (i.e the left inferior frontal gyrus) in comparison with the NoMRI_group. Finally, no significant GMV alterations were detected when the Dysplasia_group and the NoMRI_group were compared together.

Only few regions of significant increased GMV were detected in patients' groups in comparison with the Control_group. The left medial caudate nucleus was increased in the MTS_group in regards to the Control_group. When the latter was compared to the NoMRI_group this time, GMV was significantly augmented in the left hippocampus in the patients' group. This location was also bilaterally increased when only the left-sided patients were taken into account (Fig 7).

3.2. White matter analysis

This second part of the study considered the white matter volume (WMV) differences in between patients with temporal lobe epilepsy and the healthy subjects. To that end, same analyses as in chapter 3.1 were repeated, the only difference being that the white matter was taken into account this time. All significant results are summarised in the table 3 below.

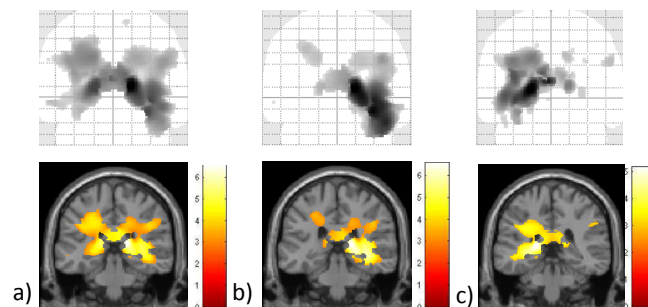


Figure 8 WMV reduction in MTS compared to healthy subjects: a) Right-sided and left-sided MTS together b) Right-sided MTS c) Left-sided MTS

Table 3 Reduction of White Matter Volume (WMV)

All_groups Tests	Cluster		Anatomical location			Voxel Wise			MNI coordinates (mm mm mm)		
	Size	Pfwe_corr	location	Ipsi/Contra	Sided	Pfwe_corr	T	Z-score	X	Y	Z
Control > MTS	29083	0.000	Anterior thalamic radiation		Right	0.000	6.99	6.66	16	-32	9
			Anterior thalamic radiation		Left	0.000	5.76	5.57	-16	-35	8
			Inferior longitudinal fasciculus		Right	0.000	5.72	5.53	33	-35	-3
Control > rMTS	13692	0.000	Anterior thalamic radiation	Ipsi	Right	0.000	6.76	6.46	16	-32	8
			Inferior fronto-occipital fasciculus	Ipsi	Right	0.000	6.51	6.24	33	-14	-12
Control > lMTS	18705	0.000	Anterior thalamic radiation	Ipsi	Left	0.000	5.65	5.47	-20	-35	8
rMTS < lMTS	3026	0.001	Inferior longitudinal fasciculus	Ipsi	Right	0.002	5.22	5.08	44	-20	-22
			Anterior thalamic radiation	Ipsi	Right	0.019	4.62	4.51	34	-15	-9
Dysplasia > MTS	1285	0.029	Anterior thalamic radiation		Right	0.030	4.5	4.4	21	-33	3
Dysplasia < MTS	119	0.626	Inferior fronto-occipital fasciculus		Right	0.037	4.44	4.35	28	-87	10
rDysplasia > rMTS	800	0.092	Anterior thalamic radiation	Ipsi	Right	0.055*	4.33	4.24	21	-32	3
NoMRI > MTS	4340	0.000	Superior longitudinal fasciculus		Left	0.018	4.62	4.52	-28	-35	45
	3360	0.001	Inferior longitudinal fasciculus		Right	0.030	4.49	4.40	36	-32	8
			Superior longitudinal fasciculus		Right	0.072	4.25	4.17	45	-35	32
			Cingulum		Right	0.190	3.95	3.89	10	-36	35
rNoMRI > rMTS	1914	0.008	Inferior longitudinal fasciculus	Ipsi	Right	0.086	4.20	4.13	34	-33	3
			Inferior fronto-occipital fasciculus	Ipsi	Right	0.683	3.40	3.36	24	-30	-1
lNoMRI > lMTS	2794	0.001	Superior longitudinal fasciculus	Ipsi	Left	0.019	4.61	4.51	-26	-60	24
			Anterior thalamic radiation	Ipsi	Left	0.171	3.99	3.92	-6	-18	15
Control > rDysplasia	3058	0.001	Superior longitudinal fasciculus	Ipsi	Right	0.003	5.07	4.94	50	-41	-6
			Inferior longitudinal fasciculus	Ipsi	Right	0.075	4.24	4.16	50	-32	-9
Control < rDysplasia	140	0.588	Cingulum	Ipsi	Right	0.002	5.12	4.99	16	-57	21
Control < lNoMRI	319	0.345	Superior longitudinal fasciculus	Ipsi	Left	0.030	4.50	4.40	-45	19	24
rDysplasia > rNoMRI	77	0.709	Cingulum	Ipsi	Right	0.020	4.60	4.50	16	-57	21

* Borderline results: P<0.06

White matter tracts in patients with MTS were mostly altered in the region of the temporal lobe in comparison with the three other groups (Fig. 8-9-10). When the MTS_group was compared to the Control_ or the Dysplasia_groups, a significant WMV reduction was discovered in the anterior thalamic radiations, bilaterally for the first comparison and only localised in the right side for the second one (Fig 8a-9a). This white matter tract was decreased ipsilaterally when the right- and left-sided MTS_subgroups were compared to the Control_group and when only the right-sided subgroups with MTS and Dysplasia were analysed together (Fig 8a-8b-9b). WMV was also reduced in a portion of the right inferior longitudinal fasciculus when the MTS_group was compared to the Control_group, whereas WMV would rather be reduced in the ipsilateral inferior fronto-occipital fasciculus in the right-sided subgroup of patients with MTS.

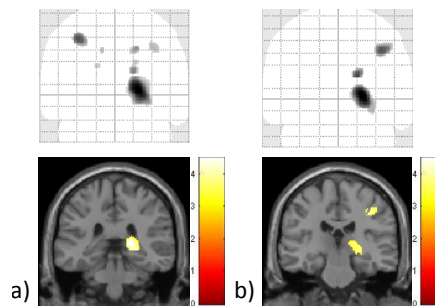


Figure 9 WMV reduction in MTS compared to the Dysplasia_group: a) Right-sided and left-sided subgroups together b) Right-sided subgroups only

In the comparison between the NoMRI_group and the MTS_group, more widespread regions of reduced WMV were detected in patients with MTS involving the parietal and the temporal lobes (bilateral superior longitudinal fasciculi, right inferior longitudinal fasciculus and right cingulum). Both regions were similarly altered ipsilaterally whether the right side or the left side was taken into consideration (Fig. 10).

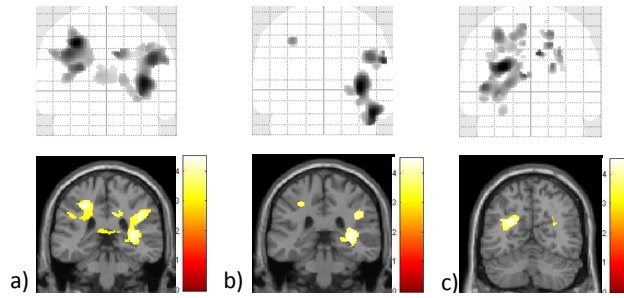


Figure 10 GMV reduction in MTS compared to the NoMRI_group: a) Right-sided and left-sided subgroups together b) Right-sided subgroups only c) Left-sided subgroups only

When the two MTS_subgroups were analysed together, a significant WMV reduction was detected in the ipsilateral anterior thalamic radiation and inferior longitudinal fasciculus in the right-sided MTS. No significant WMV decrease was discovered in patients with a left seizure focus.

When the right-sided Dysplasia_subgroup was compared to the Control_group, white matter volume was reduced in areas of the ipsilateral temporal lobe while a small cluster of white matter volume increase was revealed in the ipsilateral cingulum (Fig. 11). On the contrary, the left-sided Dysplasia_subgroup showed no significant white matter tract alterations compared to the healthy volunteers.

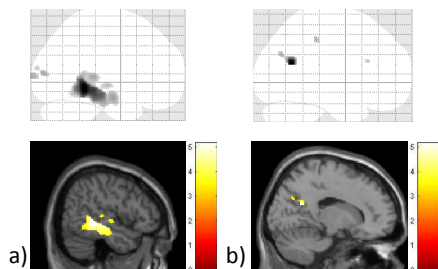


Figure 11 a) WMV **reduction** in the right-sided Dysplasia_subgroup in regards to the healthy volunteers b) WMV **increase** in the right-sided Dysplasia_subgroup in comparison with the Control_group

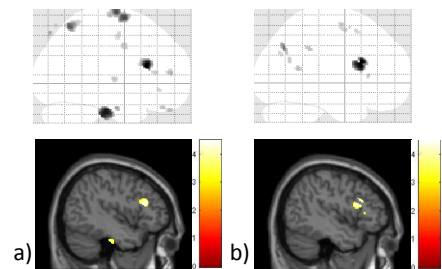


Figure 12 a) GMV **decrease** in the left-sided NoMRI subgroup compared to the Control_group b) WMV **increase** in the left-sided NoMRI subgroup in comparison with the healthy volunteers

In the comparison of patients without any evidence of brain alteration on MRI and with a left seizure focus to the healthy volunteers, a significant white matter volume increase was found in the region of the ipsilateral prefrontal lobe, the most susceptible WM tracts to be altered being the ipsilateral superior longitudinal fasciculus.

Finally, when the right-sided patients of the Dysplasia_group were compared to the right-sided patients of the NoMRI_group, the first subgroups showed significant white matter volume increase located in the ipsilateral cingulum.

3.3. Clinical features analysis

In our data, clinical features analyses showed that populations in the MTS_group and the NoMRI_group were age-matched ($P>0.05$). The age of epilepsy onset was significantly smaller in the MTS entity than in the NoMRI_group ($P=0.0064$), and the disease duration was significantly higher for the MTS_group ($P=0.0000$).

Comparable results were found for the comparison between the Dysplasia_group and the NoMRI_group. Indeed, similar populations constitute both groups ($P>0.05$) but the Dysplasia_group showed significant lower age of epilepsy onset than the NoMRI_group ($P=0.0061$) and had longer disease duration, too ($P=0.0141$).

Finally, the age of the MTS_group was significantly higher than the one of the Dysplasia_group ($P=0.0251$). However, both age of epilepsy onset and disease duration were similar in the two groups ($P>0.05$ found in both comparisons).

Table 4 Clinical features analyses

Clinical features	Mesial Temporal Epilepsy groups			Difference (Diff): ₁₋₂	P value in the following hypotheses :		
	MTS_group	Dysplasia_group	NoMRI_group		Ho: Diff = 0	Ho: Diff > 0	Ho: Diff < 0
Mean age (years)	39.77193 ₂	34.80769 ₁		-4.964238	0.0503	0.0251	0.9749
Mean age of epilepsy onset (years)	15.60877 ₁	13.85769 ₂		1.75108	0.5601	0.7200	0.2800
Mean disease duration (years)	24.16316 ₁	20.95000 ₂		3.213158	0.2987	0.8506	0.1494
Mean age (years)	39.77193 ₂		36.87143 ₁	-2.900501	0.1364	0.0682	0.9318
Mean age of epilepsy onset (years)	15.60877 ₁		21.96286 ₂	-6.354085	0.0129	0.0064	0.9936
Mean disease duration (years)	24.16316 ₁		14.90857 ₂	9.254586	0.0001	1.0000	0.0000
Mean age (years)		34.80769 ₂	36.87143 ₁	2.063736	0.4141	0.7930	0.2070
Mean age of epilepsy onset (years)		13.85769 ₁	21.96286 ₂	-8.105165	0.0121	0.0061	0.9939
Mean disease duration (years)		20.95000 ₁	14.90857 ₂	6.041429	0.0283	0.9859	0.0141

4. Discussion

In this computational anatomy study we investigated the correlation between clinical features and brain anatomy in patients with chronic epilepsy. We found characteristic brain anatomy patterns in patients with diagnosis of TLE going beyond conventional radiological assessment at the time of diagnosis. We not only bring strong evidence for limbic and extra-limbic abnormalities in patients with mesial temporal sclerosis, we much more observed wide-spread differential brain pathology in patients without evident neuroradiological abnormalities. We interpret our findings as evidence for the dynamic and plastic nature of the mature human brain where neurogenesis with initial hippocampus enlargement in early epilepsy is followed by atrophy in the chronic stage of disease.

4.1. Findings in the limbic system

4.1.1. Findings in mesio-temporal lobe sclerosis

The most prominent brain anatomy feature in epilepsy concerns the observed volume reduction in the right hippocampal formation – hippocampus and parahippocampal gyrus, together with a trend for an alteration of the left hippocampal complex in MTS patients. Same region was ipsilaterally reduced when side of the seizure focus was taken into account. These findings were consistent with previous VBM studies that compared, for the majority, TLE patients with healthy volunteers, including a meta-analysis of *Li et al.* (2011) that analysed six studies of GMV on refractory TLE and group of controls (33). We assume that this volume reduction could mainly be explained by the definition of the mesial temporal sclerosis, namely histological hippocampal atrophy with neuronal cell loss and reactive gliosis. Indeed, previous studies that worked on the correlation between MRI findings and histopathology of the epileptic hippocampus suggested that a reduction of the hippocampal volume on imaging is correlated with a decrease in number of neuron cells (6). Furthermore, the comparison of the two MTS subgroups, according to their seizure focus, showed significant ipsilateral hippocampal atrophy, reinforcing then the supposition that the primary epileptogenic hippocampus is way more affected than the contralateral.

In our study, a bilateral significant volume decrease in the thalamic nuclei and areas nearby was also observed in patients with mesial temporal sclerosis. Similar results were detected for both patients with right- and left-sided seizure focus. These findings were also compatible with previous computational brain anatomy studies (33), (34), (35), (36). Among these, a VBM meta-analysis of *Barron et al.* (2012) demonstrated that the thalamic nucleus with the most significant structural changes was the ipsilateral medio-dorsal nucleus (MDN), which is strongly connected to the hippocampus (37), (38). From these observations, we conclude that regions directly connected to the limbic system seem to be more affected than extra-limbic areas. Even though real origins of these grey and white matter alterations through the limbic system remain unclear, a few theories explaining this pattern of volume abnormalities have emerged from the literature this past decade.

According to our results and published literature, we can assume that the pattern of grey and white matter decreases is due to a global disruption in brain connectivity, whose origin owes to the epileptogenic hippocampus and affects regions with strong connections with the latter (38). Indeed, primary neuronal loss of the epileptogenic hippocampus leads to a loss of synaptic inputs affecting consequently white matter projections and neuronal pathways of the limbic network (34). Thus, *Li et al.* (2011), who also found bilateral thalamic atrophy in both subgroups of MTS patients, bring us back to the existence of a wide interconnectivity between the mesio-temporal areas and the thalamus via the fornix, mammillary bodies and mamillo-thalamic tracts. The idea suggested would be that damages in the first structures could subsequently alter the

second one (33). The other major hypothesis put forward by the literature is the implication of the pathological electrical discharges, induced during seizures, as another cause of these brain changes (34). Abnormal neuronal activity of continuous seizures increases indeed the risk of local excitotoxic effects on brain tissue (38), (35),

Even if a trend of grey and white matter alterations is often observed in areas contralateral to the seizure focus, our study revealed that regions ipsilateral to the epileptogenic point were much more affected. From that statement, we rather support the hypothesis of a limbic system disruption with a continuum of tissue alterations leading sometimes to affection of the contralateral side through inter-hemispheric connections. As an example, *Barron et al.* (2012) stressed the fact that hippocampi share direct inter-hemispheric connections through the hippocampal commissure (37). This latter could then explain our observation of a trend for contralateral hippocampal volume decrease.

In our study, MTS patients finally revealed a significant GMV increase in the medial part of the left caudate nucleus. This alteration could be explained by its strong connections with the limbic system and, indirectly, the hippocampus. Here, we speculate about the implication of the caudate as part of the striatum in goal-directed behaviour (39). According to the study from *Buot et al.* (2012), projections from the entire cortical brain are integrated in the striatum, where a topographic division defines three functional territories: the limbic and the associative territories, mainly located in the head and the medial part of the caudate nucleus respectively, and a sensorimotor surface (40). Whereas afferences from the associative area essentially come from the orbitofrontal cortex and the dorsolateral prefrontal cortex, the limbic territory receives inputs from the medial orbitofrontal cortex, the anterior cingulate and insular cortex (40). However, the delimitation between these two functional territories is not well established. This is why *Buot et al.* (2012) suggested the presence of some overlaps receiving a convergence of information from the limbic structures (40). These last MTS findings reinforce our statement that volume alterations are rather the consequence of abnormal inputs coming from a primary altered hippocampus and affecting indirectly areas strongly connected to it like the striatum.

One limitation of the voxel-based morphometry studies consists in the difficult neurobiological interpretation of grey and white matter alterations. An explanation for this lack of certainty implies the accuracy of the automated tissue classification in areas where the differentiation between grey and white matter is not clear, especially in the central grey matter structures such as brainstem or thalamus (27), (30). Changes of the brain tissue parameters appearing in some medical conditions could also alter the segmentation step. It is thus another possible explanation of this ambiguity in the subtle grey or white matter alterations. Finally, the spatial normalisation step could contribute to that phenomenon. Therefore, *Mechelli et al.* (2005) illustrated this normalisation confound with the study of *Gitelman et al.* (2001), which suggested that grey matter alterations of the caudate nucleus may result from differences of ventricle size between the groups (24). In this way, volume alterations from a group comparison could either be a veritable grey or white matter loss or simply be a structural difference of brain tissue with characteristics closed to the grey or the white matter and affecting the segmentation step in a second time. (27), (41). These are reasons why results need to be considered with prudence and we rather suspect an undetermined brain tissue alteration of the caudate nucleus in patients with MTS, without considering a real volume increase of this region.

4.1.2. Findings in cryptogenic epilepsy

In areas of the limbic system, the anatomical comparison between the MTS and the cryptogenic entities revealed similar pattern of volume alterations as the one between MTS patients and the group of controls - significant volume decrease of the ipsilateral hippocampal formation and bilateral thalamus in the MTS entity. Cryptogenic epilepsy showed no significant structural decrease compared to the healthy volunteers. Until now, only few studies worked on groups of

TLE patients without structural abnormalities noticed on standard MRI. Moreover, in contrast with our analysis, none of them found significant grey or white matter alterations between patients with and without mesial temporal sclerosis (35), (26).

This same pattern of alterations between the two comparisons and the absence of structural alteration compared to the healthy volunteers lead us to assume that the main structural origin of cryptogenic epilepsy is subtler than mesial temporal sclerosis. But at this stage, we could neither exclude nor confirm a possible hippocampal origin and a subsequent alteration of the limbic system in this TLE entity. Here, we consider that the absence of significant structural alteration in patients with cryptogenic TLE does not imply the lack of subtle temporal abnormalities at all. Indeed, the study of *Mueller et al.* (2006) justified this same hypothesis with the fact that VBM technique compares averages of presumed homogeneous groups, implying that it detects only abnormalities that are present in the majority of individuals within a group (35). This suggests then that tissue abnormalities in patients with diagnosis of cryptogenic epilepsy are more heterogeneous and less severe rendering them more difficult to identify in a group analysis (26). In contrast with the MTS entity, no significant structural changes were observed in the brain tissue when the two subgroups of cryptogenic epilepsy (left- and right-sided subgroups) were compared together. This statement makes our hypothesis of subtle abnormalities more plausible.

In our analysis, cryptogenic entity still demonstrated a significant GMV increase, mainly located in the left hippocampal formation. As explained in the introduction (see chapter 1.3.2 *mesial temporal sclerosis*), neurogenesis is a physiological phenomenon proper to the dentate gyrus. It is well known that this occurrence becomes abnormally increased in case of seizures activity at the early stage of the MTS disease, whereas it drastically decreases in the chronic stage. Hence, we suggest that this GMV increase reflects this transitory boost of neurogenesis induced by seizures at the onset of the disease. Therefore, we support the hypothesis that patients with MTS and patients with diagnosis of cryptogenic epilepsy are grouped in a unique TLE entity, the mesial temporal sclerosis entity, at different periods of the disease, the “cryptogenic phase” preceding the final step of the mesial temporal sclerosis. Our presumption is reinforced with the clinical features analysis, which showed that for two age-matched populations (two-sample t test, $P = 0.1364$), the group of patients with diagnosis of cryptogenic epilepsy had a significant reduced disease duration compared to patients with diagnosis of MTS (two-sample t test, $P = 0.000$). The age of epilepsy onset was also significantly higher for the cryptogenic epilepsy than MTS (two-sample t test, $P = 0.006$). Finally, all these results corroborate our hypothesis that temporal lobe epilepsy with hippocampal sclerosis is a progressive disease starting from a subtle clinical pattern with no evidence of MRI alterations at the time of diagnosis, evolving to a progressive alteration of the hippocampus and ending with a stage of mesial temporal sclerosis.

4.1.3. Findings in focal cortical dysplasia

In our study, patients with MTS showed significant volume decrease in the right hippocampal formation and areas nearby (i.e. right anterior thalamic radiations) compared to patients with focal cortical dysplasia. But when patients with clinically right-sided seizure focus were compared to the healthy volunteers, significant brain tissue alterations were found in regions of the ipsilateral temporal lobe (i.e. insula and the superior temporal gyrus). Lastly, no significant structural changes were observed when the two subgroups of patients with FCD (left- and right-sided subgroups) were compared together. According to these findings, we interpret abnormalities in the FCD entity as subtler and more heterogeneous as the MTS entity. Thus, various degrees of cortical alterations are found in this TLE entity (21) and, unlike the MTS entity, its origin is not preferentially localised through the hippocampal formation or the limbic system but seems to be more widespread.

In the comparison with the MTS patients and in contrast with the other MTS comparisons, GMV in the thalamus was not altered in patients with MTS. Yet, volume in this region was rather reduced in the FCD patients compared to healthy volunteers with a sparing of the hippocampus, contrary to the MTS patients. With these statements, we support the hypothesis that the thalamus is secondarily altered and, as the hippocampus is spared in our findings, is rather induced by the excitotoxic effects of seizures activity.

Earlier, we interpreted the “cryptogenic entity” as a mesial temporal sclerosis entity at an earlier stage of the disease, and the comparison between these both patients groups showed no significant thalamic atrophy. We therefore assume that thalamic nuclei were sensitive to the seizures activity after a relative long period of latency and that this pattern of abnormalities is not restricted to the MTS but involve a broader spectrum of mesial temporal lobe entities. As with the MTS features analysis, even though both groups had age-matched populations (two-sample t test, $P=0.4141$), cryptogenic had a significant smaller disease duration (two-sample t test, $P= 0.0141$) and a higher age of epilepsy onset (two-sample t test, $P= 0.0061$) in comparison with FCD patients. The absence of thalamic atrophy in the cryptogenic entity is then explained by the fact that MTS patients at an early stage of the disease mainly represent this group. This statement reinforces our presumptions that thalamic area is secondary altered, that this phenomenon occurs in all TLE entities and is mainly due to an excitotoxic effect of the seizures. Thus, while we supported the limbic network disruption as the major mechanism responsible for brain alterations, with this claim, we now conclude that both mechanisms co-exist and play an important role in the pathophysiology of all the TLE entities.

For all the TLE entities, however, grey and white matter volume alterations were not restricted to the hippocampal formation and the limbic system. A few studies agreed that smaller abnormalities were also detected in more diffuse brain regions (42). We will discuss about these alterations found in our study in the following chapters.

4.2. Findings within the prefrontal cortex

Our analysis demonstrated that MTS patients had no significant volume reduction in the frontal lobe, although some studies maintain the opposite. Indeed, whenever it concerns the grey or the white matter, the frontal lobe is often reported to be the third most relevant region altered in the MTS disease (34), especially the medial frontal gyrus (33) and the prefrontal cortex (36), (42). These studies mainly support the theory that prefrontal areas are anatomically and functionally connected to the limbic system and to the thalamus. However, while some studies affirmed that grey and white matter in this area are secondly altered further to the pathological excitotoxic discharges of seizures coming from the primary affected hippocampus (42), others rather imputed the disruption of the fronto-limbic network through the white matter tracts deterioration. In our case, even though we found a trend of volume abnormalities in the frontal lobe in the MTS patients at a lower threshold, these findings were not statistically significant.

Over this past decade, VBM studies with regard to the temporal lobe epilepsy have had a wide range of different results, sometimes leading the studies to contradict themselves. This large spectrum of results is mainly explained by a limitation proper to the VBM technique: the spatial preprocessing steps (43). There are indeed dozen ways to perform a VBM study including different preprocessing protocols and statistical methods of analysis, avoiding us to expect strict similar pattern of GM and WM alterations between studies (33). The VBM method could also miss some volume reductions if they are subtle, leading to false negative results. In the same way, some small imaging artefacts in the brain could present brain tissue abnormalities that are falsely positive (35). Lastly, some other methodological factors also interfere with the results like the modality of the neuroimaging investigations or the clinical characteristics defining the data group (44). All these reasons could in that way affect the GMV and WMV alterations in a study and should lead us to put the comparison between the studies into perspective.

Even though MTS patients showed no volume alterations in our study, patients with cryptogenic epilepsy still demonstrated a small significant GMV reduction in the left dorsolateral prefrontal cortex together with a trend for an alteration of the left superior motor area. Contrary to the grey matter, cryptogenic patients with left-sided seizure focus showed a significant WMV increase in the ipsilateral dorsolateral prefrontal cortex. These findings are partially in agreement with previous VBM studies, in particular with the one of *Bernasconi et al.* (2004) that found significant GMV reduction in different small frontal lobe areas including the bilateral dorsal frontal and the ipsilateral orbitofrontal cortices (34). From these results, they claimed that this GM reduction could be induced by the loss of white matter tracts that connect the epileptogenic hippocampus to these specific frontal areas. Because they performed their analyses on patients with evidence of MTS on conventional MRI, we cannot pretend that our results were similar and the strict comparison remains too weak. To explain this frontal alteration, we assumed that a few frontal areas -anterior cingulate cortex, the orbitofrontal cortex and the medial prefrontal cortex- have strong and reciprocal connections with the mesial temporal lobe through the fronto-limbic network and that the dorsolateral prefrontal cortex receives inputs from the cingulate cortex, (39), (45), we therefore suspect that this frontal area is indirectly connected to that circuit. But even though these findings lead us to think of a potential consequence of the limbic network disruption, arguments remain too weak to definitively exclude the excitotoxic effects of seizures activity and further studies need to be performed.

However, regardless the pathophysiological mechanism and as we demonstrated earlier that MTS is a progressive condition in which “the cryptogenic entity” represents its acute phase, we conclude that diffuse brain alterations directly or indirectly connected to the limbic network could also be present at an early stage of the disease.

4.3. Findings in the parietal and occipital lobes

In these parts of the brain, only analysis of white matter tracts showed small significant volume alterations. This way, all TLE entities exhibited small and diffuse clusters of white matter abnormalities when they are compared together. Among these, MTS patients showed volume reduction mainly localised in the bilateral parietal lobe compared to the cryptogenic entity, these findings being more altered ipsilateral to the seizure focus. MTS epilepsy also showed a trend for a WMV reduction in the same areas compared to the healthy volunteers. FCD patients also showed diffuse small regions of WMV alterations when compared to the three other groups. In contrast with our findings, only few studies revealed volume alterations in regions of the parietal and occipital lobes. (36), (46).

In each comparison, altered white matter was present in very small clusters and diffusely distributed throughout the lobes. From that statement, we suggest that white matter reduction in the parieto-occipital region is the consequence of a widespread electrical seizures excitotoxicity, which may affect brain tissue randomly. Another hypothesis for these diffuse WM alterations proposed by *McMillan et al.* (2004), would be the impact of the long-term use of antiepileptic drugs, especially at the time of the brain development. (46).

On the other hand, the alteration of some associative white matter fibers, like the inferior or the superior longitudinal fasciculi, which principally connect the temporal lobe to the occipital or the frontal lobes respectively, rather strengthens the theory that brain volume decrease is induced by a disruption of the limbic system connections; moreover, it also corroborates the fact that distant regions such as the parietal or the occipital lobes could be indirectly damaged. Even though areas of volume reduction were very slight, abnormalities found inside concerned just the white matter and were only located ipsilaterally, reinforcing the hypothesis that alterations were induced by a loss of inputs from the damaged hippocampus.

In this part of the brain, despite several hypotheses that may explain these alterations, the real pathophysiology underlying them remains actually unknown and, here again, further investigations need to be conducted.

4.4. Findings in the cerebellum

MTS patients, especially patients with left-sided seizure focus, showed a bilateral GMV reduction in the cerebellum. Same results were revealed when left-sided MTS patients were compared to the cryptogenic patients. In contrast with the mesial temporal sclerosis, no evidence of volume alterations were discovered in patients with FCD or with cryptogenic epilepsy.

These findings are in agreement with some other neuroimaging studies, which also reported significant atrophy of the cerebellum in chronic temporal lobe epilepsy (35), (42). A quantitative neuropathological study, *Crooks et al.* (2000), discovered an important loss of Purkinje cells with a relative preservation of the basket cells in the atrophic cerebellum. Bergmann gliosis and focal granule cell depletion were the two other phenomena that accompanied the cell loss (47). According to that study, the loss of Purkinje cells appears before the cerebellar atrophy visible on neuro-imaging (47). In our study, patients with MTS showed cerebellar atrophy whereas patients with cryptogenic epilepsy, which corresponds to the early stage of the MTS entity according to our hypothesis, showed no GMV reduction. We thus, assume that this phenomenon is a long-term and progressive mechanism.

To date, even though this cerebellar alteration is well known in the mesial temporal sclerosis, its exact origins and mechanisms remain still poorly understood. Some controversial hypotheses have been put forward this past decade. Among them, *Keller et al* (2002) explained this significant cerebellar atrophy with the presence of direct neural connections between the hippocampus and the cerebellum, implying then that GMV in cerebellar areas are secondary altered to the interconnections with the pathological hippocampus (42). *Mueller et al* (2006) rather suggested the long-term use of antiepileptic drugs as the origin of the cerebellar alterations (35). Indeed, phenytoin has long been incriminated for this atrophy in patients with MTS, but this has become more and more controversial this last decade. *Herman et al* (2005) did not find a significant relationship between the use of phenytoin and cerebellar atrophy but rather demonstrated a significant association between the latter and the disease duration (48).

Last but not least, we would say that no matter if this atrophy is due to a high number of seizures exposition or to the long-term use of anti-epileptic drugs, we conclude that this cerebellar atrophy seems to be a marker of disease chronicity in the mesial temporal sclerosis entity.

5. Conclusion

5.1. Summary and perspectives

At the end of this work, we first conclude that mesial temporal sclerosis is a progressive disease. Epilepsy without significant brain alterations at the time of MRI diagnosis is rather a mesial temporal sclerosis entity at an early stage of the disease than another distinctive epilepsy entity. In order to reinforce this hypothesis, it would be interesting to confront other clinical features, such as the history of febrile seizure and the drug resistance, or to compare some cognitive performances between patients with and without hippocampal sclerosis. We would then expect a similar rate of history of febrile seizures between both groups and patients with MTS should have a higher rate of drug resistance than patients without. But the best way to investigate this MTS evolution remains the creation of a longitudinal study with a follow-up of all the patients over several years.

Within this study, we also claim that cerebellar atrophy in the MTS entity is a marker of the disease chronicity, even though its real origin remains still unknown. In order to confirm this theory, the following step might be to correlate these VBM findings with the clinical aspects subsequent to a cerebellar alteration. To strengthen the hypothesis of a drug influence, especially the use of phenytoin, it would also be interesting to compare the drug resistance between both groups. Thus, we expect to find a higher rate of drug resistance and clinical signs of cerebellar alterations in patients with mesial temporal sclerosis than patients without significant MRI abnormalities.

Finally, our study also partly agrees that brain tissue alterations in mesial temporal sclerosis are a consequence of the limbic network disruption, which primary originates from the epileptic hippocampus. But grey and white matter volume modifications are by far not only explained by the limbic system disorder, e.g. excitotoxic effects of seizures could also secondarily alter brain tissue, as we have just demonstrated in the thalamic nuclei in our study. We conclude that both mechanisms play an important role in the pathophysiological mechanism of the mesial temporal epilepsy and further studies need to be conducted to detect which altered regions are rather due to one than the other cause. Besides, some histological studies could lead to a better comprehension of the pathophysiological mechanism and the pattern of grey and white matter reduction discovered in these groups. Thus, it would be interesting to confront our results with some histological analyses.

Finally, from a broader perspective, if other studies also confirm this progressive natural history of the MTS entity, it would remain very interesting to know the exact pattern of grey and white matter volume alterations in brain tissue. We may subsequently be able to find some radiological markers allowing an earlier detection of the subtle brain tissue alterations mostly present at the beginning of the MTS disease. This would globally lead us to a better management of the epilepsy entity.

5.2. Limitations and outlook

Beside the limitations proper to the VBM technique (previously treated in chapters 4.1.1 and 4.2), I have mostly struggled with some personal issues, among which the acquisition of a basic use of the SPM software and a thorough understanding of the statistics. In this way, the interpretation of the VBM results was a difficult task and I have often been limited by the time. But finally, I would say that this study allowed me, above all, to have an insight into areas of research and to acquire a better understanding of such a complex but fascinating disorder.

6. Bibliography ⁱ

1. Carl E stafstrom, MD,PHD, Jong M Rho, MD. Pathophysiology of seizures and epilepsy. UpToDate. Waltham, MA: Denis S Basow; 2013.
2. Steven C Schachter, MD. Evaluation of the first seizure in adults. UpToDate. Waltham, MA: Denis S Basow; 2013.
3. Berg AT, Berkovic SF, Brodie MJ, Buchhalter J, Cross JH, van Emde Boas W, et al. Revised terminology and concepts for organization of seizures and epilepsies: report of the ILAE Commission on Classification and Terminology, 2005-2009. *Epilepsia*. avr 2010;51(4):676-85.
4. Steven C Schachter, MD. Overview of the management of epilepsy in adults. UpToDate. Waltham, MA: Denis S Basow; 2013.
5. Lawrence J Hirsch, MD, Hiba Arif, MD. Neuroimaging in the evaluation of seizures and epilepsy. UpToDate. Waltham, MA: Denis S Basow; 2013.
6. Malmgren K, Thom M. Hippocampal sclerosis--origins and imaging. *Epilepsia*. sept 2012;53 Suppl 4:19-33.
7. Werner K, Frotscher M. Système nerveux et organes des sens. 4e édition. Médecine Sciences Publications; 2013. 423 p.
8. Purves D, Augustine GJ, Fitzpatrick D, Hall WC, LaMantia A-S, McNamara JO. Neurosciences. 3e édition. De Boeck; 2005. 811 p.
9. Rajmohan V, Mohandas E. The limbic system. *Indian J Psychiatry*. 2007;49(2):132-9.
10. Neves RS da C, de Souza Silva Tudesco I, Jardim AP, Caboclo LOSF, Lancellotti C, Ferrari-Marinho T, et al. Granule cell dispersion is associated with memory impairment in right mesial temporal lobe epilepsy. *Seizure J Br Epilepsy Assoc*. nov 2012;21(9):685-90.
11. Blümcke I, Coras R, Miyata H, Ozkara C. Defining clinico-neuropathological subtypes of mesial temporal lobe epilepsy with hippocampal sclerosis. *Brain Pathol Zurich Switz*. mai 2012;22(3):402-11.
12. Selim R Benbadis, MD. Localization-related (partial) epilepsy: Causes and clinical features. UpToDate. Waltham, MA: Denis S Basow; 2013.
13. Gambardella A, Labate A, Giallonardo A, Aguglia U. Familial mesial temporal lobe epilepsies: clinical and genetic features. *Epilepsia*. mai 2009;50 Suppl 5:55-7.
14. Chang Y-C, Huang C-C, Huang S-C. Long-term neuroplasticity effects of febrile seizures in the developing brain. *Chang Gung Med J*. avr 2008;31(2):125-35.
15. Bell B, Lin JJ, Seidenberg M, Hermann B. The neurobiology of cognitive disorders in temporal lobe epilepsy. *Nat Rev Neurol*. mars 2011;7(3):154-64.
16. Siebzehnrubl FA, Blumcke I. Neurogenesis in the human hippocampus and its relevance to temporal lobe epilepsies. *Epilepsia*. juin 2008;49 Suppl 5:55-65.
17. Parent JM, Kron MM. Neurogenesis and Epilepsy. In: Noebels JL, Avoli M, Rogawski MA, Olsen RW, Delgado-Escueta AV, éditeurs. *Jasper's Basic Mechanisms of the Epilepsies* [Internet]. 4th éd. Bethesda (MD): National Center for Biotechnology Information (US); 2012 [cité 4 mars 2014]. Disponible sur: <http://www.ncbi.nlm.nih.gov/books/NBK98198/>
18. Kuruba R, Hattiangady B, Shetty AK. Hippocampal Neurogenesis and Neural Stem Cells in Temporal Lobe Epilepsy. *Epilepsy Behav EB*. janv 2009;14(Suppl 1):65-73.
19. Parent JM, Murphy GG. Mechanisms and functional significance of aberrant seizure-induced hippocampal neurogenesis. *Epilepsia*. juin 2008;49 Suppl 5:19-25.
20. Gaitanis JN, Donahue J. Focal cortical dysplasia. *Pediatr Neurol*. août 2013;49(2):79-87.
21. Marin-Valencia I, Guerrini R, Gleeson JG. Pathogenetic mechanisms of focal cortical dysplasia. *Epilepsia*. juill 2014;55(7):970-8.
22. Bernasconi A, Bernasconi N, Bernhardt BC, Schrader D. Advances in MRI for « cryptogenic » epilepsies. *Nat Rev Neurol*. févr 2011;7(2):99-108.
23. Engel J. ILAE classification of epilepsy syndromes. *Epilepsy Res*. août 2006;70 Suppl 1:S5-10.
24. Mechelli A, Cathy J, Price, Karl J, Friston, John Ashburner. *Voxel-Based Morphometry of the Human Brain: Methods and Applications*. *Curr Med Imaging Rev*. 2005;1:00-00.
25. Ashburner J. Computational anatomy with the SPM software. *Magn Reson Imaging*. oct 2009;27(8):1163-74.
26. Scanlon C, Mueller SG, Cheong I, Hartig M, Weiner MW, Laxer KD. Grey and white matter abnormalities in temporal lobe epilepsy with and without mesial temporal sclerosis. *J Neurol*. sept 2013;260(9):2320-9.
27. Good CD, Johnsrude IS, Ashburner J, Henson RNA, Friston KJ, Frackowiak RSJ. A Voxel-Based Morphometric Study of Ageing in 465 Normal Adult Human Brains. *NeuroImage*. juill 2001;14(1):21-36.
28. Whitwell JL. Voxel-based morphometry: an automated technique for assessing structural changes in

- the brain. *J Neurosci Off J Soc Neurosci.* 5 août 2009;29(31):9661-4.
29. Ashburner J. SPM Tutorial [Internet]. 2010. Disponible sur: www.fil.ion.ucl.ac.uk/~john/misc/VBMclass10.pdf
30. John Ashburner, Karl J. Friston. *Voxel-Based Morphometry - The Methods.* *NeuroImage.* 2000;11:805-21.
31. N. Tzourio-Mazoyer, B. Landeau, D. Papathanassiou, F. Crivello, O. Étard, N. Delcroix, et al. Automated Anatomical Labeling of Activations in SPM Using a Macroscopic Anatomical Parcellation of the MNI MRI Single-Subject Brain. *NeuroImage.* 15:273-89.
32. Diedrichsen J. A spatially unbiased atlas template of the human cerebellum. *Neuroimage.* 2006;33(1):127-38.
33. Li J, Zhang Z, Shang H. A meta-analysis of voxel-based morphometry studies on unilateral refractory temporal lobe epilepsy. *Epilepsy Res.* févr 2012;98(2-3):97-103.
34. Bernasconi N, Duchesne S, Janke A, Lerch J, Collins DL, Bernasconi A. Whole-brain voxel-based statistical analysis of gray matter and white matter in temporal lobe epilepsy. *NeuroImage.* oct 2004;23(2):717-23.
35. Mueller SG, Laxer KD, Cashdollar N, Buckley S, Paul C, Weiner MW. Voxel-based optimized morphometry (VBM) of gray and white matter in temporal lobe epilepsy (TLE) with and without mesial temporal sclerosis. *Epilepsia.* mai 2006;47(5):900-7.
36. McMillan AB, Hermann BP, Johnson SC, Hansen RR, Seidenberg M, Meyerand ME. Voxel-based morphometry of unilateral temporal lobe epilepsy reveals abnormalities in cerebral white matter. *NeuroImage.* sept 2004;23(1):167-74.
37. Barron DS, Fox PM, Laird AR, Robinson JL, Fox PT. Thalamic medial dorsal nucleus atrophy in medial temporal lobe epilepsy: A VBM meta-analysis. *NeuroImage Clin.* 2012;2:25-32.
38. Bonilha L, Rorden C, Castellano G, Cendes F, Li LM. Voxel-based morphometry of the thalamus in patients with refractory medial temporal lobe epilepsy. *NeuroImage.* 15 avr 2005;25(3):1016-21.
39. Morgane PJ, Galler JR, Mokler DJ. A review of systems and networks of the limbic forebrain/limbic midbrain. *Prog Neurobiol.* févr 2005;75(2):143-60.
40. Buot A, Yelnik J. Functional anatomy of the basal ganglia: Limbic aspects. *Rev Neurol (Paris).* août 2012;168(8-9):569-75.
41. Ashburner J, Friston KJ. Why Voxel-Based Morphometry Should Be Used. *NeuroImage.* déc 2001;14(6):1238-43.
42. Keller SS, Mackay CE, Barrick TR, Wieshmann UC, Howard MA, Roberts N. Voxel-based morphometric comparison of hippocampal and extrahippocampal abnormalities in patients with left and right hippocampal atrophy. *NeuroImage.* mai 2002;16(1):23-31.
43. Keller SS, Roberts N. Voxel-based morphometry of temporal lobe epilepsy: an introduction and review of the literature. *Epilepsia.* mai 2008;49(5):741-57.
44. Keller SS, Schoene-Bake J-C, Gerdes JS, Weber B, Deppe M. Concomitant fractional anisotropy and volumetric abnormalities in temporal lobe epilepsy: cross-sectional evidence for progressive neurologic injury. *PloS One.* 2012;7(10):e46791.
45. Petrides M, Pandya DN. Dorsolateral prefrontal cortex: comparative cytoarchitectonic analysis in the human and the macaque brain and corticocortical connection patterns. *Eur J Neurosci.* mars 1999;11(3):1011-36.
46. Yu A, Li K, Li L, Shan B, Wang Y, Xue S. Whole-brain voxel-based morphometry of white matter in medial temporal lobe epilepsy. *Eur J Radiol.* janv 2008;65(1):86-90.
47. Crooks R, Mitchell T, Thom M. Patterns of cerebellar atrophy in patients with chronic epilepsy: a quantitative neuropathological study. *Epilepsy Res.* août 2000;41(1):63-73.
48. Hermann BP, Bayless K, Hansen R, Parrish J, Seidenberg M. Cerebellar atrophy in temporal lobe epilepsy. *Epilepsy Behav.* sept 2005;7(2):279-87.
-