



ELSEVIER

European Journal of Cardio-thoracic Surgery 22 (2002) 249–254

EUROPEAN JOURNAL OF  
CARDIO-THORACIC  
SURGERY[www.elsevier.com/locate/ejcts](http://www.elsevier.com/locate/ejcts)

## Hemodynamics optimization during off-pump coronary artery bypass: the ‘no compression’ technique

Xavier M. Mueller<sup>a,\*</sup>, Pierre-Guy Chassot<sup>b</sup>, Junging Zhou<sup>a</sup>, Karam M. Eisa<sup>a</sup>, Carine Chappuis<sup>b</sup>, Hendrik T. Tevaearai<sup>a</sup>, Ludwig K. von Segesser<sup>a</sup>

<sup>a</sup>Department of Cardio-vascular Surgery, Centre Hospitalier Universitaire Vaudois (CHUV), CH-1011 Lausanne, Switzerland

<sup>b</sup>Department of Anesthesiology, Centre Hospitalier Universitaire Vaudois (CHUV), CH-1011 Lausanne, Switzerland

Received 6 February 2002; received in revised form 12 April 2002; accepted 1 May 2002

### Abstract

**Objective:** Heart manipulation during OPCAB may cause hemodynamical instability in particular for access to the posterior and lateral walls. The ‘no compression’ technique involves enucleation of the heart without any compression on the cavities, and stabilization of the target area with a suction device. The impact of this technique on hemodynamics is assessed. **Methods:** In order to analyze a homogeneous group, 26 consecutive patients with triple grafts, one to each side of the heart in the same sequential order (posterior, lateral and anterior wall successively) were selected. Heart rate (HR), mean pulmonary arterial pressure (PAP, mmHg), pulmonary capillary wedge pressure (PCWP, mmHg), mean arterial pressure (MAP, mmHg), cardiac output index (COI, l/min per m<sup>2</sup>), and central venous saturation (SvO<sub>2</sub>,%) were monitored. A coronary shunt was used for all the anastomoses. **Results:** HR was stable with baseline value of 60 ± 10 and the highest value for the anterior wall, 63.6 ± 8 (*P* = 0.23). PAP and PCWP exhibited their highest increase, when compared with baseline, for the lateral wall, 23.9 ± 4.7 vs. 20.7 ± 6.2 (*P* = 0.06), and 17.2 ± 4.7 vs. 14.9 ± 5.6 (*P* = 0.16), respectively. MAP, COI and SvO<sub>2</sub>, exhibited their largest drop, when compared with baseline, for the lateral wall too, 73.1 ± 9.1 vs. 77.1 ± 7.5 (*P* = 0.12), 1.99 ± 0.47 vs. 2.26 ± 0.55 (*P* = 0.09), and 70.5 ± 8.4 vs. 74.8 ± 9.3 (*P* = 0.12), respectively. **Conclusions:** None of the hemodynamical parameter differed significantly from baseline value for all three territories. While hemodynamics was perfectly maintained during the posterior and anterior walls revascularization, exposure of the lateral wall led to marginal changes only. © 2002 Elsevier Science B.V. All rights reserved.

**Keywords:** Off-pump; Coronary artery bypass; Hemodynamics

### 1. Introduction

Cardioplegic arrest and cardiopulmonary bypass (CPB) have promoted the development of coronary artery bypass grafting (CABG), because of the quiet and bloodless conditions offered for the performance of the anastomoses. However, these techniques are currently challenged because myocardial preservation techniques are imperfect and CPB induces activation of inflammatory and clotting cascades with subsequent damaging effects [1,2]. Therefore, the concept of beating heart surgery, already pioneered in the early days of cardiac surgery by Kolesov [3], benefited renewed interest with the introduction of minimally invasive direct coronary artery bypass grafting (MIDCAB) [4,5]. With this method, the revascularization was restricted to the left anterior descending artery (LAD) because of the limited access through a left anterior mini-thoracotomy. This limita-

tion has prompted the emergence of off-pump coronary artery bypass grafting (OPCAB) which allows complete revascularization through a median sternotomy. One important concern with this technique is the hemodynamical compromise caused by displacement of the beating heart to gain access to the circumflex artery and posterior descending artery branches. However, the recent improvements of coronary artery exposure [6] and of anastomotic site stabilization method [7,8] have resulted in the widespread use of this technique for all the coronary territories [9–12].

In order to avoid hemodynamical compromise during coronary exposure and stabilization, we adopted a technique avoiding any compression on the heart chambers. The aim of this work is to study the hemodynamical profile observed with such a technique in a group of patients undergoing a triple bypass on the posterior, lateral and anterior wall, respectively.

\* Corresponding author. Tel.: +41-21-314-2313; fax: +41-21-314-2278.

E-mail address: [xavier.mueller@chuv.hospvd.ch](mailto:xavier.mueller@chuv.hospvd.ch) (X.M. Mueller).

## 2. Patients and methods

### 2.1. Patient selection

In order to ensure a homogeneous group, consecutive patients with triple vessel disease requiring a bypass on each wall of the heart, i.e. posterior, lateral and anterior, were considered for this study. For the same reason, patients with a recent myocardial infarction (<2 weeks), a left ventricular ejection fraction < 30%, or with a previous cardiac operation were excluded. All the operations were performed by a single surgeon.

### 2.2. Surgical technique

The heart is exposed through a sternotomy. The left internal thoracic artery (LITA) is harvested first and wrapped in a swab soaked with papaverine. The pericardium is incised longitudinally. At the level of the diaphragm, the pericardium is cut back at right angle: on the left side the incision is carried out till the apex of the heart in order to ensure a free movement of the latter during heart lifting, whereas on the right side the incision is restricted to the pleural reflection avoiding any extension in the right pericardium/pleura.

Then, the heart is elevated with one hand and a heavy monofilament suture (no. 1 Prolene, Ethicon, Somerville, NJ) is placed on the right side of the spine halfway between the level of the right inferior pulmonary vein and that of the inferior vena cava. The suture is passed through a half-folded swab (60 cm long and 10 cm wide) and snared down, bringing the folded end of the swab in close contact with the posterior pericardium. The basic principle of exposure is to pull on both limbs of the swab in a direction opposite to the target wall with the target artery located between both limbs. Once the appropriate exposure is obtained, each limb is fixed to the surgical drapes. Care is

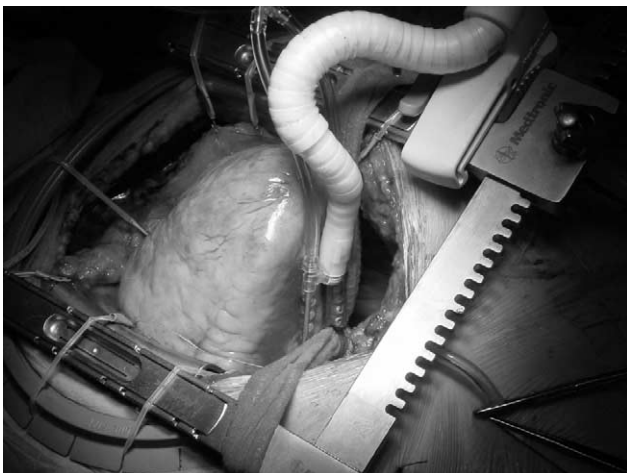

Fig. 1. Exposure of the posterior wall. The traction on the arms of the swab has enucleated the heart which stands like a pyramid. Note that the artery lies between the two arms of the swab and that no compression is applied on the heart chambers.

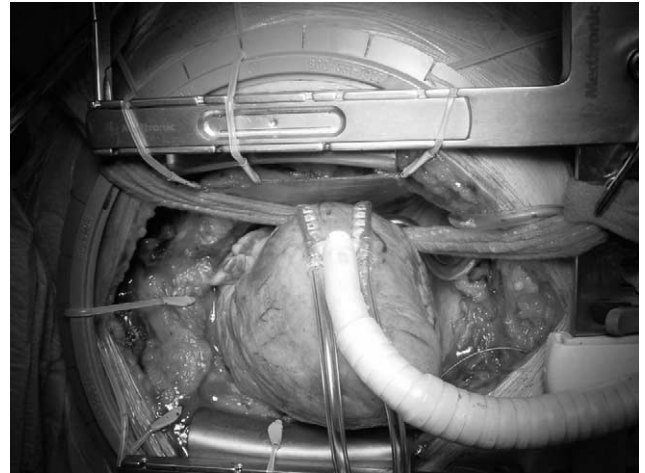


Fig. 2. Exposure of the lateral wall. The same remarks as for Fig. 1 are valid here.

taken to avoid any wrapping of the limbs around the heart or any traction of the limbs across the heart, both of which may generate compression. The illustration of this principle for each wall is shown in Figs. 1–3. When the heart is lifted to expose the lateral and posterior walls, it lies on its base like a pyramid and moves freely without any compression or distortion constraint.

In addition to this elevation technique, the position of the patient is important for a proper access to the target artery. First, before the elevation of the heart for the placement of the pericardial stitch, the legs are elevated while the upper part of the body is left horizontal. Then for the posterior wall, the table is set in the Trendelenburg position, for the lateral wall the table is rotated sideways to the right of the patient (30°), and for the anterior wall the upper body is brought back to the horizontal position.

The target anastomotic site is stabilized with a suction

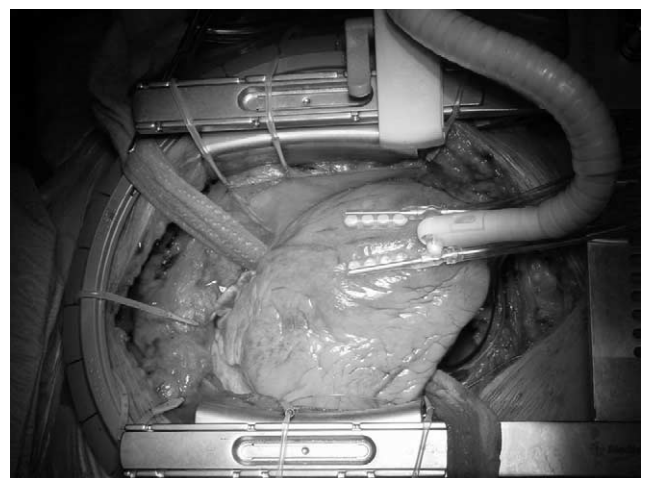


Fig. 3. Exposure of the anterior wall. The arms of the swab are pulled to lift up the heart. This allows proper exposure of the LAD which often lies laterally under the thoracic wall.

type stabilizer, the Octopus system (Medtronic Inc., Minneapolis, MN). During all the anastomoses, the coronary flow is maintained with an intracoronary shunt. LITA is used to bypass the left anterior descending artery (LAD) in all patients, while internal saphenous vein segments are used to bypass the other arteries. Proximal anastomoses to the ascending aorta are performed during a single aortic partial side-bite clamping period. Graft flow is assessed with a transit time flowmeter (Medi-Stim, Oslo, Norway). The main parameter used to evaluate an adequate flow is the pulsatility index. A value exceeding 5 is considered as an indication to refashion the anastomosis.

The distal anastomoses are always performed in the same sequence, starting with the posterior wall, then the lateral wall and lastly the anterior wall. Moreover, the successive anastomoses are performed without interruption: between the anastomoses, the arms of the swab are moved in order to expose directly the next target artery, without bringing back the heart to its resting position. For the right coronary artery territory, we basically favored an anastomosis on the right coronary branches on the posterior wall. This policy was dictated by the risk of arrhythmias such as an atrioventricular block during the occlusion of non-critical right coronary stenosis due to blood flow interruption of the AV node artery taking off at the crux. The indication to bypass the right coronary artery was limited to critical proximal stenosis or occlusion.

### 2.3. Anesthesia

Patients receive their usual medication including long-acting  $\beta$ -blockers up to the morning of the intervention. Perioperative monitoring consists of a five-lead ECG, capillary pulse oximetry, end-tidal  $\text{CO}_2$  determination, invasive arterial blood pressure measurement, and right heart pressure measurement with a pulmonary artery catheter (Baxter Healthcare, Irvine, CA). Cardiac output measurements are performed using intermittent 10-ml boluses of dextrose 5% solution at a temperature of 18–20 °C. A transesophageal echocardiography probe is inserted in order to record the segmental motion and the heart function during the operation.

The anesthetic technique consists of premedication with benzodiazepine, and induction with etomidate (0.3 ml/kg) and fentanyl (18–20  $\mu\text{g}/\text{kg}$ ). Neuromuscular blockade is achieved with vecuronium (0.1 mg/kg). The lungs are ventilated to slight hypocapnia ( $\text{PaCO}_2$  30–35 mmHg) with air and  $\text{O}_2$  (50%) and without positive end expiratory pressure. Anesthesia is maintained with isoflurane (1–1.5% inspired concentration). At skin incision, a continuous infusion of diltiazem (0.1 mg/kg per hour), without loading dose, is started and continued throughout the operation. After mobilization of the LITA and before mobilization of the heart, 1 mg/kg of heparin is administered with a target activated clotting time (ACT) between 250 and 300 s. Patient intravenous solutions are adjusted with colloid and

lactated Ringer to maintain a pulmonary capillary wedge pressure between 15 and 20 mmHg. During the coronary procedure, a noradrenaline drip is initiated when necessary to maintain  $\text{MAP} > 70$  mmHg. Importantly, no  $\beta$ -adrenergic inotrope is used in order to avoid any increase of myocardial  $\text{O}_2$  consumption. Before heart mobilization, an auricular pacemaker lead is inserted, and the pacemaker is switched on at a rate of 60/min, should the  $\text{SvO}_2$  drop to less than 65%. Blood loss is processed with a cell spinning device in all the cases. At the end of the procedure, 50 mg of protamine is administered if the  $\text{ACT} > 300$  s.

### 2.4. Hemodynamical monitoring and clinical data

The following hemodynamical parameters were analyzed: heart rate (HR), mean pulmonary arterial pressure (PAP), pulmonary capillary wedge pressure (PCWP), mean systemic arterial pressure (MAP), cardiac output index (COI) and central venous saturation ( $\text{SvO}_2$ ). The measurements were first recorded after the LITA harvest and before any surgical manipulation to expose and stabilize the target vessels, and then 10 min after the beginning of each grafting.

The following postoperative events were recorded: myocardial infarction defined as new Q wave and/or CK-MB  $> 100\text{IU/l}$ , need for postoperative inotrope agents, supraventricular arrhythmias, pneumonia, neurological complications, renal failure (creatinine  $> 120 \mu\text{mol/l}$ ), and need for transfusion.

### 2.5. Statistics

Values recorded during the completion of each anastomosis were compared with those recorded at baseline using a *t*-test. Values were considered to differ significantly if  $P < 0.05$ .

Table 1  
Patients' characteristics<sup>a</sup>

Variable	No. of patients	Percentage
Age (years, $\pm$ SD)	64.9 $\pm$ 10.8	
Male	16	62
Unstable angina	10	38
Emergency surgery	7	27
Previous PTCA	6	23
Previous myocardial infarction	10	38
Diabetes	4	15
Hyperlipidemia	16	62
Hypertension	15	58
Family history of CAD	7	27
LVEF		
30–40%	4	15
41–50%	10	38
51–60%	9	35
$>60\%$	3	12

<sup>a</sup> CAD, coronary artery disease; LVEF, left ventricular ejection fraction; PTCA, percutaneous transluminal coronary angioplasty.

Table 2  
Pressures profile (mmHg)<sup>a</sup>

	PAP			PCWP			MAP		
	Value	Δ	P	Value	Δ	P	Value	Δ	P
Baseline	20.7 ± 6.2			14.9 ± 5.6			77.1 ± 7.5		
Posterior wall	22.1 ± 6.1	1.4 ± 3.3	0.45	15.9 ± 5.1	0.9 ± 5.2	0.59	75.0 ± 8.7	-2.0 ± 7.5	0.41
Lateral wall	23.9 ± 4.7	3.2 ± 6.9	0.06	17.2 ± 4.7	2.2 ± 5	0.16	73.1 ± 9.1	-3.9 ± 9	0.12
Anterior wall	22.3 ± 5.7	1.6 ± 5.6	0.38	15.9 ± 5.4	0.9 ± 3.9	0.58	74.9 ± 7.3	-2.2 ± 7.9	0.34

<sup>a</sup> PAP, mean pulmonary artery pressure; PCWP, pulmonary capillary wedge pressure; MAP, mean systemic artery pressure; Δ, difference between the value recorded 10 min following exposure and stabilization of the target artery and that recorded at baseline.

### 3. Results

#### 3.1. Patient characteristics

Characteristics of the patients are summarized in Table 1.

#### 3.2. Hemodynamical data

LITA was anastomosed to the mid-third of the LAD in all the patients. All of the patients were candidates for the revascularization of the right coronary branches. Anastomosis to the lateral wall was performed within 2 cm of the atrioventricular groove in seven patients. The diameter of the shunts varied between 1.25 and 2.75 mm.

No patient received any intraoperative inotropic agent or intra-aortic balloon pump. Twenty patients required a norepinephrine drip to maintain MAP > 70 mmHg, and four patients required atrial pacing. All patients received colloid as well as crystalloid solutions. The amounts were 850 ± 230 ml and 2800 ± 800 ml, respectively.

All of the hemodynamical recordings were able to be completed for the three grafts for all patients. One patient required a refashioning of a LITA-LAD anastomosis following unsatisfactory transit flowmeter measures, with a satisfactory result. Notably, once the heart was displaced with the arms of the swab, no adequate echocardiographic view could be obtained. The changes of each hemodynamical parameter are detailed in Tables 2 and 3.

#### 3.3. Postoperative outcome

There was no death. One patient suffered a myocardial

infarction in the territory of a heavily calcified posterior descending artery. This patient required a transient inotropic support and the ejection fraction at 1 week was similar to the preoperative one (55%). No other patient required β-adrenergic inotrope postoperatively. Supraventricular arrhythmias in form of an atrial fibrillation occurred in four patients (15%). All could be converted with amiodarone therapy. Two patients required antibiotics because of pneumonia (8%). There was neither wound infection, renal failure nor neurological event. Transfusion was required in three patients (11%), but no re-exploration for bleeding was needed.

### 4. Discussion

This study shows that stable hemodynamics can be preserved during OPCAB, whichever target artery is revascularized, provided a technique of exposure and stabilization avoiding any compression of the heart chambers is applied. None of the hemodynamical parameters differed significantly from baseline value for all three territories. While hemodynamics was perfectly maintained during the posterior and anterior walls revascularization, exposure of the lateral wall led to marginal hemodynamical changes only.

The technique of exposure reported here is a modification of the 'single suture' technique described by Ricci et al. [6]. Traction sutures were not applied because they lift the whole pericardial cavity, reducing the freedom of movement of the heart, which is required for subsequent manip-

Table 3  
Heart rate, cardiac output index and mixed venous saturation profiles<sup>a</sup>

	HR			COI			SvO <sub>2</sub>		
	Value	Δ	P	Value	Δ	P	Value	Δ	P
Baseline	60.2 ± 10.3			2.26 ± 0.55			74.8 ± 9.3		
Posterior wall	60.9 ± 8.8	0.8 ± 4.5	0.79	2.17 ± 0.39	-0.08 ± 0.15	0.56	71.7 ± 8.3	-3.1 ± 5.4	0.24
Lateral wall	62.2 ± 9.3	2.9 ± 6	0.33	1.99 ± 0.47	-0.26 ± 0.18	0.09	70.5 ± 8.4	-4.3 ± 5.3	0.12
Anterior wall	63.6 ± 8	3.5 ± 6	0.23	2.17 ± 0.63	-0.09 ± 0.24	0.61	71.3 ± 9.4	-3.5 ± 5.9	0.23

<sup>a</sup> HR, heart rate (beats/min); COI, cardiac output index (l/min per m<sup>2</sup>); SvO<sub>2</sub>, mixed venous saturation (%); Δ, difference between the value recorded 10 min following exposure and stabilization of the target artery and that recorded at baseline.

ulations. Nevertheless, several important points differ from the original technique [6]. Firstly, the stitch was placed on the right side of the spine in order to increase the lever arm when lifting the heart. Secondly, the traction on the arms of the swab was always applied away from the target wall, in other words the arms were never pulled across the heart in order to avoid any compression which may alter the geometry of the heart chambers leading to systolic and diastolic function compromise. With appropriate traction on both arms and adequate positioning of the operating table, a proper exposure of the lateral and posterior walls may be achieved without hemodynamical compromise, even for those difficult accessible arterial segments near the atrio-ventricular groove. Thirdly, no right pericardial/pleura incision, to allow partial herniation of the heart into the right chest as recommended [6], was necessary.

In keeping with this 'no compression' philosophy, a suction-type stabilizer was used. It allows stabilization of the target artery with minimal compression effect in contrast to compression type system. In order to apply properly these exposure and stabilization techniques, it is important to stress that both should be used in a complementary fashion exclusively. Neither exposure technique should be used for stabilization, nor should stabilization technique be used for exposure. In the first case, the arms of the swab are used to stabilize the target area by wrapping them around the heart which may induce heart function compromise. In the second case, two complications may be anticipated. On the one hand, using the stabilizer as an exposure device can potentially damage the ventricular wall with the risk of severe bleeding. On the other hand, the stabilizer device itself leads to a distortion of the underlying and the adjacent heart chambers, and/or a compression of the underlying chamber according to the predominant forces applied by the stabilizer. Experimental studies fully support these hemodynamical concerns. Gründeman et al. [8] and Porat et al. [9] both used a suction stabilizer to displace the heart vertically in a porcine model by applying the device on the posterior wall. This procedure uniformly induced significant hemodynamical disturbance.

The use of intracoronary shunt belongs to the strategy of hemodynamical optimization. When dealing with ischemic heart disease, it seems logical to maintain intracoronary flow during the completion of the anastomosis in order to avoid any additional ischemic burden while the heart is not in its physiological position. Nevertheless, Gründeman et al. [14], in a porcine model, was able to restore coronary flow in the three coronary territories which were compromised while the heart was retracted by 90°, by increasing the preload with the Trendelenburg maneuver. However, this experiment was carried out on healthy hearts with normal coronary arteries, and such findings cannot be applied to diseased coronaries with ischemic myocardium.

Beside the exposure and stabilization techniques and the use of intracoronary shunt, anesthetic management appears as an essential part of the hemodynamics optimization strat-

egy. Our anesthetic technique relies on two principles. Firstly, the heart rate should be slow and the myocardium contractility should be limited in order to offer the best conditions for the grafting. For these purposes, preoperative  $\beta$ -blocker and intraoperative diltiazem were used. Secondly, the tools applied to maintain hemodynamics, when needed, should not increase myocardial oxygen consumption. Therefore, atrial pacing and noradrenaline were used, while  $\beta$ -adrenergic inotropes were avoided.

The impact of other strategies of exposure and stabilization have been reported in previous clinical series [15–17]. As expected, the use of the stabilization device as an exposure tool led to significant hemodynamical changes in all three territories [15,16]. The distinction between the exposure and the stabilization phase with the 'Bristol technique' led to improved hemodynamics. However, significant changes were still noted with the posterior descending artery and the circumflex branches. Notably, with this technique, the arms of the swab were pulled across the heart during the exposure of these two territories, which could explain the observed changes. With our technique, the hemodynamical parameters were nearly unchanged for both the anterior and the posterior walls, while the lateral wall appeared to have the largest impact on hemodynamics albeit non significant. This trend is in keeping with the other studies which all reported the most severe disturbances associated with lateral wall exposure. The most striking difference with the other studies is the remarkable hemodynamical stability observed during posterior wall exposure which was similar to that of the anterior wall.

This study was designed to analyze a homogeneous group of patients and to obtain comparable data. Therefore, in contrast to others, only patients requiring three grafts, one to each side of the heart, were selected and the three walls were always revascularized in the same sequential order. Moreover, an ejection fraction  $\geq 30\%$  was required. With these criteria, the interferences of different sequences of grafting, different timings of grafting and severe ventricular dysfunction were avoided. Notably, a pre-established sequence of grafting may be safely followed independently of the degree of stenosis of the different coronary arteries only when intracoronary shunts are systematically used. We performed the LAD-LITA anastomosis last in order to allow enough time to the papaverine to diffuse to the LITA graft. Of course, this sequence should not be considered as a recommendation and the choice of the sequence is dictated by the surgeon's preference.

Bringing the heart back to its anatomical position between the grafts in order to allow hemodynamical recovery has been described by previous groups [16,17]. Nevertheless, with the present technique, good hemodynamics could be maintained despite the fact that no time was allowed for the heart to resume between the grafts. Such a maneuver appears unnecessary provided that the principles of the present technique are respected.

No proper echocardiographic window could be found

once traction was applied to the arms of the swab. This is mainly due to the interposition of the swab between the heart and the echocardiographic probe, because filling the pericardium with saline did not improve the echocardiographic access. The monitoring was limited to hemodynamical measurements. Nevertheless, this drawback is compensated by the good hemodynamical tolerance to the heart manipulation.

The results of initial experimental [13,14] and clinical studies [16] have prompted the development of miniaturized circulatory assist system [18–20] in order to stabilize the hemodynamical situation especially for the grafting of posterior and lateral walls. It is clear from the present results that with improved techniques of exposure and stabilization, such devices are not necessary for routine OPCAB. This is supported by the recent large series of OPCAB which did not use circulatory support system [9–11] even in a subgroup of patients with ejection fraction  $\leq 30\%$  [21]. Moreover, the aim of OBCAB is to reduce the invasiveness of the procedure. Performing OPCAB without circulatory support is in accordance with this philosophy, as the inflammatory response to foreign surfaces and the full dose of heparin with its subsequent clotting disturbances are avoided.

In conclusion, the present technique of exposure and stabilization which avoids compression of the heart chambers allows stable hemodynamics during OPCAB whichever the myocardial area is revascularized. This technique is simple, reproducible and applies the same principle to all the arterial segments.

#### 4.1. Limitations

In order to maintain the homogeneity of the study group, patients with an ejection fraction  $\geq 30\%$  were selected. This study did not address the patients with a severe left ventricular dysfunction, and clearly further study is needed for this group. The right coronary artery was not specifically analyzed because the indication to bypass the right coronary artery was limited to critical proximal stenosis or occlusion, and in the present series, it occurred that all the patients were candidates for the revascularization of its branches. Cardiac output measurements were performed on heart with altered left and right ventricular geometry. Whether these conditions interfere with the validity of such measurements remains to be determined. Nevertheless, while absolute values of cardiac output may be questioned, their trend throughout the manipulations parallel those of the  $SvO_2$ , which advocates for the validity of their profile.

#### References

- [1] Kirklin JK, Westaby S, Blackstone EH, Kirklin JW, Chenoweth DE, Pacifico AD. Complement and the damaging effects of cardiopulmonary bypass. *J Thorac Cardiovasc Surg* 1983;86:847–857.
- [2] Westaby S. Organ dysfunction after cardiopulmonary bypass. A systemic inflammatory reaction initiated by the extracorporeal circuit. *Intensive Card Med* 1987;13:85–95.
- [3] Kolesov VI. Mammary artery-coronary artery anastomosis as a method of treatment of angina pectoris. *J Thorac Cardiovasc Surg* 1967;54:535–544.
- [4] Buffolo E, Andrade JC, Branco JN, Aguiar LF, Ribeiro EE, Jatene AD. Myocardial revascularization without extracorporeal circulation. Seven-year experience in 593 cases. *Eur J Cardiothorac Surg* 1990;4:504–507.
- [5] Calafiore AM, Angelini GD, Bergsland J, Salerno TA. Minimally invasive coronary artery bypass grafting. *Ann Thorac Surg* 1996;62:1545–1548.
- [6] Ricci M, Karamnouchian HL, D'Ancona G, Bergsland J, Salerno TA. Exposure and mechanical stabilization in off-pump coronary artery bypass grafting via sternotomy. *Ann Thorac Surg* 2000;70:1736–1740.
- [7] Gründeman PF, Borst C, van Herwaarden JA, Mansvelt Beck HJ, Jansen EWL. Hemodynamic changes during displacement of the beating heart by the Utrecht Octopus method. *Ann Thorac Surg* 1997;63:S88–S92.
- [8] Gründeman PF, Borst C, Verlaan CWJ, Meijburg H, Moues CM, Jansen EWL. Exposure of circumflex branches in the tilted, beating porcine heart: echocardiographic evidence of right ventricular deformation and the effect of right or left bypass. *J Thorac Cardiovasc Surg* 1999;118:316–333.
- [9] Sergeant P, de Worm E, Meyns B, Wouters P. The challenge of departmental quality control in the reengineering towards off-pump coronary artery bypass grafting. *Eur J Cardiothorac Surg* 2001;20:538–543.
- [10] Arom K, Flavin TF, Emery RW, Kshetry VR, Janey PA, Petersen RJ. Safety and efficacy of off-pump coronary artery bypass grafting. *Ann Thorac Surg* 2000;69:704–710.
- [11] Cartier R, Brann S, Dagenais F, Martineau R, Couturier A. Systemic off-pump coronary artery revascularization in multivessel disease: experience of three hundred cases. *J Thorac Cardiovasc Surg* 2000;119:221–229.
- [12] Caputo M, Chamberlain MH, Özap F, Underwood MJ, Ciulli F, Angelini GD. Off-pump coronary operations can be safely taught to cardiothoracic trainees. *Ann Thorac Surg* 2001;71:1215–1219.
- [13] Porat E, Sharony R, Ivry S, Ozaki S, Meyns BP, Flameng WJ, Uretzky G. Hemodynamic changes and right heart support during heart displacement of the beating heart. *Ann Thorac Surg* 2000;69:1188–1191.
- [14] Gründeman PG, Borst C, van Herwaarden JA, Verlaan CW, Jansen EWL. Vertical displacement of the beating heart by the Octopus tissue stabilizer: influence on coronary flow. *Ann Thorac Surg* 1998;65:1348–1352.
- [15] Nierich AP, Diephuis J, Jansen EWL, Borst C, Knappe JTA. Heart displacement during off-pump CABG: how well is it tolerated? *Ann Thorac Surg* 2000;70:466–472.
- [16] Mathison M, Edgerton JR, Horwell JL, Akin JJ, Mack MJ. Analysis of hemodynamic changes during beating heart surgical procedures. *Ann Thorac Surg* 2000;70:1355–1361.
- [17] Waters MPR, Ascione R, Ryder IG, Ciulli F, Pitsis AA, Angelini GD. Haemodynamic changes during beating heart coronary surgery with the 'Bristol Technique'. *Eur J Cardiothorac Surg* 2001;19:34–40.
- [18] Mathison M, Buffolo E, Jatene AD, Reichensperner H, Matheny RG, Shennib H, Akin JJ, Mack MJ. Right heart circulatory support facilitates coronary artery bypass without cardiopulmonary bypass. *Ann Thorac Surg* 2000;70:1083–1085.
- [19] Geskes GG, Dekker AL, van der Veen FH, Cramers AA, Maessen JG, Shoshani D, Prenger KB. The Enabler right ventricular circulatory support system for beating heart coronary artery bypass graft surgery. *Ann Thorac Surg* 1999;68:1558–1561.
- [20] Meyns B, Sergeant P, Siess T, Zietkiewicz M, Perek B, Nishida Y, Flameng W. Coronary artery bypass graft with biventricular microaxial pumps. *Perfusion* 1999;14:287–290.
- [21] Arom K, Flavin TF, Emery RW, Kshetry VR, Petersen RJ, Janey PA. Is low ejection fraction safe for off-pump coronary bypass operation? *Ann Thorac Surg* 2000;70:1021–1025.