

A rare cause of pacemaker-related endocarditis

Vanessa Kraege^{a,b}, Jonathan Bloch^b, Jean-Daniel Baumgartner^b, Martin Fromer^c, Alain Delabays^{b,c}

^a Department of Internal Medicine, Centre Hospitalire Universitaire Vaudois, Lausanne, Switzerland

^b Department of Internal Medicine, Ensemble Hospitalier de la Côte, Morges, Switzerland

^c Department of Cardiology, Centre Hospitalire Universitaire Vaudois, Lausanne, Switzerland

Summary

We report the case of a 76-year-old man who had a dual-chamber pacemaker implanted 17 years before and was initially admitted due to a *Campylobacter fetus* bacteraemia without any evident source of infection. He was treated by imipenem/cilastatin followed by ciprofloxacin for a total of four weeks. Two months later he presented with high fever, night sweats and a weight loss of 11 kg. Blood cultures showed the presence of *Campylobacter fetus*. An echocardiogram demonstrated vegetations on the pacemaker probes, not visualised on the ultrasound performed two months before. After extraction of the leads and pacemaker and another four weeks of intravenous antibiotherapy (imipenem/cilastatin and gentamicin), a new system was implanted. The patient regained weight and did not show any recurrence of symptoms at one-year follow-up.

Key words: *Campylobacter fetus*; pacemaker leads

Case report

This 76-year-old man had a dual-chamber pacemaker implanted in a right pectoral position 17 years before because of a sick sinus syndrome, a right bundle branch block and a left anterior fascicular block, without syncope. The battery was changed after 12 years. Other medical problems included chronic stable coronary artery disease, high blood pressure, dyslipidaemia, well-controlled type II diabetes mellitus (HbA1c 6%) and chronic renal disease stage IIIa.

The patient initially presented with a ten-day history of high fever and night sweats, as well as a three-day history of lumbar back pain. Clinical examination was non-contributive. Laboratory exams showed a white blood cell count of 9.2 G/l with 22% non-segmented neutrophils, CRP 104 mg/l and sedimentation rate 20 mm/h. *Campylobacter fetus* grew in three of six blood culture bottles. The urine culture was sterile.

Search for an infection site included spinal X-rays followed by a lumbar CT-scan which disclosed important bone remodelling of the L2/L3, L3/L4, L4/L5 intersomatic spaces with numerous erosions of the vertebral bodies and subchon-

dral condensations without any sign of intradiscal air. Although the nature of the bone lesions was not typically infectious, spondylodiscitis could not be formally excluded. Other radiological examinations included a chest X-ray and an abdominal CT-scan. Neither showed any sign of infection. A transthoracic echocardiogram was performed: there were no alterations suspicious of a vegetation, neither on the tricuspid valve nor on the pacemaker leads. The left ventricular ejection fraction was 60%.

Once *Campylobacter fetus* was isolated in the blood cultures, antibiotherapy by amoxicillin / clavulanic acid and clarithromycin was initiated but stopped the next day due to a skin reaction. The patient then received two days of gentamicin and imipenem/cilastatin (500 mg 4 times a day), followed by two weeks of imipenem/cilastatin alone and another two weeks of oral ciprofloxacin. The antibiogram showed sensitivity to these antibiotics. Shortly after the start of the therapy, the fever disappeared and a pair of blood cultures on the eighth day post admission was negative. Laboratory results then showed a white blood cell count of 5 G/l with 0% non-segmented neutrophils.

Because of the reappearance of fever, night sweats and a weight loss of 11 kg since the first symptoms, the patient was referred to our hospital by his general practitioner, two months later. Clinical examination was non-contributive. Four out of four blood cultures grew *Campylobacter fetus*. A thoraco-abdominal CT-scan was repeated. No infection focus could be seen and the L2/L3, L3/L4, L4/L5 lesions had not changed. The lack of evolution in two months allowed us to rule out spondylodiscitis. A transthoracic echocardiogram was repeated. This time, the presence of vegetations on the pacemaker probes was suspected, motivating a transoesophageal echocardiogram. The latter showed an image suggestive of vegetations on the leads in the right atrium and possibly in the right ventricle too.

Funding / potential competing interests:

No financial support and no other potential conflict of interest relevant to this article were reported.

Correspondence:

Vanessa Kraege
Department of internal medicine, CHUV, Bâtiment hospitalier
Rue du Bugnon 46
CH-1011 Lausanne
Switzerland
vrkraege[at]yahoo.com

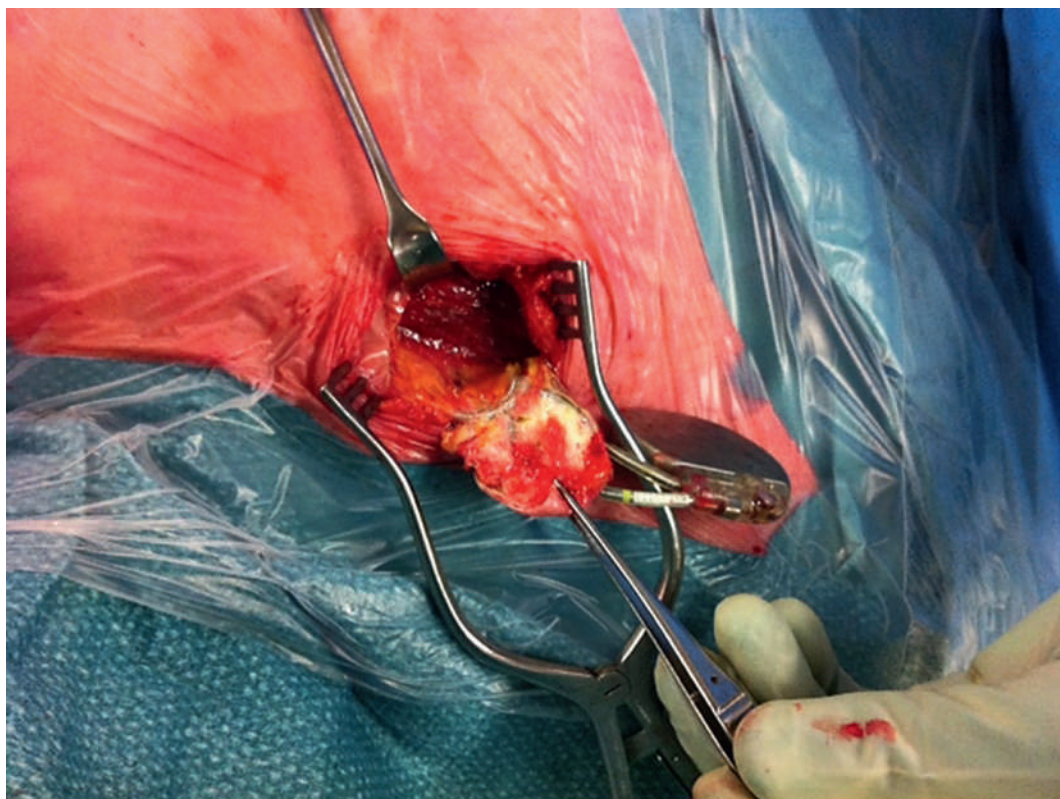


Figure 1
Photograph of the pacemaker during removal. The battery is completely surrounded by calcified granulation tissue. Culture grew *Campylobacter fetus*.

A therapy of imipenem/cilastatin and gentamicin was initiated. Five days later a transitory pacemaker was implanted. The next day the original pacemaker was removed and the leads extracted. The pacemaker, including the battery and leads, was entirely surrounded by a calcified granulation tissue (fig. 1). The ventricular lead grew *Campylobacter fetus*, whereas there was no growth on the atrial lead. Two weeks after the start of antibiotherapy, a new dual-chamber pacemaker was implanted in a left pectoral position. A transthoracic echocardiogram performed five days after this implantation did not show any vegetations and repeated blood cultures were negative. The intravenous antibiotherapy was stopped after four weeks without any recurrence of infectious symptoms at one-year follow-up.

Discussion

Despite the absence of previous gastrointestinal symptoms, our patient presented with a fever of unknown origin finally attributed to a systemic *Campylobacter fetus* infection. We did not perform a transoesophageal echocardiogram because symptoms rapidly disappeared with the start of antibiotherapy and no vegetations were seen on the first transthoracic cardiac ultrasound. Moreover, *Campylobacter fetus* can cause pro-

longed fever without one's being able to demonstrate a source of infection. However, when the patient presented two months later, both the transthoracic and transoesophageal echocardiograms showed the presence of vegetations. The growth of *Campylobacter fetus* on the ventricular lead confirmed that this bacteria was responsible for the pacemaker infection. Since *Campylobacter fetus* appears to have a tropism for endovascular tissue, we suggest that a transoesophageal echocardiogram be performed systematically in patients with a pacemaker and a *Campylobacter fetus* infection, because transoesophageal echocardiography allows better visualisation of cardiac valves and pacemaker leads. We also suggest that prolonged intravenous antibiotherapy be administered in patients with *Campylobacter fetus* and a cardiac device, even if no vegetations are visible.

Due to the presence of infected foreign material, the optimal treatment is long term antibiotherapy and removal of the infected device [1]. Removal of the leads can be complicated by cardiac perforation or tears in the superior vena cava leading to potentially life-threatening situations, thus remaining a medical challenge.

Campylobacter fetus is an uncommon pathogen. Its reservoir hosts are mainly cattle and sheep, and consumption of meat is probably the main source of infec-

tion in humans. Unlike *Campylobacter fetus* which is much more frequent in humans, *Campylobacter fetus* has the capacity to cross the gastrointestinal barrier. The presence of a capsule-like S protein prevents complement-mediated killing in the serum, thus causing systemic infections. It produces diarrheal illness less frequently than *Campylobacter jejuni* and often occurs in immunocompromised patients. *C. jejuni* infected patients usually present with fever without any localised source of infection. Indeed, *Campylobacter fetus* has a tropism for endovascular tissue but focal infection such as meningoencephalitis, osteomyelitis, perimyocarditis, salpingitis or cholecystitis can also occur [2, 3].

To the best of our knowledge, this case is the first report of a pacemaker lead infection by *C. fetus*. A single case report of a *Campylobacter fetus* infection of a pacemaker pocket has been published [4]. Interestingly, the patient was immunocompromised and did not have any gastrointestinal symptoms nor close contact with animals or undercooked animal products. A red swelling developed in the region of the pacemaker pocket concomitantly with the worsening of the patient's condition. *Campylobacter fetus* was found in three blood cultures and on the extracted pacemaker. Transoesophageal echocardiography was normal. Once the pacemaker was removed and the pocket drained, the patient showed an immediate disappearance of symptoms.

Pacemaker lead infections by any pathogen are more unusual than pocket infections and more difficult to diagnose because they are not always accompanied by local symptoms such as erythema or pain at the site of implantation. Clinicians should be aware of the possibility of pacemaker leads infection in every patient with a pacemaker and a prolonged febrile illness. Pacemaker removal and lead extraction are generally indicated together with a prolonged course of antimicrobial therapy.

References

- 1 Habib G, Hoen B, Tornos P, Thuny F, Prendergast B, Vilacosta I, et al. Guidelines on the prevention, diagnosis, and treatment of infective endocarditis (new version 2009): the Task Force on the Prevention, Diagnosis and Treatment of Infective Endocarditis of the European Society of Cardiology (ESC). Endorsed by the European Society of Clinical Microbiology and Infectious Diseases (ESCMID) and the International Society of Chemotherapy (ISC) for Infection and Cancer. *Eur Heart J*. 2009;30(19):2369–413.
- 2 Allos BM, Calderwood SB, Bloom A. Infection with less common *Campylobacter* species and related bacteria. UpToDate; 2012.
- 3 Blaser MJ, Smith PF, Repine JE, Joiner KA. Pathogenesis of *Campylobacter fetus* infections: failure of encapsulated *Campylobacter fetus* to bind C3b explains serum and phagocytosis resistance. *J Clin Invest*. 1988;81:1434–44.
- 4 Ledina D, Ivic I, Karanovic J, Karanovic N, Kuzmicic N, Ledina D, et al. *Campylobacter fetus* infection presenting with bacteremia and cellulitis in a 72-year-old man with an implanted pacemaker: a case report. *J Med Case Rep*. 2012;6:414.