

Article

Oral Mineralocorticoid-Receptor Antagonists: Real-Life Experience in Clinical Subtypes of Nonresolving Central Serous Chorioretinopathy With Chronic Epitheliopathy

Alejandra Daruich^{1*}, Alexandre Matet^{1*}, Ali Dirani¹, Mathilde Gallice¹, Luke Nicholson², Sobha Sivaprasad², and Francine Behar-Cohen^{1,3,4,5}

¹ Department of Ophthalmology, University of Lausanne. Jules-Gonin Eye Hospital. Fondation Asile des Aveugles, Avenue de France 15, CP 133 1000 Lausanne 7, Switzerland

² NIHR Moorfields Biomedical Research Centre, 162 City Road, London EC1V 2PD, United Kingdom

³ Sorbonne Universités, UPMC Université Paris 06, UMR 1138, Centre de Recherche des Cordeliers, team 17, 15 rue de l'École de Médecine, 75006, Paris, France

⁴ INSERM, UMR 1138, Centre de Recherche des Cordeliers, 15 rue de l'École de Médecine, 75006, Paris, France

⁵ Université Paris Descartes, Sorbonne Paris Cité, UMR 1138, Centre de Recherche des Cordeliers, 15 rue de l'École de Médecine, 75006, Paris, France

Correspondence: Francine Behar-Cohen, Department of ophthalmology, University of Lausanne, Jules-Gonin Eye Hospital, Fondation Asile des Aveugles, Avenue de France 15, CP 133, 1000 Lausanne 7, Switzerland; e-mail: francine.beharcohen@fa2.ch

Received: 12 August 2015

Accepted: 12 January 2016

Published: 4 March 2016

Keywords: central serous chorioretinopathy; treatment, eplerenone; spironolactone; mineralocorticoid-receptor antagonist; drug-related side effects and adverse reactions; choroid; retinal pigment epithelium

Citation: Daruich A, Matet A, Dirani A, et al. Oral mineralocorticoid-receptor antagonists: real-life experience in clinical subtypes of nonresolving central serous chorioretinopathy with chronic epitheliopathy. 2016;5(2):2, doi:10.1167/tvst.5.2.2

Purpose: To evaluate the efficacy and safety of oral mineralocorticoid-receptor antagonist (MRa) therapy in three clinical presentations of nonresolving central serous chorioretinopathy (CSCR) with chronic epitheliopathy.

Methods: Retrospective case series of consecutive patients with nonresolving CSCR treated with oral eplerenone or spironolactone. Treatment criteria were: persistent CSCR with subretinal fluid (SRF) lasting longer than 4 months; recurrent CSCR with SRF lasting longer than 2 months; persistent CSCR (SRF \geq 4 months) with fundus autofluorescence gravitational tracks. Outcomes at 1, 3, and 6 months were: foveal SRF height, central macular thickness (CMT), subfoveal choroidal thickness (SFCT), best-corrected visual acuity (BCVA), and occurrence of side effects.

Results: Among 54 eyes from 42 patients (mean age: 53 years), mean foveal SRF, CMT, and SFCT decreased significantly at 1, 3, and 6 months after treatment initiation. Mean BCVA improved significantly at 6 months. In the subgroup analysis, mean foveal SRF, CMT, and SFCT decreased significantly at 3 and 6 months in the persistent and recurrent groups. In persistent cases with tracks, a significant diminution of mean CMT and SFCT was achieved at 6 months. Treatment-related side effects were observed in 6 patients, prompting treatment discontinuation in one case.

Conclusion: Response to treatment was observed in the three subgroups. In persistent CSCR with tracks the response was delayed compared with persistent and recurrent cases, suggesting that longer treatment durations would be beneficial in patients with gravitational tracks of RPE alteration.

Translational Relevance: The clinical response to oral MRa is consistent with the involvement of the mineralocorticoid pathway in CSCR pathogenesis.

Introduction

Central serous chorioretinopathy (CSCR) is a vision-threatening condition predominantly affecting middle-aged males and characterized by serous retinal detachments in the macular area. Acute CSCR episodes usually resolve within 4 months without visual consequences. Yet, a fraction of these cases

may persist or recur.¹ The chronic form, also known as “diffuse retinal pigment epitheliopathy,”² presents with widespread RPE changes and atrophy associated to variable degrees of intraretinal cysts.³ These alterations persist over time, leading to pronounced visual loss.^{4,5} In addition, choroidal thickening, or “pachychoroid,” is frequently observed in acute and chronic CSCR.

There is no consensus regarding the optimal timing

and the most suitable option for treatment of nonresolving CSCR. Whereas observation is the appropriate first-line approach for acute episodes,⁶ long-standing subretinal detachments may induce irreversible photoreceptor damage, and treatment is therefore justified in these cases.⁷

To date, available physical treatments target specific features presumably involved in CSCR pathophysiology. Verteporfin photodynamic therapy (PDT) aims at reducing choroidal vascular hyperpermeability and congestion.⁸ Laser photocoagulation attempts to seal RPE leakage sites.⁹ Both treatments are aimed at focal leakage areas, while there is evidence of diffuse and bilateral changes affecting the choroid and the RPE, particularly in chronic CSCR.

Recently, significant progress has been made on our understanding of a hypothesis regarding molecular events triggering choroidal vasodilatation in CSCR.^{10,11} Inappropriate activation of the mineralocorticoid receptor (MR) in choroidal endothelial cells, either by its natural ligand, aldosterone, or by glucocorticoids that have a high affinity for MR, induces upregulation of the vasodilator potassium channel KCa2.3 (calcium-dependent channel) and smooth muscle cells relaxation in the choroidal vasculature.

Therefore, spironolactone and eplerenone, two oral MR antagonists, have been proposed as systemic treatments for nonresolving CSCR, with reports of significant anatomical and functional responses in three series^{12–14} and one randomized trial.¹⁵ However, little data is available regarding the efficacy of these treatments on the various clinical forms of CSCR. Based on our experience of CSCR management using this novel approach, this retrospective interventional study aimed to evaluate the effect of oral MR antagonists in three clinical presentations of nonresolving CSCR.

Methods

For this retrospective interventional study, records of consecutive patients with nonresolving CSCR followed up at Jules-Gonin Eye Hospital or Moorfields Eye Hospital, who were initiated treatment with oral eplerenone or spironolactone between April 2013 and August 2014 were reviewed. This study involving human participants was designed in accordance with the tenets of the 1964 Declaration of Helsinki and its later amendments and with the ethical standards of the Ethics Committee of the

Swiss Federal Department of Health (n° CER-VD 19/15 and 20/15) and the institutional review board at the NIHR Moorfields Biomedical Research Centre (n° ROAD 15/031). The need of formal informed consent was waived due to the retrospective nature of the study.

‘Nonresolving CSCR with chronic epitheliopathy’ was defined by the presence of a sensory retinal detachment associated with areas of RPE atrophy and pigment mottling, manifesting on fluorescein angiography as extended or multifocal areas of granular hyperfluorescence, possibly containing one or several subtle leaks.¹⁶ Patients presenting features suggestive of an overlap with neovascular age-related macular degeneration, such as drusen, retinal hemorrhages, hard exudates or type 1 choroidal neovascularisation on dynamic and static indocyanine green angiography (ICG) were excluded, as well as patients who had previously responded to anti-vascular endothelial growth factor (VEGF) therapy. Patients with follow-up shorter than 3 months or with simultaneous treatment by PDT, laser photocoagulation, or intravitreal anti-VEGF were also excluded. Three groups were defined according to their history and retinal findings reflecting disease duration: (1) persistent CSR defined as nonresolving subretinal fluid for at least 4 months of observation, without knowledge of previous episodes, (2) recurrent CSCR defined as an active CSCR episode occurring at least 3 months after a previous episode, with nonresolving subretinal fluid for at least 2 months, and (3) persistent CSCR with tracks defined as nonresolving subretinal fluid for at least 4 months with gravitational tracks on fundus autofluorescence.

Baseline and monthly evaluations included best-corrected visual acuity (BCVA), comprehensive ophthalmological examination, and multimodal imaging by spectral-domain OCT and fundus autofluorescence (Spectralis, Heidelberg Engineering, Heidelberg, Germany). Fluorescein angiography, dynamic and static ICG angiography were performed at baseline (Spectralis).

Decision to treat with eplerenone or spironolactone for this off-label indication was made in agreement with each patient after informed consent. Treatment by eplerenone (Inspra; 25–50 mg daily; Pfizer AG, Zürich, Switzerland or Surrey, UK) or spironolactone (25–75 mg daily; Aldactone; Pfizer AG, Zürich, Switzerland or Sandwich, Kent, UK; Xenalon; Mepha Pharma AG, Basel, Switzerland) was administered orally in the morning. Treatment

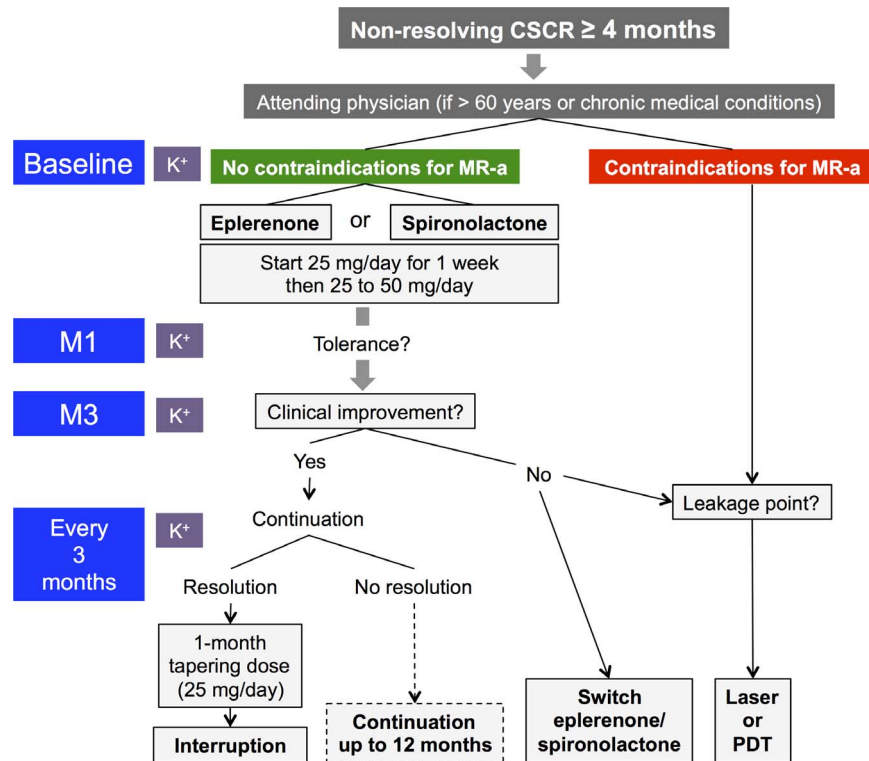


Figure 1. Treatment scheme for mineralocorticoid-receptor antagonists in patients with nonresolving CSCR. K⁺, potassium plasma level monitoring; M1, month 1; M3, month 3; MR-a, mineralocorticoid-receptor antagonists; PDT, photodynamic therapy.

was discontinued after complete resolution of subretinal fluid.

Based on recommendations by the Swiss Agency for Therapeutic Products (Swissmedic)¹⁷ and the electronic Medicines Compendium (eMC, Data-pharm, Leatherhead, UK)¹⁸ treatment by mineralocorticoid receptor antagonists was not initiated to patients presenting the following contraindications: pregnancy, severe heart, hepatic, or renal failure (creatinine clearance ≤ 30 mL/min), baseline kalemia greater than 5.0 mEq/L, concurrent treatment by potassium-sparing diuretics, angiotensin-converting enzyme inhibitors, angiotensin-2 receptor antagonists, nonsteroidal anti-inflammatory drugs, lithium, or potent CYP3A4 inhibitors. For patients older than 60 years of age, and those on treatment for a chronic condition (such as hypertension, diabetes, cardiovascular disease), MR-antagonists were introduced after agreement with the attending physician.

Kalemia was monitored at baseline, after 1 month and subsequently every 3 months in case of normal levels.¹⁹ In case of hyperkalemia greater than or equal to 5.0 mEq/L, MR antagonist dosing was reduced, and K⁺ levels were controlled closely. In case of hyperkalemia greater than or equal to 5.5 mEq/L,

treatment was interrupted. The treatment scheme is represented in [Figure 1](#).

The primary outcome was the height of subretinal fluid (SRF) at the fovea. Secondary outcomes were: central macular thickness (CMT), subfoveal choroidal thickness (SFCT), BCVA, and occurrence of side effects. In cases with extrafoveal SRF at presentation, the maximal elevation of SRF was also measured. CMT was measured from RPE to internal limiting membrane via the built-in Spectralis OCT software using the central field of an Early Treatment Diabetic Retinopathy Study (ETDRS) grid projected onto the thickness map. SFCT was evaluated manually on enhanced-depth imaging horizontal OCT scans, except when image quality was insufficient to discriminate the interface between outer choroid and sclera. All parameters were measured at baseline, 1, 3, and 6 months after treatment introduction. For each anatomical parameter (foveal SRF, CMT, SFCT), patients were classified as ‘responders’ when this parameter decreased from baseline to the last time-point available, and as ‘nonresponders’ otherwise. To compute means, Snellen BCVA values were converted to logarithm of the minimum angle of resolution (LogMAR). Statistical analyses were performed using

Table 1. Baseline Clinical Characteristics and Treatments Received

	All Patients	CSCR Subtype		
		Persistent	Recurrent	Persistent With Tracks
Baseline patients characteristics				
Number of subjects	<i>n</i> = 42	<i>n</i> = 17	<i>n</i> = 15	<i>n</i> = 10
Age, y	53.1	54.1	47.5	59.7
M/F (N)	37/5	13/4	14/1	10/0
Bilateral CSCR (N)	17	3	6	8
History of corticosteroid exposure	13	9	3	1
Baseline eyes characteristics				
Number of eyes	<i>n</i> = 54	<i>n</i> = 20	<i>n</i> = 19	<i>n</i> = 15
Duration since CSCR diagnosis, y (range)	5.4 (0.4–14.3)	4.1 (0.4–14.3)	4.3 (0.4–9.8)	8.7 (0.5–12.4)
Subfoveal SRF (N)	42	17	17	8
Extrafoveal SRF (N)	9	3	2	4
Intraretinal cysts (N)	8	3	0	5
Previous laser or PDT treatment (N)	9	3	3	3
Previous intravitreal anti-VEGF (N)	11	4	3	4
Treatment by oral mineralocorticoid receptor antagonist (patients treated, N)				
Spiro	12	6	3	3
Eple	22	7	9	6
Spiro, then eple	7	3	3	1
Eple, then spiro	1	1	0	0

Spiro, spironolactone; Eple, eplerenone; SRF, subretinal fluid; PDT, photodynamic therapy; VEGF, vascular endothelial growth factor.

Wilcoxon paired test, Mann-Whitney U test, and Chi-square tests where appropriate on GraphPad Prism (Version 5.0, GraphPad Software Inc., La Jolla, CA). *P* values inferior to 0.05 were considered significant.

Results

Cohort Description

Among 50 CSCR patients (67 eyes) who received oral MR antagonists during the study period, 42 patients (54 eyes) met the inclusion criteria, consisting of 37 men and 5 women. Mean age was 53.1 years (range, 32–81). According to their history at presentation, 20 eyes were classified as persistent CSCR, 19 eyes as recurrent CSCR, and 15 eyes as persistent CSCR with tracks. Eyes with persistent CSCR with tracks had significantly more advanced RPE alterations on fluorescein angiography, more frequent intraretinal cysts, photoreceptor atrophy, and flat irregular pigment epithelial detachments on OCT. Comparative imaging findings according to the clinical subtype are summarized in the [Supplementary Table S1](#).

Duration of disease since diagnosis of CSCR was 5.4

years in the whole cohort, and 4.1 years, 4.3 years, and 8.7 years in the persistent, recurrent, and persistent-with-tracks groups, respectively. Among the persistent cases with tracks, 9 of 15 eyes (60%) had a duration that exceeded 10 years. Overall, 12 subjects received spironolactone, 22 received eplerenone, and 8 received both treatments sequentially. Clinical and treatment characteristics are detailed in [Table 1](#).

Treatment Effect

When considering all patients together, mean foveal SRF decreased from 93 μm at baseline to 65 ($P = 0.009$), 39 ($P < 0.0001$), and 35 μm ($P < 0.0001$) at 1, 3, and 6 months, respectively ([Fig. 2](#)). Among 42 eyes with foveal SRF at baseline, 16 (38%) and 21 eyes (50%) showed a complete resolution of foveal SRF at 3 and 6 months, respectively. Notably, eyes with total foveal SRF resolution at 6 months had a greater relative foveal SRF decrease at 3 months than those without resolution (–69% vs. –21%, $P < 0.0001$).

Mean CMT decreased from 342 μm at baseline to 310 ($P = 0.002$), 288 ($P < 0.0001$), and 285 μm ($P = 0.0003$) at 1, 3, and 6 months, respectively ([Fig. 3](#)).

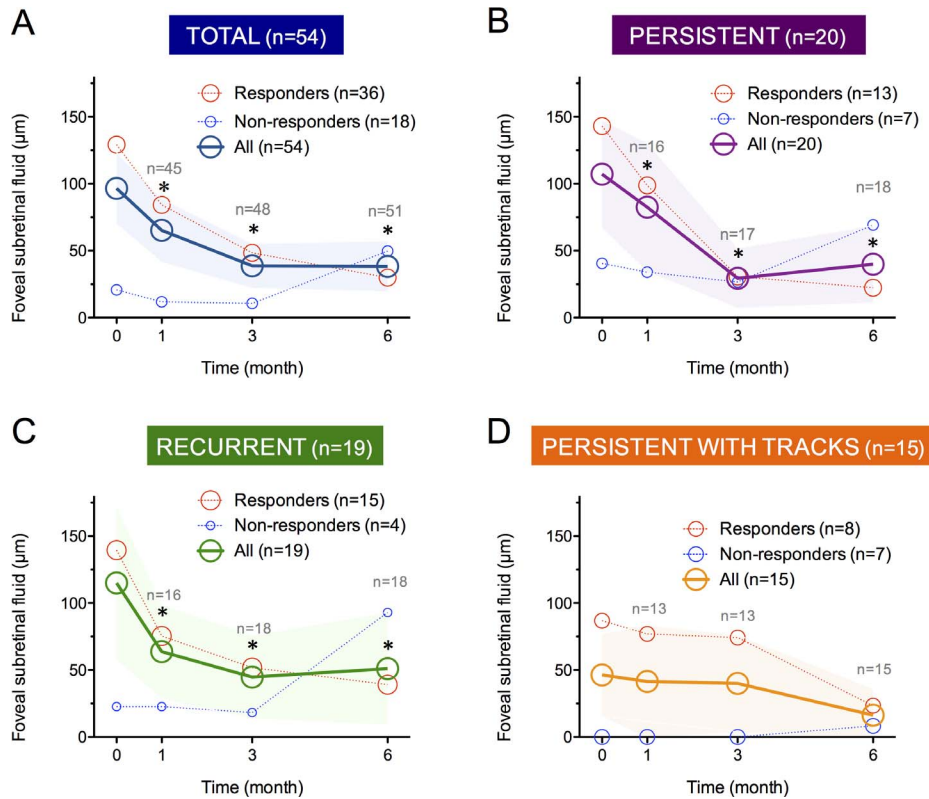


Figure 2. Profile of foveal subretinal fluid in 54 eyes with nonresolving CSCR treated by mineralocorticoid-receptor antagonists (A), and in three clinical CSCR subgroups: persistent (B), recurrent (C), and persistent with tracks (D). The areas of circular marks are proportional to the number of responders (red) and nonresponders (blue). * $P < 0.05$ compared with baseline values (Wilcoxon paired test), color-filled band: superior and inferior 95% confidence intervals.

Accurate determination of the SFCT was possible in 48 eyes. Mean SFCT decreased from 474 µm at baseline to 465 ($P = 0.039$), 434 ($P = 0.0007$), and 446 µm ($P < 0.0001$) at 1, 3, and 6 months, respectively (Fig. 4).

In a subset of 12 eyes that presented extrafoveal SRF at baseline, the maximal SRF height decreased from 101 µm at baseline to 42 ($P = 0.022$), 89 ($P = 0.46$), and 72 µm ($P = 0.039$) at 1, 3, and 6 months, respectively.

Mean LogMAR BCVA improved from 0.28 at baseline to 0.23 at 6 months ($P = 0.041$).

In a subgroup analysis according to the three clinical presentations, mean foveal SRF and CMT diminished significantly at 1, 3, and 6 months in both the persistent and recurrent groups (Figs. 2 and 3). Mean SFCT also decreased significantly at 3 and 6 months in these groups (Fig. 4). In persistent cases with tracks, a near-significant decrease in foveal SRF was observed after 6 months of treatment ($P = 0.058$; Fig. 2). In this group, a significant diminution of the mean CMT and SFCT was achieved only at 6 months

(Figs. 3 and 4). Results are reported in Table 2 and treatment responses are illustrated in Figure 5. Noticeably, mean SFCT at baseline was higher in the recurrent group (544 µm) than in the two other groups (431 µm; $P = 0.016$).

The kinetics of foveal SRF decrease differed between the three groups, with an early response followed by a plateau in the persistent and recurrent groups, and an initial plateau followed by a delayed response in the persistent cases with tracks (Fig. 2 and Table 2). In Figures 2 through 4 and 6, the proportion of responders/nonresponders regarding foveal SRF, CMT and SFCT are graphically reported. The three anatomical parameters showed a bimodal response with the proportion of responders systematically exceeding the proportion of nonresponders.

In a subgroup analysis according to age, patients younger than 51 years (the median age of the study population), showed at 1, 3, and 6 months a significant decrease in foveal SRF ($P = 0.0004$, $P = 0.0007$, and $P = 0.0031$, respectively) and CMT ($P = 0.0017$, $P = 0.0016$, and $P = 0.0037$, respectively),

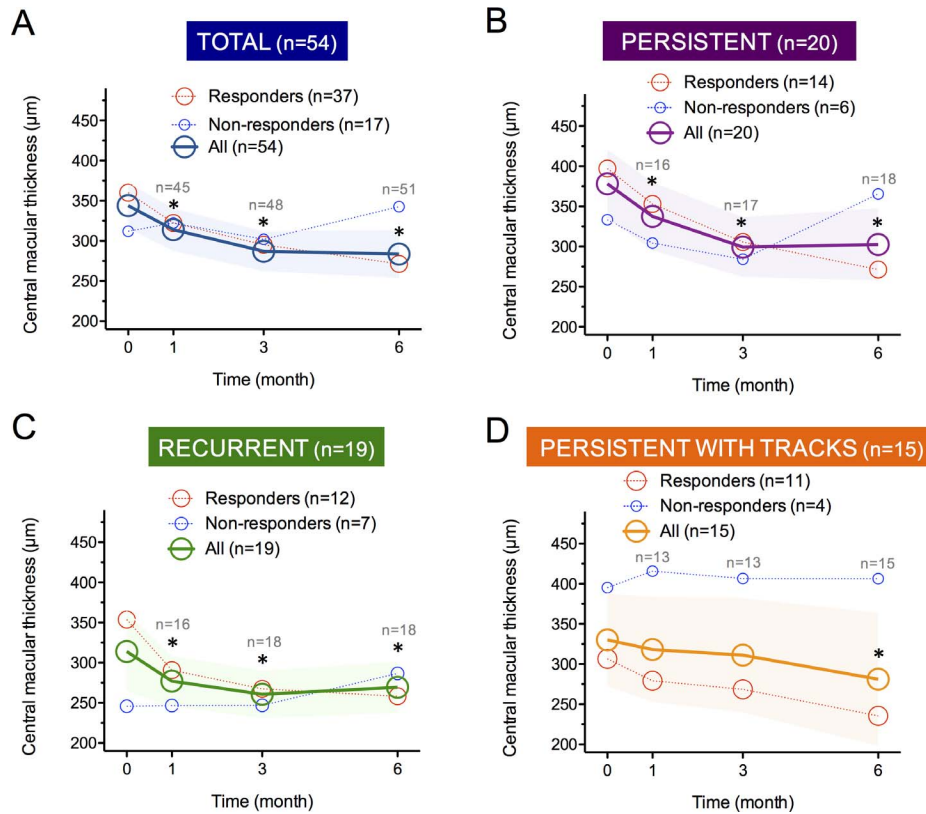


Figure 3. Profile of central macular thickness in 54 eyes with nonresolving CSCR treated by mineralocorticoid-receptor antagonists (A), and in three clinical CSCR subgroups: persistent (B), recurrent (C), and persistent with tracks (D). The areas of circular marks are proportional to the number of responders (red) and nonresponders (blue). * $P < 0.05$ compared with baseline values (Wilcoxon paired test), color-filled band: superior and inferior 95% confidence intervals.

while patients older than 51 years presented a significant decrease in both parameters at 3 and 6 months only (SRF, $P = 0.016$ and $P = 0.021$; CMT, $P = 0.011$ and 0.039 , respectively). Figure 6 illustrates the delayed and less pronounced response in older patients compared with younger ones.

Treatment Safety and Tolerance

Treatment-related side effects were observed in six patients. Among 20 patients who received spironolactone, one developed gynaecomastia, one had a systolic blood pressure less than 100 mm Hg detected by his attending physician without symptoms, and two developed hyperkalemia (5.0 and 5.2 mEq/L). Among 30 patients who received eplerenone, hyperkalemia was detected in two patients (5.0 and 5.7 mEq/L). All complications resolved after treatment interruption (1 patient), continuation under surveillance (2 patients), or switch from spironolactone to eplerenone (3 patients). A case-by-case description of these events is provided in Table 3.

Treatment Switch and Interruption

Among patients who received both treatments sequentially, seven subjects switched from spironolactone to eplerenone and one switched from eplerenone to spironolactone. Beside side effects described above, causes for treatment modifications are detailed in Table 4. No subject discontinued the treatment before 3 months. It was stopped in 11 patients after 3 to 6 months: in eight patients, resolution of foveal SRF was observed, and three individuals refused to continue the treatment.

At 6 months, there was no significant difference in foveal SRF variation from baseline between patients treated by spironolactone, eplerenone, or both drugs sequentially: -59 , -62 , and -73 μm, respectively ($P > 0.5$, Mann-Whitney U tests).

Discussion

In nonresolving CSCR patients treated with oral MR-antagonists, a significant anatomical improve-

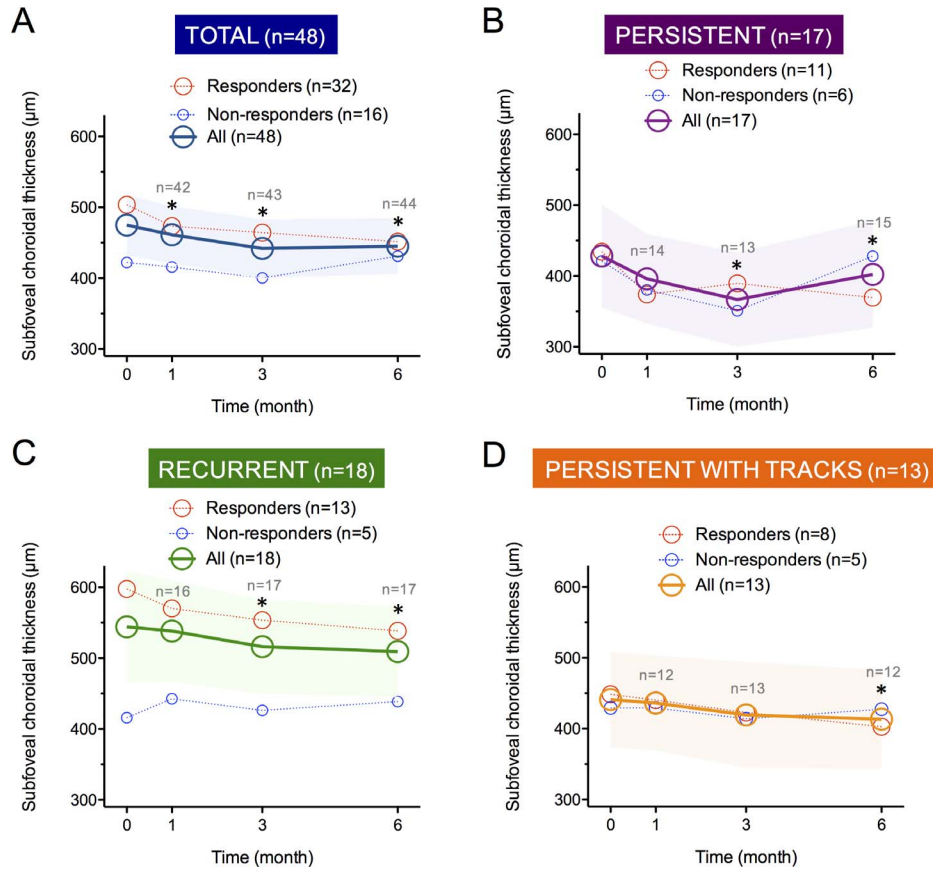


Figure 4. Profile of subfoveal choroidal thickness in 48 eyes with nonresolving CSCR treated by mineralocorticoid-receptor antagonists (A), and in three clinical CSCR subgroups: persistent (B), recurrent (C), and persistent with tracks (D). The areas of circular marks are proportional to the number of responders (red) and nonresponders (blue). * $P < 0.05$ compared with baseline values (Wilcoxon paired test), color-filled band: superior and inferior 95% confidence intervals.

ment was observed after 1, 3, and 6 months and visual improvement was observed at 6 months. Treatment produced only a limited number of side effects. These results suggest that oral MR-antagonists have a pharmacologic effect on CSCR eyes, as supported by previous animal¹⁰ and clinical studies.^{12–15}

When categorizing nonresolving CSCR cases into persistent, recurrent and persistent-with-tracks, a response to treatment was observed in all three subgroups. Interestingly, the kinetics of anatomical resolution indicated an earlier response to treatment in persistent and recurrent cases as compared with the persistent cases with tracks. This delayed response suggests that MR-antagonists should be prescribed for longer periods in persistent cases with tracks, characterized by gravitational tracks on fundus autofluorescence and more extended RPE disease on fluorescein angiography, in order to obtain significant anatomical benefits. Interestingly, in these eyes CMT is a relevant clinical endpoint due to the high

frequency of intraretinal cysts and low amount of SRF, and was significantly improved after treatment. Moreover, persistent cases with tracks often present an irreversible loss of photoreceptor outer segments, as observed in the present study (Figure 5O and Supplementary Table S1). Complete subretinal fluid resolution may not be reached due to this morphological gap, which is otherwise bridged by elongated outer segments. Patients aged 51 years or more also showed a delayed response as compared with those below 51 years, a finding consistent with the older age of persistent cases with tracks, as observed here and reported in the literature.¹⁶ Whether specific biological mechanisms involved in advanced RPE disease explain the delayed response of older, more chronic cases to oral MR-antagonists remains to be elucidated.

Regarding the functional effects of treatment, a significant improvement in BCVA was observed in the overall cohort and the persistent CSCR group at 6

Table 2. Treatment Effect According to the Three Clinical CSCR Subtypes

	Total (<i>n</i> = 54 Eyes)	Persistent CSCR (<i>n</i> = 20 Eyes)	Recurrent CSCR (<i>n</i> = 19 Eyes)	Persistent CSCR With Tracks (<i>n</i> = 15 Eyes)
Foveal subretinal fluid, μm (<i>P</i> value compared with baseline ^a)				
Baseline	96 \pm 28	107 \pm 40	115 \pm 57	46 \pm 31
1 mo	68 \pm 25 (0.009)	83 \pm 47 (0.016)	66 \pm 40 (0.0002)	42 \pm 41 (0.94)
3 mo	40 \pm 17 (<0.0001)	33 \pm 24 (0.002)	43 \pm 33 (0.0006)	40 \pm 36 (0.47)
6 mo	37 \pm 18 (<0.0001)	36 \pm 25 (0.006)	50 \pm 40 (0.012)	16 \pm 16 (0.058)
Central macular thickness, μm (<i>P</i> value compared with baseline ^a)				
Baseline	336 \pm 28	378 \pm 43	314 \pm 50	330 \pm 58
1 mo	316 \pm 28 (0.002)	337 \pm 50 (0.015)	277 \pm 32 (0.014)	318 \pm 66 (0.64)
3 mo	290 \pm 27 (<0.0001)	299 \pm 38 (0.020)	261 \pm 29 (0.0009)	311 \pm 81 (0.09)
6 mo	276 \pm 27 (0.0003)	303 \pm 45 (0.017)	264 \pm 21 (0.026)	281 \pm 83 (0.044)
Subfoveal choroidal thickness, μm (<i>P</i> value compared with baseline ^a)				
Baseline	474 \pm 34	428 \pm 73	544 \pm 69	434 \pm 82
1 mo	465 \pm 40 (0.039)	396 \pm 64 (0.81)	538 \pm 72 (0.050)	429 \pm 72 (0.50)
3 mo	434 \pm 43 (0.0007)	367 \pm 67 (0.009)	516 \pm 62 (0.023)	408 \pm 67 (0.41)
6 mo	446 \pm 40 (<0.0001)	402 \pm 76 (0.008)	509 \pm 64 (0.0024)	410 \pm 70 (0.041)
Best-corrected visual acuity, LogMAR (<i>P</i> value compared with baseline ^a)				
Baseline	0.28 \pm 0.09	0.25 \pm 0.12	0.13 \pm 0.06	0.52 \pm 0.25
1 mo	0.23 \pm 0.07 (0.24)	0.20 \pm 0.13 (0.014)	0.13 \pm 0.09 (0.93)	0.41 \pm 0.21 (1)
3 mo	0.25 \pm 0.09 (0.093)	0.21 \pm 0.14 (0.074)	0.10 \pm 0.08 (0.44)	0.52 \pm 0.27 (0.91)
6 mo	0.23 \pm 0.09 (0.041)	0.17 \pm 0.12 (0.018)	0.14 \pm 0.08 (0.82)	0.42 \pm 0.27 (0.16)

Mean values \pm 95% confidence intervals. LogMAR, logarithm of the minimum angle of resolution.

^a Wilcoxon paired signed-rank test.

months. In the recurrent group, the absence of significant improvement may be related to the high baseline BCVA levels. Patients presenting persistent CSCR with tracks showed a moderate improvement that failed to achieve significance due to the limited number of subjects. Consistently with RPE damages due to their long-standing disease, they also displayed lower baseline and final BCVA levels than the other CSCR subtypes. In these patients, initiation of treatment at earlier time, and prolonged treatment could avoid irreversible damage and should be further evaluated.

Nonresolving CSCR patients often have bilateral disease, as illustrated by the 40% of bilateral CSCR observed in the present study. They often present multiple leakage sites and areas of choroidal hyperpermeability.²⁰ This widespread involvement of the choroid and RPE in CSCR pathogenesis is also reflected by the diffuse choroidal thickening reported in acute and chronic CSCR.^{21,22} Hence, compared with focal treatments such as laser photocoagulation and PDT, oral therapies have a systemic biodistribution and diffuse in target organs at cellular level. In

addition, rationale for treatment by eplerenone and spironolactone rely on evidences that the MR is expressed in the choroid and neuroretina, and is implicated in CSCR pathogenesis.^{10,12,23}

Both drugs have already been evaluated for the treatment of nonresolving CSCR. In a prospective pilot study, Bousquet et al.¹² evaluated oral eplerenone (25–50 mg/day) in 13 CSCR eyes without improvement after 4 months, and observed a significant effect on foveal SRF and BCVA at 3 months. In a retrospective series of 17 CSCR eyes presenting the same characteristics and treated by oral eplerenone (25–50 mg/day), Singh et al.¹³ reported similar results up to 6 months after treatment initiation.¹⁴ In a prospective series of 20 eyes with nonresolving CSCR lasting longer than 6 weeks, Herold et al.¹³ evaluated oral spironolactone (50 mg/day) and described an improvement in SRF, CMT, and BCVA after 3 months. Finally, in a prospective, randomized, double-blinded study Bousquet et al.¹⁵ evaluated spironolactone (50 mg/day) versus placebo for 30 days followed by a crossover period of 30 days, on 16 eyes with SRF persisting for 3 months or more. They

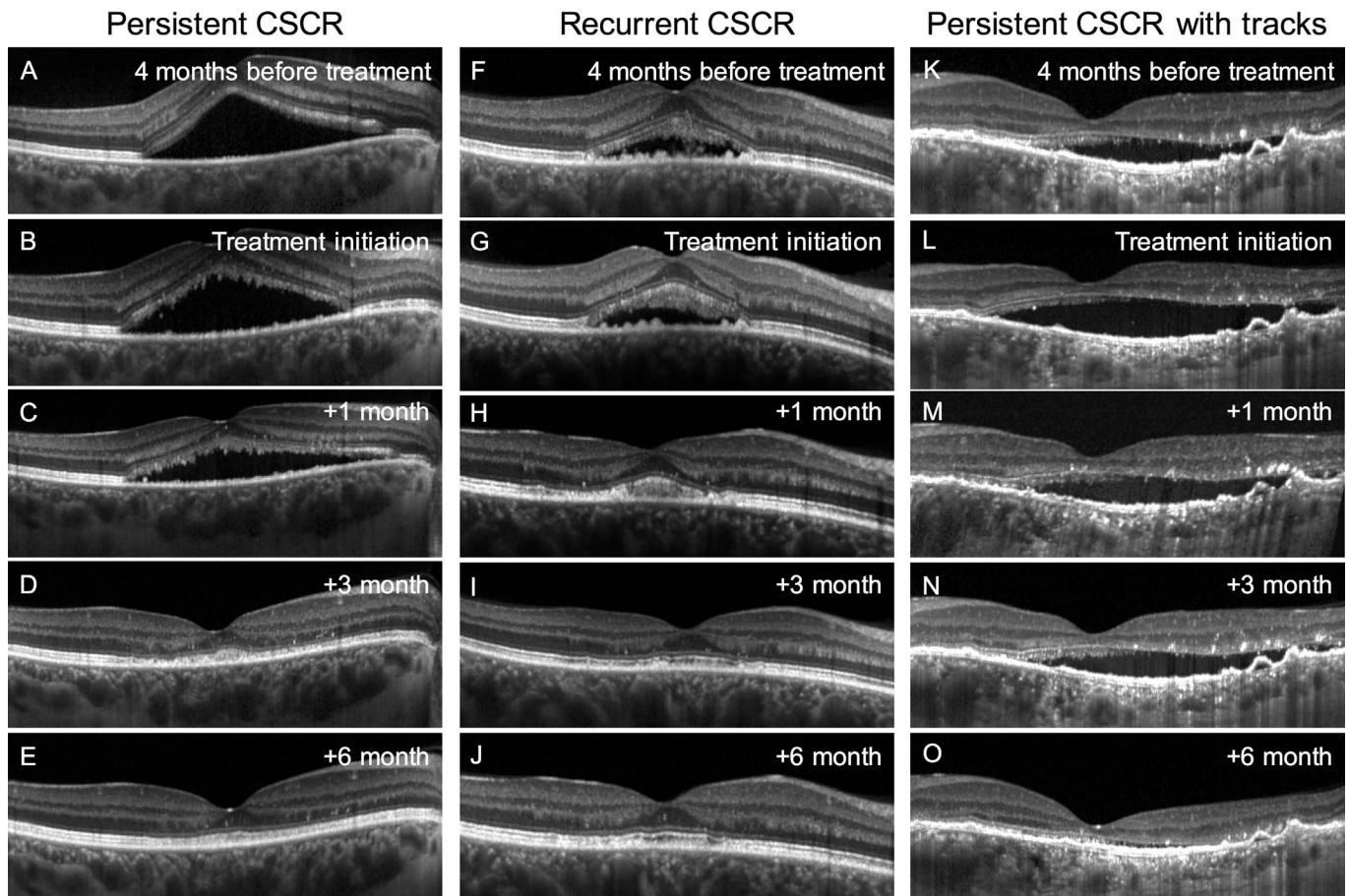


Figure 5. Optical coherence tomography showing the response to treatment by oral mineralocorticoid-receptor antagonists in three eyes with nonresolving CSCR. (A–E) Eye with persistent CSCR for 4 months without improvement, showing a progressive decrease in subretinal fluid after introduction of oral spironolactone, with complete resolution at 3 months, absence of recurrence and reconstitution of the ellipsoid zone by 6 months. (F–J) Eye with recurrent CSCR without improvement after 4 months of observation, progressive resolution 1 and 3 months following the introduction of oral eplerenone, with stability at 6 months. (K–O) Eye with persistent CSCR with tracks and evidence of nonresolving subretinal fluid during 4 months. After initiation of oral eplerenone, subretinal fluid was still present at 1 and 3 months, but a delayed, complete resolution was observed at 6 months.

observed a significant reduction in SRF in the spironolactone-treated eyes compared with the same eyes during the placebo period. The present study, collecting subjects from two different eye centers, confirms these observations in a larger cohort, and discriminates the effects of treatment between three clinical subcategories of nonresolving CSCR, which, to the best of our knowledge has not been previously contemplated. Moreover, we have pooled data from patients on spironolactone, eplerenone, or both drugs sequentially, and observed no difference in efficacy between both molecules, despite the higher binding affinity of spironolactone for the MR compared with eplerenone.²⁴

In all three subgroups, a significant diminution in

SFCT was observed after 6 months. In persistent CSCR, there was an overall SFCT diminution compared with baseline, but a partial reincrease at 6 months, possibly caused by an on/off effect because 5 of 20 patients discontinued treatment after 3 months. A decrease in SFCT has been previously observed in CSCR after spontaneous resolution, half-dose PDT²⁵ or treatment by oral MR-antagonists.¹⁵ These SFCT variations further illustrate the role of choroidal vasculature in CSCR pathogenesis. Unexpectedly, we observed that eyes categorized as recurrent CSCR had thicker choroids than those categorized as persistent or persistent with tracks. Consistently, a recent study evaluating CSCR recurrences after anti-VEGF or PDT reported a lower reduction in SFCT

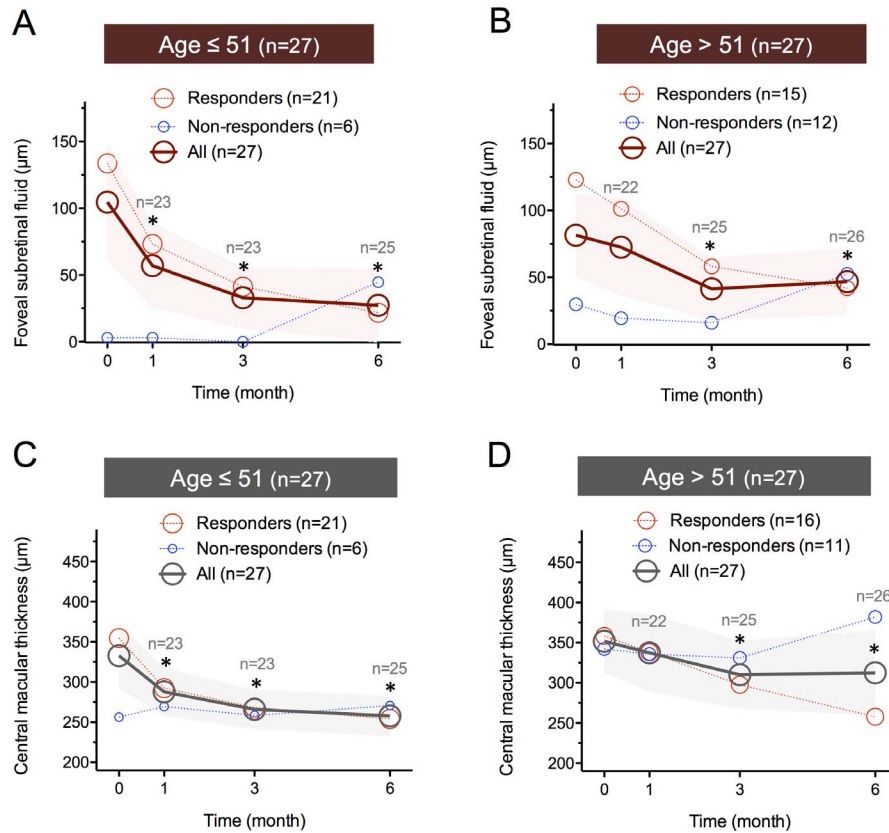


Figure 6. Profile of foveal subretinal fluid (A, B) and central macular thickness (C, D) in 54 eyes with nonresolving CSCR treated by mineralocorticoid-receptor antagonists, according to age at treatment introduction: less than or equal to 51 years (A, C) and greater than 51 years (B, D). The areas of circular marks are proportional to the number of responders (red) and nonresponders (blue). **P* < 0.05 compared with baseline values (Wilcoxon paired test), color-filled band: superior and inferior 95% confidence intervals.

Table 3. Description and Management of Side Effects Observed During Mineralocorticoid-Receptor Antagonist Therapy

Case		Treatment		Side Effect		Management of Side Effect	
Sex, Age	CSCR Type	Drug (Dose, mg/d)	Duration	Category	Effect	Decision	Resolution
M, 58 y	Recurrent	Spiro (50)	6 mo	Endocrine	Gynaecomastia	Switch to Eple	Yes
M, 46 y	Recurrent	Spiro (50)	3 mo	Vascular	Systolic blood pressure < 100 mm Hg	Switch to Eple	Yes
M, 60 y	Recurrent	Spiro (50)	1 mo	Electrolytic	K ⁺ = 5.0 mEq/L	Continuation of Spiro	Yes
M, 68 y	Persistent	Spiro (75)	3 mo	Electrolytic	K ⁺ = 5.2 mEq/L	Switch to Eple	Yes
M, 67 y	Persistent with tracks	Eple (50)	3 mo	Electrolytic	K ⁺ = 5.7 mEq/L	Interruption	Yes
M, 43 y	Recurrent	Eple (50)	3 mo	Electrolytic	K ⁺ = 5.0 mEq/L	Continuation of Eple	Yes

Spiro, spironolactone; Eple, eplerenone.

Table 4. Characteristics of Patients Who Underwent a Treatment Switch Between Oral Mineralocorticoid Antagonists

Sex, Age	CSCR Type	Drug Before Switch (Dose, mg/d)	Duration	Reason for Switch	Drug After Switch (Dose, mg/d)	Clinical Response
Switch from spiro to eple						
F, 53 y	Persistent	Spiro (50)	3 mo	Partial resolution with residual SRF	Eple (50)	Improvement
M, 38 y	Persistent	Spiro (50)	3 mo	Partial resolution with residual SRF	Eple (50)	Improvement
M, 46 y	Recurrent	Spiro (75)	3 mo	Partial resolution with residual SRF	Eple (50)	No improvement
M, 45 y	Persistent with tracks	Spiro (50)	4 mo	No effect	Eple (25)	No improvement
Switch from eple to spiro						
M, 68 y	Persistent	Eple (50)	3 mo	No effect	Spiro (25)	No improvement

* $P < 0.05$ compared with baseline values (Wilcoxon paired test), dotted lines: superior and inferior 95% confidence intervals. Spiro, spironolactone; Eple, eplerenone.

after resolution in recurrent eyes than in nonrecurrent eyes,²⁶ suggesting a link between thick choroids and recurrence risk.

Limitations of this study include its retrospective nature, the absence of a control group, the use of two drugs from the same class, and the numerical dispersion of clinical parameters between and within the three CSCR subtypes, related to the clinical heterogeneity of the disease.

To summarize, treatment by eplerenone or spironolactone for the management of long-standing CSCR seemed to be beneficial and well-tolerated when carefully monitored in real-life conditions, with half of the patients with nonresolving foveal subretinal fluid showing a complete resolution 6 months after treatment initiation. This study also demonstrated the relevance of a clinical classification of CSCR cases for future therapeutic trials and the different treatment responses according to these clinical phenotypes. Further prospective, controlled studies are needed to evaluate appropriate doses and durations of oral MR-antagonists in nonresolving CSCR.

Acknowledgments

This study was supported by the Swiss National Fund (156401), the Agence Nationale de la Recherche

(ANR-11-BSV1-0022) and the Fondation pour la Recherche Médicale (DVS20131228894).

*Alejandra Daruich and Alexandre Matet have contributed equally to this work.

Disclosure: **A. Daruich**, None; **A. Matet**, None; **A. Dirani**, None; **M. Gallice**, None; **L. Nicholson**, None; **S. Sivaprasad**, None; **F. Behar-Cohen**, (P)

References

1. Yannuzzi LA. Central serous chorioretinopathy: a personal perspective. *Am J Ophthalmol.* 2010; 149:361–363.
2. Yannuzzi LA, Slakter JS, Kaufman SR, Gupta K. Laser treatment of diffuse retinal pigment epitheliopathy. *Eur J Ophthalmol.* 1992;2:103–114.
3. Piccolino FC, De La Longrais RR, Manea M, Cicinelli S. Posterior cystoid retinal degeneration in central serous chorioretinopathy. *Retina.* 2008; 28:1008–1012.
4. Ooto S, Hangai M, Sakamoto A, et al. High-resolution imaging of resolved central serous chorioretinopathy using adaptive optics scanning laser ophthalmoscopy. *Ophthalmology.* 2010;117: 1800–1809.

5. Piccolino FC, de la Longrais RR, Ravera G, et al. The foveal photoreceptor layer and visual acuity loss in central serous chorioretinopathy. *Am J Ophthalmol*. 2005;139:87–99.
6. Nicholson B, Noble J, Forooghian F, Meyerle C. Central serous chorioretinopathy: update on pathophysiology and treatment. *Surv Ophthalmol*. 2013;58:103–126.
7. Karim SP, Adelman RA. Profile of verteporfin and its potential for the treatment of central serous chorioretinopathy. *Clin Ophthalmol*. 2013;7:1867–1875.
8. Chan W-M, Lai TYY, Lai RYK, Liu DTL, Lam DSC. Half-dose verteporfin photodynamic therapy for acute central serous chorioretinopathy: one-year results of a randomized controlled trial. *Ophthalmology*. 2008;115:1756–1765.
9. Robertson DM, Ilstrup D. Direct, indirect, and sham laser photocoagulation in the management of central serous chorioretinopathy. *Am J Ophthalmol*. 1983;95:457–466.
10. Zhao M, Célérier I, Bousquet E, et al. Mineralocorticoid receptor is involved in rat and human ocular chorioretinopathy. *J Clin Invest*. 2012;122:2672–2679.
11. Daruich A, Matet A, Dirani A, et al. Central serous chorioretinopathy: recent findings and new physiopathology hypothesis. *Prog Retin Eye Res*. 2015;48:82–115.
12. Bousquet E, Beydoun T, Zhao M, Hassan L, Offret O, Behar-Cohen F. Mineralocorticoid receptor antagonism in the treatment of chronic central serous chorioretinopathy: a pilot study. *Retina*. 2013;33:2096–2102.
13. Herold TR, Prause K, Wolf A, Mayer WJ, Ulbig MW. Spironolactone in the treatment of central serous chorioretinopathy - a case series. *Graefes Arch Clin Exp Ophthalmol*. 2014;52:1985–1991.
14. Singh RP, Sears JE, Bedi R, Schachat AP, Ehlers JP, Kaiser PK. Oral eplerenone for the management of chronic central serous chorioretinopathy. *Int J Ophthalmol*. 2015;8:310–314.
15. Bousquet E, Beydoun T, Rothschild P-R, et al. Spironolactone for nonresolving central serous chorioretinopathy: a randomized controlled crossover study. *Retina*. 2015;35:2505–2515.
16. Spaide RF, Campeas L, Haas A, et al. Central serous chorioretinopathy in younger and older adults. *Ophthalmology*. 1996;103:2070–2079. discussion 2079–2080.
17. Swissmedic. Available at: <http://www.swissmedicinfo.ch>. Accessed 12 July 2015.
18. Electronic Medicines Compendium. Available at <http://www.medicines.org.uk>. Accessed 12 July 2015.
19. Eschalier R, McMurray JJV, Swedberg K, et al. Safety and efficacy of eplerenone in patients at high risk for hyperkalemia and/or worsening renal function: analyses of the EMPHASIS-HF study subgroups (eplerenone in mild patients hospitalization and survival study in heart failure). *J Am Coll Cardiol*. 2013;62:1585–1593.
20. Spaide RF, Hall L, Haas A, et al. Indocyanine green videoangiography of older patients with central serous chorioretinopathy. *Retina*. 1996;16:203–213.
21. Imamura Y, Fujiwara T, Margolis R, Spaide RF. Enhanced depth imaging optical coherence tomography of the choroid in central serous chorioretinopathy. *Retina*. 2009;29:1469–1473.
22. Yang L, Jonas JB, Wei W. Optical coherence tomography-assisted enhanced depth imaging of central serous chorioretinopathy. *Invest Ophthalmol Vis Sci*. 2013;54:4659–4665.
23. Zhao M, Valamanesh F, Celerier I, et al. The neuroretina is a novel mineralocorticoid target: aldosterone up-regulates ion and water channels in Müller glial cells. *FASEB J*. 2010;24:3405–3415.
24. Kolkhof P, Borden SA. Molecular pharmacology of the mineralocorticoid receptor: prospects for novel therapeutics. *Mol Cell Endocrinol*. 2012;350:310–317.
25. Kang NH, Kim YT. Change in subfoveal choroidal thickness in central serous chorioretinopathy following spontaneous resolution and low-fluence photodynamic therapy. *Eye Lond Engl*. 2013;27:387–391.
26. Kim DY, Joe SG, Yang HS, Lee JY, Kim J-G, Yoon YH. Subfoveal choroidal thickness changes in treated idiopathic central serous chorioretinopathy and their association with recurrence. *Retina*. 2015;35:1867–1874.