



Murdoch
UNIVERSITY

MURDOCH RESEARCH REPOSITORY

This is the author's final version of the work, as accepted for publication following peer review but without the publisher's layout or pagination.

The definitive version is available at

<http://dx.doi.org/10.1080/00480169.2015.1063468>

Le Souëf, A.T., Barry, M., Brunton, D.H., Jakob-Hoff, R. and Jackson, B. (2015) Ovariectomy as treatment for ovarian bacterial granulomas in a Duvaucel's gecko (*Hoplodactylus duvaucelii*). *New Zealand Veterinary Journal*, 63 (6). pp. 340-344.

<http://researchrepository.murdoch.edu.au/27810/>

Copyright: © 2015 New Zealand Veterinary Association.


It is posted here for your personal use. No further distribution is permitted.

This article was downloaded by: [Murdoch University Library]

On: 26 June 2015, At: 01:13

Publisher: Taylor & Francis

Informa Ltd Registered in England and Wales Registered Number: 1072954 Registered office: Mortimer House, 37-41 Mortimer Street, London W1T 3JH, UK



New Zealand Veterinary Journal

Publication details, including instructions for authors and subscription information:
<http://www.tandfonline.com/loi/tnzv20>

Ovariectomy as treatment for ovarian bacterial granulomas in a Duvaucel's gecko (*Hoplodactylus duvaucelii*)

AT Le Souëf^{ac}, M Barry^b, DH Brunton^b, R Jakob-Hoff^a & B Jackson^{ac}

^a New Zealand Centre for Conservation Medicine, Auckland Zoo, Motions Road, Western Springs Auckland 1022, New Zealand

^b Institute of Natural and Mathematical Sciences, Massey University Albany, Private Bag 102-904, Albany, Auckland 0745, New Zealand

^c Current address: Conservation Medicine Program, School of Veterinary and Life Sciences, Murdoch University, South Street, Murdoch, Western Australia

Accepted author version posted online: 18 Jun 2015.



[Click for updates](#)

To cite this article: AT Le Souëf, M Barry, DH Brunton, R Jakob-Hoff & B Jackson (2015): Ovariectomy as treatment for ovarian bacterial granulomas in a Duvaucel's gecko (*Hoplodactylus duvaucelii*), *New Zealand Veterinary Journal*, DOI: [10.1080/00480169.2015.1063468](https://doi.org/10.1080/00480169.2015.1063468)

To link to this article: <http://dx.doi.org/10.1080/00480169.2015.1063468>

Disclaimer: This is a version of an unedited manuscript that has been accepted for publication. As a service to authors and researchers we are providing this version of the accepted manuscript (AM). Copyediting, typesetting, and review of the resulting proof will be undertaken on this manuscript before final publication of the Version of Record (VoR). During production and pre-press, errors may be discovered which could affect the content, and all legal disclaimers that apply to the journal relate to this version also.

PLEASE SCROLL DOWN FOR ARTICLE

Taylor & Francis makes every effort to ensure the accuracy of all the information (the "Content") contained in the publications on our platform. However, Taylor & Francis, our agents, and our licensors make no representations or warranties whatsoever as to the accuracy, completeness, or suitability for any purpose of the Content. Any opinions and views expressed in this publication are the opinions and views of the authors, and are not the views of or endorsed by Taylor & Francis. The accuracy of the Content should not be relied upon and should be independently verified with primary sources of information. Taylor and Francis shall not be liable for any losses, actions, claims, proceedings, demands, costs, expenses, damages, and other liabilities whatsoever or howsoever caused arising directly or indirectly in connection with, in relation to or arising out of the use of the Content.

This article may be used for research, teaching, and private study purposes. Any substantial or systematic reproduction, redistribution, reselling, loan, sub-licensing, systematic supply, or distribution in any form to anyone is expressly forbidden. Terms & Conditions of access and use can be found at <http://www.tandfonline.com/page/terms-and-conditions>

Publisher: Taylor & Francis & New Zealand Veterinary Association

Journal: *New Zealand Veterinary Journal*

DOI: 10.1080/00480169.2015.1063468

Clinical Communication

**Ovariectomy as treatment for ovarian bacterial granulomas in a
Duvaucel's gecko (*Hoplodactylus duvaucelii*)**

AT Le Souëf*^{‡§}, M Barry[†], DH Brunton[†], R Jakob-Hoff* and B Jackson*[‡]

*New Zealand Centre for Conservation Medicine, Auckland Zoo, Motions Road, Western Springs
Auckland 1022, New Zealand

[†]Institute of Natural and Mathematical Sciences, Massey University Albany, Private Bag 102-904,
Albany, Auckland 0745, New Zealand

[‡]Current address: Conservation Medicine Program, School of Veterinary and Life Sciences,
Murdoch University, South Street, Murdoch, Western Australia

[§]Author for correspondence. Email: A.LeSouef@murdoch.edu.au

Abstract

CASE HISTORY: An adult female Duvaucel's gecko (*Hoplodactylus duvaucelii*) from a threatened species breeding programme presented due to a prolonged gestation period and distended abdomen.

CLINICAL AND PATHOLOGICAL FINDINGS: The gecko was in lean body condition with an irregularly-shaped, firm mass in the coelomic cavity. Radiographically there was a diffuse radio-opacity within the coelomic cavity with cranial displacement of the right lung field.

Ultrasonography revealed a round homogenous abdominal mass of medium echogenicity with an echogenic capsule. Haematology showed a leucocytosis with a moderate left shift in heterophils and toxic changes. Bilateral ovariectomy was performed to remove two ovarian granulomas and *Salmonella enterica* subspecies *houtenae* (IV) was cultured from the ovarian tissue. The gecko recovered well from the surgery, regained weight and remained in good health 3 years following the surgery.

DIAGNOSIS: Pre-ovulatory stasis and ovarian granulomas associated with infection with *Salmonella enterica* subsp. *houtenae*.

CLINICAL RELEVANCE: The surgery described in this case resulted in recovery of the gecko, which despite its loss of reproductive capability is of value as an education animal. This is the first report of pre-ovulatory stasis and ovarian granulomas associated with infection with *Salmonella enterica* in a Duvaucel's gecko and is also the first reported case of pre-ovulatory stasis in a

viviparous lizard species. The case adds to knowledge regarding potential reproductive pathology in lizards, which is particularly important information for managers of captive lizard breeding programmes.

KEYWORDS: *Duvaucel's gecko*, *Hoplodactylus duvaucelii*, *ovariectomy*, *pre-ovulatory stasis*, *ovarian granuloma*, *Salmonella enterica*

MURF Massey University Reptile Facility

Introduction

Duvaucel's gecko (*Hoplodactylus duvaucelii*) is a native New Zealand lizard with a lifespan of at least 50 years (Wilson 2010) and a viviparous mode of reproduction. In the wild, female Duvaucel's geckos probably breed annually or biannually, with gestation periods of 8 months or more (Barwick 1982; Cree 1994). The mating season occurs in spring (September–November) and females usually give birth to one or two young in late summer or autumn (February–May; Barwick 1982).

Anthropogenic habitat modification and the introduction of small non-native predatory mammals caused severe range contractions and the extirpation of Duvaucel's geckos from mainland New Zealand (Towns and Daugherty 1994). The species is currently listed as at risk–relict in the New Zealand Department of Conservation threat classification system (Hitchmough *et al.* 2013). In recent years, Duvaucel's geckos have been reintroduced to pest-free island habitats within their former range as part of ecological restoration initiatives, to help improve their conservation status. Furthermore, a captive breed-for-release programme with 30 wild-caught adult Duvaucel's geckos (21 females, nine males) from Korapuki Island (part of the Mercury Islands group off the northeast coast of New Zealand's North Island) was established at the Massey University Reptile Facility (MURF) in Auckland in 2006.

Pre-ovulatory stasis occurs when a lizard undergoes vitellogenesis (yolk deposition) and mature follicle development but fails to ovulate. The condition has been reported in oviparous species, but not in viviparous species (Melidone *et al.* 2008). This paper presents the first report of pre-ovulatory stasis in a Duvaucel's gecko and contributes to existing knowledge of reproductive medicine in lizards which may be useful for reptile veterinarians or managers of lizard breeding programmes.

Case history

After collection from the wild as a gravid adult of unknown age in 2006, a female Duvaucel's gecko was housed at MURF in a naturalistic outdoor enclosure with one male and up to three other breeding females. The diet consisted of a puree of fruit, water, honey, Wombaroo Reptile Supplement (Wombaroo Food Products, Adelaide, SA, Australia) and vitamin powder, given once weekly in winter and twice weekly in summer. Live invertebrates were provided when available, and calcium-fed *Tenebrio* beetles or mealworms were given fortnightly. The diet had a Ca:P ratio of 1.2:0.8 and a vitamin D₃ concentration of 1.34 IU/g. Between 2007 and 2011, the female produced one to two healthy offspring annually, and did not exhibit any signs of ill health prior to January 2012. During February 2012, the gecko displayed normal basking behaviours and appetite but was not seen to defecate. In March 2012, the gecko was presented to the New Zealand Centre for Conservation Medicine at Auckland Zoo due to a prolonged gestation period and distended, firm abdomen.

Clinical findings and treatment

On initial examination under manual restraint, the gecko was alert and in lean body condition (based on epaxial muscle condition). It weighed 65 g with a snout-vent length of 126.5 mm. On palpation, there was an irregularly-shaped, firm mass occupying and distending the mid- to caudal coelomic cavity. Radiography and ultrasonography were performed with the gecko under manual restraint to minimise the invasiveness of diagnostic tests in a potentially compromised animal. Only dorso-ventral views taken, as positioning for lateral radiographic views in lizards usually requires chemical sedation. Radiological findings included a diffuse radio-opacity in the mid- to caudal coelomic cavity and cranial displacement of the right lung field (Figure 1). Ultrasonography revealed a round, homogenous coelomic mass of medium echogenicity with a small amount of surrounding fluid and an echogenic capsule. Blood was drawn from the ventral tail vein into a heparinised syringe, a fresh blood smear was stained with Leishman's stain and a white cell count was estimated from the smear (Table 1). There was a marked leucocytosis and a moderate left shift in heterophils with toxic changes including cytoplasmic basophilia and vacuolation, indicating severe acute inflammation.

Ceftazidime (20 mg/kg; Fortum Injection; GlaxoSmithKline, Boronia, VIC, Australia) was administered I/M in the forelimb and 1.5 mL 0.9% sodium chloride was administered S/C in the lateral body wall. The gecko was housed in a terrarium at 21°C without access to food or water overnight.

Based on the physical examination, radiographs, ultrasound and haematology, an exploratory coeliotomy was performed the following day. The gecko was induced for general anaesthesia using

5 mg/kg alfaxalone (Alfaxan Anaesthetic Injection; Jurox, Rutherford, NSW, Australia) administered I/M in the forelimb. After 20 minutes, moderate sedation was achieved, however breath holding occurred when mask induction was attempted therefore an additional 1.6 mg/kg alfaxalone was administered I/M. This facilitated intubation with an 18 gauge I/V catheter, after which general anaesthesia was maintained using isoflurane and oxygen via an artificial ventilator (Small Animal Ventilator; BASi Vetronics, West Lafayette, Indiana, USA) to deliver intermittent positive pressure ventilation.

A paramedian surgical incision was made through the skin and abdominal musculature. The large abdominal vein was readily visible directly beneath the skin, and was moved laterally out of the surgical field using a moistened sterile cotton bud. A large, pale, well-vascularised intra-coelomic mass (32.5 mm x 27 mm, weight 10.2 g) was exteriorised (Figure 2) using sterile cotton buds, and one small blood vessel on its lateral aspect was ligated with 5/0 polyglycolic acid braided absorbable suture (Polysyn; SVS, Auckland, NZ) for removal of the mass. Surrounding attachments and fimbria were bluntly dissected and the mass was resected. A second smaller, smoothly shaped round yellow mass (15 mm diameter, weight 1.55 g) with few surrounding attachments was bluntly dissected out of the right cranial abdomen using sterile cotton buds. The coelomic cavity was flushed with warmed sterile saline, before the muscle incision was closed with the same absorbable suture using a continuous pattern. The skin incision was closed using an everting horizontal mattress suture pattern with 5/0 Polysyn. Prior to recovery, 1 mg/kg butorphanol (Torbugesic; Zoetis, Auckland, NZ) was administered I/M in the forelimb and 0.2 mg/kg meloxicam (diluted 1:10 with water for injection; Metacam; Boehringer Ingelheim, North Ryde, NSW, Australia) and 1.5 mL 0.9% sodium chloride were administered S/C in the lateral body wall. The gecko continued to receive meloxicam and 0.9% sodium chloride every 48 hours for 6 days, butorphanol I/M once daily for 6 days and ceftazidime I/M every 72 hours for 14 days, at the above doses. A smooth recovery from anaesthesia was observed and the gecko was bright and active several hours later. Immediately following surgery, the gecko weighed 54 g.

The sutures in the healed surgical wound were removed 39 days following surgery, after the gecko's next skin slough. The gecko had a good appetite and bright demeanour at the time and its weight had increased to 60 g. Radiographically, although there was still increased radio-opacity in the caudal right lung, the size of this lung field had increased since before the ovariectomy (Figure 3). Three years following surgery, the gecko remained healthy in appearance, displayed normal basking behaviours and appetite and weighed 73 g. It is used as an education and advocacy animal.

Histopathology and microbiology

The two intra-coelomic masses were submitted for histopathology. The tissue was fixed in 10% buffered formalin then processed as a batch in paraffin. Sections were cut at 4 µm, and stained with H&E and Gram stains. Histopathology was similar for the two lesions: the intra-coelomic masses were chronic-active yolk granulomas, composed of a central egg yolk surrounded by a thick band of heterophils and epithelioid macrophages admixed with moderate numbers of Gram-negative bacilli bacteria. Tissue from the masses was also submitted for aerobic and anaerobic culture, which resulted in a heavy growth of *Salmonella* spp. These were then serotyped and phage typed as *Salmonella enterica* subspecies *houtenae* (IV) ser.43:z4, z23. Subsequently single cloacal swabs were taken from 90 Duvaucel's geckos in the MURF group and sent for culture; one sample from an asymptomatic female from a different enclosure to the dystocic gecko was positive for *Salmonella enterica* subspecies *houtenae* (IV) ser.43:z4, z23.

Discussion

The Duvaucel's gecko in this case report was diagnosed with ovarian granulomas associated with infection with *Salmonella enterica* subsp. *houtenae*. In a previous study, examination of 58 Duvaucel's gecko female reproductive tracts revealed that ovarian follicles grow to a maximum length of approximately 19 mm during the period of vitellogenesis, which lasts from March through to October (Cree 1994). This suggests that one of the ovarian masses removed from the gecko in this report was substantially enlarged at 32.5 mm, probably as a result of granulomatous reaction and coalescence of the ova, which occurs as a result of chronic pre-ovulatory stasis and ovarian deterioration (Mader *et al.* 2006). Both ovaries removed were likely to be static in their development as, at the time of presentation (March), the gecko should have been displaying either early vitellogenesis with small ovaries, or late gestation with a fully developed fetus. It is therefore likely that the follicular development had not progressed from vitellogenesis to ovulation during the previous year.

Pre-ovulatory stasis may be caused by inappropriate nutrition, environmental conditions or lack of nesting substrate (Barten 2005; Sykes 2010). The condition has been commonly reported in oviparous species, but not previously in viviparous species (Backues and Ramsay 1994; Melidone *et al.* 2008; Scheelings 2008; Gardner and Barrows 2010). Whether this is due to the lower number of species with the latter mode of reproduction, which makes up only 20% of all lizard species (Pough *et al.* 2001), or due to a lower overall prevalence of the condition in viviparous species is not known. Clinical signs may include anorexia, lethargy, coelomic distension and dyspnoea due to the effect of the space-occupying lesion (Barten 2005; Mader *et al.* 2006; Stacy *et al.* 2008). As in the current case, diagnosis of pre-ovulatory stasis can be made using ultrasonography or

radiography, which may show a space-occupying mass in the mid- to caudal coelom, and haematology to assess for underlying or concurrent conditions, such as metabolic abnormalities or infection (Sykes 2010). Resorption of the vitellogenic follicles in lizards with pre-ovulatory stasis can occur, but potentially fatal yolk coelomitis is a common consequence when ova become friable and rupture (Stacy *et al.* 2008), therefore surgical ovariectomy is recommended for lizards with pre-ovulatory stasis (Rivera 2008; Gardner and Barrows 2010).

Salmonella enterica subspecies *houtenae* (IV) ser.43:z4, z23, identified from the ovarian granuloma tissue in this gecko, is an uncommon serovar in New Zealand that has been isolated from Duvaucel's geckos on Korapuki Island (Middleton *et al.* 2010). The MURF group (n = 30) had tested negative on one cloacal swab following collection from the wild, although generally at least three swabs are required to rule out *Salmonella* spp. infection. The initial source of *Salmonella* serovars in wild New Zealand lizards is unknown, but may have been spread by human activities (Middleton *et al.* 2010). The route by which this gecko's ovaries became infected, and the relevance of the infection to the aetiology of the pre-ovulatory stasis remains undetermined. Culture of microorganisms in retained ova of reptiles is common and whether the organisms cause the retained ova or vice versa is usually unknown (DeNardo 2006), however *Salmonella* spp. are generally regarded as secondary opportunistic organisms in reptiles (Chiodini 1982). If the pre-ovulatory stasis occurred as a primary condition, with subsequent deterioration of the ovarian tissue coupled with systemic stress caused by the condition, the ovarian granulomas more likely resulted from secondary opportunistic rather than primary infection. *Salmonella* spp. have been isolated from the reproductive tract of wild lizards, suggesting that transovarian transmission probably occurs naturally in individuals, but it is thought that this mainly occurs in individuals under adverse conditions such as stress (Kourany and Telford 1982).

Female reptile reproductive cycles can be affected by many different variables including environmental cues such as temperature and humidity (Licht 1972; Summers 1988), altitude (Gorman and Licht 1974), hibernation (Gavaud 2005), the presence of a male (Crews *et al.* 1986), the act of copulation (Mendonça and Crews 1990), stress (Summers *et al.* 1995) and the nutritional status and body condition of the specific individual (Jones *et al.* 1987). Dystocias are more common in captive than free-ranging lizards, presumably because captivity alters the balance between the environment and physiology (DeNardo 2006). If pre-ovulatory stasis was the primary condition in this gecko, with the infection occurring secondarily, there are no obvious factors involved in its development. There had been no recent changes in the husbandry of the breeding group and this gecko had bred successfully for 4 years prior to presentation and was otherwise in apparent good health. Although the diet composition of wild Duvaucel's geckos is not fully known, the Ca:P ratio

and vitamin D₃ concentration of the MURF gecko diet was within the recommended ranges for reptiles (Donoghue 2006).

The chronic effect of the disease on the gecko's body condition, and the gecko's initial body condition index is difficult to state due to the weight of the inspissated ova. The post-surgical body mass (54 g) was lighter than previous post-partum weights in this individual (60–70 g) but this body mass may also reflect the loss of organs after the ovariectomy. However, the presence of granuloma formation within the enlarged ova and the acute severe leucocytosis with toxic haematological changes does suggest that this gecko would not have survived without surgical intervention. Although there was no evidence of follicle rupture or yolk peritonitis, there was haematological evidence of inflammation, likely as a result of the granulomas; also rupture was a risk given the friable nature of the ovarian masses removed in this case. It is therefore probable that surgery prolonged the life span of this individual, which, despite the resulting loss of reproductive capability, could still fulfil a valuable conservation role as an advocacy and display animal.

This is the first report of pre-ovulatory stasis and ovarian granuloma formation in a Duvaucel's gecko and, to our knowledge, the first report of this condition in a viviparous lizard species. This case expands the current knowledge of potential reproductive conditions that may be seen in threatened lizards, including viviparous species. Managers of captive lizard breeding groups should be aware of this condition and of the factors which may predispose individuals to reproductive pathology, such as inappropriate environmental conditions, stress, nutrition and improper body condition. Careful control of these factors may lead to better reproductive success and therefore potentially improve the outcomes of conservation programmes involving captive breeding. Finally, although conclusions cannot be drawn as to the significance or pathophysiology of the infection with *Salmonella enterica* subspecies *houtenae* (IV), this case also highlights the importance of ongoing surveillance and identification of *Salmonella* spp. strain types in captive and wild reptiles, to guide assessment of disease risks for translocation and reintroduction programmes.

Acknowledgements

The authors are grateful to C. Harvey for comments on the manuscript relating to clinical pathology.

References

- ***Barwick R.** The growth and ecology of the gecko *Hoplodactylus duvaucelii* at The Brothers Islands. In: Newman D (ed). *New Zealand herpetology: proceedings of a symposium held at Wellington 29-31 January 1980*. Pp 377–91. New Zealand Wildlife Service, New Zealand, 1982
- Backues K, Ramsay E.** Ovariectomy for treatment of follicular stasis in lizards. *Journal of Zoo and Wildlife Medicine* 25, 111–6, 1994
- ***Barten S.** Lizards. In: Mader D (ed). *Reptile Medicine and Surgery, 2nd Edition*. p 690. Saunders Elsevier, St Louis, USA, 2005
- Chiodini RJ.** Transovarian passage, visceral distribution, and pathogenicity of *Salmonella* in snakes. *Infection and Immunity* 36, 710–3, 1982
- Cree A.** Low annual reproductive output in female reptiles from New Zealand. *New Zealand Journal of Zoology* 21, 351–72, 1994
- Crews D, Grassman M, Lindzey J.** Behavioral facilitation of reproduction in sexual and unisexual whiptail lizards. *Proceedings of the National Academy of Sciences* 83, 9547–50, 1986
- ***DeNardo D.** Dystocias. In: Mader D (ed). *Reptile Medicine and Surgery, 2nd Edition*. Pp 787–92. Saunders Elsevier, St Louis, USA, 2006
- ***Donoghue S.** Nutrition. In: Mader D (ed). *Reptile Medicine and Surgery, 2nd Edition*. p 287. Saunders Elsevier, St Louis, USA, 2006
- Gardner B, Barrows M.** Yolk coelomitis in a white-throated monitor lizard (*Varanus albigularis*). *Journal of the South African Veterinary Association* 81, 121–2, 2010
- Gavaud J.** Obligatory hibernation for completion of vitellogenesis in the lizard *Lacerta vivipara* J. *Journal of Experimental Zoology* 225, 397–405, 2005
- Gorman G, Licht P.** Seasonality in ovarian cycles among tropical Anolis lizards. *Ecology* 55, 360–9, 1974
- ***Hitchmough R, Anderson P, Barr B, Monks J, Lettink M, Reardon J, Tocher M, Whitaker T.** *Conservation status of New Zealand reptiles, 2012*. New Zealand Threat Classification Series 2 <http://www.doc.govt.nz/Documents/science-and-technical/nzctcs2entire.pdf> (accessed 10 June 2015). Department of Conservation, Wellington, NZ, 2013

- Jones S, Ballinger R, Porter W.** Physiological and environmental sources of variation in reproduction: prairie lizards in a food rich environment. *Oikos* 48, 325–35, 1987
- Kourany M, Telford S.** *Salmonella* and *Arizona* infections of alimentary and reproductive tracts of Panamanian lizards. *Infection and Immunity* 36, 432-4, 1982
- Licht P.** Environmental physiology of reptilian breeding cycles: role of temperature. *General and Comparative Endocrinology* 3, 477–88, 1972
- *Mader D, Bennett R, Funk R, Fitzgerald K, Vera R, Hernandez-Divers S.** Surgery. In: Mader D (ed). *Reptile Medicine and Surgery, 2nd Edition*. p 594. Saunders Elsevier, St Louis, USA, 2006
- Mayer J, Knoll J, Wrubel K, Mitchell M.** Characterizing the hematologic and plasma chemistry profiles of captive crested geckos (*Rhacodactylus ciliatus*). *Journal of Herpetological Medicine and Surgery* 21, 68–75, 2011
- Melidone R, Knoll J, Parry N.** Preovulatory stasis and dystocia in oviparous lizards. *Veterinary Medicine* 103, 595, 2008
- Mendonça M, Crews D.** Mating-induced ovarian recrudescence in the red-sided garter snake. *Journal of Comparative Physiology A* 166, 629–32, 1990
- Middleton D, Minot E, Gartrell B.** *Salmonella enterica* serovars in lizards of New Zealand's offshore islands. *New Zealand Journal of Ecology* 34, 247–52, 2010
- *Pough F, Andrews R, Cadle J, Crump M, Savitzky A, Wells K.** *Herpetology, 2nd edition*. Prentice Hall, New York, USA, 2001
- Rivera S.** Health assessment of the reptilian reproductive tract. *Journal of Exotic Pet Medicine* 17, 259–66, 2008
- Scheelings T.** Preovulatory stasis in a yellow-spotted monitor *Varanus panoptes panoptes*. *Journal of Herpetological Medicine and Surgery* 18, 18–20, 2008
- Stacy B, Howard L, Kinkhaid J, Vidal J, Papendick R.** Yolk coelomitis in Fiji Island banded iguanas (*Brachylophus fasciatus*). *Journal of Zoo and Wildlife Medicine* 39, 161–9, 2008
- Summers C.** Chronic low humidity-stress in the lizard *Anolis carolinensis*: Effects on ovarian and oviductal recrudescence. *Journal of Experimental Zoology* 248, 192–8, 1988

Summers C, Suedkamp D, Grant T. Regulation of ovarian recrudescence: Effects of social interaction and size on female lizards, *Anolis carolinensis*. *Journal of Experimental Zoology* 271, 235–41, 1995

Sykes J. Updates and practical approaches to reproductive disorders in reptiles. *Veterinary Clinics of North America: Exotic Animal Practice* 13, 349–73, 2010

Towns D, Daugherty C. Patterns of range contractions and extinctions in the New Zealand herpetofauna following human colonization. *New Zealand Journal of Zoology* 21, 325–39, 1994

***Wilson J.** Population viability and resource competition on North Brother Island: Conservation implications for tuatara (*Sphenodon punctatus*) and Duvaucel's gecko (*Hoplodactylus duvaucelii*). MSc thesis, Victoria University of Wellington, New Zealand, 2010

* Non-peer-reviewed

Submitted 13 October 2014

Accepted for publication 10 June 2015

First published online [insert date]

Table 1. Haematological values ($\times 10^9/L$) for a Duvaucel's gecko (*Hoplodactylus duvaucelii*) with pre-ovulatory stasis, with comparative reference values for crested gecko (*Rhacodactylus ciliatus*; n = 38) from Mayer *et al.* (2011).

Parameter	Duvaucel's gecko	Reference values ^a
Leukocytes	48.2	15.4 ± 7.1
Heterophils	11.6	0.35, 8.4
Lymphocytes	32.8	10.7 ± 5.1
Monocytes	2.4	0.35, 9.02
Basophils	1.4	0, 2
Eosinophils	0	0, 6

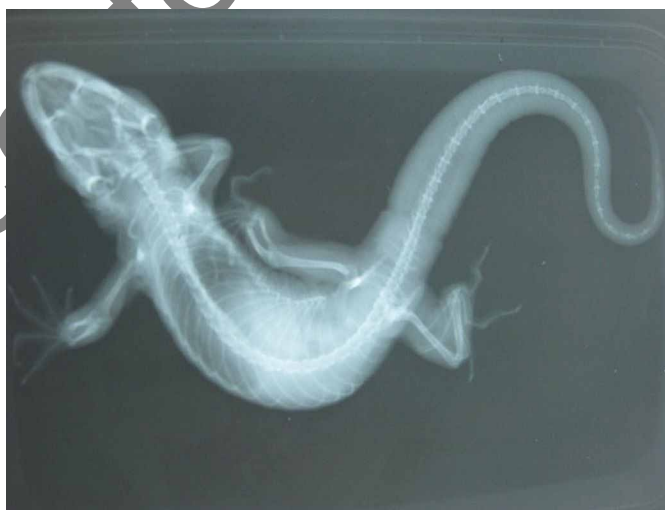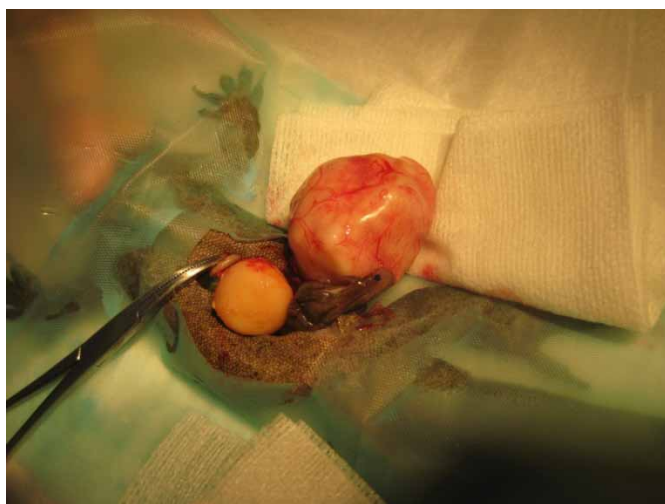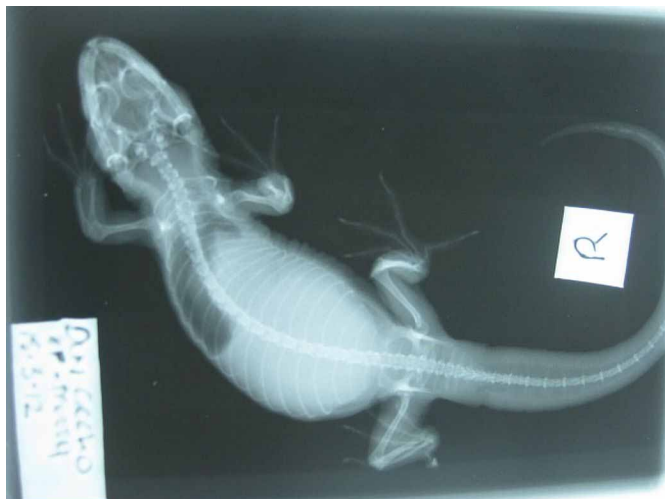^a Values are mean ± SD for parameters with a normal distribution, or minimum and maximum for parameters that were not normally distributed.

Figure 1. A dorso-ventral radiographic view of a Duvaucel's gecko (*Hoplodactylus duvaucelii*) upon presentation with abdominal distension, showing diffuse radio-opacity in the coelomic cavity and cranial displacement of the right lung field.

Figure 2. Photograph showing exteriorisation of ovarian granulomas prior to ovariectomy in a Duvaucel's gecko (*Hoplodactylus duvaucelii*).

Figure 3. A dorso-ventral radiographic view of a Duvaucel's gecko (*Hoplodactylus duvaucelii*) taken 39 days following ovariectomy to remove two ovarian granulomas, showing reduction of abdominal distension and intra-coelomic radio-opacity, and expansion of the right lung field compared to pre-surgical radiography.

Accepted Manuscript



Accepted Manuscript