

result in injury,² the consequences can be severe; death, long hospital admissions, painful operations, and permanent physical and mental scarring. The National Joint Utilities Group (Post Office Telecommunications, Electricity Supply Industry, British Gas, and the Water Industry) publish advisory booklets and also cards suitable for use at work sites; these recommend how to avoid underground electricity cables and give information on cable locating devices. Legislation to prevent injury from electricity cables is contained in the Construction (General Provisions) Regulations 1961, the Health and Safety at Work Act 1974, and the Electric Lighting (Clauses) Act 1899. It has however been stated that "apathy is the greatest single obstacle to progressive improvement" in safety and health at work (Robens Report, 1972³) and that more education rather than legislation is required.³

The experiences of our patients show the need for even more knowledge and understanding of the dangers of striking underground electricity cables.

I thank Mr D H Harrison for permitting me to report on patients under his care, and Mr A P Gifford of the Health and Safety Executive for the statistics and details of relevant legislation.

¹ Muir IFK. The treatment of electrical burns. *Br J Plast Surg* 1958;10:292-9.

² Shield D. Underground movement that costs £3,000,000 a year. *Tenders and Contracts Journal* 1978 Nov 20-1.

³ Hunter D. *The Diseases of Occupation*. 6th ed. London: Hodder and Stoughton, 1978:1088.

(Accepted 1 July 1981)

Mount Vernon Hospital, Northwood, Middlesex
M J TIMMONS, MA, FRCS, registrar in plastic surgery

Spinal cord degeneration in a case of "recovered" spinal decompression sickness

Degeneration in the spinal cord of goats after experimental decompression sickness is well documented^{1,2} but opportunities to examine the long-term effects in man are rare.³ We describe severe damage in the spinal cord of a man who had made an almost complete functional recovery from spinal decompression sickness.

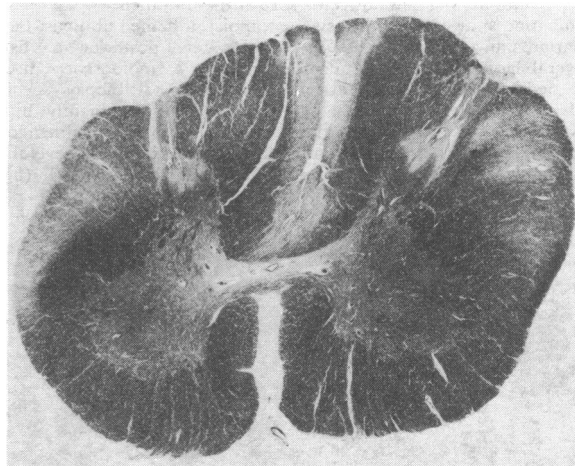
Case report

In June 1976 a 34-year-old scuba diver surfaced probably rather rapidly from about 110 feet (33.5 m), where he had remained for 20-25 minutes. Shortly afterwards he suffered pain and tightness in a girdle distribution around the mid-chest and had difficulty speaking and breathing. By the time of admission (11 am) symptoms had disappeared but he was nevertheless put into a pressure chamber, which was adjusted to 28 lb/in² (2 kg/cm²) gauge pressure. Ten minutes later he still had no complaints and began decompression over one and a half hours. That night his right thigh and foot became numb with some patchy loss of sensation to pinprick, and there was weakness in the left leg. He was repressurised to 30 lb/in² (2.1 kg/cm²). After two hours 20 minutes he improved; co-ordination, sensation, and reflexes were recorded as normal. He was then decompressed on an oxygen table (US Navy, 6; Royal Navy, 6B). At the time there was only indefinite weakness in the left leg and a slightly abnormal gait. The paraparesis improved gradually over about three weeks.

In January 1980 the patient was re-examined neurologically. He felt no fatigue after exercise but during cold weather his legs tended to shake when standing. No evidence of mental impairment was found and cranial nerve functions were normal apart from brisk snout and palmental reflexes. Muscle power, tone, and co-ordination were normal in all limbs but deep tendon reflexes in the legs were abnormally brisk, with sustained clonus at the ankles and knees and bilateral extensor plantar responses. Reflexes in the arms were also brisk but within normal limits. Superficial abdominal reflexes were present. The left cremasteric reflex was less active than the right. Sensory testing showed only slight impairment of joint position sense at the toes. It was concluded that there was evidence of residual corticospinal tract damage and perhaps some higher involvement, because of the unexpectedly

active primitive facial reflexes. Twelve days later he met with a violent death not connected with diving.

Neuropathological changes were confined to the spinal cord. Between C1 and T4 there was bilateral degeneration of the fasciculus gracilis, the subspinal myelin often being spared (figure). The lateral funiculi were also affected between C1 and L4, the most severe damage being between C6 and T10, where the lateral corticospinal tracts and spinocerebellar tracts were principally affected. Between C1 and C6 this degeneration was confined to the dorsal spinocerebellar tracts, decreasing in severity at the rostral levels. Degeneration in the ventral columns was present between T3 and T5; this was more prominent on the left side and affected the deep fibres. Overall focal damage was most severe between C7 and T4, where there were changes compatible with a past ischaemic episode.



Spinal cord at C5 showing degeneration of fasciculus gracilis and lateral funiculi. Methasol fast blue $\times 10$ (original magnification).

Comment

The distribution of lesions was similar to that reported in other cases of spinal decompression sickness. Haymaker³ described symmetrical softening and later sclerosis of the dorsal and lateral columns, particularly in the thoracic cord. In our patient tract degeneration may have stemmed from an area of infarction between C7 and T4. In view of the extent of the damage it was remarkable that he had made such a good recovery.

This case poses major questions concerning the definition of clinical recovery from spinal decompression sickness and the advice that should be given about subsequent diving activities. Neurophysiological tests would perhaps be more likely to disclose functional derangement than the more routine neurological assessment.

We thank Professor A Usher for helpful co-operation and Dr C S Treip for advice.

¹ Palmer AC, Blakemore WF, Greenwood AG. Neuropathology of experimental decompression sickness (dysbarism) in the goat. *Neuropathol Appl Neurobiol* 1976;2:145-56.

² Palmer AC, Blakemore WF, Payne JE, Sillence A. Decompression sickness in the goat; nature of brain and spinal cord lesions at 48 hours. *Undersea Biomed Res* 1978;5:275-86.

³ Haymaker W. Decompression sickness. In: Lubarsch O, Henke F, Rössle R, eds. *Handbuch der speziellen pathologischen Anatomie und Histologie*. Berlin: Springer-Verlag, 1957:1600-72.

(Accepted 9 June 1981)

Department of Clinical Veterinary Medicine, University of Cambridge, Cambridge CB3 0ES

A C PALMER, SCD, FRCVS, assistant director of research

Department of Morbid Anatomy, London Hospital Medical College, London E1 1BB

I M CALDER, MD, honorary lecturer

University Department of Industrial Health, Newcastle upon Tyne
R I McCALLUM, MD, DSC, reader in industrial health

Department of Medicine, University of Western Australia
F L MASTAGLIA, MD, FRACP, associate professor of neurology