



## Case of the Month

### Ehrlichiosis...in Hawaii? An Unusual Presentation

**Matthew G. Weeks, MD, CPT, MC, USA**  
Department of Family Practice  
Tripler Army Medical Center  
Honolulu, Hawaii

Tick-borne disease like Rocky Mountain Spotted Fever, tularemia, and relapsing fever, have long been recognized but have been joined in the past two decades by newly described diseases such as Lyme disease, babesiosis, and ehrlichiosis. The first case of human ehrlichiosis in the western hemisphere was recorded in 1986.<sup>1</sup> Human ehrlichiosis is a geographically diverse tick-borne disease that has two pathologically distinct but clinically similar forms. Human monocytic ehrlichiosis (HME) and human granulocytic ehrlichiosis (HGE) have been reported in 32 states on the U.S. mainland, Western Europe, Scandinavia, and Africa.<sup>2</sup> Indigenous and introduced species of ticks may be found in Hawaii, but none have been implicated as vectors for ehrlichiosis or other human pathogens. The incubation period for ehrlichiosis ranges from 0-34 days, but symptoms generally occur one week after tick exposure. If untreated, ehrlichiosis can lead to multi-organ failure and death. The following case illustrates that clinicians living in non endemic areas must obtain a remote history of a tick bite or travel into areas endemic for tick-borne illness.

#### Case Report

A previously healthy 29-year-old Hispanic male soldier presented to a military hospital in Hawaii with a two-week history of severe retro-orbital headaches, photophobia, intermittent fevers up to 103 degrees F, rigors, anorexia, nausea, and vomiting. The patient was treated for suspected sinusitis with Bactrim and reported no resolution of his symptoms. He was referred to an Otolaryngologist. Evaluation with nasopharyngolaryngoscopy and CT scans failed to reveal evidence of sinusitis.

This soldier was stationed at Schofield Barracks, Hawaii. His travel history included attendance at field exercises in Texas and Alaska, ten and six weeks prior to presentation, respectively. In Texas, he recalled a tick bite to his left groin.

His physical examination revealed a temperature of 101.8 degrees F, moderate distress secondary to headache, pain on extraocular movement, photophobia, and bilateral inguinal and axillary adenopathy. Pertinent negative findings included normal fundi, no rhinorrhea, no meningismus, and no focal neurological deficits.

Initial laboratory values were significant for elevated hepatic transaminases; AST-415 U/L, ALT-517 U/L, GGT-128 U/L, alkaline phosphatase 260 U/L, and total bilirubin level of 1.7 mg/dl. The patient was noted to have thrombocytopenia with a platelet level of  $94 \times 10^9/L$ . A normal WBC count of  $8.1 \times 10^9/L$ , hemoglobin of 15.3 g/dl, and hematocrit of 44.4%. A lumbar puncture was performed and spinal fluid analysis was normal with respect to glucose, protein, cell count, gram stain, and culture. Other pertinent

negative lab tests included serum chemistry, Lyme, Babesia, Rocky Mountain Spotted Fever, Leptospirosis, EBV, CMV, HIV, Hepatitis A/B/C, and Toxoplasmosis serologies.

The patient was empirically started on Doxycycline 100 mg po bid for 14 days. His symptoms and laboratory abnormalities resolved rapidly over the next two days and he had a full recovery. An admission serum titer was positive for *Ehrlichia chaffeensis* IgG at 1:256 and convalescent testing was not performed given the high acute titer and clinical criteria consistent with the diagnosis of Human Monocytic Ehrlichiosis.

#### Discussion

Ehrlichiae are obligate intracellular gram negative bacteria. *Ehrlichia chaffeensis* is the agent responsible for HME and a yet unnamed organism genetically similar to *Ehrlichia equi* and *Ehrlichia phagocytophilia* results in HGE.<sup>3,4,5</sup> The ticks responsible for transmission of HME are *Dermacentor variabilis* (Dog tick) and *Amblyomma americanum* (Lone Star tick). The organism responsible for HGE is also carried by *Dermacentor variabilis* as well as *Ixodes scapularis* (Deer tick).<sup>(2)</sup> Neither Hawaii nor Alaska have reported a case of HME or HGE, but both are endemic in Texas.

Human Ehrlichiosis is usually suspected on the basis of a history of a recent tick bite. The usual incubation period is one to thirty four days.<sup>(6)</sup> Common presenting symptoms include fever, rigors, malaise, myalgia, and headaches. Less frequently, one may see diaphoresis, cough, pharyngitis, lymphadenopathy, anorexia, nausea, vomiting, diarrhea, abdominal pain, arthralgias, mental confusion, or a non-specific rash. Other clinical features described include ARDS, toxic shock syndrome, myocardial involvement (e.g. left ventricular dilatation), brachial plexopathy, prolonged fever, hypotension, pharyngitis, and conjunctivitis.<sup>2</sup>

Laboratory findings most commonly seen include thrombocytopenia, lymphocytopenia, leukopenia, and elevated hepatic transaminase levels. Less frequent laboratory findings include anemia, elevated cerebrospinal fluid protein and pleocytosis, fibrin split products, hyponatremia, elevated ESR, elevated blood urea nitrogen and creatinine, elevated CPK and elevated bilirubin.<sup>2</sup> On a Wright stain of the peripheral smear there may be morulae (intracellular inclusions) seen in either monocytes or granulocytes.<sup>1</sup>

Complications of untreated Human Ehrlichiosis include severe cough with pulmonary infiltrates, gastrointestinal bleeding, gastroenteritis, meningitis, pericarditis, hepatitis with focal hepatic necrosis, renal failure, disseminated intravascular coagulopathy, opportunistic infections, and multi-organ failure.<sup>6</sup>

The emergence of ehrlichiosis has broadened the differential diagnosis of patients with "flu-like" symptoms. The clinical presentation mimics many infectious diseases, to include leptospirosis, mononucleosis, viral hepatitis, gastroenteritis, endocarditis, pneumonia, and meningoencephalitis. It also may resemble non infectious diseases, such as hematologic malignancies and collagen vascular diseases.

Ehrlichiosis should be considered in any febrile patient with exposure to ticks within the preceding three weeks, particularly if leukopenia, thrombocytopenia, or elevated hepatic transaminases are seen. However, as this case illustrates, prolonged incubation periods occur and clinicians must take this into account.

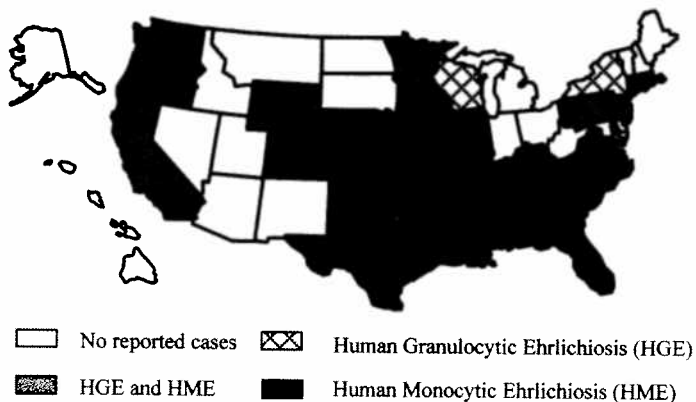
Currently the diagnosis of HME and HGE is made by a fourfold

rise or fall in immunofluorescent antibody (IFA) titer with a peak titer of 64 or greater in a clinically compatible case.<sup>7</sup> Observation of morulae in a blood smear or a buffy coat preparation is insensitive but should be pursued, as it can help establish the diagnosis immediately. Other diagnostic techniques include immunohistochemistry, and culture.<sup>2</sup> PCR primer sets have also been developed for the diagnosis of both HGE and HME.<sup>8</sup>

Doxycycline 100 mg po bid for 10-14 days is the treatment of choice.<sup>6,7</sup> For children, chloramphenicol is recommended but has been shown to be less effective.<sup>2</sup> Treatment should not be withheld pending laboratory confirmation, as delays in diagnosis may be associated with worse outcomes.

This case was unusual in that it either represents a prolonged incubation period if acquired in the endemic area of Texas, or a case of transmission of the disease occurring in Alaska or Hawaii – states where there have been no prior reported cases of ehrlichiosis. It is presumed that this most likely represents a prolonged incubation period based on the history of a tick bite in Texas. Although no endemic tick-borne disease is found in Hawaii, the increased recognition and prevalence of emerging tick-borne diseases worldwide will impact healthcare providers here. The differential diagnosis in the febrile traveler continues to expand and ehrlichiosis is yet another disease to be considered.

**Geographic Distribution of Human Ehrlichiosis 1986-1996**



#### References

1. Maeda K, Markowitz N, Hawley RC, et al. Human infection with *Ehrlichia canis*, a leukocytic rickettsia. *N Eng J Med* 316: 853-856, 1987.
2. Fritz CL, Glaser CA. Ehrlichiosis. *Infectious Disease Clinics of North America*. 1998, 12: 123-136.
3. Dawson JE, Anderson BE, Fishbein DB, et al. Isolation and characterization of an *Ehrlichia* sp. From a patient diagnosed with human ehrlichiosis. *J Clin Microbiol*. 29: 2741-2745, 1991.
4. Chen SM, Dumler JS, Bakken JS, et al. Identification of a granulocytotropic *Ehrlichia* species as the etiologic agent of human disease. *J Clin Microbiol*. 32: 589-595, 1994.
5. Madigan HE, Richter PJ, Kimsey RB, et al. Transmission and passage of horses of the agent of human granulocytic ehrlichiosis. *J Infect Dis*. 172: 1141-1144, 1995.
6. Eng TR, Harkess JR, Fishbein DB, et al. Epidemiologic, clinical and laboratory findings of human ehrlichiosis in the United States. 1988. *JAMA* 264: 2251-2258, 1990.
7. Centers for Disease Control and Prevention: Human ehrlichiosis - Maryland, 1994. *MMWR* 45: 798-802, 1996.
8. Everett ED, Evans KA, Henry RB, et al: Human ehrlichiosis in adults after tick exposure: Diagnosis using polymerase chain reaction. *Ann Intern Med* 120: 730-735, 1994.



## Letter to the Editor



Thomas J. Whelan, Jr., MD  
1921-1999

Sir:

Mrs. Norma Whelan, Dr. Thomas Whelan's wife, mailed my daughter, Sandra, and I copies of the Hawaii Medical Journal special memorial issue on Dr. Thomas J. Whelan, Jr. I have read each article written by his children and professional colleagues, but I saw nothing of his compassion for his patients and the patients family. His compassion is what I believe made him a great surgeon.

I met Dr. Whelan in August 1962 when he was chief of vascular surgery at Walter Reed Medical Center when my 7-year-old daughter, Sandra, had been referred to him with a large liver tumor. Dr. Whelan removed the tumor in a 12 hour complicated procedure that I later learned few surgeons in the United States were qualified to perform.

What really impressed my wife, Louise, and I was Dr. Whelan's compassion and concern for his patients and their family. He arranged accommodations for my wife and I at Walter Reed and spent hours with Sandra while she was in surgical intensive care. After Sandra's release from the hospital, she was followed for years by Dr. Whelan. While sitting in the doctor's office during follow up visits I've heard Dr. Whelan make telephone calls to arrange transportation to Washington, DC and accommodations near Walter Reed Medical Center while a family member was undergoing and recovering from a major surgical procedure. Mrs. Whelan told me that Doctor Whelan often made house calls. And over the ensuing years I remained in touch with Dr. Whelan and on my frequent visits to Hawaii a must for me was a call to a doctor.

My family and I are fortunate and honored to have met a man possessing so great a professional skill and so much concern for his patients and their families. I am fortunate to have met and know so wonderful a man. To my family he was special.

Sincerely,  
John Ireland