

Effect of organic turmeric (*Curcuma longa*) feeding on testicular histology of rabbits exposed to ultraviolet radiation

VICTOR ADEGBOYE TOGUN¹, OLAJIDE ABRAHAM AMAO², JONATHAN ADEBOWALE ADEBISI³, JOHN IWEBENDU OKWUSIDI⁴, OLANREWAJU SUNDAY WILLIAMS¹

Key words: organic, turmeric, ultraviolet radiation, testes, rabbits

Abstract

Thirty six male rabbits of 450-600g body weights fed with organic turmeric (OT) containing diet (D_2) or without OT supplementation (D_1) were randomly assigned to six treatment groups: Control (T_0); D_2 plus Ultraviolet radiation (UV, T_1); D_2 until UV (T_2); D_2 after UV (T_3); D_1 non-turmeric-fed with UV (T_4) and D_2 without UV (T_5). UV irradiated animals showed conspicuous damage in their testicular tissues. The OT corrected UV-induced damages and offered a prophylactic protection to the testicular tissues. It was concluded that OT feeding could restore the testicular tissue damage by ultraviolet radiation.

Introduction

Rabbits can be raised on high fiber feeds and industrial by-products, not utilized by man (N.R.C, 1981). The small body size, short generation interval, rapid growth rate, genetic diversity and high reproductive potentials are characteristics, which make them suitable as meat producing livestock in developing countries (Arijeniwa et al. 2000).

Trends in applying nutritional antioxidants in diseases related to oxidative stress have gained immense interest in recent years. Turmeric plant (*Curcuma longa*) is a rhizome, which has been known to be a spice as well as medicinal agent (Eigner and Scholz, 1999). Curcumin is the main active ingredient in Turmeric (Osawa et al. 1995). Curcumin has been found to have nematocidal, antifungal and anti-inflammatory effect as well as the ability to scavenge free radicals. It modulates anti-oxidant properties against oxidative tissue damage through the inhibition of Reactive Oxygen Species (ROS) generation, with no side effect (Osawa et al. 1995; Khanna 1999). According to Asami et al (2003) and Brandt et al (2010), several studies have shown that crops grown with organic principles have significantly higher levels of certain minerals, vitamins, antioxidants and phytonutrients, and thus could give substantial protection against deleterious risks.

Ultraviolet (UV) radiation is an invisible light ray, to which living organisms are generally exposed on daily basis. It induces the production of Vitamin D in the skin, which helps bone growth and maintenance of bone density, immunity, cell proliferation, insulin secretion and maintenance of normal blood pressure (Vieth 1999). However, it has been indicated that when organisms are exposed to ultraviolet radiation, a constant fraction of the living cells are inactivated during each progressive increment in time by absorption of light, which causes a photochemical reaction that alters the molecular components essential to cell function (Davies et al. 2002). Prolonged exposure to solar ultraviolet radiation may result in acute and chronic health effects on the skin, eye and immune system through mutagenic or carcinogenic process (USERPA 1966). Such exposure is associated with various pathological conditions that include reproductive dysfunctions, consequent upon oxidative stress. This is one of the plausible mechanisms for UV induced cellular deteriorations. Currently, there is a dearth of information on the use of organic turmeric to mitigate the harmful effect of UV radiation on reproductive organs of rabbits. This study was therefore conducted to investigate the efficacy of organic turmeric on the structural architecture of the testes of rabbits exposed to UV radiation.

Material and methods

The experiment was conducted at the Rabbit Unit of Ladoke Akintola University of Technology (LAUTECH) Agricultural Services (LAS) Ltd Certified Organic Farm, Ogbomoso, Nigeria. Thirty six male weaner rabbits of mixed breed, weighing between 450 - 600g were weight-balanced and randomly assigned to 6 dietary treatment groups of 6 rabbits each. Each rabbit was housed individually and received experimental diet,

¹ Department of Animal Production and Health, Faculty of Agricultural Sciences, gboyetogun@yahoo.com

² Department of Animal Nutrition and Biotechnology, Faculty of Agricultural Sciences

³ Department of Biochemistry, ⁴Department of Physiology, Faculty of Basic Medical Sciences

⁴ Ladoke Akintola University of Technology (LAUTECH), Ogbomoso, Nigeria.

prepared mostly from feed ingredients, harvested on the organic farm, with *Moringa olifera* at 0.2% inclusion, to replace synthetic lysine and methionine. A premix, which included garlic, ginger and *Asparagus racemosus*, served as ethno veterinary provision in the feed. Fresh grass and legumes were cut daily and allowed to wilt before they were generously offered later in the day. The experimental diet was offered to the rabbits with fresh water ad libitum, fortified with organic Horney as anti-stress, during the first two weeks, to acclimatize before data collection. The rabbits received diets either without 2% organic turmeric (D₁) or with 2% organic turmeric (D₂) for the nine-week experimental period. The treatments were T0 (Control – No organic Turmeric, no UV radiation exposure); T1 (Turmeric feeding before and after UV radiation exposure); T2 (Turmeric feeding before and not after UV radiation exposure); T3 (Turmeric feeding after UV radiation); T4 (UV radiation exposure without turmeric feeding) and T5 (Turmeric feeding without UV radiation exposure). Rabbits were exposed to UV radiation in a radiation box of 1 x 2m² equipped with UV fluorescent tubes, measuring 0.61m. The rabbits were exposed for 10 minutes per animal per day for five days. Animals were slaughtered 30 days after exposure to ultraviolet radiation and the male reproductive organs were carefully removed for histological examinations after the standard procedure for slide preparation.

Results

The histological results are shown in Figures 1 to 6. Figure 1 shows the testicular structure of rabbits fed the control diet (T0). The testicular structure was normal with seminiferous tubules full of spermatogenic cells with normal Sertoli cells. The basement membrane was normal and showed no abnormality. Figure 2 shows the testicular structure of rabbits in T1. The seminiferous tubules were necrotic, with some disintegration of the lumen and degenerative effect on the epithelial lining of the cells. Figure 3 represents the T2. There was no major damage to the testicular cells but the seminiferous tubules were smaller. Figure 4 represents T3. There were no major damages to the germinal, Leydig and Sertoli cells. The seminiferous tubules were normal with spermatozoa at various stages of development in the lumen. Figure 5 shows the testicular structure of rabbits in T4. Degeneration of basement membrane, germ and Sertoli cells were observed. The seminiferous tubules were distorted; the Leydig cells were diffused into the lumen and spermatozoa were disorganized. Figure 6 represents the T5. There was no major damage to the basement membrane, germ and Sertoli cells. The seminiferous tubules were normal with conspicuous spermatozoa at various stages of development. The Leydig cells were also intact.

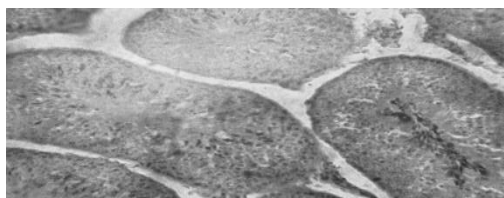


Figure 1. Testis of Control rabbits, turmeric No UV radiation) x100

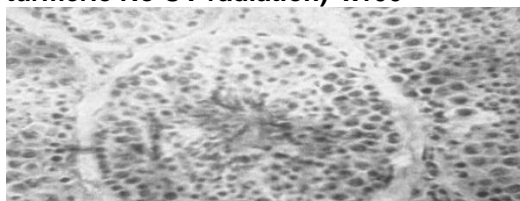


Figure 3. Testis of rabbits fed turmeric before to UV radiation x100

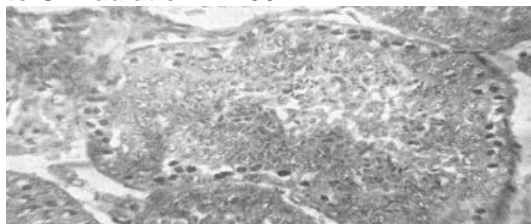


Figure 5. Testis of rabbits exposed to UV Radiation without turmeric feeding x100

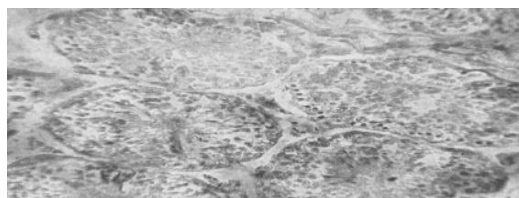

Figure 2. Testis of rabbits fed turmeric (No before and after UV radiation x100

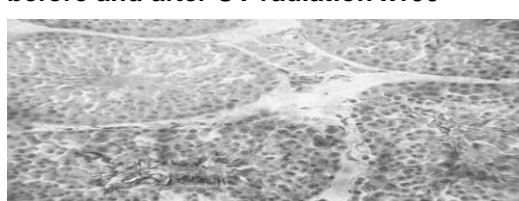


Figure 4. Testis of rabbits fed turmeric exposure after UV radiation x100

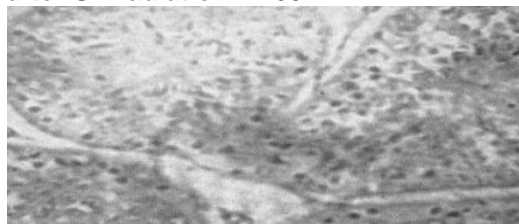


Figure 6. Testis of rabbits fed turmeric without exposure to UV radiation x100

Discussion

The histological results showed that rabbits that were not exposed to UV radiation had no damage to their cells while varying degrees of necrosis were observed in the rabbits exposed to UV radiation. Pamphilon et al (1991) reported that necrosis is the morphological change caused by the progressive degenerative action of enzymes on the lethally injured cells. Powell et al (1993) reported that UV radiation is known to affect the cell membranes of living organisms. It changes the cell surface antigens thereby blocking the cell to cell interactions and antigen introduction. The ameliorative property of the organic turmeric demonstrated over the negative effect of UV radiation on the testis in this study, can be explained by the fact that the organic soils on which such crops grow, typically have higher soil quality with more available natural micronutrients. These crops will therefore, naturally struggle to build up antioxidant and nutrient stores on their own, in order to protect and strengthen themselves, rather than waiting to receive rations of instantly available synthetic nutrients, which are supplied only to their conventional farm counterparts. Thus, these typically stronger plants, with more nutrient-dense food from the organic soil, offer more nutrients to the consumers of such crops as reported by Asami et al. (2003). Nutrigenomic studies have elucidated how extra nutritional constituents that usually occur in small quantities in foods, interact with the genome by modifying gene expression and consequently altering protein and metabolite composition within the cells, and even participating in the DNA repair and replication process (Zheng and Chen 2005; Subbiah 2008).

Conclusion

Inclusion of organic Turmeric, simply boiled, dried and powdered without any sophisticated processing to extract curcumin, in the diet ameliorated the effect of UV radiation on the testes of rabbits in the study. Organic turmeric could serve as prophylactic and curative treatment for reproductive damages that may result from exposure to UV radiation.

References

- Asami D K, Hong Y J, Barrett and Mitchell A E (2003): Comparison of total phenolic and Ascorbic content of Freeze-dried and Air-dried Marionberry, Strawberry, and Corn Crown using nonorganic, organic and sustainable agricultural practices, *Journal of Agricultural and Food Chemistry* 55 (15): 1237-1241)
- Arieniwa A, Otaikhian S O, Imaseun J A (2000): Performance of weaner rabbits fed grower diets supplemented with different grass legume rations. *In: Proc. 5th Annual conference of Animal Sci. Ass. Nig. (ASAN), 2000 September*, 103-105.
- Brandt K, Leifert C, Sanderson R and Seal C J (2011): Agroecosystem Management and Nutritional Quality of Plant Foods: The case of organic fruits and vegetables, *Critical Reviews in Plant Sciences*, 30: 1-2, 177-179.
- Davies H, Bignell G R and Cox C (2002): Mutations of the BRAF gene in human cancer. *Nature* 417 (6892): 949-954
- Eigner D and Scholz D (1999): *Ferula asa-foetida* and *Curcuma longa* in traditional medicinal treatment and diet in Nepal. *J. Ethnopharmacol.*, 1999, 67, 1-6. National Research Council, (NRC) (1981). Nutrient Requirements of Domestic Animals.No. 9. Nutrient
- Requirement of rabbits. Second Revised Edition, National Academy of Science. National Research Council, Washington D.C.
- Osawa T, Suguyama Y, Inayoshi M and Kawakisi S (1995): Anti-oxidative activity of tetrahydrocurcuminoids. *Biotechnol.andBiochem.* 59: 1609 - 1611
- Oseni S O (2008): A proposal for the genetic improvement of rabbits for smallholder units in Nigeria. *9th World Rabbit Congress – June 10-13, 2008- Verona – Italy*.P 464.
- Pamphilon D H, Alnaqdy A A and Wallington T B (1991): Immunomodulation by ultraviolet light: Clinical studies and biological effects. *Immunol. Today*. 12: 119 – 123.
- Powell M B, Rosenberg R K, Graham M J, Birch M L, Yamanishi D T, Buckmeier J A and Meyskens F L J (1993): Protein kinase C beta expression in melanoma cells and melanocytes; differential expression correlates with biological responses to 12-O tetradecanoylphorbol 13- acetate, *J. Cancer Resource Clinic*. 119:199-206.
- Subbiah M T (2008): Understanding the Nutrigenomic definitions and concepts at the Food-Genome Junction. *OMICS A journal of integrative Biology*. Vol 12, Number 4: 229-235

United State Environmental Protection Agency (USERPA) (1996): Water-US Environmental Protection Agency.

Vieth R (1999): Vitamin D supplementation, 25-hydroxyvitamin D concentrations and safety. *American Journal of Clinical Nutrition* 69 (5): 842 - 856

Zheng S and Chen A (2005): Curcumin suppresses the expression of extracellular matrix genes in activated hepatic stellate cells by inhibiting gene expression of connective tissue growth factor. *Am J Physiol (Gastrointest Liver Physiol)* 290, G883-G893