



THE UNIVERSITY *of* EDINBURGH

Edinburgh Research Explorer

Lethal BCG-osis in the context of superficial urothelial bladder carcinoma, diagnosed in autopsy

Citation for published version:

Madentzoglou, MS, Nathena, D, Sinatkas, V, Michalodimitrakakis, M & Kranioti, E 2016, 'Lethal BCG-osis in the context of superficial urothelial bladder carcinoma, diagnosed in autopsy' *Egyptian Journal of Forensic Sciences*, vol. 6, no. 3, pp. 284-288. DOI: 10.1016/j.ejfs.2015.07.007

Digital Object Identifier (DOI):

[10.1016/j.ejfs.2015.07.007](https://doi.org/10.1016/j.ejfs.2015.07.007)

Link:

[Link to publication record in Edinburgh Research Explorer](#)

Document Version:

Publisher's PDF, also known as Version of record

Published In:

Egyptian Journal of Forensic Sciences


General rights

Copyright for the publications made accessible via the Edinburgh Research Explorer is retained by the author(s) and / or other copyright owners and it is a condition of accessing these publications that users recognise and abide by the legal requirements associated with these rights.

Take down policy

The University of Edinburgh has made every reasonable effort to ensure that Edinburgh Research Explorer content complies with UK legislation. If you believe that the public display of this file breaches copyright please contact openaccess@ed.ac.uk providing details, and we will remove access to the work immediately and investigate your claim.





CASE REPORT

Lethal BCG-osis, in the context of superficial urothelial bladder carcinoma, diagnosed in autopsy



Maria S. Madentzoglou ^{a,*}, Despoina Nathena ^a, Vaios Sinatkas ^b,
Manolis Michalodimitrakis ^a, Elena F. Kranioti ^{a,c}

^a Department of Forensic Sciences, Faculty of Medicine, University of Crete, Greece

^b Department of Pathology, Medical School, Voutes-Stavrakia, Heraklion, Crete, Greece

^c Edinburgh Unit for Forensic Anthropology, SHCA, University of Edinburgh, Scotland, UK

Received 31 May 2015; revised 21 July 2015; accepted 29 July 2015

Available online 18 August 2015

KEYWORDS

BCG-osis;
Superficial urothelial bladder carcinoma;
Autopsy

Abstract Intra-vesicular Bacillus Calmette–Guérin (BCG) immuno-therapy is a cornerstone in the treatment of superficial bladder carcinoma. However, it can rarely cause BCG-osis, a systemic infection, potentially fatal. A case of a 73 year old man, diagnosed with superficial urothelial bladder carcinoma five months ago, who died with clinical features of septic shock one day after BCG therapeutic maintenance infusion, is presented. The cause of death, BCG-osis, was revealed during autopsy.

© 2015 The International Association of Law and Forensic Sciences (IALFS). Production and hosting by Elsevier B.V. This is an open access article under the CC BY-NC-ND license (<http://creativecommons.org/licenses/by-nc-nd/4.0/>).

1. Introduction

BCG (Bacillus Calmette–Guérin) is prepared from a strain of the attenuated live bovine bacillus, *Mycobacterium bovis*.^{1,2} Additional to its use, as a vaccine for the prevention of tuberculosis, BCG has therapeutic effects on several conditions such as leprosy,³ Buruli ulcer⁴ and several carcinomas. BCG has been reported for its potency against lung, stomach and colorectal cancer, melanoma, ovarian carcinoma and bladder tumors.^{5–8} However, if BCG is accidentally given to an immunocompromised patient, it can cause disseminated or life-threatening infection.^{2,9} BCG immunotherapy, is a safe method^{10–12} used against recurrence and progression of

superficial urothelial carcinoma of the bladder.¹³ It affects both healthy urothelial cells and tumor cells^{14–15} by inducing a localized type IV hypersensitivity reaction in the bladder mucosa. It has been postulated that epitopes of BCG bacillus are presented as antigens on the surface of tumor cells, thus initiating cell to cell cytotoxicity.¹⁵

According to EAU Guidelines non-muscle-invasive urothelial bladder carcinoma patients are stratified in low, intermediate and high risk groups in order to estimate their prognosis and indicate an adequate treatment regimen.¹⁶ BCG immunotherapy is indicated, in intermediate and high risk tumors. Several studies have proved that it prevents tumor recurrence and progression after transurethral resection (TUR) and that is more effective than TUR with adjuvant chemotherapy.¹⁶ The usual induction protocol for BCG instillation is the six-weekly one, followed by a maintenance protocol, if needed.¹⁷ However, BCG immunotherapy has a greater complication incidence than intra-vesical chemotherapy and

* Corresponding author.

E-mail address: nebulaaluben@yahoo.gr (M.S. Madentzoglou).

Peer review under responsibility of The International Association of Law and Forensic Sciences (IALFS).

<http://dx.doi.org/10.1016/j.ejfs.2015.07.007>

2090-536X © 2015 The International Association of Law and Forensic Sciences (IALFS). Production and hosting by Elsevier B.V. This is an open access article under the CC BY-NC-ND license (<http://creativecommons.org/licenses/by-nc-nd/4.0/>).

some of these complications, although rare, can be serious.^{10,16} BCG-osis is one of them.

The absolute contra-indications of BCG intra-vesical instillation are: recent TUR (less than fourteen days), macroscopic hematuria, urinary tract infection and traumatic bladder catheterization.^{6,16}

We present a case of fatal BCG-osis revealed in autopsy.

2. Case report

The deceased, a 73 year old white man, was a chronic smoker who had suffered a myocardial infarct thirty-eight years ago. He was under anti-hypertensive medication with a combination of an angiotensin converting enzyme inhibitor plus a thiazide diuretic and acetylsalicylic acid. There was no history of previous pulmonary disease or immunodeficiency state. He was diagnosed with superficial papillary urothelial bladder carcinoma 5 months ago, after a TUR. Following this diagnosis, he underwent intra-vesicular BCG immunotherapy, based on a weekly and then monthly instillation protocol. He had been reporting low fever (<38 °C) after each therapeutic session, which remised without medication.

After, his last intra-vesical BCG infusion, he presented with high fever, fatigue, oliguria, and dysuria. The clinical records didn't state any complication during the last instillation procedure. Due to a progressively deteriorating general condition, and the presence of an abdominal skin rash, he was transferred to our hospital the following day. Upon arrival, he was already septic, and despite the administration of adrenaline, broad spectrum antibiotics and corticosteroids, the patient passed away ten hours later. Certainty about previous BCG vaccination could not be reached either through medical records or through relative testimonies. The main autopsy findings are summarized below.

2.1. Macroscopic findings

A diffuse micro-petechial rash on the abdominal wall was observed. The examination of the cardiovascular system revealed critical stenosis in all coronary arteries: 85% of the lumen was occluded in the left anterior descending artery and the left circumflex artery was almost completely occluded in its central portion. The heart weighed 420 g, and had a left type perfusion. Mild concentric hypertrophy of the left ventricle was present. A broad, whitish, scar in the rear wall of the left ventricle, accompanied with focal wall attenuation was found. Bold atherosclerotic lesions were present in the aorta, and particularly in the bifurcation of the abdominal aorta and also in the common iliac arteries.

The right and left lung weighed 880 g and 860 g respectively, and appeared congestive and edematous. On their pleural surface were exhibited multiple, yellowish nodules of maximum diameter 0.1–0.2 cm. Nodules of the same morphology were also noted during lung dissection. The liver weighed 2180 g with fatty liver appearance. The gallbladder was filled with gallstones.

Focal hyperemia of the bladder mucosa, micro-granular appearance of the kidneys and few adhesions between the viscera of the pelvic region were also observed.

2.2. Histological examination

The histological examination of lung parenchyma, revealed multiple caseating and non-caseating epithelioid granulomas, with the presence of Langhans and Touton giant cells (Figs. 1a and 1b). Diffuse, lymphocytic infiltrates were observed in the pulmonary interstitium. Peripheral emphysema, as well as thickening of alveolar septa were observed. Focally, amorphous eosinophilic material filled the alveolar spaces. Hyperplasia of type II pneumocytes, and sloughing of alveolar type I pneumocytes were present in these regions.

The histologic sections from the coronary arteries, showed features of activated atherosclerotic plaques. The microscopic examination of the myocardium, revealed findings of mild cardiac hypertrophy, as well as features of previous ischemic myocardial necrosis and fibrosis in the posterior wall of the left ventricle and in the posterior portion of the intraventricular septum.

Severe, fatty degeneration of the liver parenchyma was evident, along with dense lymphocytic inflammatory infiltrates in the portal frames. Focal destruction of hepatocytes and extension of the inflammatory infiltrate within the hepatic lobules were also present. Tiny lymphocytic aggregates were also observed inside the hepatic lobules. Multiple abscesses with neutrophil granulocytes, parenchymal necrosis as well as multiple non-caseating and caseating epithelioid granulomas not associated with bile ducts were present (Fig. 2). Reactive hepatocyte regeneration was evident in the form of bi-nucleated hepatocytes.

The kidneys presented findings typical of hypertensive atherosclerotic disease, with chronic inflammatory cells (lymphocytes) in the interstitial tissue. The bladder mucosa and submucosa were moderately infiltrated by lymphocytes, plasma cells and eosinophilic leukocytes. Focally, minute, non-necrotic epithelioid granulomas were present. In one of the few places where the transitional epithelium of the bladder was present, features of hyperplasia with regenerative atypia were evident. These minute granulomas, may be attributed to TUR, as well as BCG immunotherapy, so they are not specific for BCG-osis. Thin sections of the prostate, revealed massive necrosis of the organ confluent necrotic granulomas and epithelioid histiocyte aggregates (Fig. 3).

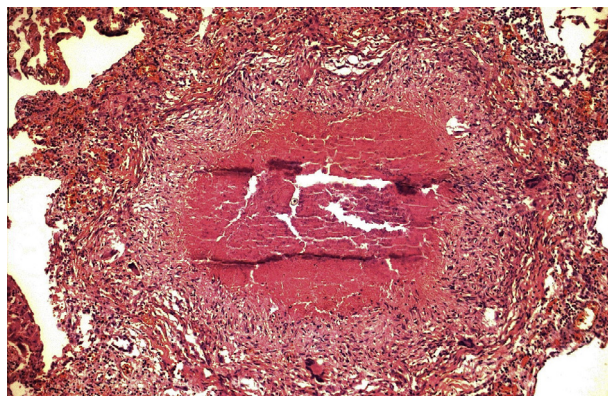


Figure 1a Large caseating granuloma in the lung parenchyma (H&E stain ×200).

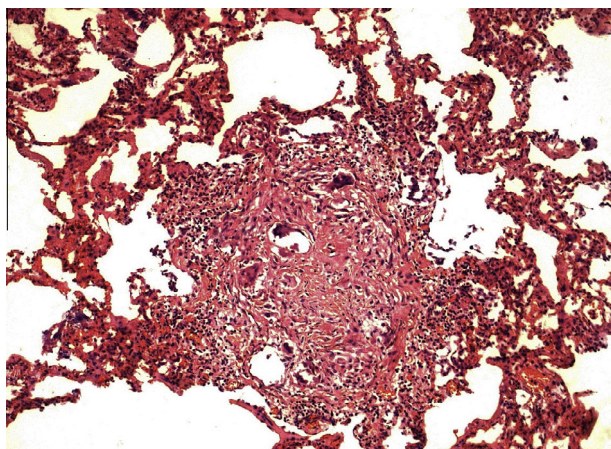


Figure 1b Non caseating lung granuloma (H&E stain $\times 200$).

Histochemical staining for acid fast bacilli (Ziehl–Neelsen) was performed in sections from the lung and liver parenchyma where granulomas were evident, but proved negative. PCR for mycobacterial bacilli was not performed.

The cause of death was attributed to generalized BCG-osis, on grounds of coronary heart disease and papillary urothelial carcinoma of the bladder treated with BCG immunotherapy. The manner of death was certified as natural.

3. Discussion

The side effects of BCG intra-vesical immunotherapy are usually mild and short-term, such as abacterial cystitis, dysuria, hematuria, low fever and usually recede without special treatment.^{6,12,13} They are also called noninfectious or inflammatory side effects in the literature.¹² The major side effects are relatively rare (seen in less than 5% of the patients)^{10,18–19} and can be divided in early or late ones, depending on whether the patient consulted a physician during or after, a 6 month interval from BCG installation.¹⁹ Besides, adverse effects are

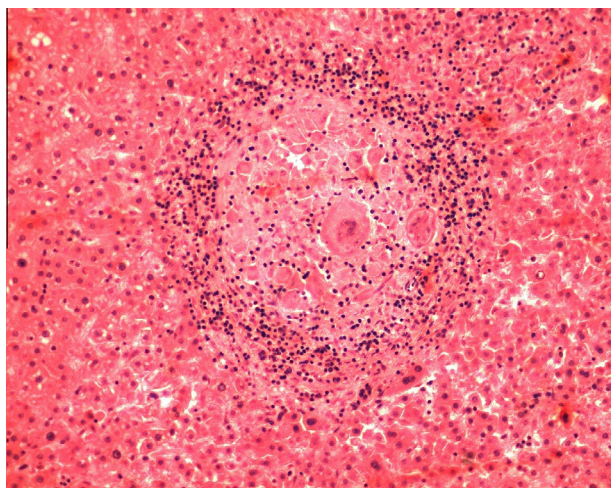


Figure 2 Liver granuloma (H&E stain $\times 400$).

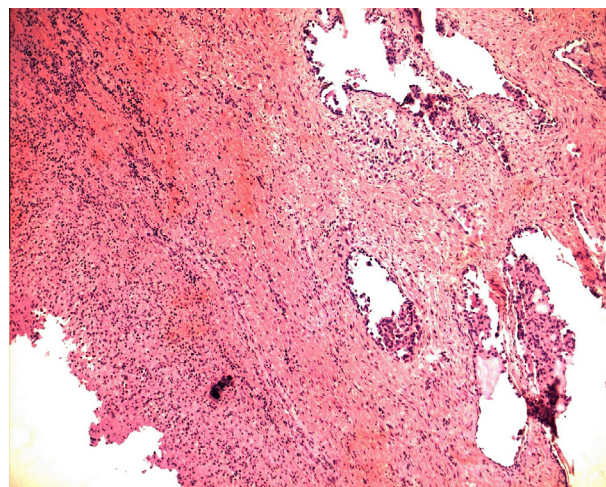


Figure 3 Part of large necrotic area in the prostate (H&E stain $\times 100$).

stratified as local or bladder related, and systemic.²⁰ Both of them are more frequent during the immediate period after induction, or in the first semester of the maintenance protocol.²⁰ There are also side effects nonspecific to BCG, which are related with malpractice during the procedure of transurethral BCG installation.¹³

Hepatitis,²¹ miliary tuberculosis,²² systemic granulomatous disease,^{21,23–26} sepsis,^{12,27–28} allergic reactions,¹³ and cardiac toxicity have been reported among BCG serious adverse effects.²⁹ The most serious side effect of BCG immunotherapy is BCG-osis or BCG-itis, which is a regularly associated with traumatic bladder catheterization,^{6,10,13,30} subsequent hematogenous dispersion of *M. bovis*, with multiple organ dysfunction³¹ and failure. This status may be lethal.¹³

If a patient with a history of BCG immunotherapy becomes septic, has fever over 39.5 °C or has persistent fever over 38.5 °C for more than 24 h, BCG-osis should be suspected.^{30,32} The therapeutic manipulation under these circumstances consists of multi-drug antituberculous scheme, plus antibiotics against gram negative bacteria, and corticosteroids.^{6,13,33} The mechanism implicated in the above mentioned side effects is a hypersensitivity response, based on the presence of granulomas, frequently in the absence of microorganisms or real active dissemination of *M. bovis*, which is rather unusual.^{27,34}

Furthermore, it must be noted that detection of *M. bovis*, by means of Ziehl Neelsen stain or PCR reaction in the sputum, bronchial or bone marrow biopsy material,^{27,35} is usually negative, and so diagnosis is based on histopathological findings and case history.²⁵

In conclusion, attention must be drawn to the affiliation of nurses, physicians and patients with BCG infusion complications in order to decrease side effects and improve the therapeutic procedure.^{18,24,25} Although BCG administration is common practice between urologists, usually non urologists have to deal with BCG side effects.¹³

Regarding the case presented, none of the above mentioned contra-indications were present according to the clinical records. However, the massive necrosis of the prostate as well as the rapid onset of the disease speaks in favor of a traumatic bladder catheterization during the last BCG instillation. The

patient developed an acute, rapidly evolving syndrome with high persistent fever after BCG maintenance infusion. He was eventually hospitalized, with septic shock clinical features, the following day. Although, he received adrenaline, broad spectrum antibiotics and corticoids, he did not recover. The cause of death, BCG-osis was revealed by autopsy findings.

This case stresses the importance of alertness for side effects of BCG immunotherapy. Patients as well as health professionals in general, but also forensic pathologists should be acquainted with its features.

Funding

None.

Conflict of interest

None declared.

Ethical approval

Necessary ethical approval was obtained from the institute ethics committee.

Acknowledgements

The authors would like to thank the technicians: Mrs. T. Apostolaki for the preparation of histological slides and Mr. S. Kougiou and A. Katsounas for their technical assistance during the autopsy procedure.

References

- Luca S, Mihaescu T. History of BCG vaccine. *Maedica (Buchar)* 2013;**8**(1):53–8.
- Marciano BE, Huang CY, Joshi G, et al. BCG vaccination in patients with severe combined immunodeficiency: complications, risks, and vaccination policies. *J Allergy Clin Immunol* 2014;**133**(4):1134–41.
- Merle CS, Cunha SS, Rodrigues LC. BCG vaccination and leprosy protection: review of current evidence and status of BCG in leprosy control. *Expert Rev Vaccines* 2010;**9**(2):209–22.
- Tanghe A, Content J, Van Vooren JP, et al. Protective efficacy of a DNA vaccine encoding antigen 85A from *Mycobacterium bovis* BCG against Buruli ulcer. *Infect Immun* 2001;**69**(9):5403–11.
- Raez LE, Fein S, Podack ER. Lung cancer immunotherapy. *Clin Med Res* 2005;**3**(4):221–8.
- Gandhi NM, Morales A, Lamm DL. Bacillus Calmette–Guérin immunotherapy for genitourinary cancer. *BJU Int* 2013;**112**(3):288–97.
- Mosolits S, Nilsson B, Mellstedt H. Towards therapeutic vaccines for colorectal carcinoma: a review of clinical trials. *Expert Rev Vaccines* 2005;**4**(3):329–50.
- Kelleher BM, Cristopherson W, Macpherson T. Disseminated granulomatous disease (BCGosis) following chemoimmunotherapy for ovarian carcinoma. *Gynecol Oncol* 1988;**31**:321–6.
- Mak TK, Hesseling AC, Hussey GD, et al. Making BCG vaccination programmes safer in the HIV era. *Lancet* 2008;**372**(9641):786–7.
- Lamm DL, van der Meijden PM, Morales A, et al. Incidence and treatment of complications of bacillus Calmette–Guérin intravesical therapy in superficial bladder cancer. *J Urol* 1992;**147**(3):596–600.
- Lamm DL, Stogdill VD, Stogdill BJ, et al. Complications of bacillus Calmette–Guérin immunotherapy in 1,278 patients with bladder cancer. *J Urol* 1986;**135**(2):272–4.
- Naudžiūnas A, Juškaitis R, Žiaugrytė I, et al. Tuberculosis complications after BCG treatment for urinary bladder cancer. *Medicina (Kaunas)* 2012;**48**(11):563–5.
- Lockyer CR, Gillatt DA. BCG immunotherapy for superficial bladder cancer. *J R Soc Med* 2001;**94**(3):119–23.
- Rentsch CA, Biot C, Gsponer JR, et al. BCG-mediated bladder cancer immunotherapy: identifying determinants of treatment response using a calibrated mathematical model. *PLoS One* 2013;**8**(2):e56327.
- Steinberg GD, Patel SG, Sachdeva K, et al. *Bacillus Calmette–Guérin immunotherapy for bladder cancer overview of BCG immunotherapy*. Updated: May 12, 2014. Available at: <<http://emedicine.medscape.com/article/1950803-overview>> accessed July 11, 2014.
- Babjuk M, Burger M, Zigeuner R, et al. European Association of Urology. EAU guidelines on non-muscle-invasive urothelial carcinoma of the bladder: update 2013. *Eur Urol* 2013;**64**(4):639–53.
- Palou J, Laguna P, Millán-Rodríguez F, et al. Control group and maintenance treatment with bacillus Calmette–Guérin for carcinoma in situ and/or highgrade bladder tumors. *J Urol* 2001;**165**(5):1488–91.
- Palou J. Factors related to side effects of intravesical bacillus Calmette–Guérin: dose, maintenance treatment, and physicians? *Eur Urol* 2014;**1265**(1):77–8.
- Gonzalez OY, Musher DM, Brar I, et al. Spectrum of bacille Calmette–Guérin (BCG) infection after intravesical BCG immunotherapy. *Clin Infect Dis* 2003;**36**(2):140–8.
- van der Meijden AP, Sylvester RJ, Oosterlinck W, et al. EORTC Genito-Urinary Tract Cancer Group. Maintenance Bacillus Calmette–Guérin for Ta T1 bladder tumors is not associated with increased toxicity: results from a European Organisation for Research and Treatment of Cancer Genito-Urinary Group Phase III Trial. *Eur Urol* 2003;**44**(4):429–34.
- Fernández Cañabate E, Longoni Merino M. Systemic infection secondary to intravesical BCG instillation. *Farm Hosp* 2006;**30**(5):317–9 article in Spanish.
- Dimitropoulos C, Kotsifas K, Vamvakaris I, et al. Miliary tuberculosis induced by intravesical BCG instillation in a patient with bladder carcinoma. *Arch Hell Med* 2011;**28**(4):548–52 article in Greek.
- Mooren FC, Lerch MM, Ullerich H, et al. Systemic granulomatous disease after intravesical BCG instillation. *BMJ* 2000;**320**(7229):219.
- Parker SG, Kommu SS. Post-intravesical BCG epididymo-orchitis: case report and a review of the literature. *Int J Surg Case Rep* 2013;**4**(9):768–70.
- Aslan G, Sevinc C, Tuna B, et al. Penile lesion with inguinal adenopathy after intravesical Bacillus Calmette–Guérin instillation therapy. *Indian J Urol* 2013;**29**(1):70–2.
- Tan L, Testa G, Yung T. Diffuse alveolar damage in BCGosis: a rare complication of intravesical bacillus Calmette–Guérin therapy for transitional cell carcinoma. *Pathology* 1999;**31**:55–6.
- Bachlitzanakis N, Patsourakis G, Pigakis K, et al. Granulomatous pneumonitis after intravesical instillation of BCG in a patient with bladder carcinoma. *Pneumon* 2007;**20**(4):395–400.
- Garyfallou GT. Mycobacterial sepsis following intravesical instillation of bacillus Calmette–Guérin. *Acad Emerg Med* 1996;**3**(2):157–60.
- Elkabani M, Greene JN, Vincent AL, et al. Disseminated *Mycobacterium bovis* after intravesical bacillus Calmette–Guérin treatments for bladder cancer. *Cancer Control* 2000;**7**(5):476–81.

30. Lukacs S, Tschobotko B, Szabo NA, et al. Systemic BCG-Osis as a rare side effect of intravesical bcg treatment for superficial bladder cancer. *Case Rep Urol* 2013;**2013**:821526.
31. Demers V, Pelsser V. "BCGitis": a rare case of tuberculous epididymoorchitis following intravesical Bacillus Calmette–Guérin therapy. *J Radiol Case Rep* 2012;**6**(11):16–21.
32. Elmer A, Bermes U, Drath L, et al. Sepsis and multiple organ failure after BCG instillation in bladder cancer. *Urologe A* 2004;**43**(12):1537–40 article in German.
33. Lamm DL. Complications of bacillus Calmette–Guérin immunotherapy. *Urol Clin North Am* 1992;**19**(3):565–72.
34. Iantorno R, Nicolai M, Storto ML, et al. Miliary tuberculosis of the lung in a patient treated with bacillus Calmette–Guerin for superficial bladder cancer. *J Urol* 1998;**159**(5):1639–40.
35. Foster DR. Miliary tuberculosis following intravesical BCG treatment. *Br J Radiol* 1997;**70**(832):429.