



THE UNIVERSITY *of* EDINBURGH

Edinburgh Research Explorer

Unusual presentations of feline cowpox

Citation for published version:

O'Halloran, C, Del-Pozo, J, Breheny, C, Gunn-Moore, D, Dobromylskyj, M, Papasoulitis, K, Simpson, K & Henken, J 2016, 'Unusual presentations of feline cowpox' *Veterinary Record*, vol. 179, no. 17, pp. 442-443.
DOI: 10.1136/vr.i5767

Digital Object Identifier (DOI):

[10.1136/vr.i5767](https://doi.org/10.1136/vr.i5767)

Link:

[Link to publication record in Edinburgh Research Explorer](#)

Document Version:

Peer reviewed version

Published In:

Veterinary Record

General rights

Copyright for the publications made accessible via the Edinburgh Research Explorer is retained by the author(s) and / or other copyright owners and it is a condition of accessing these publications that users recognise and abide by the legal requirements associated with these rights.

Take down policy

The University of Edinburgh has made every reasonable effort to ensure that Edinburgh Research Explorer content complies with UK legislation. If you believe that the public display of this file breaches copyright please contact openaccess@ed.ac.uk providing details, and we will remove access to the work immediately and investigate your claim.



Dear Editor,

We would like to share with colleagues a significant increase in the number and severity of feline cowpox (FPxV) cases positively diagnosed in the UK in recent weeks.

At a recent meeting of ISCAID (International Society for Companion Animal Infectious Diseases) it was noted by several clinicians, as well as the authors, that the severity of presenting skin lesions in a number of these cases was markedly atypical. Cases appear to be presenting with large areas of focal dermal necrosis (eschars) and/or extensive erythema and oedema (Figure 1). This presentation is not concordant with the usual clinical signs of small, well demarcated ulcerated skin lesions (Figure 2), which spontaneously resolve¹. FPxV is also known to be associated with severe pneumonia in a number of cats¹. As well as an increase in the number of tissue samples being submitted by practitioners for histological examination, the sample appearance is also much more severe than usual (Figure 3). These more virulent presentations have been documented across the UK, with cases confirmed in practices as distant as Edinburgh and Bristol.

It is important that colleagues are aware of these changes because, whilst rare, FPxV can infect owners resulting in a potentially life threatening infection^{1,2}. FPxV cases tend to peak in the autumn, annually, as this is when the reservoir host numbers (bank voles, field voles and wood mice) are at their greatest and this year the weather has been appropriate for a boon in rodent numbers¹.

Incidentally, this is also supported by a similar increase in the number of feline lungworm cases (being caused by either *Aelurostrongylus abstrusus* or *Capillaria aerophila* [aka *Eucoleus aerophilus*]) being diagnosed at the present time in the UK, as numbers of slugs and snails may also be increased.

It is also possible that the observed change in clinical severity of FPxV infections, and to some extent the increase in case frequency, represents the circulation of a new or particularly virulent viral strain of FPxV than has previously been documented in the UK. An increase in viral virulence may have implications for zoonotic transmission and severity of transmitted disease, therefore the authors would like to be made aware of any such cases. Whereas typical FPxV lesions frequently spontaneously resolve, in these severe cases more aggressive therapy may be required including hospitalisation for non-specific supportive care as well as the use of more targeted therapy such as recombinant interferon. In all cases of FPxV, the use of exogenous corticosteroids is contraindicated.

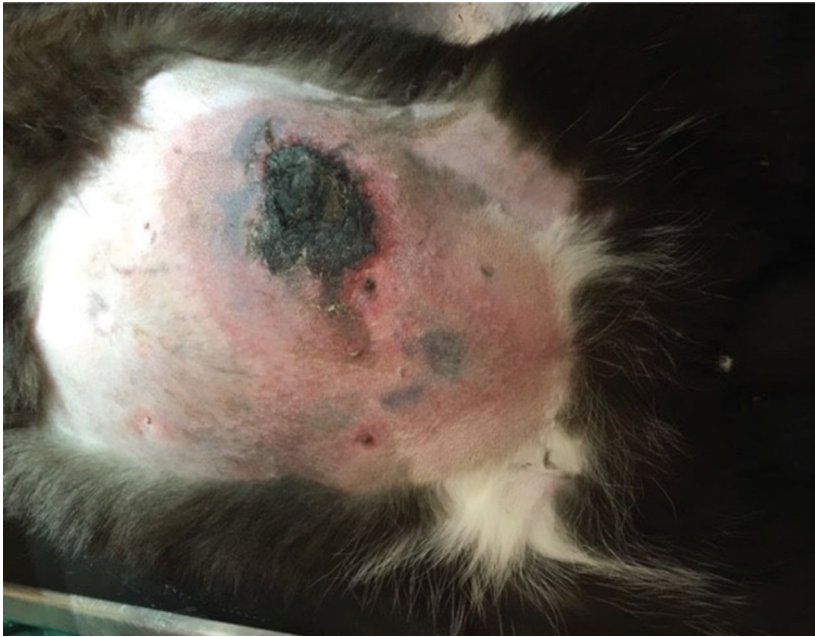


Figure 1: A well demarcated focally extensive area of dermal necrosis (eschar) with surrounding tissue erythema and oedema on the ventral abdomen of a male DSH cat due to FPxV infection. *Picture courtesy of Julia Henken.*

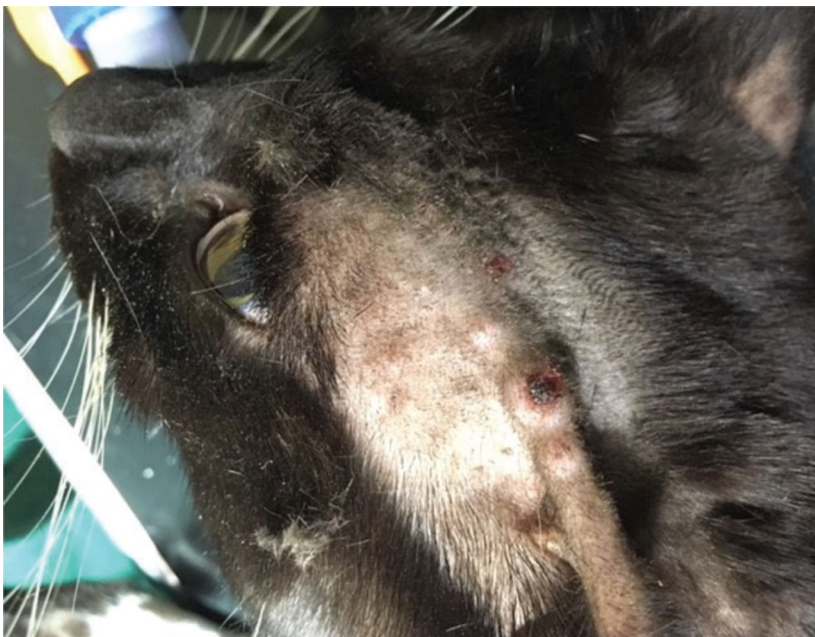


Figure 2: Typical small, well demarcated, raised alopecic and ulcerated skin nodules on the head of a male DSH cat due to FPxV infection. *Picture courtesy of Julia Henken.*

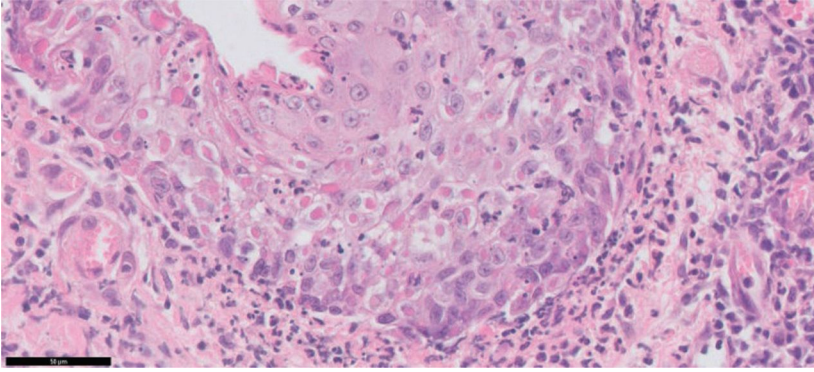


Figure 3: Histological examination of skin biopsy (40x magnification, haematoxylin and eosin staining) demonstrating severe response to FPxV infection including eosinophilic viral inclusion bodies. *Picture courtesy of Melanie Dobromylskyj and Richard Fox.*

References:

1. McInerney, J., Papasouliotis, K., Simpson, K., English, K., Cook, S., Milne, E., Gunn-Moore, D.A. (2015) **Pulmonary cowpox in cats: Five cases** *Journal of Feline Medicine and Surgery*, 18 (6), pp. 518-525.
2. Schulze, C., Alex, M., Schirrmeier, H., Hlinak, A., Engelhardt, A., Koschinski, B., Beyreiß, B., Hoffmann, M., Czerny, C.-P. (2007) **Generalized fatal Cowpox virus infection in a cat with transmission to a human contact case** *Zoonoses and Public Health*, 54 (1), pp. 31-37.

Conor O'Halloran^{1a}, Melanie Dobromylskyj^b, Jorge Del-Pozo^a, Craig Breheny^a, Kostas Papasouliotis^c, Kerry Simpson^d, Julia Henken^e and Danielle Gunn-Moore^a.

¹Corresponding author: Conor O'Halloran BVSc MSc MRCVS, Royal (Dick) School of Veterinary Studies and Roslin Institute, University of Edinburgh, Easter Bush Campus, Midlothian, EH25 9RG
Email: conor.o'halloran@roslin.ed.ac.uk

^aRoyal (Dick) School of Veterinary Studies and Roslin Institute, University of Edinburgh, Easter Bush Campus, Edinburgh

^bFinn Pathologists, One Eyed Lane, Weybread, Diss, Norfolk

^cSchool of Veterinary Sciences, University of Bristol, Langford, Bristol

^dHighcroft Veterinary Referrals, Witchurch, Bristol

^eBatchelor, Davidson and Watson, Edinburgh