

Left Ventricular Non-compaction, Or Is It?

Nay Aung, MD, MRCP^a; Filip Zemrak, MD, MRCP^a; Steffen E Petersen, MD, DPhil, MPH, FRCP^a

^aWilliam Harvey Research Institute, NIHR Cardiovascular Biomedical Research Unit at Barts, Queen Mary University of London, London, United Kingdom

Brief title: Left Ventricular Non-compaction, Or Is It?

Acknowledgements: The authors would like to express their gratitude to Robert Anderson, David Maclver and Bjarke Jensen for the excellent discussions on LVNC which informed this editorial.

Disclosure: NA and FZ have no conflict of interest to declare. SEP provides Consultancy to Circle Cardiovascular Imaging Inc., Calgary, Canada.

Corresponding Author:

Steffen E. Petersen, MD, DPhil, MPH, FRCP
Professor of Cardiovascular Medicine,
Honorary Consultant Cardiologist,
Director for Research Barts Heart Centre
Centre Lead for Advanced Cardiovascular Imaging,
William Harvey Research Institute,
NIHR Cardiovascular Biomedical Research Unit at Barts,
Charterhouse Square,
London, EC1M 6BQ, United Kingdom
Phone: 0044-(0)207 882 6902
E-mail: s.e.petersen@qmul.ac.uk

Excessive trabeculation of human left ventricles (LV) has been found in both pediatric and adult patients, with or without manifest cardiac disease. Presence of excessive trabeculations together with extensive inter-trabecular spaces that communicate with the ventricular cavity and a thin and ‘compacted’ myocardium points to a diagnosis of left ventricular non-compaction (LVNC). However, a global consensus on diagnosis, management or even the existence of this condition as a separate entity is lacking at present.

The capability of cardiac magnetic resonance (CMR) imaging to visualize trabeculae at high-spatial resolution has led to several quantification methods and LVNC diagnostic criteria, ranging from measurements of trabeculae length and total trabeculae mass to the fractal dimension technique (1-3). However, overreliance on imaging criteria for LVNC poses the risk of false diagnosis which will have tremendous impact on patients and their families. Therefore, it is vital to address 2 key questions. 1) What is the prognostic value of excessive trabeculation in an asymptomatic low risk population with normal cardiac morphology and function? 2) Is the extent of trabeculation important in the context of cardiovascular disease?

In this issue of *JACC*, Weir-McCall and colleagues described a cross-sectional analysis of association between excessive LV trabeculation meeting the current diagnostic criteria for LVNC and a variety of demographic, clinical and LV parameters in 1,480 asymptomatic participants (TASCFORCE cohort) free from known cardiovascular diseases. This study found that a significant proportion of the cohort (15%) met ≥ 1 of the current CMR-based LVNC diagnostic criteria. In addition, in multivariate analysis the long-axis non-compaction to compaction ratio was negatively correlated with systolic blood pressure and LV mass, even though the effect sizes were minimal and unlikely to have any clinical significance. These results echoed the previous study by our group published in this *Journal*, where we demonstrated similar findings of high prevalence of excessive trabeculation in the

asymptomatic multi-ethnic study of atherosclerosis (MESA) cohort, which appeared to have clinically insignificant influence on prognostically important LV parameters (4). It would certainly be interesting to see if those with excessive trabeculation in the TASCFORCE cohort develop adverse clinical outcomes at the planned 10-year follow-up, but our own data from the larger MESA study (sample size of ~3,000) showed that the event rates in an otherwise healthy cohort were too low for any definitive conclusion.

Most published literature on poor clinical outcomes of pediatric LVNC were relatively small in sample size and retrospective in nature, and the prognostic value of extent of trabeculation was not assessed (5-7). A recent paper by Claudia Stöllberger et al. described an excellent summary on co-morbidities and prognosis of published adult LVNC studies (8). These studies were also relatively small in size (maximum 220 participants) and typically consisted of patients with abnormal heart function or pre-existing cardiac symptoms. The adverse event rates were extremely variable in these studies and the extent of trabeculation was not found to be an independent predictor of major adverse cardiovascular events.

This issue of *JACC* presents an article by Daniele Andreini et al. which sheds further light on the prognostic relevance of the extent of trabeculation measured by CMR. In this prospective multicenter observational study, 113 patients with imaging evidence of LVNC were followed up for a composite endpoint of adverse cardiovascular outcomes— thromboembolic events, heart failure hospitalization, ventricular arrhythmias or cardiac death—over a course of approximately 4 years. It is important to note that a significant proportion of the study cohort had impaired cardiac function at recruitment with mean LV ejection fraction of 45%. Those with high clinical pre-test probability of LVNC made up 74% of the cohort. Thirty-six patients met the primary endpoint and 97% of those with events belonged to the high clinical pre-test probability group. The extent of trabeculation quantified by CMR was not associated with clinical outcome in the whole cohort. In multivariate

analysis, LV dilatation and presence of late gadolinium enhancement (LGE) were the only significant independent CMR predictors of adverse outcomes. In fact, none of the event-free patients had abnormal LV volumes or LGE.

These findings have important clinical implications. First, features of high pre-test probability of cardiomyopathy—cardiac symptoms, positive family history of non-ischemic cardiomyopathy, neuromuscular diseases, or prior malignant arrhythmias and thromboembolic events—are excellent predictors of adverse outcomes in those patients with excessive trabeculation. Second, the extent of trabeculation alone does not have any additional prognostic implication above and beyond the well-established deleterious markers, such as LV dilatation or LGE. The latter finding also reinforces the expanding pool of evidence suggesting trabeculation as an epiphenomenon coexisting with other forms of cardiomyopathies such as dilated cardiomyopathy (DCM) (9).

These 2 timely papers and previous literature highlight the absence of convincing evidence to consider the degree of trabeculation as prognostically relevant in asymptomatic low risk populations and in cardiomyopathies. This conclusion leads to further open questions on whether our current trabeculation quantification or LVNC diagnostic criteria are adequate for diagnosis and risk stratification and perhaps, more importantly, on the existence of LVNC as a separate disease entity.

The nomenclature of LVNC implies that the ‘compact’ or ‘solid’ layer of the myocardium develops through coalescing of pre-existing embryonic trabeculation. However, the emerging evidence suggests that this commonly-held belief of the mode of compact myocardium development is incorrect except for the papillary muscles (10). Using molecular staining techniques, studies by de Boer et al. and Sizarov et al. demonstrated the role of cellular proliferation within the solid myocardium during embryonic cardiogenesis in mouse and human, which contradicts the theory of trabecular condensation in formation of compact

myocardium (11,12). If trabeculation is indeed important for the size of compact wall, we should expect the compact wall thickness to be negatively correlated with degree of trabeculation. However, the inverse was true in our data from the MESA study (**Figure 1**). A seminal paper by Jensen and colleagues examined the evolution of ventricular trabeculation in both endothermic (warm-blooded) and ectothermic (cold-blooded) species (13). They found that the hypertrabeculated ventricles in post-natal human hearts were far less trabeculated than the embryonic ventricles. In contrast, the ventricles of fully-formed cold-blooded vertebrate were as trabeculated as their embryonic counterparts. These findings greatly challenge the hypothesis of LVNC as persistence of embryonic design at least in warm-blooded vertebrates and the term LVNC itself may be a misnomer.

In summary, there is growing evidence in the literature that presence of excessive trabeculation has no meaningful independent prognostic value in asymptomatic low risk populations and in cardiomyopathies, particularly DCM, when other prognostic factors are considered in regression models. Compaction does not appear to be an important process for formation of the solid ventricular wall and it may be the opportune time to reconsider the term “LVNC” and maybe use a preferable term such as ‘excessive trabeculation’ instead. Further research is needed to investigate if the extent of trabeculation plays an important prognostic role in physiological remodeling and in non-DCM cardiomyopathies.

REFERENCES

1. Petersen SE, Selvanayagam JB, Wiesmann F, et al. Left ventricular non-compaction: insights from cardiovascular magnetic resonance imaging. *J Am Coll Cardiol.* 2005;46(1):101-105.
2. Jacquier A, Thuny F, Jop B, et al. Measurement of trabeculated left ventricular mass using cardiac magnetic resonance imaging in the diagnosis of left ventricular non-compaction. *Eur Heart J.* 2010;31(9):1098-1104.
3. Captur G, Muthurangu V, Cook C, et al. Quantification of left ventricular trabeculae using fractal analysis. *J Cardiovasc Magn Reson.* 2013;15:36.
4. Zemrak F, Ahlman MA, Captur G, et al. The relationship of left ventricular trabeculation to ventricular function and structure over a 9.5-year follow-up: the MESA study. *J Am Coll Cardiol.* 2014;64(19):1971-1980.
5. Chin TK, Perloff JK, Williams RG, et al. Isolated noncompaction of left ventricular myocardium. A study of eight cases. *Circulation.* 1990;82(2):507-513.
6. Ichida F, Hamamichi Y, Miyawaki T, et al. Clinical features of isolated noncompaction of the ventricular myocardium: long-term clinical course, hemodynamic properties, and genetic background. *J Am Coll Cardiol.* 1999;34(1):233-240.
7. Pignatelli RH, McMahon CJ, Dreyer WJ, et al. Clinical characterization of left ventricular noncompaction in children: a relatively common form of cardiomyopathy. *Circulation.* 2003;108(21):2672-2678.
8. Stöllberger C, Blazek G, Gessner M, et al. Neuromuscular comorbidity, heart failure, and atrial fibrillation as prognostic factors in left ventricular hypertrabeculation/noncompaction. *Herz.* 2015;40(6):906-911.
9. Amzulescu M-S, Rousseau MF, Ahn SA, et al. Prognostic Impact of

Hypertrabeculation and Noncompaction Phenotype in Dilated Cardiomyopathy: A CMR Study. *JACC Cardiovasc Imaging*. 2015;8(8):934-946.

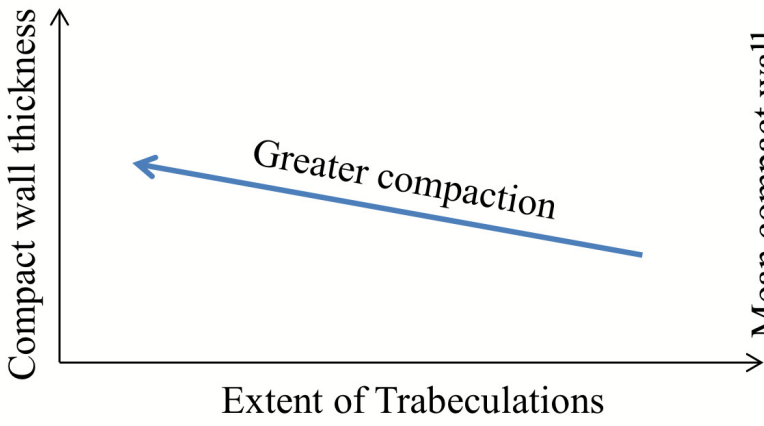
10. Anderson RH. The relationship between the positions of the left ventricular papillary muscles and the direction of the QRS axis. *J Electrocardiol*. 49(5):675-679.
11. de Boer BA, van den Berg G, de Boer PAJ, et al. Growth of the developing mouse heart: An interactive qualitative and quantitative 3D atlas. *Dev Biol*. 2012;368(2):203-213.
12. Sizarov A, Ya J, de Boer BA, et al. Formation of the building plan of the human heart: morphogenesis, growth, and differentiation. *Circulation*. 2011;123(10):1125-1135.
13. Jensen B, Agger P, de Boer BA, et al. The hypertrabeculated (noncompacted) left ventricle is different from the ventricle of embryos and ectothermic vertebrates. *Biochim Biophys Acta - Mol Cell Res*. 2016;1863(7):1696-1706.

FIGURE LEGEND

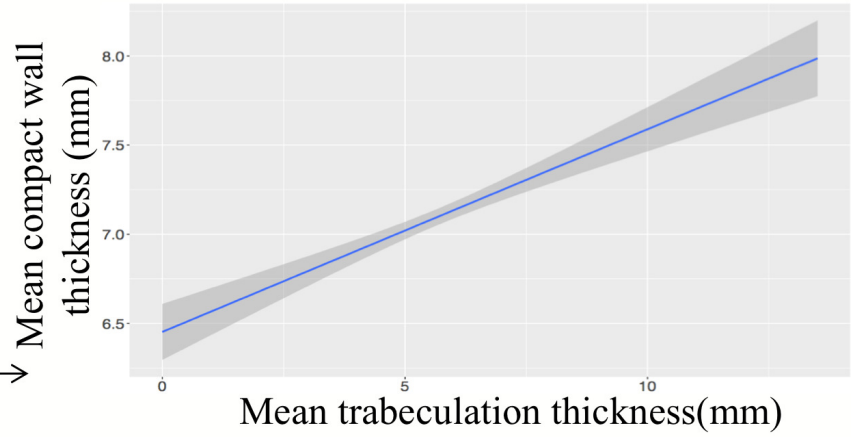
Figure 1. Correlation between extent of trabeculation and compact myocardium thickness

A – Expected relationship; B – Observed relationship in MESA data

A



B



Courtesy of Bjarke Jensen, Amsterdam and Filip Zemrak, MESA data