



## HIGH DENSITY MINERALISED PROTRUSIONS FROM THE TIDEMARK INTO HYALINE CARTILAGE IN HUMAN JOINTS

Gallagher, JA; Thomas, N; Donnelly, JL; Jeffery, N; Mills, D; Davis, GR; Boyde, A

Open access funded by OsteoArthritis Society International

For additional information about this publication click this link.

<http://qmro.qmul.ac.uk/xmlui/handle/123456789/12067>

Information about this research object was correct at the time of download; we occasionally make corrections to records, please therefore check the published record when citing. For more information contact [scholarlycommunications@qmul.ac.uk](mailto:scholarlycommunications@qmul.ac.uk)

anterior and central cartilage regions of the injured knee, in comparison to the contralateral, uninjured side. Tibial cartilage thickness was found to significantly decrease at one location within the posterior region of the medial compartment (Table 1 and Figure 1B). No significant differences in lateral tibial cartilage thickness were found.

Femoral segmentation could only be completed on 13 of 15 subjects. Significant increases in femoral cartilage thickness were found in the central, and posterior cartilage regions of the medial femur. Significant increases were also found within the anterior, and posterior cartilage regions of the lateral femur (Table 1 and Figure 1A). No significant differences were found within the anterior-medial or central-lateral cartilage regions.

**Conclusions:** Female subjects an average of 4 years post ACL-injury and reconstruction, displayed significant within subject differences in both femoral and tibial cartilage thickness. Within medial tibial cartilage, injured knees displayed significant thickness increases in the anterior and central cartilage regions, as well as a significant decrease in cartilage thickness within the posterior cartilage region. Significant increases in femoral cartilage thickness were displayed within the central, and posterior cartilage regions of the medial femur, as well as the anterior and posterior cartilage regions of the lateral femur.

Within the current study, significant medial tibial cartilage thickness differences were similar in location but greater in magnitude than significant differences seen within our previous study of acutely injured subjects; suggesting that tibial cartilage thickness changes seen at baseline may persist at 4 year follow up. These changes may serve as early indicators of osteoarthritic progression because they appear in a region known to develop PTOA, in advance of symptom onset and radiographic change.

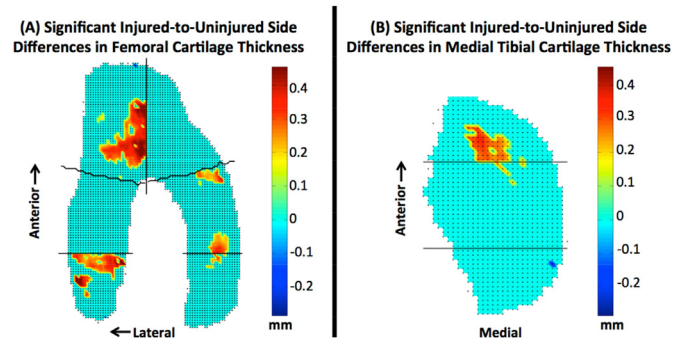


Figure 1A) Significant side-to-side increases in femoral cartilage thickness were found within the central and posterior regions of the medial femur. Significant increases were also found within the anterior, and posterior regions of the lateral femur. Figure 1B) Significant increases were found within the anterior and central cartilage regions of the medial tibia. A significant decrease was found in the posterior cartilage region of the medial tibia.

Femoral Cartilage Region	Mean	Range	Std. Dev
Anterior Medial	–	–	–
Central Medial	+ 0.26	0.18 – 0.41	0.05
Posterior Medial	+ 0.28	0.23 – 0.35	0.03
Anterior Lateral	+ 0.33	0.14 – 0.51	0.07
Central Lateral	–	–	–
Posterior Lateral	+ 0.33	0.20 – 0.59	0.09
Tibial Cartilage Region	Mean	Range	Std. Dev.
Anterior Medial	+ 0.28	0.21 - 0.33	0.04
Central Medial	+ 0.23	0.21 - 0.26	0.02
Posterior Medial	– 0.29	–	–
Anterior Lateral	–	–	–
Central Lateral	–	–	–
Posterior Lateral	–	–	–

Table 1: Significant within subject, injured-to-uninjured side differences in tibial and femoral cartilage thickness. (Differences displayed in millimeters).

**502 HIGH DENSITY MINERALISED PROTRUSIONS FROM THE TIDEMARK INTO HYALINE CARTILAGE IN HUMAN JOINTS**

J.A. Gallagher †, N. Thomas †, J.L. Donnelly †, N. Jeffery †, D. Mills †, G.R. Davis ‡, A. Boyde ‡. †Univ. of Liverpool, Liverpool, United Kingdom; ‡Barts and The London Sch. of Med., QMUL, London, United Kingdom

**Purpose:** High density mineralised protrusions (HDMP) are pathoanatomical structures recently identified in equine and human weight bearing joints. They arise from the tidemark mineralising front and project into hyaline articular cartilage (HAC). HDMPs appear to be formed by the extrusion of a mineralisable matrix into clefts in HAC. Their formation may be an extension of a crack self-healing mechanism found in bone and articular calcified cartilage. Mineral concentration exceeds that in articular calcified cartilage and is not uniform, consisting of an agglomeration of many fine particles into larger concretions. HDMP are surrounded by HAC. They are brittle, and show fault lines within them. HDMP have the potential to disintegrate and give rise to abrasive cutting and grinding particles within HAC which may contribute to mechanical joint destruction of joints. To date, HDMPs have been identified in the fetlock joints of Thoroughbred racehorses, the hock joints of Icelandic horses and most recently in the hip joints of people with osteoarthropathy of alkaptonuria and with more common osteoarthritis. The aim of this study was to increase our knowledge of the incidence of HDMPs in human weight bearing joints.

**Methods:** An on-going survey has to date involved the ex vivo investigation of twelve human weight bearing joints: 9 femoral heads and 3 knee joints. Samples obtained at surgery for arthroplasty or from dissection of bequeathed cadavers were fixed in 10% neutral formal saline for at least 12 h and then transferred to 70% ethanol and subsequently to glycerol for long term storage. Initial investigation on all samples was undertaken by MRI on a Trio 3 tesla MRI scanner using a circularly polarised wrist coils. Samples were taken out of storage pots and excess fluid removed from the surface with tissue paper. They were placed in sealed polythene bags to minimise evaporation. Three localiser sequences ensured a good representation of orientation of the joint. A range of scanning modalities were used to determine the sequences which would provide optimum contrast between HDMP and HAC. Some of the samples in which there was MRI evidence of HDMPs were subsequently analysed by X-ray microtomography. These were placed in glycerol in a plastic container that provided a tight fit and scanned in the QMUL MuCAT high definition scanner which uses a combination of long X-ray exposures, a time-delay integration readout CCD camera and advanced calibration techniques to enable accurate quantification of mineral concentration.

**Results:** HDMPs could be detected with several scanning MRI modalities, but the optimum contrast between HDMP and HAC was observed using dual echo steady state (DESS) sequence at 0.23 mm resolution. We found MRI evidence of HDMPs in 6/6 cadaveric hip samples 2/3 cadaveric knee joint samples and 2/3 osteoarthritis hip samples. HDMPs appear as focal regions of hypointensity within the high signal HAC. This is the first report of HDMPs in human knee joints. In one of the OA hip samples the presence of HDMPs was confirmed by X-ray microtomography.

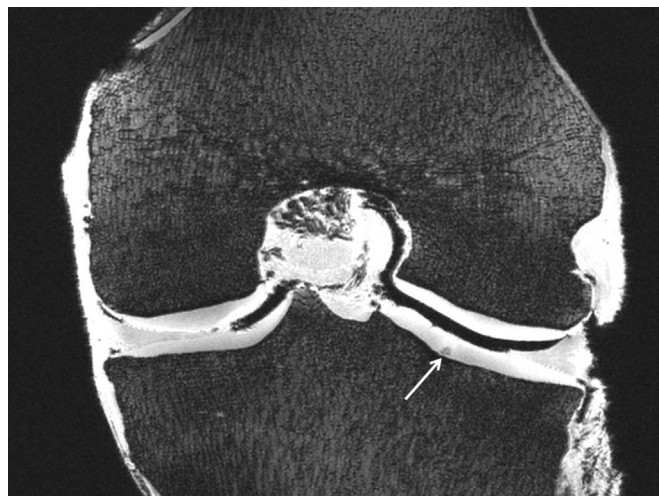

Fig. 1. MRI of human knee joint showing evidence of a HDMP (white arrow).

**Conclusions:** The results of this study suggest that HDMPs might be a common feature in ageing and degenerating weight bearing joints. The existence of these structures provides novel insights into the mechanism of joint destruction, highlighting the central role of micro-anatomical changes to the subchondral plate. HDMPs provide a novel imaging biomarker of joint destruction for diagnosis of joint disease and to monitor disease progression.

### 503 CHANGES IN EPIPHYSEAL BONE, SUBCHONDRAL BONE PLATE AND EPIPHYSEAL TRABECULAR BONE IN SURGICALLY AND CHEMICALLY INDUCED RAT MODELS OF OSTEOARTHRITIS

J. Morko, Z. Peng, J. Vääräniemi, K.M. Fagerlund, J.P. Rissanen, J. Bernoulli, J.M. Halleen. *Pharmatest Services Ltd, Turku, Finland*

**Purpose:** Several experimental animal models have been developed for human osteoarthritis (OA) and used to study the preclinical efficacy of disease and symptom modifying OA drug candidates. The preclinical efficacy has been determined by various microscopic scoring systems and joint pain assessments. The histopathology initiative of Osteoarthritis Research Society International (OARSI) has presented recommendations for OA assessment in order to standardize preclinical efficacy studies. Recommendations for rat samples include the histological analysis of cartilage degeneration and extracellular matrix (ECM) loss, osteophytes, calcified cartilage and subchondral bone, synovium, joint capsule, and growth plate. As subchondral bone has been identified to play an important role in the development and progression of OA, treatment effects on bone tissue have been studied even in more detailed. In this study, we performed a systemic characterization of epiphyseal bone, subchondral bone plate and epiphyseal trabecular bone together with the assessment of knee joint discomfort and pain and degenerative changes in articular cartilage and synovium in four rat OA models.

**Methods:** The study was conducted using male Lewis rats (body weight range 330–380 g). Unilateral OA was induced in their knee joints by applying the following models: 1) intra-articular injection of monoiodoacetate (MIA) at the dose of 1 mg, 2) medial meniscal tear (MMT) combined with medial collateral ligament transection (MCLT), 3) anterior cruciate ligament transection (ACLT) combined with partial medial meniscectomy (pMMx), 4) ACLT. Body weight and OA symptoms were followed in each model during the study. Knee joint discomfort and pain were used as the symptoms of OA. Knee joint discomfort was analyzed as static weight bearing using Incapacitance Tester and knee joint pain as static mechanical allodynia using von Frey monofilaments. Knee joints were harvested at two different time points in each model as follows: in the MIA model at 2 and 4 weeks, in the MMT + MCLT model at 3 and 6 weeks, in the ACLT + pMMx model at 4 and 8 weeks, and in the ACLT model at 5 and 10 weeks. The structure of epiphyseal bone, subchondral bone plate and epiphyseal trabecular bone were analyzed in coronal sections of medial tibial plateau followed by the histological OA assessment as recommended by the OARSI histopathology initiative. This experimental protocol was approved by National Animal Experiment Board, Regional State Administrative Agency for Southern Finland, Hämeenlinna, Finland.

**Results:** Knee joint discomfort was observed in operated hind limbs as decreased static weight bearing during the first week of the study. Knee joint pain was identified in operated and MIA-injected hind limbs as decreased paw withdrawal threshold during the first week and at the end of in-life phase of each model. In the rat MIA model, this knee joint pain was associated with mild synovial inflammation at 2 weeks, cartilage degeneration and ECM loss in superficial layer at 2 weeks and exacerbating down to intermediate layer at 4 weeks, and with the reduction in the amount of epiphyseal and subchondral bone. In the rat MMT + MCLT model, the knee joint pain was observed together with synovial inflammation, cartilage degeneration and the loss of ECM from superficial layer down to tidemark at 3 and 6 weeks, large osteophytes, and with the increased amount of epiphyseal and subchondral bone. In the rat ACLT + pMMx model, the pain of knee joint was identified in association with synovial inflammation, cartilage degeneration and ECM loss from superficial layer down to tidemark at 4 and 8 weeks, and with large osteophytes. In the rat ACLT model, the knee joint pain was associated with mild synovial inflammation, cartilage degeneration and the loss of ECM in superficial layer at 5 weeks and exacerbating down to deep layer at 10 weeks, osteophytes, and with the reduction in the amount of subchondral bone.

**Conclusions:** This study characterized changes in the structure of epiphyseal bone, subchondral bone plate and epiphyseal trabecular bone together with degenerative changes in articular cartilage and synovium, and knee joint discomfort and pain in four rat OA models. The amount of bone decreased in the rat OA models exhibiting from mild to moderate degenerative changes in articular cartilage, whereas the amount of bone remained unchanged or increased in the rat OA models exhibiting from moderate to severe degenerative cartilage changes. These results can be used to design studies for testing the preclinical treatment effects of OA drug candidates on articular cartilage, synovium, epiphyseal bone, and knee joint discomfort and pain.

### 504 COMMON GENES BETWEEN HUMAN AND RODENT OSTEOARTHRITIS CARTILAGE STUDIES SHOW LITTLE OVERLAP WITH AN INFLAMMATORY GENE-SET

A. Chanalaris. *Univ. of Oxford, Oxford, United Kingdom*

**Purpose:** We were interested to compare published gene sets of microarray studies on cartilage samples from rodent models of surgically induced, chemically induced and spontaneous osteoarthritis (OA). We also compare the datasets to published gene sets from human osteoarthritic cartilage, in order to determine genes that are dysregulated in osteoarthritis regardless of species and models used. Furthermore we were interested to identify which of those genes might be related with inflammation.

**Methods:** We used gene sets that adhered to the following criteria:

- 1) Was from pure cartilage or from samples enriched for cartilage
- 2) The species of origin was mouse, rat or human
- 3) We only preferred studies that have been deposited in a public database
- 4) We compared the datasets to a gene-set that was bioinformatically constructed to consider genes that are involved on the onset, resolution and response to inflammation. The study was gene centric, rather than probe centric and the genes mapping to the probes for each microarray was used for annotation purposes. For comparison of the different species, all genes were converted to the mouse ENTREZ gene ids. The common data sets were examined for gene ontology term enrichment and KEGG pathway enrichment.

**Results:** A high degree of overlap between the surgically and chemically induced OA models in rodents was observed. KEGG pathway analysis reveals that TGF beta pathway is the only pathway that is not over-represented in the chemically induced array.

In total we identify 75 genes that are common in more than 50% of the arrays. In this group of 75 genes only 7 appear to be present in the inflammatory gene-set ( $p > 0.05$ ). However, if single arrays are examined the probability mass function of the overlap with the inflammatory gene-set is always less than 0.05 and for some arrays as low as  $6.2 \times 10^{-14}$ . At the 4 weeks time point the probability mass function increased. 10 genes are present in more than 8 out of the 11 OA datasets studied with no inflammatory counterpart.

**Conclusions:** The cartilage response that leads to OA appears to follow a common transcriptional trajectory regardless of the insult that has caused it. Although inflammatory molecules produced by the cartilage are part of the OA response, a significant part of the transcriptional cartilage response appears to be independent to inflammation.

### 505 MCP-1-CCR2 LIGAND-RECEPTOR AXIS IN HUMAN CHONDROCYTE DEGRADATION AND DISEASE PROGRESS IN OSTEOARTHRITIS

X. Yuankun, Sr.. *Peking Univ., Beijing, China*

**Purpose:** To investigate the role of (OA).

**Methods:** Expression of the C-C chemokines monocyte chemo-attractant protein 1 (MCP-1), and its receptor CCR-2, was assessed in 16 OA patients and 6 normal controls, by reverse transcriptase-polymerase chain reaction (RT-PCR), enzyme-linked immunosorbent assay (ELISA) on MCP-1 stimulated chondrocytes, and the apoptosis of the chondrocytes was detected by flow cytometry. While, the Expression of the markers, collagen I, V, IX, XI and Matrix metalloproteinases (MMP), of chondrocyte degeneration was assessed by ELISA. Finally, as to estimate the essentiality of MCP-1-CCR2 ligand-receptor axis in induce and maintain the pathologic features of OA, the CCR-2 antagonist (RS102895) was used to block the animal model of OA in rats induced by