

## **Pneumonitis and Pulmonary haemorrhage after Acute Myocardial Infarction**

### **Case presentation**

A 55 year old hypertensive man developed chest pain while working on an off-shore oil station. ECG showed acute lateral ST elevation myocardial infarction. He was treated with tissue plasminogen activator-Tenectaplastase, low molecular weight Heparin and Aspirin. The ECG changes and chest pain completely resolved. He was transferred to our centre for coronary angiography on the same day. Prior to the procedure he was given Ticagrelor 180mg. Coronary angiogram (Fig1) showed severe thrombotic stenosis in a large obtuse marginal branch of the left circumflex artery and diffuse distal left anterior descending artery disease. 4000 IU Heparin and Tirofiban were administered and the stenosis in obtuse marginal artery was successfully treated with a 4.0x16mm drug eluting stent. Following the procedure he was treated with Aspirin 75mg OD and Ticagrelor 90mg BD. Later that day, he was also started on Bisoprolol 1.25 mg OD and Simvastatin 40 mg OD.

On day 2, he complained of productive cough and had low grade temperature of 38°C. Cardiovascular and respiratory examination was unremarkable. Chest X-ray showed clear lung fields (Fig2). Blood cultures were negative. An echocardiogram showed mildly impaired LV systolic function with a central pulmonic pressure of 42 mm Hg.

On day 3, he was started on Amoxicillin for suspected chest infection but with little symptomatic benefit. Over the following few days, he developed significant hypoxia (PaO<sub>2</sub> was 7.27 kPa on 5 litre O<sub>2</sub>), haemoptysis and bilateral lung crepitation. Clarithromycin was added to the treatment regime. Repeat chest X-ray showed bi-lateral hazy peri-hilar shadowing with some left basal pleural effusion.

A CT pulmonary angiogram was done on day 5 and this showed bi-lateral patchy ground-glass opacification in central distribution in keeping with inflammatory change and pulmonary haemorrhage (Fig3).

A repeat echocardiogram showed rapid rise in central pulmonic pressure to 70 mm Hg with no change in LV function. Haemoglobin fell from 153 g/l to 123 g/l. Prothrombin time was marginally prolonged at 13.2 sec (reference range 10-12.6 sec) but APTT was normal. C - reactive protein increased from 4 mg/l on day 1 to 293 mg/l on day 6. He was reviewed by the respiratory and renal teams. ANCA, Anti-nuclear and anti-glomerular basement membrane antibodies were negative and complements C3 and C4 were within normal limits. A diagnosis of pneumonitis and secondary pulmonary haemorrhage was made; Ticagrelor was suspected to be the cause.

Ticagrelor was replaced with Clopidogrel 75 mg/day. He was started on Prednisolone 60 mg/day at day 5. Over the course of following few days, the haemoptysis and SOB resolved. His clinical improvement was mirrored by improvements in the inflammatory markers (Fig 4). Chest X-ray changes progressively resolved with near complete resolution on day-15. He was discharged home on day 15, with a reducing course of Prednisolone for one month. After stopping his steroid regimen, he presented with recurrence of haemoptysis. CT chest revealed mild bronchiolitis pattern and a bronchoscopy was normal. A CT after 6 months was normal. He managed to continue on dual-antiplatelet therapy during this period without interruption. This is reported to the MHRA as a probable adverse effect of Ticagrelor.

## **Discussion**

This is a case report of a rare but a potentially life-threatening pneumonitis and pulmonary haemorrhage. Our patient was initially treated with thrombolysis and anti-coagulant therapy. The biological half-life of Tenecteplase is 65-132 minutes (1), Heparin is 60 minutes (2) and

Tirofiban is 9 hours. Hence, it seems unlikely that these agents have caused the pulmonary haemorrhage on day 3. The rapid improvement on steroids, and mild recurrence on steroid withdrawal, supports an immune mechanism for this complication. All other medications apart from Ticagrelor were continued further, suggesting that Ticagrelor as a possible causative agent. There has been one previous case report of Ticagrelor induced pulmonary haemorrhage, reported by Whitmore et al (3).

Dual anti-platelet therapy is routinely advised for patients with acute coronary syndrome. Studies from late 90's and early 2000 showed dual antiplatelet therapy to improve outcomes in patients undergoing percutaneous coronary intervention after acute myocardial infarction (4, 5), but has to be balanced against the potential bleeding risk.

Ticagrelor, a reversible and direct acting oral Adenosine Di-Phosphate receptor antagonist, is an anti-platelet agent used in the treatment of patients presenting with acute coronary syndrome. It was found to significantly reduce mortality and bleeding compared to Clopidogrel in the treatment of acute coronary syndrome in the multicentre randomised controlled PLATO trial (6). These favourable outcomes of Ticagrelor compared to Clopidogrel have been demonstrated in all ACS patients regardless of whether or not they have undergone PCI (7). Hence, Ticagrelor is currently the most widely used second anti-platelet agent used in this group of patients.

Pulmonary haemorrhage is a rare complication after acute myocardial infarction. The differential diagnosis of pulmonary haemorrhage may include pulmonary oedema, pneumonia and pulmonary embolism. Other causes of pulmonary haemorrhage include autoimmune conditions, infections (viral, fungal), other cardiac disorders (such as mitral stenosis), idiopathic pulmonary haemosiderosis, coagulopathy caused by drugs and diseases. Pulmonary haemorrhage secondary to drug reactions have been described with Amiodarone, Infliximab

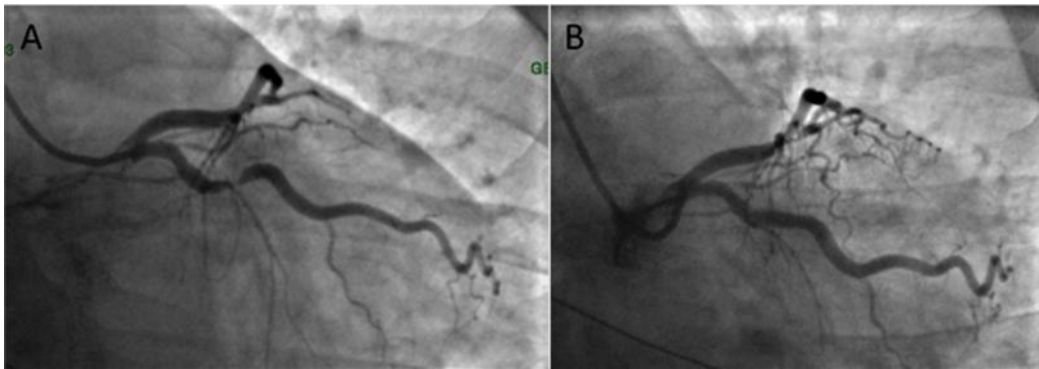
and Propylthiouracil. The symptoms, signs and X-ray changes of pulmonary haemorrhage are non-specific. Diagnosis is by CT imaging and broncho-alveolar lavage.

The natural history of this condition and success of steroid therapy if delayed are unclear. In the case report by Whitmore et al, the patient presented 10 days after starting treatment with Ticagrelor. He had more significant haemoptysis than our patient and this persisted even after replacing Ticagrelor with Clopidogrel. As a result of this, dual anti-platelet therapy was completely withdrawn and the patient underwent CABG. Lung biopsy at time of surgery showed alveolar septal wall fibrosis with inflammatory cell infiltrate indicating that this is a rapidly progressive condition.

In summary, pneumonitis and pulmonary haemorrhage are rare but serious adverse effects after myocardial infarction. Awareness among clinicians that Ticagrelor could cause this serious adverse effect could lead to early diagnosis. Steroid therapy is one potential avenue.

Figure 1: Coronary angiography-AP caudal image

- A) severe stenosis of the obtuse marginal artery
- B) after drug eluting stent insertion



Graph 1: Observations & blood results

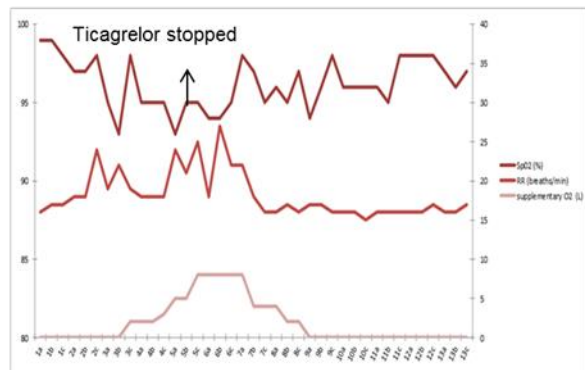
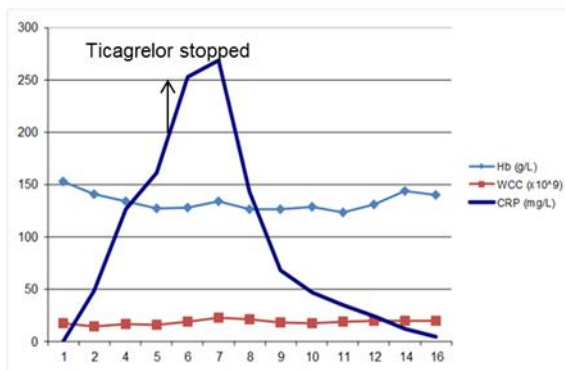


Figure 2: CTPA was performed which ruled out pulmonary embolism, but showed pulmonary haemorrhage and inflammation

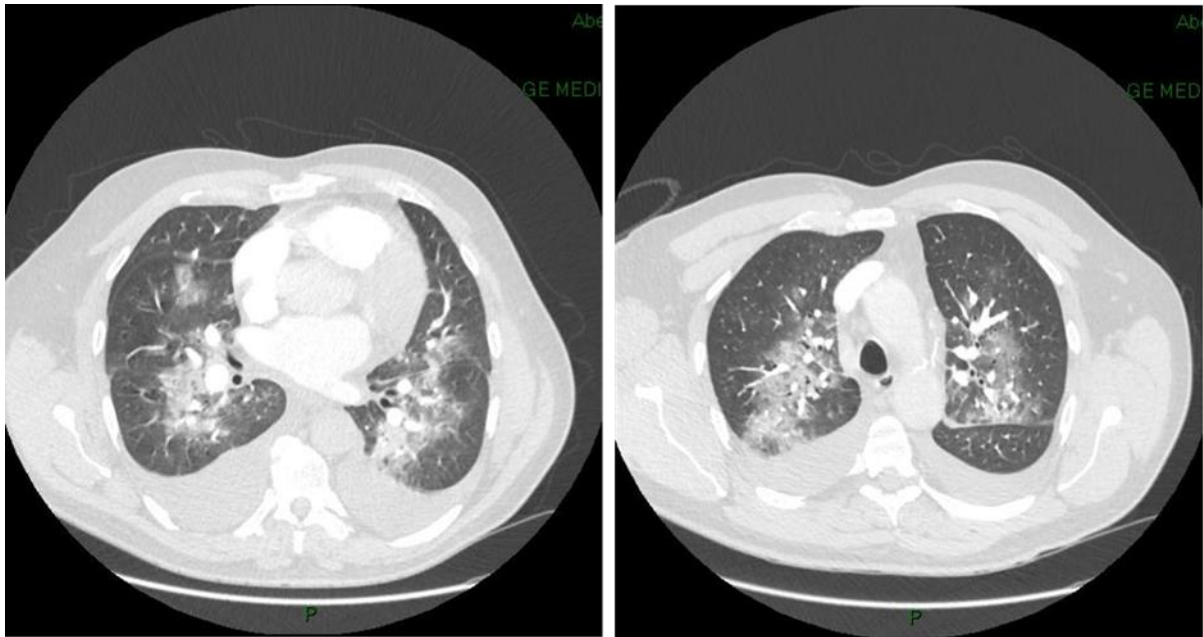
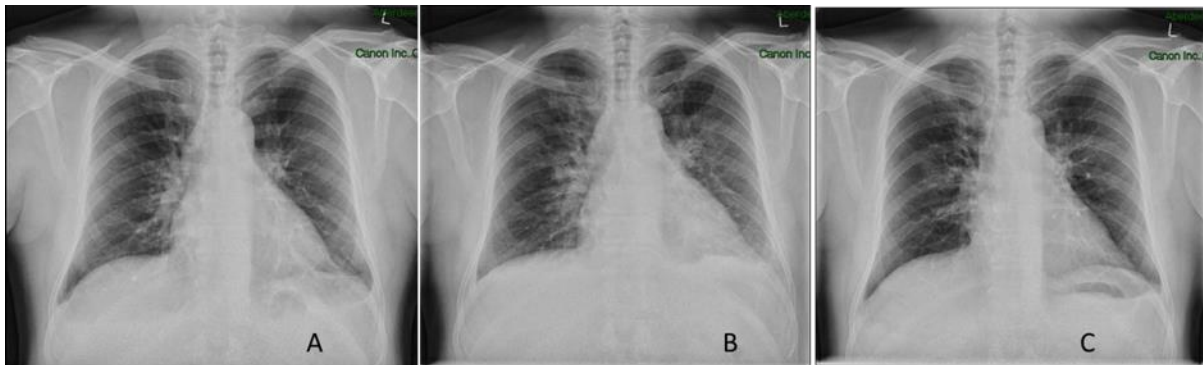


Figure 3: A) Day 2-showing largely clear lung fields; B) Day 4 showing hazy peri-hilar shadowing and small left pleural effusion C) Day 15 showing near complete resolution



## Bibliography:

- (1) Tanswell P, Modi N, Combs D, Danays T. Pharmacokinetics and pharmacodynamics of tenecteplase in fibrinolytic therapy of acute myocardial infarction. *Clin Pharmacokinet* 2002;41(15):1229-1245.
- (2) Hirsh J, Raschke R. Heparin and low-molecular-weight heparin: The Seventh ACCP Conference on Antithrombotic and Thrombolytic Therapy. *Chest* 2004;126(3 SUPPL.):188S-203S.
- (3) Whitmore TJ, O'Shea JP, Starac D, Edwards MG, Waterer GW. A case of pulmonary haemorrhage due to drug-induced pneumonitis secondary to ticagrelor therapy. *Chest* 2014;145(3):639-641.
- (4) Mehta SR, Yusuf S, Peters RJG, Bertrand ME, Lewis BS, Natarajan MK, et al. Effects of pretreatment with clopidogrel and aspirin followed by long-term therapy in patients undergoing percutaneous coronary intervention: The PCI-CURE study. *Lancet* 2001;358(9281):527-533.
- (5) Walter H, Neumann F-, Hadamitzky M, Elezi S, Müller A, Schömig A. Coronary artery stent placement with postprocedural antiplatelet therapy in acute myocardial infarction. *Coron Artery Dis* 1998;9(9):577-582.
- (6) Wallentin L, Becker RC, Budaj A, Cannon CP, Emanuelsson H, Held C, et al. Ticagrelor versus Clopidogrel in Patients with Acute Coronary Syndromes. *N Engl J Med* 2009 09/10; 2014/07;361(11):1045-1057.
- (7) Jneid H, Anderson JL, Wright RS, Adams CD, Bridges CR, Casey DE, et al. 2012 ACCF/AHA Focused Update of the Guideline for the Management of Patients With Unstable Angina/Non-ST-Elevation Myocardial Infarction (Updating the 2007 Guideline and Replacing the 2011 Focused Update) A Report of the American College of Cardiology Foundation/American Heart Association Task Force on Practice Guidelines. *Journal of the American College of Cardiology* 2012 August 14;60(7):645-681.

## Patient Perspective

At the time of my initial illness I considered myself to be a reasonably fit 55 year old who never smoked, tried to eat healthy and took a drink in moderation. I work in the offshore industry as a Training and Competency Supervisor so underwent regular medicals checks.

On Tuesday the 10/06/15 I was asleep offshore in my cabin on the Balmoral FPV but was awoken in a cold clammy sweat and felt a slight discomfort across my shoulders and upper chest. I initially thought that I needed to go and empty my bowels and after doing so returned back to bed. Unfortunately the discomfort did not subside so I eventually sought the attention of the medical team on board.

After initially being administered an aspirin and following an ECG the onshore duty Doctor confirmed that I had symptoms of a Heart attack so authorisation was given to administer me with the clot busting drug and morphine which was given in my right leg.

Around 10:30 am that very same day I was taken down to theatre and underwent the angioplasty procedure, I felt no pain and very little discomfort throughout this procedure. The Doctor who performed the procedure was very informative and advised me that my problem has been caused by the narrowing / blockage of a large and small artery on the back of my heart, and he was confident that the procedure had been successfully carried out to avoid any future reoccurrence.

Unfortunately over the next couple of days I developed a bit of a dry cough, suffered loss of voice and hoarseness and started to cough up small amounts of blood in my sputum. It felt as though I was starting to suffer from some form of chest infection and as time went on the blood in the sputum became more frequent. My chest felt as though it was rattling and I was bringing up more blood in my sputum and had difficulty breathing. I was prescribed antibiotics and eventually administered oxygen and put on a nebuliser to assist my breathing, the doctors came and went and I went through many tests over this period which did wear me down.

I can also recall the foul taste in my mouth and found I needed to regularly rinse my mouth with antiseptic mouthwash to relieve the taste.

My partner asked "what is the taste like" and I recall my reply was simply "death" as it was hard to describe.

I struggled to control my bodily functions and made a mess when using the bedside commode that was provided.

That evening I could not get comfortable and moved between the bed, a reclining chair and a hard upright chair in my endeavours to find some comfort and get some sleep.

I recall I sat in the hard upright chair wedged the bedside table in close to me so I could rest my elbows on it to support holding the nebuliser in my mouth, I dozed off for a few minutes and covered myself in Listerine which I had placed on the table.

I recall going for a chest scan on the Saturday morning and having to hold the nebuliser in place to support my breathing and wondering where this was going to end.

This was the morning I was examined by Dr Colin Miller a strait talking no nonsense guy to whom I have the greatest respect. Dr Miller examined me, during which I struggled to control my body functions and wet the bed. I was still having trouble breathing and was coughing up blood.

The Saturday night I did get a little sleep and on the Sunday morning I felt a slight improvement in my condition, although breathing was still laboured and there were still streaks of blood in my sputum.



By lunchtime a consultant had delivered the news to me that the testing for vasculitis had come back ok, at which stage my emotions broke down.

I had not really eaten since the Thursday and was constantly being encouraged to do so, although I continued to drink plenty of water so not to dehydrate.

Over the next days I feel like I gradually improved and was regularly visited by Dr Miller when doing his rounds.

On the 16/07/14 I finished the course of steroids, (Prednisolone), Calcichew D3 & Nystatin.

I was gradually increasing my stamina through exercise and walking and there were no signs of blood in my sputum. I did feel weak but gradually tried to build myself up again through regular daily walks.

I continued with my physio and regular exercise to increase strength and stamina however on 12/08/14 I went to see my GP to advise him of my concerns having had a small streaks of blood in my sputum. I felt as though I could relate this following on from a slight exertion and exercise but suffered no pain or breathlessness. I was advised again that this was just my body settling down to the trauma it had been through.

The following day on 13/08/14 I woke up and coughed up more blood in my sputum.

I was admitted to the Acute Medical Unit for a 2 nights stay and underwent a CT scan & X rays. The blood in the sputum subsided under rest.