



OPEN ACCESS

Images in cardiology

# Further insights into the syndrome of prolapsing non-coronary aortic cusp and ventricular septal defect

Akhlaque N Bhat<sup>1\*</sup>, Ahmad Sallehuddin<sup>1</sup>, Mohammad Riyas<sup>1</sup>, Reyaz Ahmad Lone<sup>1</sup>, Pawel Tyrsarowski<sup>1</sup>, Suresh Kumar<sup>1</sup>, Jiju John<sup>1</sup>, Pradeep Bhaskar<sup>1</sup>, Syed Zin<sup>1</sup>, Magdi H Yacoub<sup>2</sup>

## ABSTRACT

Ventricular septal defect (VSD) with prolapse of the right coronary cusp and aortic regurgitation can be managed surgically with the anatomical correction technique. However when the VSD is located underneath the non coronary cusp surgical management differs due to anatomical constraints and secondary pathological changes seen in the non coronary cusp. It is therefore important that the location of the VSD and the morphology of prolapsing cusp be characterised preoperatively in order to plan appropriate surgical repair. We present a case study in which we discuss the salient differences in the surgical management of the prolapsing right and the prolapsing non coronary cusps.

*Keywords:* aortic regurgitation, ventricular septal defect, aortic cusp prolapse, sinus of valsalva

<sup>1</sup>CCS Department, Section of Pediatric Cardiac Surgery, Hamad Hospital, Doha, Qatar

<sup>2</sup>Director Qatar Cardiovascular Research Centre, Doha, Qatar

\*Email: abhat@hmc.org.qa

<http://dx.doi.org/10.5339/gcsp.2013.11>

Submitted: 1 February 2012

Accepted: 6 March 2013

© 2013 Bhat, Sallehuddin, Riyas, Lone, Tyrsarowski, Kumar, John, Bhaskar, Zin, Yacoub, licensee Bloomsbury Qatar Foundation Journals. This is an open access article distributed under the terms of the Creative Commons Attribution license CC BY 3.0, which permits unrestricted use, distribution and reproduction in any medium, provided the original work is properly cited.

## INTRODUCTION

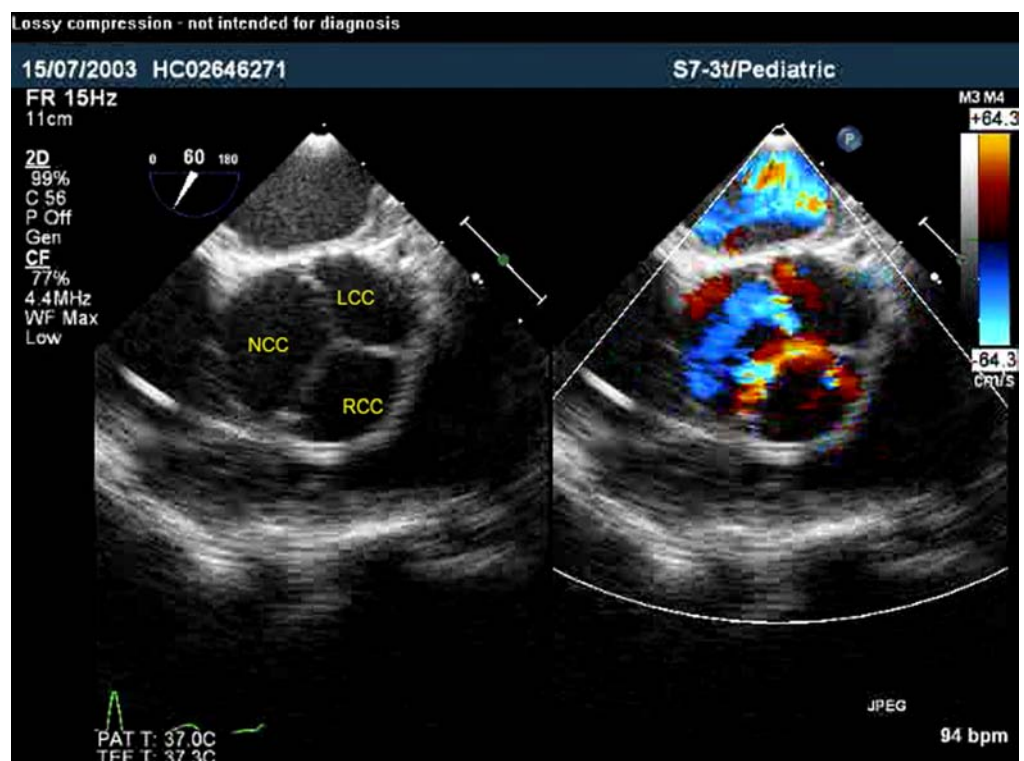
We have previously identified the lack of continuity between the ventricular septum and the aortic annulus as the salient pathological feature of the syndrome of prolapsing right coronary cusp, dilatation of the sinus of valsalva, and ventricular septal defect (VSD).<sup>1</sup> In keeping with this salient pathological feature, we devised a simple technique of anatomic correction that addressed all the components of the pathology. This consists of using a transaortic approach, closing the VSD with interrupted pledgeted sutures that elevate the crest of the septum to the aortic media, thus restoring the position of the aortic annulus and plicate the excessive tissue of the unsupported sinus of valsalva with the same sutures.

Management of patients whose VSD is located under the non coronary sinus has generally been ignored in literature. Characterisation of the cusp prolapsing into the VSD is important to determine the type of correction because prolapse of the non-coronary cusp is not amenable to anatomical correction.

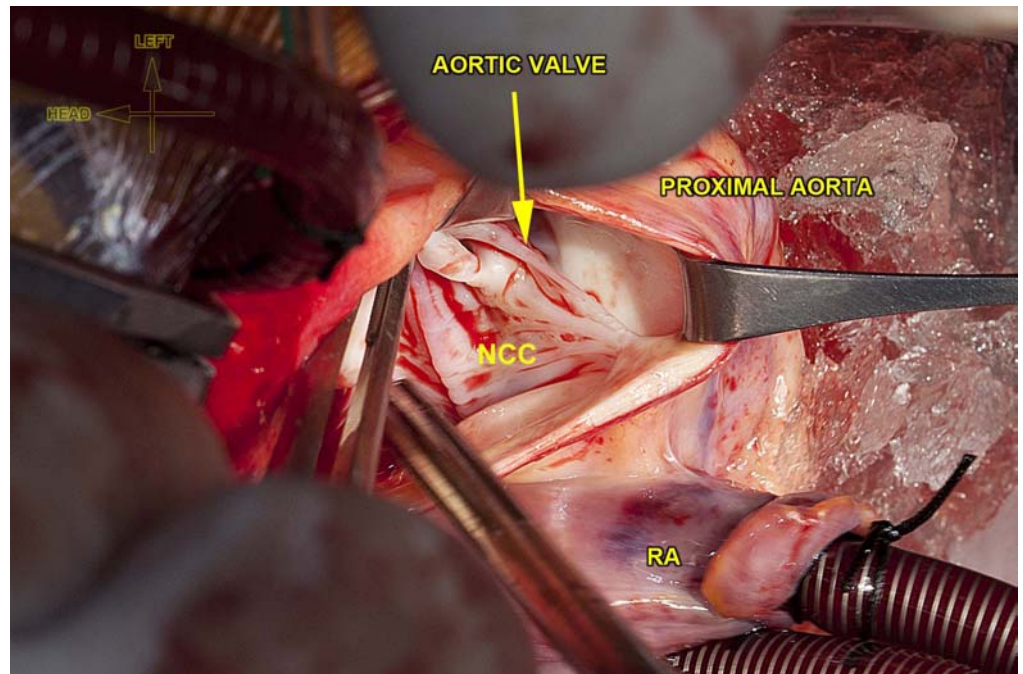
## CASE STUDY

We present the case of a male child in heart failure with NYHA class II symptoms, who weighed only 21 kilograms at 9 years of age. Echocardiography showed that he had a VSD located underneath the non-coronary aortic cusp with left-to-right shunt. He had significant prolapse of the non-coronary cusp, dilatation of the corresponding sinus of valsalva, and severe aortic regurgitation. The VSD shunt was restricted by the prolapsed cusp. His left ventricle was dilated but had preserved function. His mitral, tricuspid and pulmonary valves were normal and his right ventricular outflow tract was widely patent.

At operation the heart was significantly enlarged. Aortic valve was tricuspid. Non-coronary aortic sinus was significantly dilated and its corresponding leaflet had extensive secondary changes in the form of thickening, and a significantly redundant free margin. The commissure between the non-coronary cusp and the right coronary cusp was displaced down into the non-coronary aortic sinus. The adjoining free edge of the right cusp was also moderately thickened. A ventricular septal defect, shaped like a transverse oval, was located underneath the non-coronary cusp.

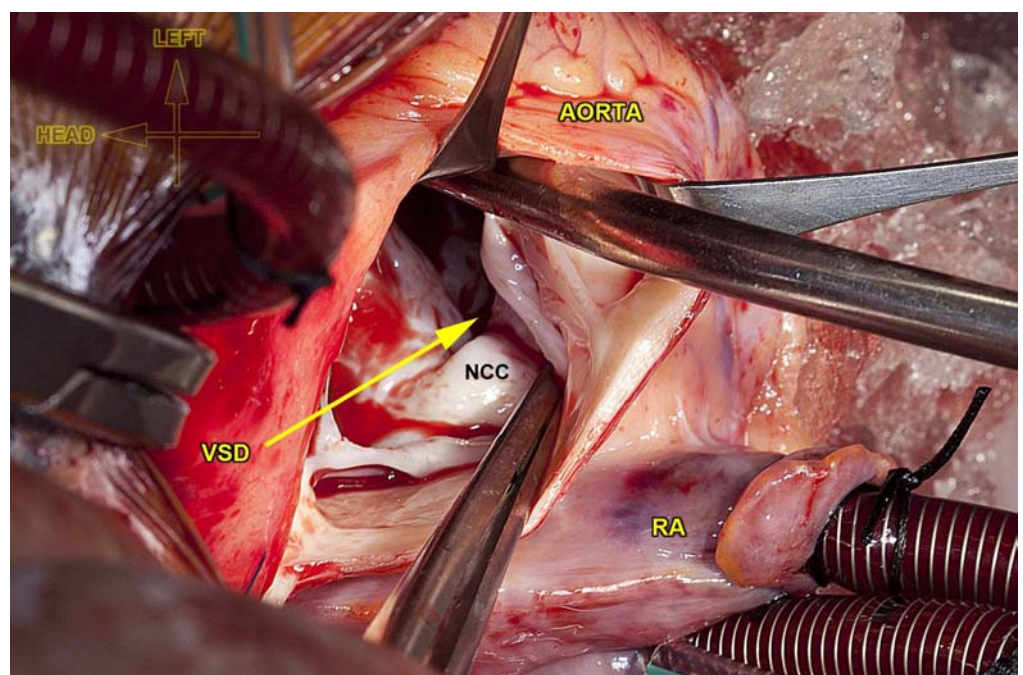


**Figure 1.** Short axis view of the aortic valve showing the dilated non coronary cusp (NCC), the right coronary cusp (RCC) and the left coronary cusp (LCC).

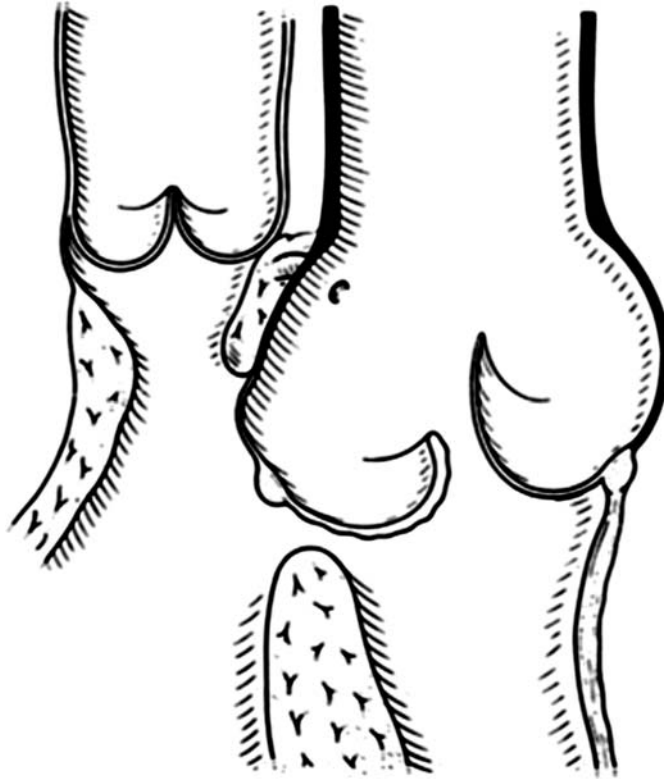


**Figure 2.** Operative photograph showing the redundant non coronary cusp (NCC). RA (*right atrium*)

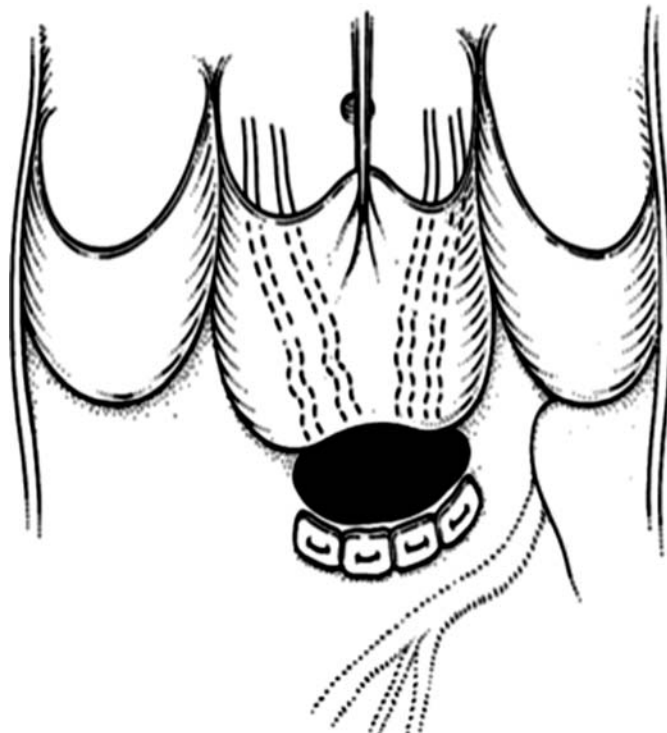
We attempted aortic valve repair by performing commissuroplasty that resuspended the non-right coronary commissure at its proper level and eliminated part of the redundant free margin of the non-coronary cusp. We performed additional plication of the free margin to accurately match the length of the free margins of the non coronary cusp with the other two cusps. A reasonably good final coaptation was achieved. The VSD was closed with a goretex patch using continuous prolene suture, taking care to safeguard the atrioventricular node. On removing the aortic cross clamp the left ventricle immediately dilated indicating severe aortic regurgitation. Cardioplegia was immediately re-administered directly



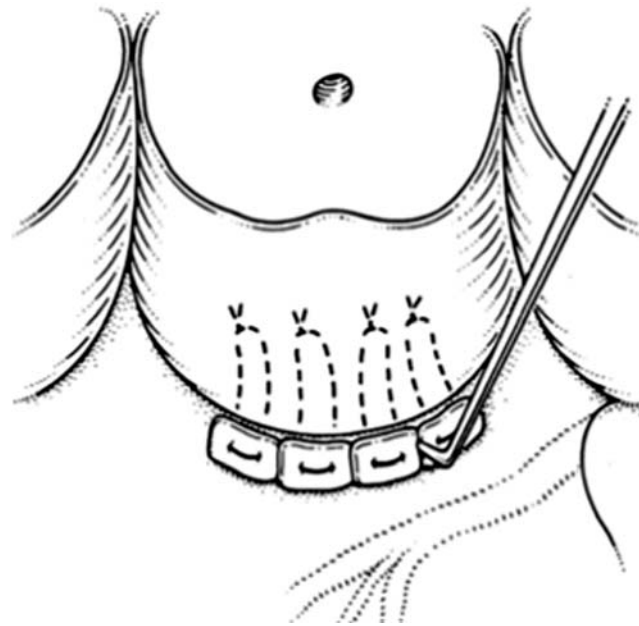
**Figure 3.** Operative photograph showing the non coronary cusp (NCC) retracted with a forceps revealing the ventricular septal defect (VSD) underneath it. RA (*right atrium*)



**Figure 4.** Cartoon showing discontinuity between the aortic media and the ventricular septal crest. (With permission *J Thorac Cardiovasc Surg* 1997;113:253–261.)



**Figure 5.** Cartoon depicting interrupted pledgeted sutures taken through the ventricular septal crest and into the right coronary cuspas placating sutures before finally being tied down in the right coronary sinus. (With permission *J Thorac Cardiovasc Surg* 1997;113:253–261.)



**Figure 6.** Cartoon depicting the final repair with the sutures tied down causing obliteration of the ventricular septal defect and plication of the right coronary aortic sinus. (With permission *J Thorac Cardiovasc Surg* 1997;113:253–261.)

into coronary ostia, and cardiac standstill was achieved. We replaced the aortic valve by performing a Ross procedure using the root replacement technique. Right ventricular outflow tract was reconstructed with a pulmonary homograft. The child made an uneventful recovery and was discharged home on the seventh post-operative day.

### LESSONS LEARNT

Preoperative characterisation of the prolapsing cusp is important to plan repair in patients with VSD, aortic valve prolapse and aortic regurgitation. In patients whose VSD is located underneath the non coronary sinus, the atrioventricular node is in close proximity to the non-coronary cusp and is therefore extremely vulnerable to damage if direct closure of the VSD is undertaken. Also, the non-coronary cusp is extensively involved by secondary pathological changes which diminish the chances of a successful repair. In our patient, patch closure of the VSD and failure to simultaneously plicate the non coronary sinus added to the redundancy of tissues of the non-coronary sinus. This resulted in failure to restore the normal position of the aortic annulus and caused severe aortic regurgitation.

Early diagnosis of this disease and clear delineation of aortic valve prolapse and aortic regurgitation can be easily achieved with transthoracic echocardiography. Close follow-up is important to diagnose the onset of aortic valve prolapse. As soon as the aortic valve shows signs of prolapse the patient should be referred for repair before the onset of significant aortic regurgitation. Late diagnosis in our patient contributed significantly to the severity of his aortic regurgitation.

Finally, a Ross procedure can easily be performed in this group of patients in spite of the presence of significant pathology in the region of the right ventricular outflow tract and pulmonary valve.

### REFERENCE

- [1] Yacoub MH, Khan H, Stavri G, Shinebourne E, Radley-Smith R. Anatomic correction of the syndrome of prolapsing right coronary aortic cusp, dilatation of sinus of valsalva, and ventricular septal defect. *J Thorac Cardiovasc Surg.* 1997;113:253–261.