



University of Dundee

Variaciones anatómicas del sistema venoso ácigos

Dahran, Naief; Soames, Roger

Published in:

International Journal of Morphology

DOI:

[10.4067/S0717-95022016000300051](https://doi.org/10.4067/S0717-95022016000300051)

Publication date:

2016

Document Version

Publisher's PDF, also known as Version of record

[Link to publication in Discovery Research Portal](#)

Citation for published version (APA):

Dahran, N., & Soames, R. (2016). Variaciones anatómicas del sistema venoso ácigos: Clasificación y relevancia clínica. *International Journal of Morphology*, 34(3), 1128-1136. DOI: 10.4067/S0717-95022016000300051

General rights

Copyright and moral rights for the publications made accessible in Discovery Research Portal are retained by the authors and/or other copyright owners and it is a condition of accessing publications that users recognise and abide by the legal requirements associated with these rights.

- Users may download and print one copy of any publication from Discovery Research Portal for the purpose of private study or research.
- You may not further distribute the material or use it for any profit-making activity or commercial gain.
- You may freely distribute the URL identifying the publication in the public portal.

Take down policy

If you believe that this document breaches copyright please contact us providing details, and we will remove access to the work immediately and investigate your claim.

Anatomical Variations of the Azygos Venous System: Classification and Clinical Relevance

Variaciones Anatómicas del Sistema Venoso Ácigos: Clasificación y Relevancia Clínica

Naief Dahran,^{*,**} & Roger Soames*

DAHRAN, N. & SOAMES, R. Anatomical variations of the azygos venous system: Classification and clinical relevance. *Int. J. Morphol.*, 34(3):1128-1136, 2016.

SUMMARY: The azygos venous system is highly variable in terms of its origin, course, communications, tributaries and termination of the associated veins: this study aimed to classify these anatomical variations. Thirty Thiel-embalmed cadavers aged 48–98 years (18 female, 12 male) were examined. The vertebral level of termination and diameter of the azygos, hemiazygos, accessory hemiazygos and the left superior intercostal veins were determined, as well as the termination level of the right superior intercostal vein. The azygos system was classified into 3 types; primitive (type 1), transitional (type 2) and unicolumnar (type 3). Type 2 was further divided into 5 subgroups (A to E) according to the number of retroaortic communications. Type one was observed in 3 % (n=1), type 2 in 87 % (n=26) and type 3 in 10 % (n=3) of specimens. The vertebral level of termination of the azygos, hemiazygos, accessory hemiazygos, right superior intercostal and left superior intercostal veins were between T2 and T3, T6 and T10, T5 and T9, T2 and T4, and T2 and T4 respectively. Identification and understanding these variations are important during preoperative radiological investigations and surgical procedures, especially spinal surgery between T7 and T12 using a left thoracotomy approach, to avoid injuries which may lead to postoperative hematomas.

KEY WORDS: Azygos; Hemiazygos; Retroaortic communications; Thiel-embalmed cadavers; Variations.

INTRODUCTION

The azygos system is formed by veins which drain the thoracic cage and some contents of the posterior mediastinum into the superior vena cava (SVC) (Tatar *et al.*, 2008). It lies anterior to the bodies of the thoracic vertebrae and consists of three interconnected major veins the azygos (AV), hemiazygos (HV) and accessory hemiazygos (AHV) veins (Drake *et al.*, 2005; Snell, 2004).

The AV is embryologically derived from the right azygos line, originating caudally from the union of the right subcostal and right ascending lumbar veins (Shin & Ho, 1999; Standring, 2008). It ascends cranially draining the lower eight right posterior intercostal veins (RPIVs) into the superior vena cava at the level of T3 (Snell). Along its course it receives the HV, AHV, mediastinal, pericardial, oesophageal, right bronchial and right superior intercostal veins (Drake *et al.*; Snell). The hemiazygos system (HV and AHV), together with the left superior intercostal vein, drains the lower eight left posterior intercostal and upper four left posterior intercostal veins (LPIVs) into the azygos and left

brachiocephalic veins, respectively (Dahran & Soames, 2015). The azygos venous system also connects the inferior vena cava (IVC) to the SVC. Thus, it has the ability to drain the lower half of the body into the SVC when the IVC is obstructed (Dudiak *et al.*, 1991).

The anatomical organisation of the azygos system is highly variable in terms of its origins, tributaries and levels of termination (Kutoglu *et al.*, 2012; Ozbek *et al.*, 1999). Several studies (Seib, 1934; Falla *et al.*, 1963; Anson & McVay, 1984; Kutoglu *et al.*; Tatar *et al.*) have therefore stressed the importance of its classification; however this is quite controversial to date. It is important for clinicians to know the types of variation and normal diameter of the constituent vessels before addressing abnormal conditions, as any abnormality of the system can be misdiagnosed as an aneurysm, mediastinal tumor or enlarged lymph node (Celik *et al.*, 1996). The azygos system also acts as a metastatic pathway to the lungs (Piciucchi *et al.*, 2014). The aim of the current study was therefore to investigate further the

* Centre for Anatomy and Human Identification, School of Science and Engineering, University of Dundee, Dundee, DD1 5EH, UK.

** Department of Anatomy, College of Medicine, University of Jeddah, Jeddah, Kingdom of Saudi Arabia.

anatomical variations of the azygos venous system and classify these into types, as well as assess their clinical importance.

MATERIAL AND METHOD

Thirty Thiel-embalmed cadavers, which had been previously subjected to educational dissection by human anatomy, forensic anthropology and medical students, were examined. Eighteen cadavers were female and 12 male, with an age range of 48 to 98 years (mean 81.3 ± 12.4 years). This study was undertaken in the Centre for Anatomy and Human Identification (CAHID), University of Dundee, Scotland.

The lungs, heart, thoracic aorta and oesophagus were carefully removed, followed by the parietal pleura thereby exposing the AV, HV, AHV and thoracic duct. The diaphragm was depressed to reveal the origin of the AV and HV. The azygos system was then cleaned. Three colored pins were inserted into the anterior surface of the thoracic vertebrae: a green pin into T12, a white pin into T8 and a red pin into T5 (Fig. 1). Photographs were taken and a schematic drawing made of each specimen.

Sections of the origin and termination of the AV and HV, as well as the terminations of the AHV and the right and left superior intercostal veins were taken and placed onto wet foil to avoid stretching. Using calipers, the circumference (C) of each section was determined as shown in Fig. 2, from which the vessel diameter (D) was calculated using the formula $D=C/\pi$. All measurements were recorded in millimeters (mm). This technique was found to be useful in determining the diameter of blood vessels from cadavers, which are not necessarily cylindrical.

Using the classification of Anson & McVay and the schematic drawings of the specimens, the azygos system was classified into one of three types: primitive (type 1), transitional (type 2) and unicolumnar (type 3). The primitive type consisted of two longitudinal azygos lines with no connections between them. The transitional type was further subdivided into five groups according to the number of the retroaortic communications in the azygos venous system: group A had one communications, group B two communications, group C three communications, group D four communications and group E five or more communications. The unicolumnar type consisted of a single vein located in the midline draining the posterior intercostal veins from both sides. Following classification schematic drawings were made of each type and subgroup.

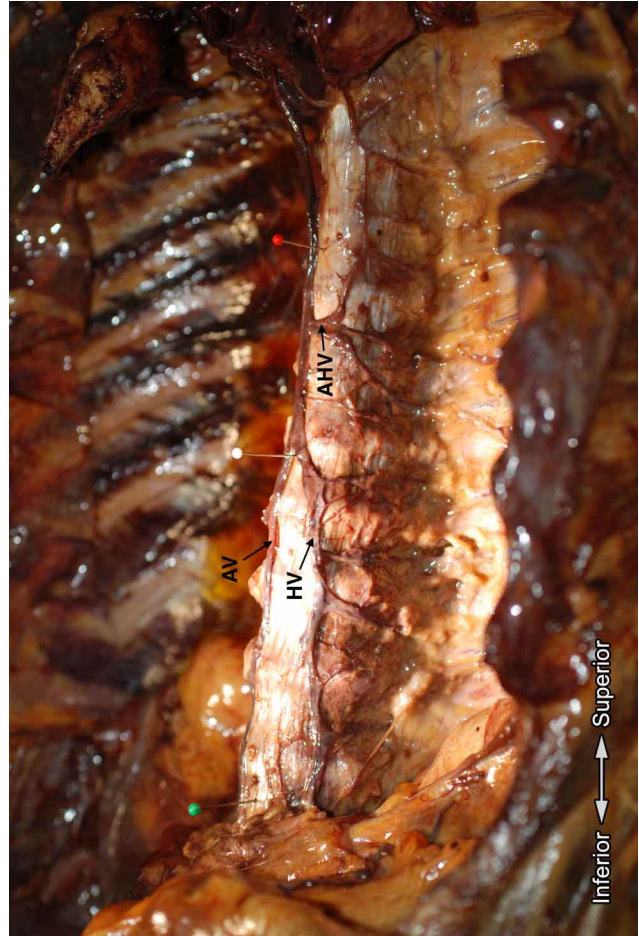


Fig. 1. Pins indicating the vertebral levels T12 (green), T8 (white) and T5 (red). AV, Azygos vein; HV, Hemiazygos vein; AHV, Accessory hemiazygos vein.

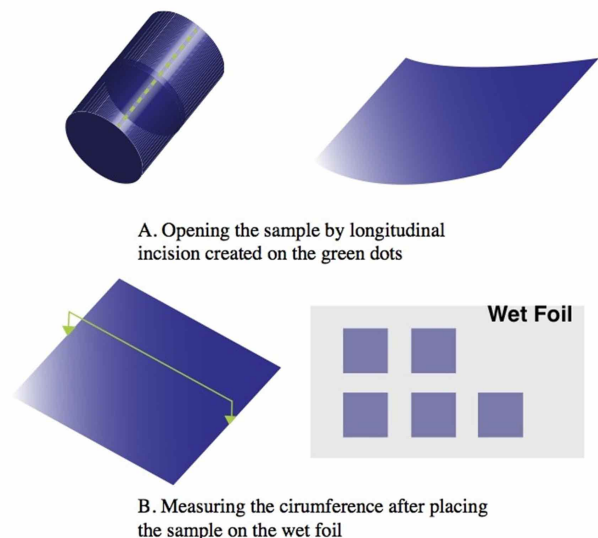


Fig. 2. The technique of measuring the circumference of a vein.

RESULTS

Type 1 was observed in one cadaver (3 %) in which there were two longitudinal veins with no communications between them (Fig. 3). The right vein drained into the SVC, while the left drained into the left brachiocephalic vein. This type may be considered a primitive type as the two longitudinal veins appear to be similar to the azygos lines present during development.

Type 2 was observed in 26 cadavers (87 %), being the most commonly observed type in the current study: these were divided into five subgroups depending on the number of retroaortic communications. Type 2A was present in 3 cadavers (12 %), type 2B in 9 cadavers (35 %), type 2C in 7 cadavers (27 %), type 2D in 4 cadavers (15 %) and type 2E in 3 cadavers (12 %) (Fig. 4a-e). Type 2B was the most common consisting of two communications between the right (AV) and left sides (HV and AHV).

In type 2A, the communicating vein between both sides of the azygos venous system was the HV: in two cadavers the AHV drained into the HV at either T6 or T7. In the third type 2A cadaver a longitudinal vein connected to the left superior intercostal vein, which then descended to drain the 4th to 9th left posterior intercostal veins terminating by joining the HV at the level of T10–T11 after crossing anterior to the 10th left posterior intercostal vein: this longitudinal vein can be considered an AHV draining into the HV. Type 2E consisted of cadavers with five or more retroaortic communications: in 2 cadavers there was a plexus on the surface of the vertebral bodies (Fig. 5).

Three type 3 variations were observed in which the AV and HV united to form a single vein located in the midline draining the right and left posterior intercostal veins into the SVC. The single vein began at the level of T9 in two cadavers and at T8 in the third (Fig. 6). This type might also include the HV, as in the three cases observed.

This study confirmed that the more communications between the right and left sides of the azygos system, then the larger the diameter of the AV at its termination. In type 2, subgroup E had the largest mean diameter and subgroup A the smallest: a positive correlation was observed between the number of communications and diameter of the AV termination (Fig. 7).

The mean diameter of the AV at its origin and termination was 2.14 ± 0.39 mm and 6.21 ± 1.36 mm, respectively, with the diameter at the termination almost three times larger than its origin. The mean diameter of the HV at

its origin and termination was 1.55 ± 0.64 mm and 3.23 ± 1.24 mm respectively, with the diameter at the termination approximately twice as large as its origin. The mean diameter of the AHV termination was 1.91 ± 1.02 mm. The origin of the AHV was highly variable as it was formed at different levels from the union of the posterior intercostal veins and often communicated with the left superior intercostal vein. Table I shows the mean diameters of the origin and termination of each vein of the azygos system.

There was a significant positive correlation between the diameters of the AV and HV at their origins ($r = 0.51$), but a negative correlation between the diameters of the AV origin and AHV termination ($r = -0.487$). There were no other significant correlations between the diameters of the azygos venous system. In addition, there were no correlations between gender and the diameters of the veins that form the azygos venous system (Table II).

The AV drained the eight lower right posterior intercostal veins in 30 % of cadavers, with its termination observed to be between T2 and T3. In 47 % of cadavers the AV terminated at the level of T3, in 30 % at T2 and in 20 % it was between T2 and T3.

The HV drained the lower four left posterior intercostal veins in 33 % of cadavers, with its termination being between T6 and T10. In 33 % of cadavers, the HV terminated at T8, in 17 % at T7, in 17 % between T9–T10, in 10 % at T9 and in 7 % T6–T7.

The termination of the AHV was between T5 and T9: in 27 % it terminated at T5, in 20 % at T6, in 17 % at T7, in 7 % between T7–T8 and in 7 % at T8.

The right superior intercostal vein drained the upper four right posterior intercostal veins into the AV in 30 % of cadavers. Its termination was observed to be between T2 and T4: in 30 % of cadavers it was at T4, in 27 % at T3, in 10 % between T2–T3 and in 3 % between T3–T4.

In 53 % of cadavers the left superior intercostal vein communicated with the azygos system, either directly without communicating with the AHV (7 % of cadavers) or via the AHV with or without communicating with the AV (46 % of cadavers): it drained into the left brachiocephalic vein in all cadavers. The HV and AHV also communicated with each other in 10 cadavers (33 %), with the communicating veins running either longitudinally or obliquely. The termination of the left superior intercostal vein was between T2 and T4: in 27 % of cadavers it was at T2, in 23 % at T3, in 13 % at T4 and in 10 % between T2–T3. Table III shows the termination levels of the azygos venous system.

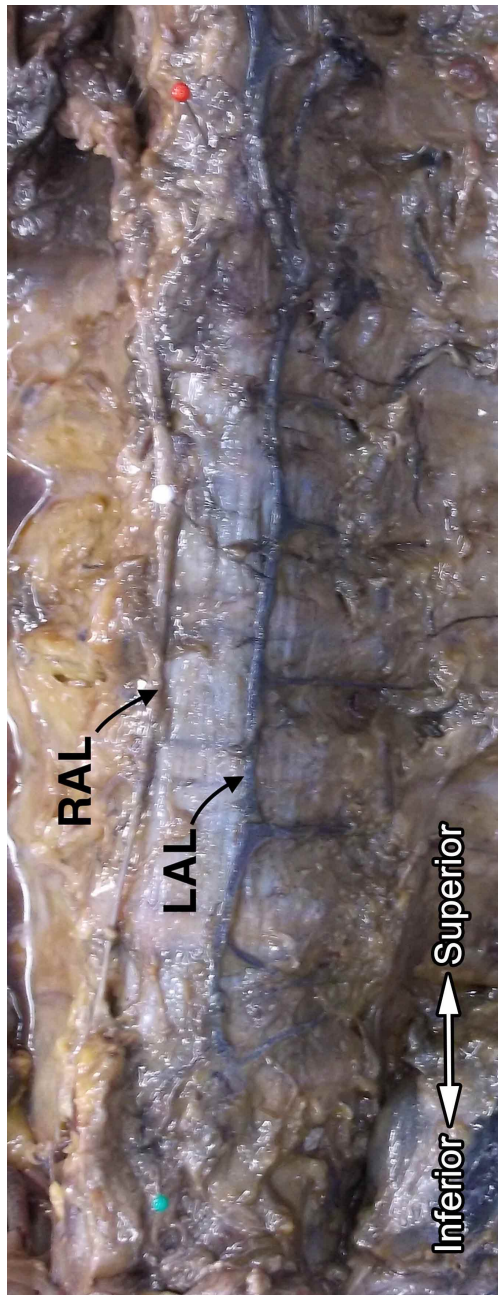


Fig. 3. Type 1 of the azygos venous system showing right and left longitudinal veins (RAL and LAL) with no retroaortic communications between them.

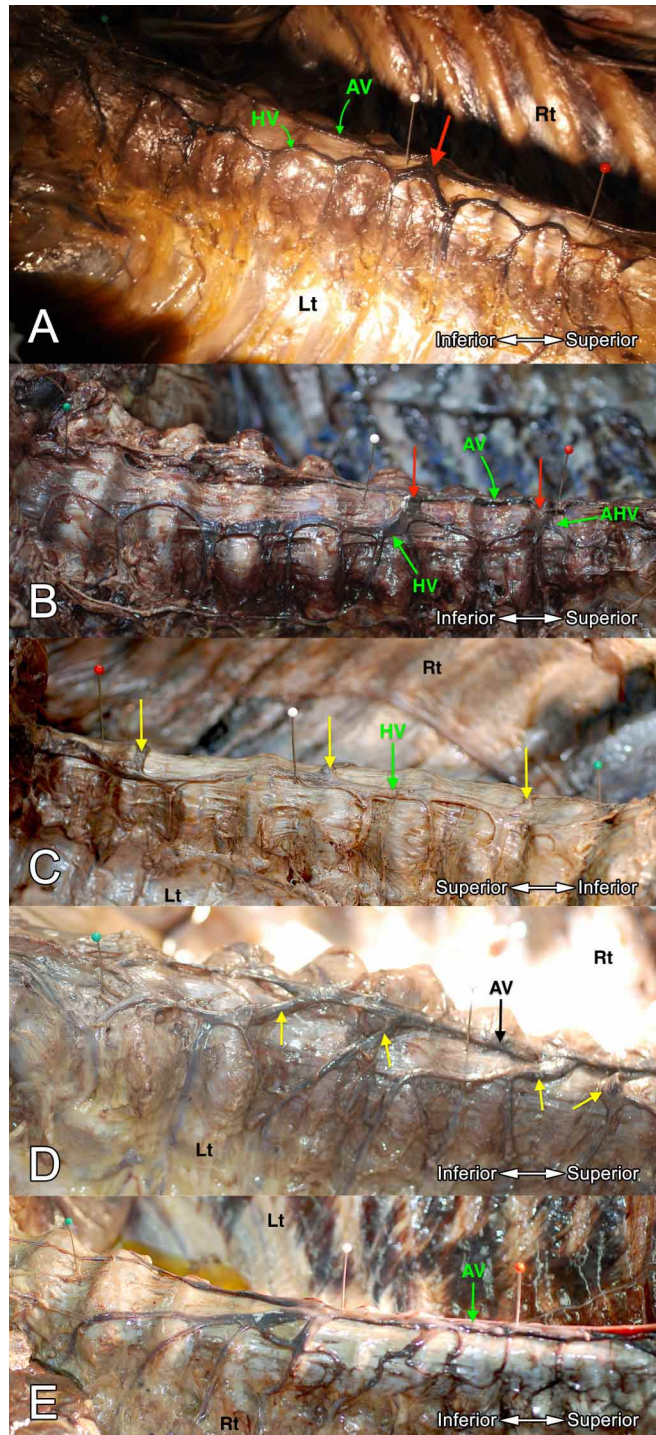


Fig. 4. A. Type 2A with one retroaortic communication (HV, red pin) at the level of T7-T8. AV, Azygos vein. B. Type 2B with two retroaortic communications at the levels of T7 (HV) and T5 (AHV). Red pins are at the sites of communication. AV, Azygos vein. C. Type 2C with 3 retroaortic communications at different levels (right side view). Yellow pins are at the sites of communication. AV, Azygos vein. D. Type 2D with four retroaortic communications at different levels. Yellow pins are at the sites of communication. AV; Azygos vein. E. Type 2E with five or more retroaortic communications. These communications drain the left posterior intercostal veins through a venous plexus located on the lateral aspect of the vertebral column. AV, Azygos vein.

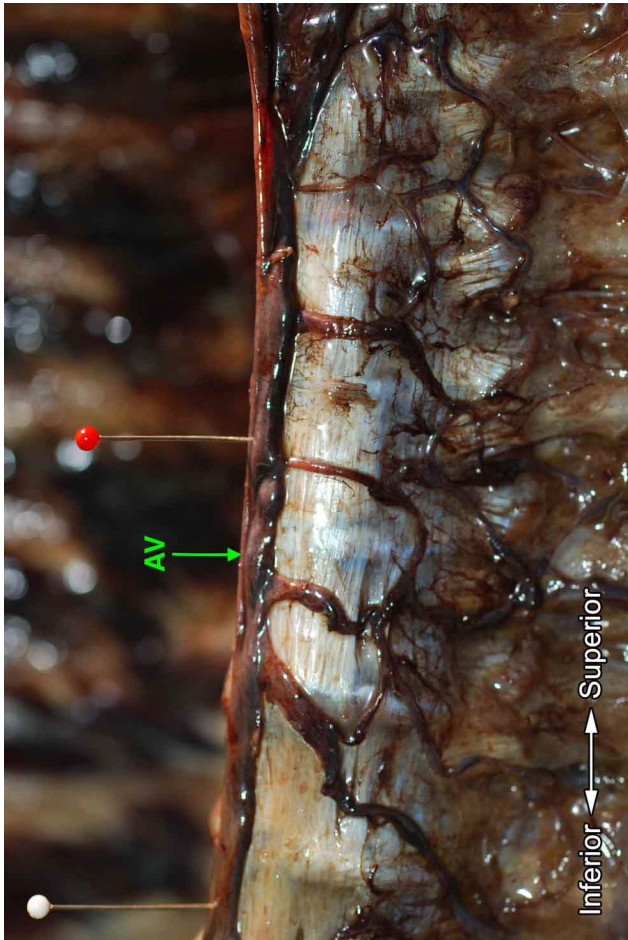


Fig. 5. Type 2E with more than five retroaortic communications draining the left posterior intercostal veins after forming a plexus on the lateral aspect of the vertebral column. AV, Azygos vein.

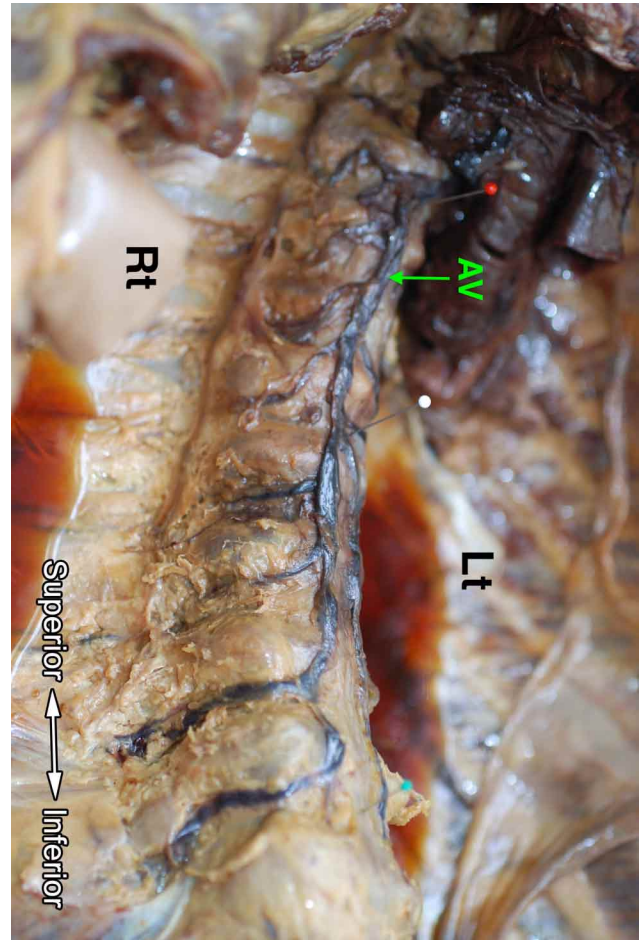


Fig. 6. Unicolumnar vein located in the midline starting at the level of T8. Below this level the AV and HV drained the right and left posterior intercostal veins respectively. AV, Azygos vein.

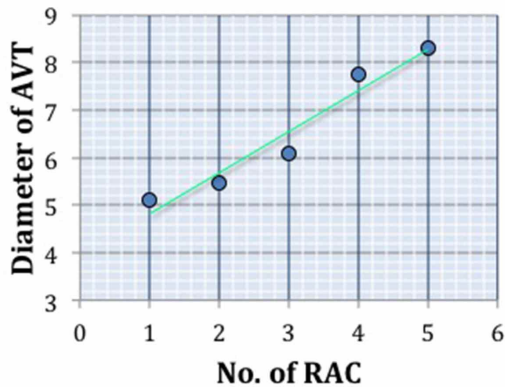


Fig. 7 Correlation between the number of retroaortic communications (RAC) (horizontal axis) and the mean diameter of the AV termination (AVT) (vertical axis) in type 2 variations of the azygos system.

Table I. The diameters of the azygos vein (AV), hemiazygos vein (HV) and accessory hemiazygos vein (AHV) at various levels: all measurements in mm.

	N	Minimum	Maximum	Mean	SD*
AV Origin	27	1.21	3.05	2.14	0.39
AV Termination	30	3.94	8.87	6.21	1.36
HV Origin	27	0.23	2.82	1.55	0.64
HV Termination	30	1.52	6.44	3.23	1.24
AHV	22	0.79	4.47	1.91	1.02

*N = number; SD = standard deviation

Table II. Correlations between various diameters of the azygos vein (AV), hemiazygos vein (HV) and accessory hemiazygos vein (AHV).

	AV Origin	AV Termination	HV Origin	HV Termination	AHV Termination
AV Origin	1				
AV Termination	-0.370	1			
HV Origin	0.510**	-0.468	1		
HV Termination	-0.027	0.320	-0.184	1	
AHV Termination	-0.487*	0.137	-0.096	0.158	1

* Significant at the 0.05 level (2-tailed).

** Significant at the 0.01 level (2-tailed).

Table III: Termination levels of the azygos venous system.

Thoracic vertebral level	Frequency AV.T*	Frequency HV.T*	Frequency AH.T*	Frequency RSIV.T*	Frequency LSIV.T*
T2	9			1	8
T2-T3	6			3	3
T3	14			8	7
T3-T4				1	1
T4				9	4
T5			8		
T6		1	6		
T6-T7		2	0		
T7		5	5		
T7-T8		1	2		
T8		10	2		
T8-T9		1	1		
T9		3	1		
T9-T10		5			
T10		1			
Not determined	1	1	5	9	7
Total	30	30	30	30	30

*AV.T = azygos vein termination; HV.T = hemiazygos vein termination; AH.T = accessory hemiazygos vein termination; RSIV.T = right superior intercostal vein termination; LSIV.T = left superior intercostal vein termination

DISCUSSION

The azygos system is highly variable with each vein exhibiting variations in its origin, course and termination: the tributaries of each vein are also variable. These variations are believed to occur during development. The AV may have one or more origins, but usually drains the lower eight right posterior intercostal veins directly, as well as the right superior intercostal vein, which in turn drains the four upper right posterior intercostal veins.

Anson & McVay classified 100 azygos systems into 3 types and 11 groups. The first type they called the primitive or embryological type, which consisted of two vertical veins

not connected to each other: this type had only 1 group. The second type was the transition type that consisted of retroaortic anastomoses connecting the azygos and hemiazygos systems: this type had subgroups 2 to 10. The third type had a single azygos vein located in the midline and consisted of 1 group only. These 11 groups were classified according to the vertical alignment and horizontal communications of the azygos venous system. Falla *et al.* also classified the azygos venous system of 100 cadavers into 11 groups. In their study, Anson & McVay reported one case (1 %) of type 1, 98 cases (98 %) of type 2 and one case (1 %) of type 3.

Earlier, Seib studied 200 cadavers and classified them into the same main types, but refer to them as double column, transitional and single column types: these types consisted of 21 groups. One to two percent of cadavers were found to be of the embryological type and classified as type 1, with the single column type observed in 5 %.

Kutoglu *et al.* used the classification of Anson & McVay in their study and observed type 1 in one cadaver (2.1 %), type 2 in 44 cadavers (91.7 %) and type 3 in one cadaver (2.1 %). In addition, two specimens did not match any of Anson and McVays classification groups and were considered to be 'atypic' with four retroaortic anastomoses.

In the current study of 30 cadavers, the azygos venous system was classified using Anson & McVay's three types: primitive (type 1), transitional (type 2) and unicolumnar (type 3), with type 2 further subdivided into five groups depending on the number of retroaortic anastomoses between the right and left azygos lines. Table IV summarises the findings of studies used the same classification. Compared to Anson and McVay & Kutoglu *et al.* this classification is simpler, furthermore the atypic cases of Kutoglu *et al.* are included in type 2D.

Kutoglu *et al.* reported no relationship between age or gender and azygos system variations. However, a relationship between type 2C and gender was observed in the current study, with six of the seven cadavers being female. It is accepted that this occurrence might be incidental; nevertheless it is worthy of mention. There was no relationship with age.

In one type 2A a long vein was observed to communicate with the left superior intercostal vein and then descend to receive tributaries from the 4th to 9th left posterior intercostal veins: it terminated by joining the HV at the level of T10-T11 after crossing anteriorly to the 10th left posterior intercostal vein. This long vein can be considered to be an AHV draining into the HV. This observation has not previously been reported.

In two type 2E cadavers the number of small retroaortic communications was more than five forming a

plexus on the surface of the vertebral bodies. This observation has also not been previously reported.

Although the veins collapse in Thiel embalmed cadavers the technique used in this study to determine vessel diameter is considered to be useful in obtaining accurate data. In the current study the mean diameter of the AV termination was 6.21±1.36 mm, which is significantly less than that (8.5±1.26 mm) reported by Kutoglu *et al.*

In the current study the mean diameter of the AV termination was approximately three times greater than its origin. Kutoglu *et al.* reported a difference of two times, while Tatar *et al.* report it to be four times. With respect to Kutoglu *et al.* and Tatar *et al.* the differences might be due to the number of specimens examined and/or the methods of measurement.

According to Tatar *et al.* the AV terminates at the level of T5 close to the level of the carina. The current study showed that the most common termination level was at T3 (47 % of cadavers). In this respect, this is similar to Kutoglu *et al.*, but not Tatar *et al.*

Regarding the HV the mean diameter of its origin and termination was 1.55±0.64 mm and 3.23±1.24 mm, respectively, the difference being double. According to Kutoglu *et al.* the corresponding values were 3.168±0.70 mm and 5.647±1.17 mm, both larger than observed in the current study.

According to Kutoglu *et al.* the HV termination is between T7 and T10 with the exception of one case, which drained into the AV at the level of T6. They also showed that the HV most frequently drained into the AV at the level of T8. In the present study, the HV termination was between T7 and T9 with the exception of one case, which terminated at the level of T6. The most frequent level of HV termination in the current study was T8, which is in agreement with Kutoglu *et al.*

The AHV was the most variable vein in the present study, as also reported by Kutoglu *et al.*. The mean diameter of the AHV at its termination was 1.91±1.02 mm, being

Table IV. The following studies have classified the azygos venous system into three main types. Each of which has different subgrouping.

Study	N	Type 1	Type2	Type 3
Seib (1934)	200	1 to 2%	-	10 cases (5%)
Anson and McVay (1984)	100	1 case (1%)	98 case s (98%)	1 case (1%)
Kutoglu <i>et al</i> (2012)	48	1 case (2.1%)	44 case s (92%)	1 case (2.1%)
This Study	30	1 case (3.3%)	26 case s (86.7%)	3 cases (10%)

smaller than the corresponding diameter of the HV. This could be due to the HV also receiving blood from the abdomen and lower left posterior intercostal veins. In 46 % of cadavers the AHV communicated with the left superior intercostal vein, which probably received some middle left posterior intercostal veins that normally drained into the left brachiocephalic vein. Kutoglu *et al.* reported the mean diameter of the AHV at its termination to be 5.47 ± 1.16 mm, considerably larger than observed in the current study.

The termination of the AHV was observed to be between T5 and T9, with the most common level being at T5 (27 % of cadavers) and the second most common at T7 (17 % of cadavers). This shows a highly variable level of termination of the AHV. According to Kutoglu *et al.* the termination of the AHV varied between T6 and T9, with their most common termination level being at T7. They reported no AHV terminations at the level of T5. Therefore, it is considered that the AHV is the most variable part of azygos venous system in terms of its presence, tributaries, communications and level of termination.

Spinal surgery, especially the anterior approach, is challenging as many vital structures lie adjacent to the thoracic vertebral column. De Giacomo *et al.* (2011) are of the view that left thoracotomy is generally used for thoracic spine procedures between T7 and T12. As the highly varia-

ble termination of the hemiazygos system (T5-T10) overlaps this area it would be important to preoperatively consider its level of termination in mediastinal and spinal surgeries to avoid injury leading to postoperative hematomas.

CONCLUSION

Veins of the azygos system, especially the HV and AHV, are highly variable in their origin, course and termination, with azygos system variations believed to occur during development. Identification and understanding of these variations are important during preoperative radiological investigations and surgical procedures, especially spinal surgery between T7 and T12 using a left thoracotomy approach to avoid injuries, which may lead to postoperative hematomas.

ACKNOWLEDGEMENT

The authors thank and respect all those who donated their bodies for scientific and medical education. ND also thanks the Centre for Anatomy and Human Identification (CAHID) for the opportunity to gain experience in dissecting Thiel-embalmed cadavers.

DAHARAN, N. & SOAMES, R. Variaciones anatómicas del sistema venoso ácigos: Clasificación y relevancia clínica. *Int. J. Morphol.*, 34(3):1128-1136, 2016.

RESUMEN: El sistema venoso ácigos es muy variable en función de su origen, comunicaciones, afluentes y terminación de venas asociadas. Este estudio tuvo como objetivo clasificar las variaciones anatómicas relacionadas con el sistema venoso ácigos. Se examinaron treinta cadáveres embalsamados con la técnica de Thiel, con edades comprendidas entre 48-98 años (18 mujeres, 12 hombres). Se determinó el nivel vertebral de terminación y el diámetro de las venas ácigos, hemiacigos, hemiacigos accesorias e intercostales superiores izquierdas, así como el nivel de terminación del lado derecho de la vena intercostal superior. El sistema ácigos se clasificó en 3 tipos; primitivo (tipo 1), de transición (tipo 2) y unicolumnar (tipo 3). El tipo 2 se dividió en 5 subgrupos (A a E) de acuerdo con el número de comunicaciones retroaórticas. El tipo 1 se observó en 3 % (n = 1), el tipo 2 en 87 % (n = 26) y tipo 3 en 10 % (n = 3) de las muestras. El nivel vertebral de terminación de las venas ácigos, hemiacigos, hemiacigos accesorias, intercostal derecho superior e intercostales superiores izquierda se presentaron entre T2 y T3, T6 y T10, T5 y T9, T2 y T4 y T2 y T4, respectivamente. La identificación y comprensión de estas variaciones anatómicas son importantes durante las investigaciones radiológicas preoperatorias y de los procedimientos quirúrgicos, especialmente en cirugía de columna vertebral, entre los niveles T7 y T12, utilizando un abordaje de toracotomía izquierda, para evitar lesiones que pueden conducir a hematomas postoperatorios.

PALABRAS CLAVE: Ácigos; Hemiacigos; Comunicaciones Retroaórticas; Cadáveres embalsamados mediante la técnica de Thiel; Variaciones.

REFERENCES

Anson, B. J. & McVay, C. B. *Surgical Anatomy*. 6th ed. Philadelphia, Saunders, 1984. pp.464-5.

Celik, H. H.; Sargon, M. F.; Aldur, M. M. & Cumhur, M. An anomalous course of the interazygos vein. *Surg. Radiol. Anat.*, 18(1):61-2, 1996.

Dahran, N. & Soames, R. Intervertebral veins directly connecting the vertebral venous system to the azygos venous system rather than the proximal end of the posterior intercostal veins. *Rev. Argent. Anat. Clin.*, 7(1):88-92, 2015.

De Giacomo, T.; Francioni, F.; Diso, D.; Tarantino, R.; Anile, M.; Venuta, F. & Coloni, G. F. Anterior approach to the thoracic spine. *Interact. Cardiovasc. Thorac. Surg.*, 12(5):692-5, 2011.

Drake, R. L.; Vogl, W. & Mitchell, A. W. M. *Gray's Anatomy for Students*. Philadelphia, Elsevier/Churchill Livingstone, 2005. pp.197.

Dudiak, C. M.; Olson, M. C. & Posniak, H. V. CT evaluation of congenital and acquired abnormalities of the azygos system. *Radiographics*, 11(2):233-46, 1991.

Falla, A.; Preston, F. & Anson, B. Classification and calibration of the azygos venous system in 100 specimens. *Surg. Gynecol. Obstet.*, 116:405-12, 1963.

Kutoglu, T.; Turut, M.; Kocabiyik, N.; Ozan, H. & Yildirim, M. Anatomical analysis of azygos vein system in human cadavers. *Rom. J. Morphol. Embryol.*, 53(4):1051-6, 2012.

Ozbek, A.; Dalçik, C.; Colak, T. & Dalçik, H. Multiple variations of the azygos venous system. *Surg. Radiol. Anat.*, 21(1):83-5, 1999.

Piciucchi S, Barone D, Sanna S, Dubini A, Goodman LR, Oboldi D, Bertocco M, Ciccotosto C, Gavelli, G, Carloni A, Poletti V. *The Azygos Vein Pathway: An Overview From Anatomical Variations To Pathological Changes*. *Insights Imaging*, 5, 619-28, 2014.

Seib, G. A. The azygos system of veins in American whites and American negroes, including observations on the inferior caval venous system. *Am. J. Phys. Anthropol.*, 19(1):39-163, 1934.

Shin, M. S. & Ho, K. J. Clinical significance of azygos vein enlargement: radiographic recognition and etiologic analysis. *Clin. Imaging*, 23(4):236-40, 1999.

Snell, R. S. *Clinical Anatomy*. Philadelphia, Lippincott Williams & Wilkins, 2004. pp.132.

Standring, S. *Gray's Anatomy: The Anatomical Basis of Clinical Practice*. Edinburgh, Churchill Livingstone/ Elsevier, 2008. pp.205-10.

Tatar, I.; Denk, C. C.; Celik, H. H.; Oto, A.; Karaosmanoglu, D.; Ozdemir, B. M. & Surucu, S. H. Anatomy of the azygos vein examined by computerized tomography imaging. *Saudi Med. J.*, 29(11):1585-8, 2008.

Correspondence to:

Dr. Naief Dahran,
Centre for Anatomy and Human Identification (CAHID)
College of Art, Science and Engineering
University of Dundee
Dundee, DD1 5EH,
UK

Email: n.dahran@dundee.ac.uk

Received: 08-06-2016

Accepted: 18-07-2016