



University of Dundee

Mucosal and lacrimal flaps for endonasal dacryocystorhinostomy (DCR)

Green, Richard; Gohil, Rohit; Ross, P.

Published in:
Clinical Otolaryngology

DOI:
[10.1111/coa.12754](https://doi.org/10.1111/coa.12754)

Publication date:
2016

Document Version
Peer reviewed version

[Link to publication in Discovery Research Portal](#)

Citation for published version (APA):

Green, R., Gohil, R., & Ross, P. (2016). Mucosal and lacrimal flaps for endonasal dacryocystorhinostomy (DCR): a systematic review. *Clinical Otolaryngology*. DOI: 10.1111/coa.12754

General rights

Copyright and moral rights for the publications made accessible in Discovery Research Portal are retained by the authors and/or other copyright owners and it is a condition of accessing publications that users recognise and abide by the legal requirements associated with these rights.

- Users may download and print one copy of any publication from Discovery Research Portal for the purpose of private study or research.
- You may not further distribute the material or use it for any profit-making activity or commercial gain.
- You may freely distribute the URL identifying the publication in the public portal.

Take down policy

If you believe that this document breaches copyright please contact us providing details, and we will remove access to the work immediately and investigate your claim.

Received Date : 14-Apr-2016
Revised Date : 06-Jul-2016
Accepted Date : 19-Sep-2016
Article type : Original Manuscript

Mucosal and lacrimal flaps for endonasal dacryocystorhinostomy (DCR) a systematic review

R. Green (MBBS, DOHNS)
R. Gohil (MBBS, DOHNS)
P. Ross (MBChB, FRCS (ORL) Glasgow, FRCS (Edin))

ENT Department Ninewells Hospital, Dundee

Correspondance address

Richard Green
ENT Department
Ninewells Hospital
Dundee
DD2 1UB

01382 660111

E-Mail ID: richard.green14@nhs.net

Abstract

Background;

Historically dacryocystorhinostomy (DCR) has been performed externally with very good outcomes. Current literature shows comparable success rates between endonasal and external approaches. A common reason for the failure of a DCR is the re-closure of the nasolacrimal stoma by granulation tissue and synechiae.

This article has been accepted for publication and undergone full peer review but has not been through the copyediting, typesetting, pagination and proofreading process, which may lead to differences between this version and the Version of Record. Please cite this article as doi: 10.1111/coa.12754

This article is protected by copyright. All rights reserved.

Objective of review;

A systematic review and critical evaluation of the evidence relating to the preservation of nasal mucosal flaps in DCR surgery.

Type of review and evaluation method;

A systematic review using the consort guidance for review of randomised control trials.

Search strategy;

A search of the following evidence-based medicine databases was performed: Cochrane database of systematic reviews (DSR), Database of abstracts of reviews of effectiveness (DARE), Cochrane central register of controlled trials (CCTR), Ovid, Medline, EMBASE, PubMed. The search was limited to English language articles and the following key words were used: Endonasal, Endoscopic, Dacryocystorhinostomy, DCR, Mucosal Flaps, between years 1970 and 2015.

Results;

The best available evidence was level 1B, comprising 2 randomised control trials and 3 comparative studies included in the review. The main outcome measures used were lacrimal irrigation and absence of epiphora. Two of the studies demonstrated a statistically significant benefit of mucosal sparing either with nasal mucosal flaps or lacrimal flaps. More debridement was needed and granulation tissue was also seen in the groups without mucosal preservation. There was no difference in surgical complications between a mucosal and non-mucosal sparing technique.

Conclusions;

The overall quality of current evidence is poor, there does however appear to be a trend towards improved outcomes and reduced granulation in groups where nasal mucosal and lacrimal flaps were preserved, but this is not clear-cut. There was no evidence of increased complication rates with mucosal sparing techniques. We recommend that until further good quality research is available we should be performing a mucosal sparing technique when performing DCR routinely.

Key Points

- Little evidence with only two level 1B RCTs and three comparative studies available to review
- There is some evidence that mucosal flaps improve outcome measures, such as lacrimal irrigation and absence of epiphora
- Evidence suggests that fewer granulations and nasal debridement required in mucosal sparing techniques
- No increase in surgical complications with mucosal sparing techniques
- We recommend future studies include the use of a validated quality-of-life (QoL) measure for outcome assessment.

Introduction

Historically dacryocystorhinostomy (DCR) has been performed externally with very good outcomes¹. The development of endonasal instrumentation and modern visual technology has led to the endoscopic approach now being the preferred surgical technique in many centres. Current literature shows comparable success rates between endonasal and external approaches however the endonasal technique avoids an external scar².

Endonasal DCR was first described by Caldwell in 1893, the major limitation being the equipment available at that time³. The first clinical study of endonasal DCR was by McDonogh et al in 1989⁴. The technique describes the removal of the nasal mucosal flap and suturing the lacrimal flap to the inferior turbinate.

Conventional endonasal DCR had created a fistula between the lacrimal sac and the nasal cavity without the preservation of the nasal mucosa. A common reason for the failure of a DCR is the re-closure of the nasolacrimal stoma by granulation tissue and synechiae⁵. Many approaches have been used to try and improve the success rates of endonasal DCR, from silicone stents to mitomycin C application. Another commonly held belief is that the preservation of nasal mucosal flaps can help reduce the rate of granulation and synechiae formation. There has been a progressive evolution of DCR surgery with several authors describing different techniques of nasal mucosal preservation and flap creation. These

include the U-shaped ⁶, L-shaped mucosal flap ⁷, free nasal mucosal flap ⁸, and the preservation of the whole nasal mucosal flap ⁹. We present a review of the current literature on this subject.

Objective of the review: To systematically review and critically evaluate the evidence relating to the preservation of nasal mucosal flaps in DCR surgery.

Methods: A systematic review of the literature was performed to identify papers on the subject of mucosal flap use in DCR surgery. A search of the following evidence-based medicine databases was performed: the Cochrane Database of Systematic Reviews (DSR), Database of Abstracts of Reviews of Effects (DARE), Cochrane Central Register of Controlled Trials (CCTR), Ovid, Medline, EMBASE and PubMed. The search was limited to English language articles. The search terms used were: Endonasal, Endoscopic, Dacryocystorhinostomy, DCR, Mucosal Flaps. Articles between years 1970 and 2015 were used. Titles and abstracts were screened and the all the RCTs that compared mucosal flaps to no mucosal flaps or compared differing mucosal flaps were included (**Figure 1**).

Two independent reviewers assessed the relevant articles using the CONSORT Statement guidance on reporting of randomised trials ¹⁰.

Results: The best evidence available was level 1B, there were 2 randomised control trials (RCTs). The 2 RCTs form the main basis of the review, there are also 3, level 2 comparative studies included that we felt were clinically relevant. Of the 3 comparative studies, 1 compares nasal mucosal flaps and 2 compare lacrimal flaps. The review is predominantly broken down in to mucosal flaps and lacrimal flaps.

Cumulatively there are 188 patients in the RCT groups with 373 in the comparative studies: n = 561 patients.

The five studies included for discussion with their surgical intervention, outcome measures, success rates and complications are listed in **Tables 1 and 2**.

Table 1. RCTs and comparative studies showing surgical intervention, outcome measures, success rates and complications for nasal mucosal flaps versus no flaps.

Table 2. Comparative studies showing surgical intervention, outcome measures, success rates and complications for differing lacrimal sac flaps.

Outcome measures;

Lacrimal irrigation and absence of epiphora: In the two RCTs the main outcome measures were lacrimal irrigation and absence of epiphora^{11,12}. The three comparative studies all utilised lacrimal irrigation or a fluorescein test as the main outcome measures; Kansu et al also documented the absence of symptoms as well as episodes of dacryocystitis and obstruction of the neo-ostium^{13,14,15}.

Ji et al demonstrated a statistically significant benefit in the mucosal flap group with a 98% success rate in group A compared to 84% in group B ($p < 0.05$)¹¹. The other 2 papers comparing nasal mucosal flaps showed an increased success in the nasal flap groups but this was not statistically significant^{13,14}. Yuen et al illustrated a statistically significant benefit when comparing a lacrimal sac flap to lacrimal flap excision with success of 89.1% in the lacrimal flap group and 71.7% in the resection groups ($p < 0.05$)¹⁵.

Other outcome measures: In the papers comparing nasal mucosal flaps, all demonstrated either more granulation tissue or needing more debridements in the groups with no mucosal flaps. In the 2 RCTs this was statistically significant^{11,12,13}.

In the two studies comparing lacrimal flaps, Massegeur et al found an increased synechia rate in the no lacrimal flap groups although not statistically significant, and no difference in granulation¹⁴. In the Yuen paper they found a granulation tissue rate of 6.5% in the lacrimal flap group and 17.0% in the no flap group, but again not significant¹⁵.

Complications: In the 2 RCTs there were a total of 3 epistaxis with no difference between the groups^{11,12}. In the comparative study comparing mucosal flaps 5 patients had periorbital oedema with 4 developing eyelid ecchymosis and 4 epistaxis but there was no significant difference between the groups¹³.

In the two studies comparing lacrimal flaps there were 12 cases of eyelid haematoma but no difference between the groups^{14,15}.

An assessment of the evidence and results provided was undertaken at our local Clinical Trials Unit – given the limited number of RCTs, a meta-analysis could not be performed.

Discussion

The variety of surgical methods and generally good success rates of them all indicates a lack of consensus regarding best management. The above results demonstrate some conflicting evidence but overall there appears to be a trend towards preservation of both the nasal mucosal tissue and the medial lacrimal sac. The arguments for mucosal preservation in DCR surgery are similar to those of frontal sinus surgery.

Overall completeness and applicability of the evidence;

The 5 studies reviewed cover slightly differing aspects regarding mucosal preservation. Our review aimed to focus on nasal mucosal flaps, which 3 studies did. In performing the literature search we identified the 2 studies comparing medial lacrimal sac flaps and have included them as it was felt there was clinical relevance with the nasal mucosal papers.

Given that 2 of the papers are RCTs these understandably hold more weight when drawing any conclusions regarding the subject matter. We found the Khalifa et al RCT to be the most complete with a good description of patient selection, inclusion and exclusion criteria¹². It sufficiently details their randomisation procedure and sample size calculations. Importantly, this is the only double blinded study.

Trial Limitations;

Quality of the evidence

The obvious limitations are of the comparative studies. The data is retrospective, and in Kansu et al and Yeun et al different surgeons were performing the two different techniques^{13,15}. Masegur et al describe the operations taking place at different periods - group A being performed from 1998-2000 and group B from 2000 onwards¹⁴. Both of these issues introduce significant variability into the process.

There was variability in the type of mucosal or lacrimal sac flap used, the most commonly used being the posteriorly based nasal mucosa and lacrimal flaps (**see Table 3**).

Other than the difference in surgical procedure, there is a wide variation in terms of the other adjuncts used. In the two RCTs there is clear description of the surgical procedure and in Ji et al the patients were under general anaesthetic, and they used Merogel dressing on the flap with and no silicone stents¹¹. In Khalifa et al surgery was performed under local anaesthetic and sedation, using tissue glue to the mucosal and lacrimal edges with a gelfoam patch as well as silicone stenting¹².

The variation in surgical techniques and adjuncts such as silicone stents and mitomycin C is the main limitation of the evidence. Silicone stents were used in both arms of all of the studies except Ji et al where they did not use any^{11,12,13,14,15}. There was variation regarding stent removal in Kansu et al and Yuen et al with no documented protocol for their removal^{13,15}. Mitomycin C was only used in one of the comparative studies and appears to be used in both arms. The use of silicone stents and mitomycin C in both arms of the Yuen et al paper left the main difference between the groups being surgical technique and therefore improved the study's relevance and validity for review¹⁵.

Without a meta-analysis of the results, we feel that the Yuen et al paper is still valid when answering the question of mucosal preservation in DCR surgery¹⁵. In Kansu et al other nasal procedures were performed from septoplasty to FESS, although there was no statistical difference between the number of procedures performed in each arm¹³.

Another difference amongst all the papers was the postoperative treatment regimen. This differed from antibiotic and steroid eye-drops to nasal irrigation and steroid nasal sprays, along with oral antibiotics and anti-inflammatories with no two papers observing the same post-operative regime.

Both RCTs followed their patients up for 12 months with an acceptable dropout rate with no significant difference between the 2 groups in either study^{11,12}. In the comparative studies however the follow up ranged from 2 to 78 months in Kansu et al, and a minimum of 3 months in Yuen et al and 6 months in Masegur et al^{13,14,15}. This is important as not only does this illustrate a variability in practice; but also in Khalifa et al they demonstrated that in both groups there was a drop in success rates from the 6 to 12 months. This suggests that a longer follow up or at least follow up for 12 months is indicated given the potential for late failures¹².

Potential bias in review;

In all but the Khalifa et al paper there is significant potential for bias. The retrospective comparative studies as well as the Ji et al RCT were not blinded and although there is mention of randomisation by Ji the details and quality of this are not discussed¹¹.

Interpretation of outcome measures should be done so with caution. None of the papers appeared to use a visual analogue score or other validated scoring system. Although the fluorescein/lacrimal irrigation test is commonly used, the variability of the technique used from drop application to length of time observing are varied and subjective and therefore open to bias. In our clinical experience we have found that a binary approach does not reflect the complexity of the symptoms as the patients are rarely either totally symptomatic or symptom free. Therefore in future studies we would advise the use of a validated patients assessment with a visual analogue score as well as a quality of life assessment, e.g. *Glasgow Benefit Inventory* or *Lac-Q*^{16,17}.

Comparison with other reviews;

There are three reviews published recently that outline DCR in practice and include some mention of mucosal flaps^{18,19,20}. They talk of the different techniques but only Marcet et al details the evidence behind these, however this is a brief summary of Khalifa et al's findings - there were no other papers included in this review^{12,17}.

Implications for clinical practice; Implications for research;

Endonasal endoscopic DCR is still a work in progress that has been progressively refined over the last 20-30 years. It now has similar or better success rates than the external technique that had been the gold standard for so long²¹. There is significantly more evidence surrounding other aspects of the surgical approach such as silicone stents and application of mitomycin C.

There are many factors which influence the success of DCR surgery, with an overall high success rate despite variation in surgical technique or adjunct used. The biggest issue with current evidence is the lack of control of the other confounding variables. Comparing study against each other was also difficult given the heterogeneous approach to the surgical technique and adjuncts used as well as the postoperative regimes. The placement of silicone tubes is still contentious and still often used by many surgeons although there is growing evidence, including two randomised controlled trials and a meta-analysis, showing no difference in primary DCR with or without stenting^{22,23,24}. A meta-analysis of the application of mitomycin C in endoscopic DCR has shown improved success rates ($p=0.004$) but subgroup analysis found that benefit was only statistically significant if silicone stents were not used²⁵. The perceived risks and representative success rates without using mitomycin C results in it still not being used commonly.

The overall quality of evidence is low but there does appear to be a general trend towards improved outcomes with reduced granulation in the groups where nasal mucosal and lacrimal flaps were preserved but this is not clear-cut. Case series have been published demonstrating that DCR with or without mucosal flap preservation has similar success rates to the other published literature, but these are non-comparative non-randomised studies

^{26,27,28}. It is known that minimal mucosal trauma helps to reduce wound contraction and therefore minimise scarring ²⁹. It is established in surgical practice that reducing mucosal trauma in frontal sinus surgery and minimisation of bone exposure helps reduce stenosis ³⁰. Mann et al. proposed that this is also the case in DCR, where careful approximation of nasal mucosa and lacrimal flaps allows healing by primary intention and thus reduces granulation ³¹.

Further research is clearly necessary to clarify if mucosal preservation has a benefit in DCR surgery compared to mucosal sacrifice. The studies need to be significantly powered and a standardised surgical technique used. Also limitations to the number of variables that can affect the clinical outcome such as patient selection, the use of stents, mitomycin C and the method of performing osteotomies should be accounted for. There needs to be an adequate follow up period of at least a year due to late failures and changes to the rhinostomy site. Clear outcome measures both subjective and objective with Patient Related Outcome Measures (PROMs) should also be assessed in further studies. Given the limitations of current evidence we would recommend that until further good quality research is available we should be performing a mucosal-sparing technique when performing DCR routinely.

No conflict of interest.

Table 1.

Type of Study	Paper	Numbers in the study	Surgical intervention	Blinded	Follow up	Outcome measures	Success	Complications
RCT	Ji et al 2012	54 group A 57 group B	Group A mucosal flap Group B no flap	No	1,3,6,12 (months)	Lacrimal irrigation, absence of epiphora and discharge	98% group A, 84% group B $p < 0.05$, significantly more granulations and scar tissue in group B	1 epistaxis
RCT	Khalifa et al 2012	38 group A 39 group B	Group A mucosal flap Group B no flap	Yes double blind	Weekly for 1 month, every 2 weeks for 3 months then monthly	Lacrimal irrigation, absence of epiphora and discharge	92.1% group A, 87.2% group B. No difference. Only difference was regarding the number of debridement's needed. Significantly more for group B.	Pain under Local anaesthetic 45%, no difference in epistaxis and synechia
Comparative (retrospective)	Kansu et al 2008	25 group A 39 group B	Group A mucosal flap Group B no flap	No	1 week, 1,3,6,12,24 months	Lacrimal irrigation, absence of epiphora, episode of dacryocystitis, obstruction of neo ostium	Group A 100%, group B 88.3% $p 0.08$	Epistaxis, orbital oedema, ecchymosis, synechia, granulation, re-obstruction. No difference in groups

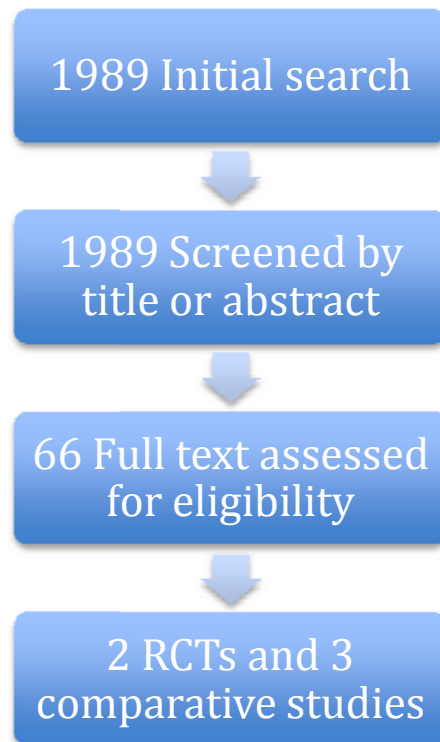
Table 2.

Type of Study	Paper	Numbers in the study	Surgical intervention	Blinded	Follow up	Outcome measures	Success	Complications
Comparative (retrospective)	Massegur 2003	96 group A 40 group B	Group A no lacrimal flap Group B lacrimal flap	No	1,2,3,4,5, 6 months	Nasal permeability fluorescein	Group A 92.7% group B 87.5% not statistically significant	Group A, 5 eyelid haematoma, 10 synechia, group B 7 eyelid haematoma, 3 synechia
Comparative (retrospective)	Yuen et al 2004	46 group A 53 group B	Group A lacrimal sac flap, Group B no lacrimal flap	No	Differs greatly	Fluorescein at 3 months	89.1% in group A, 71.7% in group B, $p < 0.05$	Granulation tissue 6.5% in group A, 17.0% group B, didn't comment if significant. One damage to lacrimal punctum.

Paper	Group A surgical technique	Group B surgical technique
Ji et al 2012	Posteriorly based nasal mucosa flap cut into V shape	Nasal mucosa removed
Khalifa et al 2012	Posteriorly based nasal mucosal and lacrimal lac flaps	Nasal mucosa and medial lacrimal sac removed
Kansu et al 2008	Posteriorly based nasal mucosal and lacrimal lac flaps	Nasal mucosa and medial lacrimal sac removed
Yuen et al 2004	Nasal mucosa removed, large posteriorly based lacrimal flap	Nasal mucosa and medial lacrimal sac removed
Massegur 2003	Inferior nasal mucosal flap	Inferior and posterior based nasal mucosal flap with posterior lacrimal sac flap

Table 3. Table showing the variation in nasal mucosal and lacrimal flaps used in each paper reviewed.

Illustration 1. Search results for systematic review on nasal mucosal flaps in DCR surgery.



¹Leong SC, MacEwen C, White PS. A systematic review of outcomes after dacryocystorhinostomy in adults. *American journal of rhinology & allergy*. 2010 Jan 1;24(1):81-90.

²Huang J, Malek J, Chin D, Snidvongs K, Wilcsek G, Tumuluri K, Sacks R, Harvey RJ. Systematic review and meta-analysis on outcomes for endoscopic versus external dacryocystorhinostomy. *Orbit*. 2014 Apr 1;33(2):81-90.

³Caldwell GW. Two new operations for the obstruction of the nasal duct with preservation of the canaliculi. *Am J Ophthalmol*. 1893;10:189-191.

⁴McDonogh M, Meiring JH. Endoscopic transnasaldacryocystorhinostomy. *The Journal of Laryngology & Otology*. 1989 Jun 1;103(06):585-7.

⁵Allen K, Berlin AJ. Dacryocystorhinostomy failure: association with nasolacrimal silicone intubation. *Ophthalmic surgery*. 1989 Jul;20(7):486-9.

⁶Tsirbas A, Wormald PJ. Endonasaldacryocystorhinostomy with mucosal flaps. *American journal of ophthalmology*. 2003 Jan 31;135(1):76-83.

⁷Trimarchi M, Resti AG, Bellini C, Forti M, Bussi M. Anastomosis of nasal mucosal and lacrimal sac flaps in endoscopic dacryocystorhinostomy. *European Archives of Oto-Rhino-Laryngology*. 2009 Nov 1;266(11):1747-52.

⁸Mahendran S, Stevens-King A, Yung MW. How we do it: the viability of free mucosal grafts on exposed bone in lacrimal surgery—a prospective study. *Clinical Otolaryngology*. 2006 Aug 1;31(4):324

⁹Codère F, Denton P, Corona J. Endonasaldacryocystorhinostomy: a modified technique with preservation of the nasal and lacrimal mucosa. *Ophthalmic Plastic & Reconstructive Surgery*. 2010 May 1;26(3):161-4.

¹⁰CONSORT 2010 Explanation and Elaboration: updated guidelines for reporting parallel group randomised trials. Moher D, Hopewell S, Schulz K, Montori V, Gøtzsche P, Devereaux P et al. *BMJ* 2010;340:c869 doi: 10.1136/bmj.c869

¹¹Ji QS, Zhong JX, Tu YH, Wu WC. New mucosal flap modification for endonasal endoscopic dacryocystorhinostomy in Asians. *International journal of ophthalmology*. 2012;5(6):704.

¹²Khalifa MA, Ragab SM, Saafan ME, El-Guindy AS. Endoscopic dacryocystorhinostomy with double posteriorly based nasal and lacrimal flaps: a prospective randomized controlled trial. *Otolaryngol Head Neck Surg* 2012; 147:782–787.

¹³Kansu L, Aydin E, Avci S, Kal A, Gedik S. Comparison of surgical outcomes of endonasaldacryocystorhinostomy with or without mucosal flaps. *AurisNasus Larynx*. 2009 Oct 31;36(5):555-9.

¹⁴Massegur H, Trias E, Ademà JM. Endoscopic dacryocystorhinostomy: modified technique. *Otolaryngology-Head and Neck Surgery*. 2004 Jan 31;130(1):39-46.

¹⁵Yuen KS, Lam LY, Tse MW, Chan DD, Wong BW, Chan WM. Modified endoscopic dacryocystorhinostomy with posterior lacrimal sac flap for nasolacrimal duct obstruction. *Hong Kong medical journal*= Xianggangyixuezhazhi/Hong Kong Academy of Medicine. 2004 Dec;10(6):394-400.

¹⁶Spielmann PM, Hathorn I, Ahsan F, Cain AJ, White PS. The impact of endonasaldacryocystorhinostomy (DCR), on patient health status as assessed by the Glasgow benefit inventory. *Rhinology*. 2009 Mar 1;47(1):48.

¹⁷Mistry N, Rockley TJ, Reynolds T, Hopkins C. Development and validation of a symptom questionnaire for recording outcomes in adult lacrimal surgery. *Rhinology*. 2011 Dec 1;49(5):538.

¹⁸Knisely A, Harvey R, Sacks R. Long-term outcomes in endoscopic dacryocystorhinostomy. *Current opinion in otolaryngology & head and neck surgery*. 2015 Feb 1;23(1):53-8.

¹⁹Marcet MM, Kuk AK, Phelps PO. Evidence-based review of surgical practices in endoscopic endonasaldacryocystorhinostomy for primary acquired nasolacrimal duct obstruction and other new indications. *Current opinion in ophthalmology*. 2014 Sep 1;25(5):443-8.

²⁰Penttilä E, Smirnov G, Tuomilehto H, Kaarniranta K, Seppä J. Endoscopic dacryocystorhinostomy as treatment for lower lacrimal pathway obstructions in adults: Review article. *Allergy & Rhinology*. 2015;6(1):e12.

²¹Huang J, Malek J, Chin D, et al. Systematic review and meta-analysis on outcomes for endoscopic versus external dacryocystorhinostomy. *Orbit* 2014; 33:81–90

²²Chong KK, Lai FH, Ho M, et al. Randomized trial on silicone intubation in endoscopic mechanical dacryocystorhinostomy (SEND) for primary nasolacrimal duct obstruction. *Ophthalmology* 2013; 120:2139–2145.

²³Smirnov G, Tuomilehto H, Terasvirta M, et al. Silicone tubing is not necessary after primary endoscopic dacryocystorhinostomy: a prospective randomized study. *Am j Rhinol* 2008; 22:214–217.

²⁴Feng YF, Cai JQ, Zhang JY, Han XH. A meta-analysis of primary dacryocystorhinostomy with and without silicone intubation. *Can J Ophthalmol* 2011; 46:521–527.

²⁵Cheng S, Feng Y, Xu L, et al. Efficacy of mitomycin C in endoscopic dacryocystorhinostomy: a systematic review and meta-analysis. *PLoS One* 2013; 8:e62737.

²⁶Ramakrishnan VR, Hink EM, Durairaj VD. Outcomes after endoscopic dacryocystorhinostomy without mucosal flap preservation. *American journal of rhinology*. 2007 Nov 1;21(6):753-7.

²⁷Hodgson N, Bratton E, Whipple K, Priel A, Oh SR, Fante RG, Kikkawa DO, Korn BS. Outcomes of endonasaldacryocystorhinostomy without mucosal flap preservation. *Ophthalmic Plastic & Reconstructive Surgery*. 2014 Jan 1;30(1):24-7.

²⁸Sonkhya N, Mishra P. Endoscopic transnasaldacryocystorhinostomy with nasal mucosal and posterior lacrimal sac flap. *The Journal of Laryngology & Otology*. 2009 Mar 1;123(03):320-6.

²⁹Kim D-H, Richardson-Burns S, Povlich L, Abidian MR, Spanninga S, Hendricks J, Martin DC. In: *Indwelling Neural Implants: Strategies for Contending with the In-Vivo Environment*. Reichert WM, editor. CRC Press, Taylor and Francis; Boca Raton, FL: 2008. pp. 165–207.

³⁰Weber R, Draf W, Kratzsch B, Hosemann W, Schaefer SD. Modern concepts of frontal sinus surgery. *The Laryngoscope*. 2001 Jan 1;111(1):137-46.

³¹Mann BS, Wormald PJ. Endoscopic assessment of the dacryocystorhinostomyostium after endoscopic surgery. *The Laryngoscope*. 2006 Jul 1;116(7):1172-4.