THE BIOLOGICAL ACTIVITY OF AMINONUCLEOSIDE

"A MORPHOLOGICAL AND BIOCHEMICAL STUDY"

BY

PETER KARL LEWIN

A THESIS SUBMITTED FOR THE DEGREE OF

DOCTOR OF MEDICINE

UNIVERSITY OF LONDON

1968

I N D E X

Chapter I. INTRODUCTION

Aminonucleoside (6. Dimethylaminopurine-3-Amino-D-Ribose) an adenosine analogue prepared from the antibiotic puromycin has attracted widespread biological interest since the discovery by Frenk et al (1955) (1) that the administration of this drug to rats could induce a nephrotic syndrome not unlike lipoid nephrosis of children.

With such an experimental tool at hand it was hoped that some insight into the pathological mechanisms of lipoid nephrosis could be gained, which in turn would increase our knowledge of the physiology and pathophysiology of the kidney, particularly in relation to glomerular function. Although over 300 papers have been published on the action of aminonucleoside in biological systems (2), the exact biological action of the drug is still not fully understood either at the biochemical or ultrastructural level. This thesis is presented with the hope of elucidating further some of the biological actions of aminonucleoside particularly as related to the production of experimental nephrosis in rats, and to demonstrate that the experimental disease entity involves not only the kidney but also the liver.

In order to study the direct changes resulting from aminonucleoside treatment, a morphological study of the action of aminonucleoside on HeLa cells was undertaken. Ultrastructural changes were found in HeLa cells following aminonucleoside treatment, and as they had not been reported previously the findings were correlated with the biochemical changes that occur in HeLa cells so treated. The results of these investigations are reported in the first part of this thesis.

It has recently been shown that serum glycoprotein biosynthesis is significantly increased prior to the onset of proteinuria in rats injected with aminonucleoside (3). As most of the plasma glycoproteins are synthesized in the liver and then released into the plasma, the liver became the main target of our investigations. Since no related ultrastructural hepatic changes have been reported in the nephrotic syndrome, light and electron microscopy of the liver was undertaken to determine whether or not the functional hepatic changes reported earlier were reflected in structural alterations.

The second part of this thesis reports the results of these investigations with particular emphasis on the relationship of the liver in the pathogenesis of the nephrotic syndrome.

Chapter II. REVIEW OF THE LITERATURE

A. Biochemical Nature of Aminonucleoside

Following the discovery of puromycin by Porter et al (4) and its biochemical characterization by Waller et al (5) in 1953, aminonucleoside was developed by the deletion of paramethoxyphenylalanine attached to the amino group of the ribose moiety of puromycin (see Fig. 1), resulting in the splitting off of a nucleoside (6 dimethylaminopurine) and called aminonucleoside.

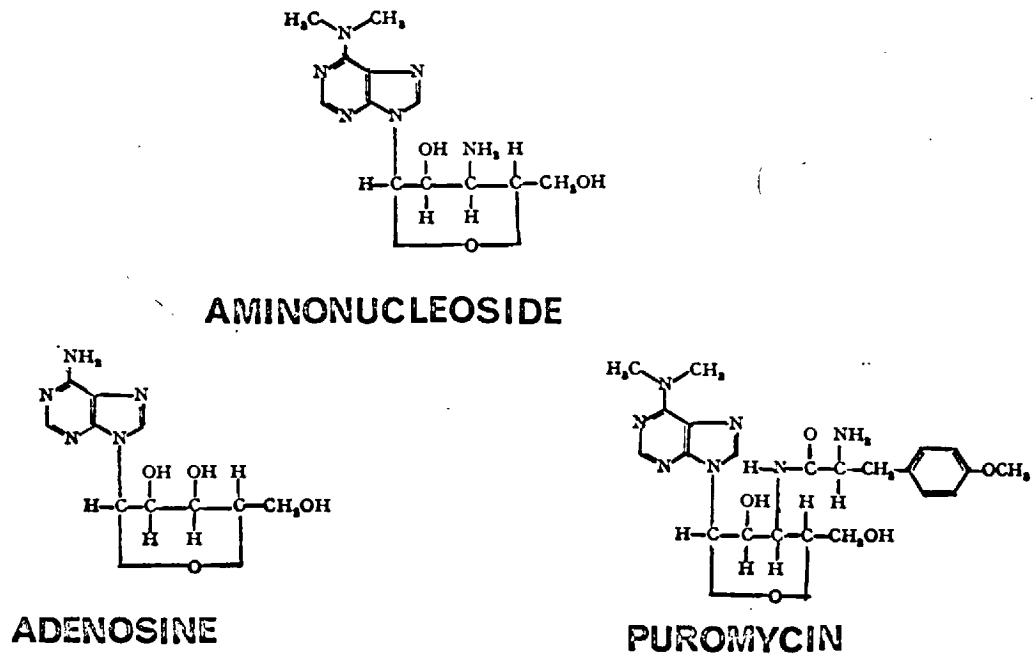

Fig. 1: Comparison of the structural formulae of aminonucleoside, puromycin and adenosine

The structure is not unlike that of dimethyl adenosine. In 1955 Baker et al (6 - 7) synthesized aminonucleoside from D-xylose at the Lederle Research Laboratories which patented the product at the time (8). The patent rights have now been sold to Nutritional Biochemical Corporation of the U.S.A., who market aminonucleoside at around 500 dollars per gram.

B. Historical Review

The therapeutic use of aminonucleoside began following reports of good biological activity against trypanosomes (9), entamoebae histolytica (10) and also against certain mammary tumours of mice (11,12). The antitumour properties of aminonucleoside in rats were further investigated by J.C. van Meter (13) who postulated that the carcinostatic activity of aminonucleoside was related to its similarity with adenosine, and thereby interfering with nucleic acid metabolism. They investigated C3H mammary adenocarcinoma of untreated and aminonucleoside treated rats and found that the ribonucleic acid content of the mammary tumours from treated rats to be significantly lower than those of untreated rats. They therefore came to the conclusion that growth in aminonucleoside treated tumours was interfered with, thereby causing a subsequent decrease of ribonucleic acid content of these tumours.

With these anti-carcinogenic properties in mind Burchenal (14) gave aminonucleoside to a number of patients with leukaemia, multiple myelomas and Hodgkin's disease, using 3 to 4 mg/kg/bodyweight intravenously for 15 to 38 days with apparent clinical improvement.

However the above patients developed massive proteinuria following aminonucleoside, the urine reverting back to normal after discontinuing therapy. Frank nephrosis was not observed in any of these patients. Good remissions in acute leukaemia following aminonucleoside were also reported in adults and children who were given aminonucleoside following failure of 6 Mercaptopurine therapy, but treatment was discontinued again because of proteinuria.

Nephrotoxic reactions following aminonucleoside were first observed in rats by Hewitt et al (15), and later confirmed by Sherman et al in 1955 (16). Frenk, Antonowicz, Craig and Metcoff (1) were the first to demonstrate conclusively that aminonucleoside had a nephrotoxic action on rat kidneys resulting in a nephrotic syndrome, the pathology of which was not unlike that of human juvenile lipoid nephrosis.

Since the first description of experimental aminonucleoside nephrosis in rats, the biological activity of aminonucleoside has been exhaustively investigated at the pathological, biochemical and ultrastructural level.

Investigations have been directed particularly towards correlating renal ultrastructural changes in aminonucleoside nephrosis of rats with the ultrastructural changes seen in kidneys of children suffering from lipoid nephrosis (Ellis Type II Glomerulonephritis) (17,18).

C. The In-Vivo Action of Aminonucleoside in Rats

Nephrosis in rats can be produced by giving aminonucleoside subcutaneously daily, proteinuria developing 6 to 7 days after the first injection, followed by oedema, ascites and hypercholesterolaemia on the 12th day (19). Nephrosis can also be produced in rats by giving a single intravenous injection. Proteinuria and oedema develops after a period averaging 6 days (20). As the latent period before the onset of proteinuria following a single intravenous injection of aminonucleoside remains relatively constant, the technique was adopted in this thesis as the method of choice in the production of experimental nephrosis.

The numerous investigations which have been undertaken in both experimental and clinical forms of nephrosis have been concerned mainly with the morphological and biochemical changes following the appearance of renal lesions and protein in the urine. The investigations per se thereby pin pointed the kidney as the target for

massive investigative programmes, with however, no definite clue being obtained as to the exact mechanism of production of the nephrotic syndrome, either under experimental or clinical conditions.

In contrast there exists a paucity of experimental or clinical data relating to biochemical changes in the pre-nephrotic stage of nephrosis, neither are there any reports available relating the nephrotic syndrome to a generalized metabolic disorder involving the liver, with the kidney being involved only during the terminal phase of this disease. Conversely, it has recently been demonstrated that kidney lesions do develop following certain hepatic disorders particularly cirrhosis and well documented at the ultrastructural level by Sakaguchi et al (21). Further the demonstration by Moscarello et al (3,22) that C^{14} glucosamine incorporation into rat serum glycoprotein is increased significantly in the latent pre-nephrotic phase as early as 24 hours following intravenous aminonucleoside administration was of great interest, because Sarcione had shown earlier (23-24) that plasma glycoproteins are predominately synthesized in the liver using a liver perfusion technique. Interest was therefore focused on the liver as being intimately involved in the metabolic disorder which involved the kidney producing a nephrotic syndrome.

i. Morphological Changes Following Aminonucleoside

a) Light Microscopy: In the acute stage of aminonucleoside nephrosis alterations occur in renal structures 1 to 3 days following aminonucleoside independent of the method of drug administration (20). The glomerular epithelial cells become proliferative with capillary endothelial swelling, the changes often being associated with proteinaceous staining material within the Bowman Capsular Space (25). Changes in glomerular basement membranes were also reported by a number of investigators (1,26,27,28), but these findings could not be confirmed at the ultrastructural level (29,30,31,32). Renal tubular changes in the acute stage of aminonucleoside nephrosis are always seen by light microscopy. The tubular cells contain numerous cytoplasmic inclusions and are pale and swollen, their lumina being filled with PAS positive staining casts.

During the chronic nephrotic stage in rats kept alive by various means following aminonucleoside, progressive glomerular changes occur with increased epithelial cell proliferation associated with thickening of the glomerular basement membranes and Bowman's capsules. Bowman's capsules at this stage are often surrounded by demilunar epithelial cell crests similar to those seen in Ellis Type II Glomerulonephritis. The tubular cells become

flattened and contain numerous PAS positive casts. Eventually, if rats are kept alive long enough, complete hyalinisation of renal glomeruli occurs (18,33,34,35,36).

Most investigators reported no light microscopical lesions in the spleen, liver, lungs, heart, adrenals or pancreas following aminonucleoside administration. However, in one report, Merchante et al (19) did observe hepatic cell damage around the central vein of hepatic lobules following aminonucleoside administration. Although not clearly stated the observations seem to have been made during the nephrotic stage but no conclusions were made on this observation.

b) Electron Microscopy: Since the first reports by Harkin and Recant (29,30), and Vernier and his co-workers (31,32) of ultrastructural changes in the rat kidney following injections of aminonucleoside, many investigators have described similar changes at the electron microscopic level (33,34,35). Investigations were particularly focused on the sequence of glomerular changes relative to proteinuria, and to correlate the changes seen in animals with those found in lipoid nephrosis of children.

Acute Stage: During the acute stage following aminonucleoside administration most investigators reported no changes in glomeruli and tubules at the ultrastructural level until immediately prior to the onset of proteinuria. However, Kortge et al (37) claimed to have observed glomerular

changes as early as 6 hours following a single intravenous injection of aminonucleoside (10 mg/per 100G weight). Similar claims of early glomerular lesions were made by Harkin and Recant (30) following a single subcutaneous injection of aminonucleoside (1.5 mg/per 100G weight). None of these early changes were definitive and only became significant 5 days after the injection.

The first alterations occur in the epithelial cells of the kidney glomerulus which show fusion or elongation of foot processes along the basement membrane. The epithelial cells at this stage contain numerous inclusion bodies and vesicles and the cytoplasm in contact with the glomerular basement membrane has increased numbers of pinocytic vesicles. Endothelial damage is characterized by proliferation, swelling and partial obstruction of the capillary lumina (35). At a later stage mesangial cell proliferation may be observed (32). Movat (38) has shown that collagen fibres may appear in the basement membrane 6 days following a single injection of aminonucleoside, however earlier changes in basement membrane structure were not described.

Farquhar and Palade (39) demonstrated that desmosomal areas between foot processes of normal animals became narrower in aminonucleoside nephrosis. The authors

interpret these changes as types of "water tight" seals to prevent further protein loss through the "filtration slits" present in this syndrome, however recent work does not substantiate their ideas. Tubular epithelial cells specially those of the proximal segment exhibit cytoplasmic vacuolation, swelling of mitochondria and appearance of electron dense bodies in the cytoplasm.

Chronic Stage: Dramatic ultrastructural changes in glomerular basement membrane occured in rats rendered nephrotic with aminonucleoside and kept alive for long periods. Thickening of the basement membrane associated with deposition of extraneous material of moderate density, on both sides of basement membrane particularly the luminal side is characteristic of this stage. These deposits may represent basement membrane like material, however this has not been confirmed (34,35). The distribution of the deposits are very similar to those seen in chronic cases of lipoid nephrosis in children (40). At this stage the epithelial cells whose cytoplasm is filled with osmophilic droplets and vacuoles are intimately attached to the basement membrane with loss of foot processes. Fusion also occurs frequently at this stage between the visceral cells of the glomeruli and the parietal cells of Bowman's capsule.

Endothelial cells showed varying degrees of swelling and as the subendothelial deposits became larger,

obliteration of the entire glomerulus occurred. As part of the same process, the mesangium becomes overloaded with protein, with deposits being laid down in the mesangial matrix. This leads to an increase of the mesangial matrix and in the total thickness of the glomerular basement membrane which corresponds to the hyalinization of basement membrane and mesangial area. These glomeruli represent the hyalinized glomeruli seen under light microscopy at this stage. The basement membrane of tubular cells at this stage is also abnormal, being thickened, irregular in shape and consistency, and in some cases containing deposits. Tubular cells contain numerous cytoplasmic inclusions and vacuoles and often show nucleolar changes.

ii. Biochemical Changes Following Aminonucleoside

Since the description by Frenk et al (1) that gross body electrolyte changes associated with renal changes occurred following aminonucleoside, and the work of van Meter et al (13) who demonstrated that aminonucleoside reduced the total ribonucleic acid content of mouse mammary adenocarcinomas (RNA/gram of tumour) in vivo, extensive experimental work has been undertaken to localise the biochemical site of aminonucleoside action.

Most investigators used the intact rat as the experimental animal, and the biochemical changes that occurred following aminonucleoside were often examined in detail once proteinuria had been established. The biochemical results obtained by these investigators following proteinuria therefore may not have been due to aminonucleoside, but secondary to protein and electrolyte disturbances following proteinuria and altered renal function. In order to minimise these secondary biochemical changes, the latent phase prior to aminonucleoside proteinuria in rats has recently been investigated biochemically (3,22).

Rats given aminonucleoside either subcutaneously in a series of injections or by a single intravenous dose, developed gross proteinuria and oedema after a short latent period. Associated with the urinary protein loss marked alterations in serum protein and electrolyte levels occurred.

The serum proteins of treated rats during the nephrotic stage are markedly reduced, with a dramatic fall in serum albumin (from a normal of 3.1G% to 0.9G%). Total serum globulin levels are not affected, however γ globulin and β globulins are decreased while α_2 globulins are increased (41). Serum cholesterol levels rise (approx. from 70 mg% to 600 mg%) during the nephrotic stage

associated with a rise of urea nitrogen (42). Changes in electrolyte levels of the serum and extracellular fluid also occurred, the sodium concentration increased while the potassium concentration fell (1).

a) Mechanisms of Proteinuria

The presence of protein in the urine is an indication of altered glomerular function with the leakage of plasma proteins through the glomerular basement membrane into the urinary space, and the inability of the tubular system to adequately re-absorb the materials.

As the mechanism whereby protein passage through the glomerular basement membrane is still poorly understood. One of the main aims of this thesis was to study the sequence of events that occurred in the kidney following proteinuria induced by aminonucleoside.

The major stumbling block in the investigation of proteinuria has been due to lack of information on the mechanism of the transfer of plasma proteins across the glomerular basement membrane.

On the one hand it is postulated that plasma proteins pass through endothelial membrane pores and then diffuse through the glomerular basement membrane. The basement membrane consists mainly of a collagen like substance and a glycoprotein (43) and is said to act as a semi-permeable differential filter between the plasma and

Bowman's space containing the glomerular filtrate. When basement membrane thickening occurs as seen in experimental nephrosis, changes in the physico-chemical composition of the membranes occur which are compatible with a molecular re-arrangement of membrane components, so that the interstices between their molecules become larger and permit the passage of large molecules such as plasma proteins.

On the other hand the concept of an active process being involved in the production of glomerular fluid cannot be disregarded particularly following the work of Chinard (44), who investigated the theoretical rate of formation of glomerular fluid across capillary walls. His results suggest that the whole capillary surface is involved in the passage of water across the membrane rather than just the intercellular cement substance.

Associated with the transfer of solutes and macromolecules across the basement membrane, is the problem of the origin of the membrane itself. Kurtz and Feldman (45) permanently labelled the glomerular basement membrane of rats with silver nitrate ingested in drinking water. After labelling the silver nitrate was stopped. Thickening of the basement membrane was effected by normal aging of of rats or by the administration of aminonucleoside. In both groups of rats new increments of glomerular basement membrane were free of silver, while the original lamina densa was diffusely and homogenously stippled by silver

deposits. The experiments demonstrated that glomerular basement membranes were a product of the epithelial cells, both in the normal processes of aging and in the pathological processes of aminonucleoside nephrosis. This view is also supported by Jørgensen (46,47) in his studies with human glomerular basement membrane. These findings are in contradiction to recent immunological studies which postulate that the endothelial cell is responsible for at least part of the glomerular basement membrane which is thickened during aminonucleoside nephrosis (48).

In conclusion, the mechanisms whereby proteinuria occurs in nephrosis most probably involves both active and passive processes. Plasma proteins that are transferred across endothelial cells are most probably incorporated as basement membrane components. Toxic agents may interfere with endothelial and epithelial cell function and possibly increase the transfer of plasma proteins across the endothelial cytoplasm. In addition there is a possibility a defective basement membrane may be synthesized. Alternatively, endothelial cells may contract following injury, and leave large areas of basement membrane exposed in the capillary lumen. Increased plasma diffusion will occur in the region of exposed basement membranes with a subsequent increase of

protein in glomerular filtrate. The epithelial cell changes are most probably secondary to the increased plasma transfer across the membrane.

b) Mechanism of Hyperlipaemia in Nephrosis

Banson et al (49-50) demonstrated that proteinuria regardless of aetiology increased the levels of circulating neutral lipids. Because of protein loss in the urine, large amounts of amino acids including methionine were lost in the urine. This reduction of methionine concentration reduced the availability of methyl groups necessary for the biosynthesis of choline. The reduction of choline levels interferes with the hepatic synthesis of lipoproteins which are involved in lipid metabolism and results in a large accumulation of circulating neutral lipids (51). These changes can also be seen with rats fed on a choline deficient diet. Increased synthesis of cholesterol has been reported both in vivo and in vitro following aminonucleoside (52,53). A negative feedback mechanism was suggested to explain these findings (54), the rate of cholesterol biosynthesis being dependent on the hepatic concentration of cholesterol.

c) Carbohydrate Metabolism in Nephrosis

Decreased glycogen concentrations were found in the livers of nephrotic rats, independent of the food intake (55). Increased levels of oxaloacetate in the

kidney and muscle was demonstrated by Metcoff and his co-workers (56) in aminonucleoside treated rats, but this increase was not seen in the liver. The above group also demonstrated increased tricarboxylic acid cycle turnover, associated with an interference of citrate incorporation into the cycle which they felt might be the specific biochemical lesion in this type of nephrosis. However, a decrease in the amino acid or protein synthesis associated with the above findings was not reported.

d) Enzyme Changes in the Rat Following Aminonucleoside

Dubach and Recant (57,58) investigated the enzyme changes in renal glomeruli, and whole kidney homogenates in aminonucleoside nephrosis and found that alkaline phosphatase levels were reduced significantly while glucose-6-phosphodehydrogenase levels increased. Hexokinase activity was also increased in both treated glomeruli and tubules. Glucose-6-phosphodehydrogenase levels were also increased in the liver following aminonucleoside administration, but occurred prior to the development of proteinuria. Increase of hepatic glucose-6-phosphodehydrogenase activity was considered to be directly related to the action of aminonucleoside, and not secondary to protein loss in the urine, as the increased levels of activity were demonstrated prior to protein loss in the urine. Once proteinuria developed

the high levels of hepatic glucose-6-phosphodehydrogenase fell, but remained significantly higher than normal. Alkaline phosphatase levels on the other hand fell markedly in the latent phase following aminonucleoside both in the liver and particularly in the kidney, and gradually returned to just below normal levels once proteinuria was established.

D. The In Vitro Action of Aminonucleoside

Except for a recent paper that demonstrated no changes in chloroplasts following aminonucleoside (59), no reports have been published on the effect of aminonucleoside on the ultrastructure of unicellular or tissue culture cells.

i. Biochemical Effect of Aminonucleoside on Mouse Fibroblast L Cells

The effect of aminonucleoside on L cells in tissue culture has been extensively investigated by Farnham and Dubin (60). Ribonucleic acid (RNA) from normal and aminonucleoside treated cells was fractionated by sucrose density gradients and analysed for base composition. When aminonucleoside produced about 50% inhibition in overall RNA synthesis, there appeared to be a relative preservation of soluble ribonucleic acid (sRNA) and messenger ribonucleic acid (mRNA) synthesis. Calculations made on the basis of base composition indicated that

whereas ribosomal RNA synthesis (rRNA) in the aminonucleoside treated cells was inhibited by only about 10%. From these experiments it became clear that aminonucleoside induced a preferential inhibition of ribosomal RNA synthesis, followed by a slowing of protein synthesis.

The mechanism of how aminonucleoside interferes with RNA synthesis is not known, however it has been suggested by Dickie et al (61) that in E. coli spheroblasts, aminonucleoside inhibits nucleic acid synthesis by mimicking adenosine as a feedback inhibitor of de novo purine synthesis. However, Farnham (60) suggested that aminonucleoside either as such, or after incorporation into sRNA acted as an analogue of uncharged sRNA which interfered with the cellular RNA synthesizing system (RNA polymerases). The uncharged soluble RNA would not by itself deplete the charged soluble RNA species and would therefore support a relatively normal rate of protein synthesis. These reports also explained the ability of the RNA containing encephalomyelitis virus to replicate in aminonucleoside treated L cells, the viral RNA polymerase being insensitive to the uncharged sRNA (Farnham), (62).

ii. Biochemical Effect of Aminonucleoside on HeLa Cells

Studzinski et al (63-64) in studying the action of aminonucleoside on HeLa cells found similar biochemical changes as those reported by Farnham (60) on L cells. Monolayers of HeLa cells were treated with varying concentrations of aminonucleoside. Analyses of DNA, RNA and protein content were then undertaken using p^{32} and H^3 thymidine as tracers for nucleic acid synthesis. Taking the rate of incorporation of the isotopic precursor as a measure of nucleic acid synthesis, they were able to demonstrate that concentrations of aminonucleoside which had a rapid effect on the rate of cell division inhibited the synthesis of all types of nucleic acids and of protein, but depressed ribosomal RNA most markedly. Conversely, lower concentrations of aminonucleoside selectively inhibited ribosomal RNA, and to a lesser extent sRNA synthesis. At these concentrations no effect on the rate of cell division was observed.

iii. Biochemical Effects of Aminonucleoside on Euglena Gracilis

Selsky (59) has recently investigated the effect of puromycin aminonucleoside on the growth and chloroplast development of the unicellular plant like organism called Euglena Gracilis. In cells treated with sufficient levels of aminonucleoside that markedly inhibited their growth

(100 μg), no effect could be demonstrated either biochemically or morphologically in their chloroplasts, which continued to synthesize chlorophyll. Since the chloroplast of Euglena has a unique type of DNA (65), and a specific type of 70S ribosome (66-67), the findings may indicate that nucleic acid and protein synthetic control systems in chloroplasts may be refractory to aminonucleoside in the intact cell. As cytoplasmic ribosomes are predominately of the 80S type and the chloroplast ribosomes are predominately of the 70S type, the author suggested that aminonucleoside may have a selective inhibitory action on the formation of 80S ribosomes.

Summary of Main Bibliographical Data

Aminonucleoside is a dimethyl adenosine analogue that inhibits ribosomal RNA synthesis of HeLa and mouse fibroblast L cells, with subsequent inhibition of their growth.

In the rat, aminonucleoside injected subcutaneously or intravenously produces a nephrotic syndrome after a latent period. The biochemical and morphological changes in the rat kidneys are not unlike those seen in lipoid nephrosis of childhood.

The exact mechanism whereby aminonucleoside can cause renal lesions is not known, however recent evidence

has shown that plasma glycoprotein biosynthesis is increased in the latent period, indicating that the liver in some way is involved in the pathogenesis of aminonucleoside nephrosis.

Chapter III. MATERIALS AND METHODS

i. Aminonucleoside:

The aminonucleoside of Puromycin 6-dimethylamino-9- (3' amino-3-deoxy-B-D-Ribofuranosyl)-purine was obtained from the Lederle Medical Research Section, American Cyanamid Company.

ii. Animals:

Male adult Wistar Albino rats weighing approximately 300 - 350 grams were used. The animals were fed ad lib (unless indicated otherwise) throughout the experiments and housed in metabolic cages.

iii. Tissue Culture Cells:

A line of HeLa (GEY) cells was used, obtained from Microbiological Associates, Maryland, U.S.A., and maintained in basal medium (Eagle) with Hanks balanced salt solution containing 10% inactivated sheeps serum. Tissue culture cells were grown in 30 ml. flasks (Falcon Plastics, Los Angeles, Calif.) which were pre-sterilised, and also in Leighton tubes (85 x 15 mm, Bellco, U.S.A.) containing coverslips.

iv. Tissue Culture Medium:

a) Hanks basal medium (Eagle, 68) is a synthetic medium containing an almost complete complement of amino acids, vitamins and accessory growth factors. The medium was obtained as a tenfold concentrate from Microbiological

Associates, U.S.A. To the above diluted medium, 10% inactivated sheep serum (Grand Island Biological Co., U.S.A.), sodium bicarbonate (1.0 ml. of a 7.5% bicarbonate solution per 100 ml.), penicillin, 250 units per ml. (Connaught Medical Research Laboratory, Toronto), streptomycin (Glaxo-Allenbury) 100 micrograms per ml., and pyrrolidinomethyl tetracycline (Reverin, Hoechst) 10 micrograms per ml. was added, the whole medium being suitable for HeLa cell growth. The same solution was also used as a maintenance medium.

b) Saline A: is a balanced salt solution containing neither calcium or magnesium ions. It was prepared according to the original description (Puck et al, 69). This solution was used for washing cell monolayers prior to trypsin treatment.

c) Trypsin-Versene (ATV) Solution: This was prepared by dissolving 0.2 G of sodium ethylenediamine tetra-acetate (versene) and 0.5 G trypsin (DIFCO 1:250) in a litre of saline A. The solution was sterilised by filtration through a millipore filter (pore size 0.05), and frozen in 10 ml. aliquots.

v. Radioactive Chemicals:

a) (^{14}C) Glucosamine and (^{14}C) Leucine: Labelled D-Glucosamine 1-C^{14} HCL was purchased from New England Nuclear at a specific activity of 8.9 mC/m mole.

Uniformly labelled (^{14}C) Leucine was purchased from New England Nuclear at a specific activity of 240 mC/m mole. The purity of (^{14}C) Glucosamine was tested by paper chromatography using a n-Butanol-Pyridine-water (5:3:2, by vol.) solvent, followed by radioautography. One radioactive spot was found with the mobility of D-Glucosamine.

b) (^{131}I) Iodide: Sodium (^{131}I) Iodide (IBS-3) was obtained from the Radiochemical Centre, Amersham, and was the distillate from the target material collected in 0.02-0.04 N NACH. The material was specified as being between pH 8 and 11, and thiosulphate and carrier free, with an isotope abundance of not less than 90%.

vi. Albumin:

Crystalline bovine plasma albumin was obtained from Armour and used as a standard control in protein determinations.

vii. Histological Fixatives:

a) For paraffin-embedded material liver and kidney sections that were to be stained with haematoxylin and eosin were fixed in Stieve's fluid, containing saturated mercuric chloride solution (76 ml.), formalin (20 ml.) and acetic acid (4 ml.).

b) For epoxy-embedded material either osmium alone or glutaraldehyde followed by osmium were used as fixatives, for specimens used for electron microscopy. Equal quantities of an aqueous solution of 2% osmium tetroxide and 0.2M Sorensen's phosphate buffer (Gomori, 70) at pH 7.2 were mixed to make a 1% working solution.

c) For coverslips For haematoxylin-eosin staining, cultures grown on coverslips were fixed in a solution consisting of methanol (94 ml.), formalin (5 ml.) and acetic acid (1 ml.).

viii. Staining:

a) For paraffin sections These were stained with haematoxylin and eosin and periodic acid-schiff reagent (with and without diastase).

b) For epoxy-embedded material half micron sections were stained at 50°C with 5% toluidine blue, buffered to approximately pH9 with an equal quantity of 5% sodium bicarbonate, according to the method of Trump et al (71). Ultrathin sections to be examined with the electron microscope were stained with lead hydroxide according to the method described by Karnovsky (72).

c) For coverslips Coverslip cultures were stained with haematoxylin and eosin using Harris' haematoxylin and 1% aqueous eosin Y.

A. General Tissue Culture Procedures

i) Trypsin Treatment of Tissue Culture Cells: HeLa cells were grown in 8 oz. milk dilution bottles at 37°C. When the monolayer was almost confluent, the cells were trypsinized in the following manner:

The nutrient fluid was decanted off and 5 ccs of a warm ATV solution was added, the pH being adjusted to 7.6 with sodium bicarbonate. The cells were incubated at 37°C until they loosened from the glass. The cell suspension was then pipetted into sterile tubes and centrifuged at 2000 revs/min. for 10 minutes. The supernatant was discarded and the cellular pellet was then resuspended in 5 ml. of fresh medium, vigorous pipetting being undertaken to ensure proper cell dispersal in solution. The suspension contained about 100,000 cells per ml., estimated by counting an aliquot of cells stained with crystal violet using a hemocytometer. The cell suspension was then dispensed into the appropriate tubes or bottles.

The optimum time for trypsin treatment was every five to seven days. Two to three days after addition of trypsin the media was gently decanted off and fresh media added. This procedure was repeated every two to three days thereafter.

ii) Flask Cultures: Cell suspensions in 5 ml. amounts were dispensed into 2 oz. sterile plastic flasks and incubated at 37°C. When a partial monolayer had formed, usually 3 days after inoculation, the medium was gently removed from the flask, and replaced by 5 ml. of fresh medium, or by an equivalent amount of medium containing aminonucleoside.

iii) Coverslip Cultures: For histological studies cell cultures were prepared in short Leighton tubes containing flying coverslips. Each Leighton tube was inoculated with 2 ml. of cell suspension in growth medium and incubated in a horizontal position at 37°C. When ready for use, each coverslip was transferred to a fresh Leighton tube, and 2 ml. of maintainance medium added.

iv) Electron Microscopy of Tissue Culture: General Method: For electron microscopy 2 oz. flask cultures were used. Monolayer cultures (3 days incubation) had their medium discarded and replaced either by normal medium or a medium containing 100 μg/ml. of aminonucleoside. At 24 hour intervals up to 72 hours, cells were fixed and embedded.

Cultures to be embedded were first drained of their tissue fluid. About 5 ml. of fixative was then gently added. Cells were fixed in 0.1 M Osmium tetroxide for

one hour. The fixative was permitted to remain on the cells for five minutes. Then using a plastic policeman, the cells were gently scraped off into the fixative. Cells and fixative were transferred to a centrifuge tube and centrifuged at 4° for ten minutes at 2500G. The supernatant fixative was then removed and fresh osmium added. The pellet was then lifted and cut into 0.5 mm fragments. The fixation was completed at 4° for 45 minutes. The fragments were then washed with 0.1 M phosphate buffer and transferred to 70% alcohol. The tissue was then processed and sections were prepared for electron microscopy as described under Histologic Methods of rat liver and kidney.

v) Biochemical Studies on Tissue Culture:

a) Incorporation of (^{14}C) Leucine into Protein of HeLa Cells 2 oz. flask cultures were used. Monolayer cultures were incubated with Hanks basal medium (Eagle) without L-Leucine in the amino acid complement. To the above 1 μc of (^{14}C) Leucine was added per 5 cc of medium, with or without 100 μg/ml. of aminonucleoside. The cells were allowed to incubate in the flasks at $37^{o}C$ for varying lengths of time up to 24 hours, and were treated with trypsin. These trypsinized cell suspensions were then passed into glass tubes and centrifuged at 2000 revs/min. for 10 minutes, the supernatant being discarded after

centrifugation. Protein in the cellular homogenate was first precipitated with cold trichloracetic acid (3 x volume of 10% TCA added to 1 vol. of cell suspension) and allowed to stand for 10 minutes at 5°C. The TCA precipitated solution was then centrifuged at 1500G for 10 minutes and the supernatant discarded. A lipid solvent was then added to the precipitate (20 volumes of a chloroform-methanol-ether 2:1:1 solution). The mixture was shaken in the cold, and then centrifuged at 10,000G for 5 minutes. The clear extract containing lipids was discarded. The precipitated protein was resuspended in 2 ml. of 1 N NaOH and heated (at 60°C) for 10 minutes. The clear protein solution obtained could then be quantitatively measured by Lowry's method (72). Radioactivity of this protein solution was also determined by drying 100 µl of the solution onto counting planchettes and inserting these planchettes into a low background gas flow counter (Nuclear Chicago Low Background Gas Flow Counter (Model 1043) with a Micromil "R" window, and perfused with a 1.3% Butane and 98.7% Helium gas mixture).

HeLa cell protein could therefore be calculated at varying times of incubation with labelled medium. The specific activity of protein was expressed as counts per minute per milligram of protein (CPM/mg. of protein).

STANDARD PROTEIN CURVE (LOWRY) 21-AUG.67

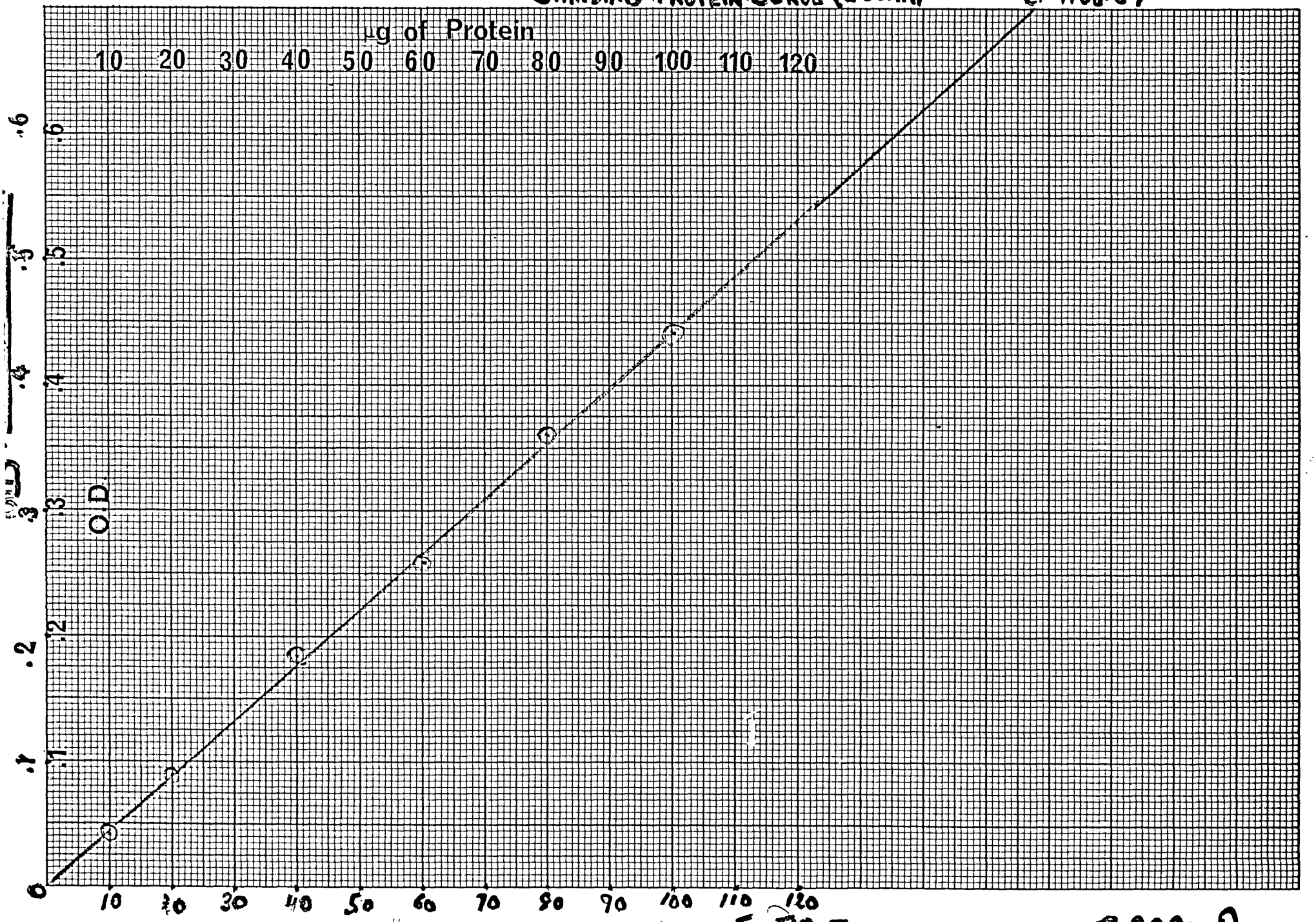

b) Protein Determination (Lowry's Method, 72)

Standards for Standard Curve (see Graph A opposite page)

	1	2	3	4	5	6
H_2O	4.8	4.6	4.2	3.8	3.4	3.0
BSA (500µg/ml.)	0.2	0.4	0.8	1.2	1.6	2.0
µg/ml. BSA in sample	20	40	80	120	160	200
Assay (½ cc) µg	10	20	40	60	80	100

½ cc of each standard sample is taken for assay.

B.S.A.: Bovine Standard Albumin.

Reagents:

A) 2% Na_2CO_3 in 0.1 N NaOH. To make up to 500 ccs 10 gms Na_2CO 50 cc in NaOH make up to 500 ccs with distilled water.

B) 0.5% $CuSo_4$. 5 H_2O in 1% SOD/POT tartarate.

C) Alkaline copper solution. Mix 50 cc of reagent A with 1 cc of reagent B.

D) Dilute folin reagent: Folin-Ciocalteu phenol reagent 5 cc 5.5 cc H_2O.

Assay:

i) ½ cc of protein solutions taken for assay (Protein test solutions diluted X10 before assay)

ii) 3.0 cc of reagent C is added to ½ cc assay material. Solution mixed and kept for 10 minutes.

iii) 0.3 cc of reagent D is then added, mixed quickly and left for 30 minutes.

iv) Optical density of solution is then read at 750 mμ.

v) Standard protein curve (O.D against concentration) will be derived from known protein concentration. The unknown protein concentrations can then be read off standard curve, if optical density known.

c) Incorporation of (^{14}C) Glucosamine into Glyco-Protein of HeLa Cells. Experimental procedures were similar to those employed with (^{14}C) leucine, except that monolayer cultures were incubated with Hanks basal medium (Eagle) containing all amino acids including L-leucine. To the above 1 μc of (^{14}C) glucosamine per 5 ml. of medium was added, and the cells were incubated with and without aminonucleoside. Incubation times were similar to (^{14}C) leucine studies (i.e. cells were harvested at 2,4,6,8,9,10,11,12 and 24 hours), and the specific activities of (^{14}C) glucosamine incorporation into HeLa cell protein at these times could be determined.

B. The Action of Aminonucleoside on the Rat

1) Morphological Studies: Four groups of adult male Wistar rats were tested, each group containing four rats, one rat of each group being used as a control.

Each group experiment was repeated once. (see chart).

Rat Group	No.	Time rat sacrificed after intravenous aminonucleoside						I.V Saline Control	
		1 hr.	2 hr.	6 hr.	24 hr.	4 days	7 days	1 hr.	24 hr.
1	1				X	X	X		X
2	2				X	X	X		X
3	3				X	X	X		X
4	4	X	X	X	X			X	

Chart to demonstrate time of sacrifice (X) following intravenous administration

Rats of groups 1 and 2 were starved 14 hours prior to sacrifice, while rat groups 3 and 4 were fed ad libitum. All groups were sacrificed by decapitation. All the treated animals were given a single dose of 1.5 cc of a 1% aminonucleoside solution in 0.45% saline into the jugular vein. The vein was exposed surgically under ether anaesthesia, and closed with Michelle's surgical clips.

The liver and kidneys of the rats were removed immediately after sacrifice and processed for light and electron microscopy.

Histological Methods:

a) Light Microscopy of Rat Specimens: Specimens of liver and kidney were taken from each animal and fixed in Stieve's solution for 24 hours. The tissues

were then dehydrated, embedded in paraffin, and stained with haematoxylin and eosin or periodic acid-schiff reagent (with and without diastase).

b) Electron Microscopy of Rat Specimens: Specimens of liver and kidney were fixed in 0.1 M buffered osmium for one hour, or in 6.25% gluteraldehyde for one half hour, followed by osmium fixation for 45 minutes. Small portions of tissue were cut into blocks about 0.5 mm square while immersed in fixative. Following fixation tissues were processed in the following manner, (modified after Luft, 73):

A) wash with 0.1 M phosphate buffer 70% alcohol for 30 minutes

B) 90% alcohol for 30 minutes

C) two changes of absolute alcohol, each 30 minutes

D) two changes of propylene oxide, each for 15 minutes

E) two changes of propylene oxide/epon araldite mix (equal parts), each for 60 minutes

Tissue was then either left in the final propylene oxide/epon-araldite mixture overnight or embedded immediately in gelatin capsules filled with epon-araldite mixture. The epon-araldite mixture was composed of araldite 502 (20 ml.), epon 812 (25 ml.), dodecenyl succinic anhydride (DDSA) (60 ml.) and accelerator 2, 4, 6 - TR1 (dimethylaminomethyl) phenol (DMP 30) (2-3 ml.).

The first three ingredients were mixed for 30 minutes, then the DMP added and the whole solution mixed a further 30 minutes. It was then placed under vacuum for 60 minutes to remove any air bubbles.

Tissues were placed in capsules containing epon-araldite, and capsules were placed in a 60°C oven for three days. At the end of this period blocks were trimmed and sectioned with glass knives in either a Servall Porter-Blum microtome or with an LKB microtome. For light microscopy sections were cut 1 micron thick. These were stained with 5% toluidine blue. For electron microscopy, silver sections were cut, placed on 200 mesh copper grids and stained with lead hydroxide for 10 minutes (74). These sections were examined and photographed in a RCA-EMU-3G, JEM 6-C or a Phillips 200 electron microscope.

2) Biochemical Studies:

a) Incorporation of (^{14}C) Glucosamine into Plasma Proteins of Rat as a Measure of Glycoprotein Biosynthesis: This procedure consisted of the intravenous injection of 5 μc of glucosamine-1-C^{14} via the jugular vein. Blood samples (0.5 ml.) were withdrawn from the vein at the appropriate intervals, (e.g. 30,60,90,120,150 and 180 minutes after C^{14} glucosamine injection), and added to 0.5 ml. cold 0.9% saline. The protein was precipitated

with an equal volume of 20% trichloracetic acid, and then resuspended in a mixture of chloroform:methanol: ether (2:1:1) to extract lipids. This solution was then centrifuged and supernatent discarded. The pellet containing protein was then dissolved in 0.5 ml. of 0.5 N sodium hydroxide. One portion (100 µl) was placed onto a planchette and counted in a Nuclear Chicago, gas flow, low background counter. A second portion (100 µl) was used for the determination of protein concentration by the method of Lowry et al (72) using bovine serum albumin as standard protein. The specific activity was expressed as CPM/mgm protein.

Glucosamine (C^{14}) incorporation into rat plasma proteins was measured 6½ hours, 17½ hours, 24 hours, 48 hours, 72 hours and 96 hours after a single intravenous dose of 1.5 ml. of a 1% aminonucleoside solution. The results obtained were compared to glucosamine C^{14} incorporation into rat plasma measured at comparable times after a single intravenous dose of saline (0.45%).

b) <u>Fractionation of Rat Plasma Proteins Labelled with C^{14} Glucosamine using Gel Filtration</u>: Rat serum (3 ml.) labelled with C^{14} glucosamine from normal and aminonucleoside treated rats was fractionated by gel filtration on a Sephadex G-200 column.

The column had a bed dimension of 4.2 x 73.5 cm (Sephadex Column K50/100, Pharmacia, Sweden) and was packed with buffered Sephadex Gel G-200 (Pharmacia). (Sephadex G-200 has a particle diameter of 40 to 120μ, and a fractionation range of peptides and globular proteins from molecular weight 5,000 to 800,000).

The serum was eluted with 0.1 M TRIS/HCL buffer at pH 8 and 1 molar NaCl (75) and the flow rate regulated to run at 15 ml. per hour. Fifteen ml. fractions were collected in labelled tubes by means of an automatic fraction collector (Gilson). The optical density of the eluant was constantly monitored at 280mμ with a U.V. spectrometer (Gilford Model 2000 Multiple Sample Absorbance Recorder). In addition each fraction had its protein concentration measured by the Lowry's method (72), and also its radioactivity by means of a low background gas flow counter.

Single or pooled plasma protein fractions were dialysed in cellulose dialysis tubing against distilled water for 48 hours with 8 changes of water, and the dialysed fractions were then lyophilised (Freeze Dryer, New Brunswick Scientific Co. Inc., U.S.A.). The lyophilised fractions were stored in sterilised glass bottles in a dessicator.

c) The Action of Labelled Radioactive Plasma Fractions on Isolated Rat Kidney Glomeruli: In order to determine whether plasma glycoprotein fractions were in equilibrium or biochemically related to the glycoprotein constituent of glomerular basement membrane, radioactive iodinated plasma glycoprotein fractions were allowed to incubate with known numbers of rat glomeruli. After incubation under varying conditions the glomeruli were washed with phosphate buffer and their radioactivity determined. The amount of radioactivity so found in the glomeruli was taken as being proportional to the amount of labelled serum protein absorbed of the glomeruli.

a) Preparation of I^{131} Labelled Plasma Protein Fractions: (Modified after the method of Greenwood, Hunter and Glover, 76). The pre-albumin plasma glycoprotein fractions from normal and aminonucleoside treated rats were obtained by gel filtration through Sephadex G-200 columns. These fractions were then labelled with I^{131} and acquired a high specific activity. The affinity of the plasma protein fractions for renal glomeruli could therefore be investigated by radioisotope tracing methods.

The iodinated protein fractions had first to be separated from I^{131} iodide, and this separation was

carried out by gel filtration through a Sephadex G-25 (Pharmacia) column (25 x 2 cm) equilibrated with an ammonium carbonate buffer at pH 8.6 and presaturated with crystalline bovine plasma albumin (20 mg). One mg. of protein fraction was added to an iodinated reaction mixture containing sodium metabisulphite (240 μg), chloramine T (800 μg), KI (5 μg) and about 1 mc of $(I)^{131}$ iodide, in a volume of 0.4 ml. The reaction mixture was eluted with the 0.1 M ammonium carbonate buffer, the iodinated protein fraction appeared in the void volume (40 ml.) followed by a larger iodide peak (100 ml.). Eluates were collected in 3 ml. fractions, and their radioactivity was determined by a Nuclear Chicago Gamma Counter (Model 4216) using an automatic scintillation system.

b) Preparation of a Crude Mass of Glomeruli: (Modified after Steblay, 77). In order to determine the relationship of certain plasma protein fractions to glomeruli, their separation from whole kidneys was as follows:

Rats were killed by decapitation and their kidneys were immediately removed. The kidneys were then decapsulated and gently squeezed through a sieve (mesh 100) over a beaker containing normal saline (about 100 ml. for 2 kidneys). The cellular suspension was allowed to stand

at 5°C for 1 hour, after which the upper layer of saline containing tubules etc. was suctioned off, the glomeruli having settled at the bottom of the beaker. The glomeruli were resuspended in saline and the procedure repeated twice, in order to obtain a better yield of pure glomeruli. The number of glomeruli in the final suspension could be determined with a haemolytometer.

c) Protein Electrophoresis: Protein fractions were characterised electrophoretically using the starch gel method of Smithies (78). TRIS borate starch gels at pH 8.6 were used. Following application of protein sample current (140 volts at 20 milliamps.) was run for 18 hours. Protein on gels were stained with amidoblack and washed with acetic acid.

Chapter IV. RESULTS

A) The Action of Aminonucleoside on HeLa Cells

1. Morphological Findings:

a) Light Microscopy: Coverslips introduced into Leighton tubes containing a suspension of HeLa cells, were fully covered with a sheet of cells when incubated in normal medium for six days. HeLa cells were observed to be spindle or polygonal in shape with an average surface area of 350 square microns. The cells had a large central nucleus which occupied just over 50% of the surface of the flattened cell. The nuclei contained on the average three to four prominent nucleoli which were irregular in shape and size. The cytoplasm of these cells under light microscopy looked granular, and occasionally contained a few clear vesicles (Fig. 2). Many HeLa cells were observed to be undergoing mitosis. HeLa cells grown on coverslips in normal medium for three days and then medium containing aminonucleoside (100 μg/ml.) for a further three days, tended to form isolated cellular clusters. The aminonucleoside treated cells were smaller in size (ca300 sq. microns), their nuclei contained multiple spherical and punctate nuclei (Fig. 3). The cytoplasm of the treated cells contained numerous vesicles, which increased the

longer the cells were exposed to aminonucleoside. Mitotic figures were rarely seen in these cells. Similar findings were observed in epon-embedded HeLa cells stained with toluidine blue (Fig. 4 and Fig. 5).

b) Electron Microscopy:

i) Normal HeLa cells: HeLa cells under electron microscopy were spindle shaped, oval or round, with microvilli projecting from their cell surfaces (Fig. 6 and 6A). The microvilli were particularly prominent in those cells which were not in contact with other cells.

HeLa cells contained large nuclei which occupied at least 50% of the volume of the cell and were surrounded by a well formed double nuclear membrane, penetrated by a number of nuclear pores. The nucleoplasm consisted of a finely fibrous or granular material of different density, with the chromatin concentrated either along the nuclear envelope or divided into small sized aggregates. Within the nucleus of most cells two or three prominent nucleoli were often observed. The nucleolar components were well differentiated into fibrillar, granular and amorphous components (Fig. 7), the granular component being often in contact with the nuclear membrane.

The cytoplasm contained numerous small vesicles to which ribosomes were attached and which was part of the rough endoplasmic reticulum of the cell. Ribosomes were also present in large numbers free in the hyaloplasm. A well developed golgi apparatus was present in most cells, with vesicles often extending for some distance into the surrounding cytoplasm. Mitochondria were fairly numerous in most cells, other organelles such as multivesicular bodies being much less in evidence.

ii) Aminonucleoside Treated Cells: HeLa cells grown in medium containing aminonucleoside (100 μg/ml.) showed ultrastructural changes as early as 12 hours following treatment. Maximal ultrastructural changes were seen if cells were incubated with aminonucleoside for 72 hours. The changes primarily involved the nucleolar components of the nucleus, and consisted of a progressive decrease in the size of the nucleoli, with condensation and redistribution of their components (Fig. 8).

The fibrillar component became compact and globular and frequently migrated to the periphery of the nucleolus (Fig. 9). Some of the fibrillar material was often observed adjacent to the nucleolus and seemed to have recently been extruded from that structure (Fig. 10).

Nuclear bodies, inclusions or nucleolar satellites of the same consistency as the fibrillar components were frequently observed in cells incubated with aminonucleoside for longer than 48 hours (Fig. 11). The amorphous components of the aminonucleoside treated nucleolus was lighter than normal, and contained darkly stained particulate bodies of unknown origin which were also present in the nucleoplasm but were not observed in normal HeLa cell nuclei (Fig. 9). Large cytoplasmic osmophilic vesicles were seen in some treated cells, while others contained abnormally shaped mitochondria. Although these cytoplasmic changes were observed in many aminonucleoside treated cells, these changes were not constant as those observed in the nucleoli.

2. HeLa Cell Growth: Aminonucleoside (100μg/ml) was added to Hanks' basal medium (Eagle) to study its effect on the growth rate of HeLa cells. The cells were grown in 2 oz. flasks in medium with and without aminonucleoside. At 24 hour intervals for a duration of 96 hours, two flasks from each group were treated with trypsin and resuspended in medium, the number of cells in these suspensions being determined with a haemocytometer. The average cell count from two culture flasks was that recorded.

As can be seen in Diagram 1, the growth was inhibited in those cells grown in medium containing aminonucleoside. HeLa cells initially treated with aminonucleoside and then given fresh normal medium resumed growth only very slowly after a lag period of 24 hours.

Diagram 1. Inhibition of HeLa Cell Growth by Aminonucleoside.

Total number of cells in flasks is plotted against time of incubation in normal and aminonucleoside (100 μg/ml.) containing medium.

A) cells incubated with normal medium

B) cells incubated with medium containing aminonucleoside

C) cells incubated with medium containing aminonucleoside for 48 hours, followed by normal medium

THE EFFECT OF AMINONUCLEOSIDE ON HELA CELL GROWTH

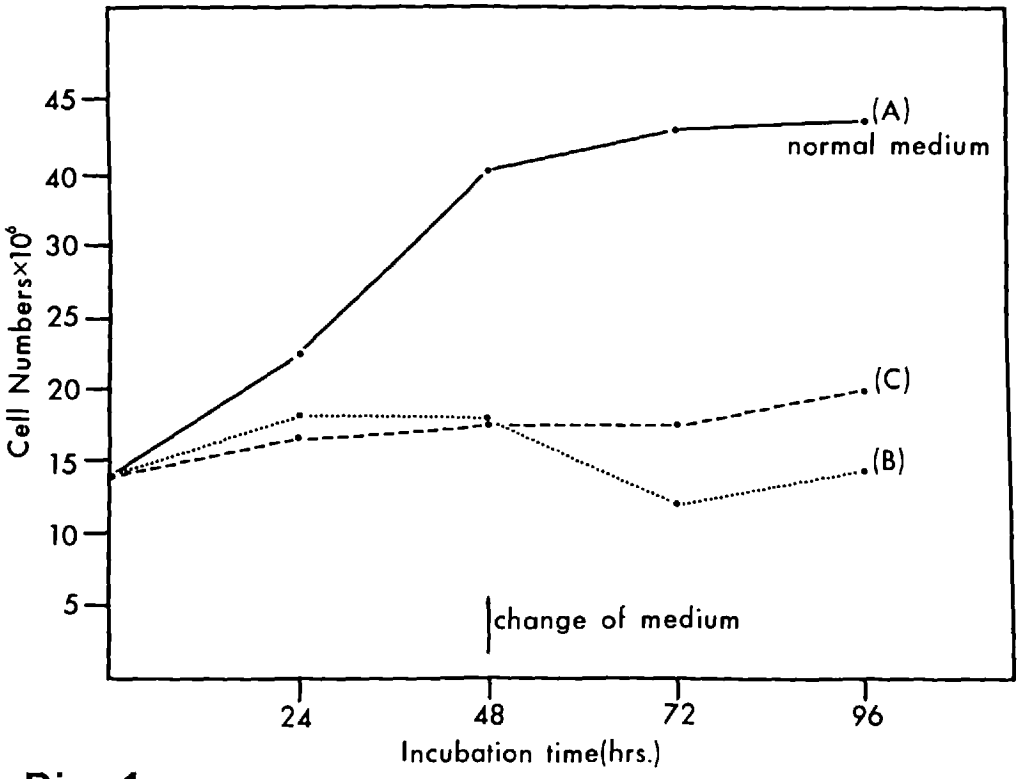

Diag·1

3. Effect of Aminonucleoside on Protein Biosynthesis:

The incorporation of C^{14} leucine into HeLa cell proteins was undertaken to determine whether the inhibition of HeLa cell growth following aminonucleoside was related to an inhibition of protein synthesis. On the other hand, C^{14} glucosamine incorporation into HeLa cell glycoproteins was studied to compare the results with the in vivo rat experiments.

a) Incorporation of C^{14} Leucine into HeLa Cell Proteins: Monolayer cultures (ca 1.5 x 10^7 cells per flask) were incubated with Hanks' basal medium (Eagle) without L leucine. To the above, 1 μc of (C^{14}) leucine, was added per 5 ml. of medium, with or without 100 μg/ml. of aminonucleoside. The cells were allowed to incubate in the flasks at 37°C for varying lengths of time up to 24 hours, and then were trypsinized. The trypsinized cell suspensions were centrifuged and the pellet analysed for its radioactivity and protein content. The specific activity was expressed as CPM/mg protein. (C^{14}) leucine incorporation into HeLa cells was plotted against time of incubation with labelled medium, and wasfound to be greatly reduced in those cells incubated for 48 hours in medium containing aminonucleoside (Diagram 2). If amino-nucleoside treated cells were given fresh medium containing (C^{14}) leucine, the specific activity of HeLa

cells remained lower than the control culture for about nine hours, after which the specific activity increased dramatically, reaching the control level in 12 hours. Each point on the chart represents the average specific activity of HeLa cell proteins from two flasks grown under the same experimental conditions. These experiments were repeated three times with comparable results.

b) Incorporation of (C^{14}) Glucosamine into HeLa Cell Proteins: Experimental procedures were similar to those employed with (C^{14}) leucine, except that monolayer cultures were incubated with Hanks' basal medium (Eagle) containing all aminoacids. One μc of (C^{14}) glucosamine per 5 ml. of medium was added to the cultures, and cells were incubated with and without aminonucleoside. Incubation times were similar to the (C^{14}) leucine studies. The specific activity of (C^{14}) glucosamine incorporation into HeLa cell proteins decreased following aminonucleoside treatment (Diagram 3), but this decrease was much less than that observed with (C^{14}) leucine.

Diagram 2. C^{14} Leucine Incorporation into HeLa Cell Proteins.

The specific activity of HeLa cell protein is plotted against time of incubation with medium containing C^{14} leucine.

All HeLa cells were first incubated in normal medium for 3 days. HeLa cells from Group A were incubated in normal medium for a further two days, while cells from Groups B and C were incubated in medium containing aminonucleoside (100 μg/ml.) for 2 days.

Fresh medium containing C^{14} leucine was then added as follows:

A) normal medium containing C^{14} leucine
B) medium containing aminonucleoside and C^{14} leucine
C) normal medium containing C^{14} leucine

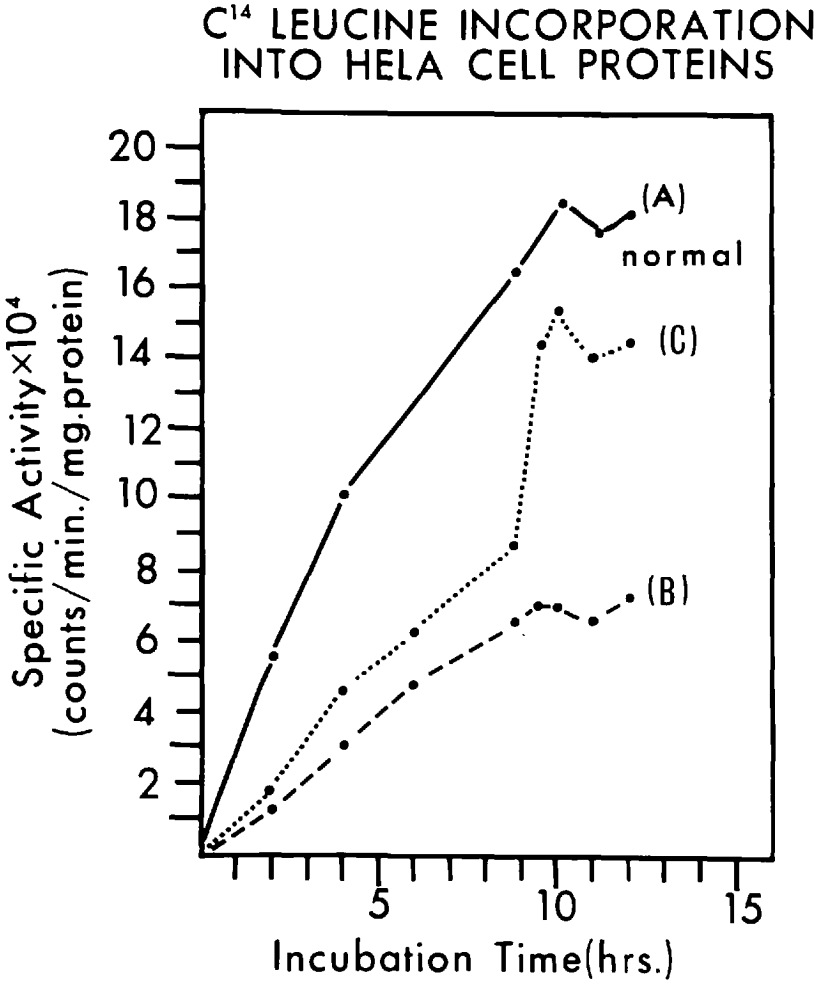
C14 LEUCINE INCORPORATION
INTO HELA CELL PROTEINS
Specific Activity×10⁴
(counts/min./mg.protein)
20
18
16
14
12
10
8
6
4
2
(A)
normal
(C)
(B)
5
10
15
Incubation Time(hrs.)

Diag-2

Diagram 3. C^{14} Glucosamine Incorporation into HeLa Cell Glycoproteins

The specific activity of HeLa cell glycoproteins is plotted against time of incubation with medium containing C^{14} glucosamine.

A) HeLa cells grown in normal medium containing C^{14} glucosamine

B) HeLa cells grown in medium containing aminonucleoside for 48 hours, and then given a medium containing aminonucleoside and C^{14} glucosamine

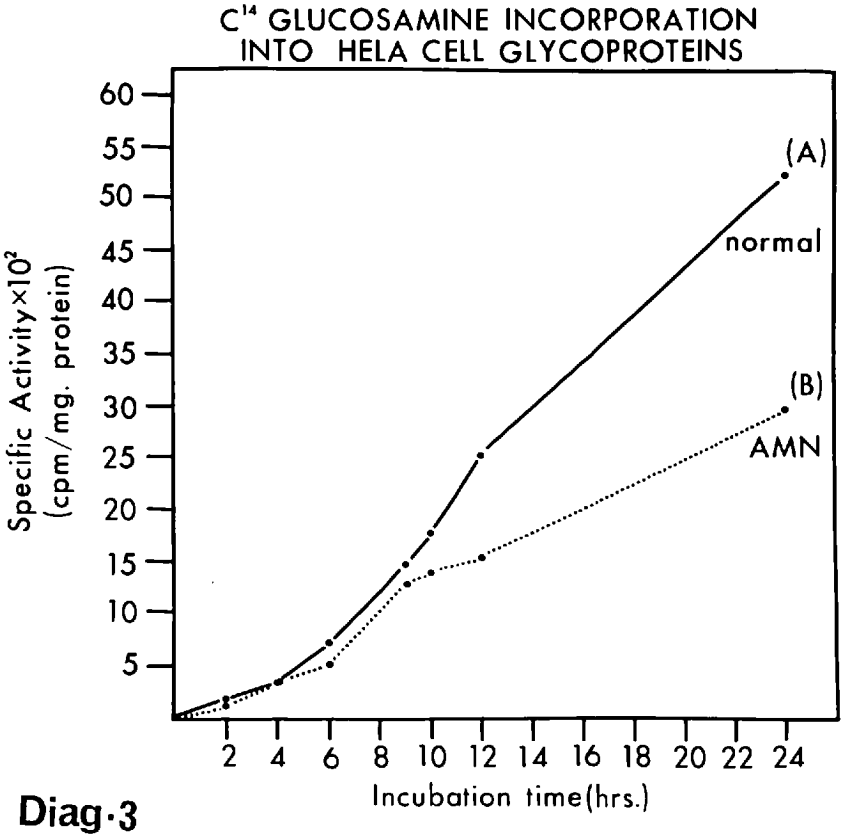
C14 GLUCOSAMINE INCORPORATION
INTO HELA CELL GLYCOPROTEINS
Specific Activity×10²
(cpm/mg. protein)
60
55
50
45
40
35
30
25
20
15
10
5
(A)
normal
(B)
AMN
2 4 6 8 10 12 14 16 18 20 22 24
Incubation time(hrs.)

Diag·3

B. The Action of Aminonucleoside on the Rat

1. Morphological Studies:

a) Light Microscopy: Kidney sections of normal rat kidney had two distinct zones consisting of an outer cortical zone and an inner medullary zone. The cortex contained most of the glomeruli, and both proximal and distal convoluted tubules, while the medulla contained mainly the tubular loops of Henle. The glomeruli were surrounded by elongated stretched epithelial cells (Bowman's capsule), and contained a number of tufts of epithelial cells which fused with the epithelial cells of Bowman's capsule at the glomerular pedicle. The glomerular tufts also contained numerous capillary loops which were lined with endothelial cells. At the glomerular pedicle in the vicinity of the afferent glomerular arteriole, a number of cuboidal cells were often seen and which were the juxtaglomerular cells.

The glomeruli were surrounded by renal tubules, the proximal convoluted tubules being differentiated from the distal convoluted tubules by having a brush border on the luminal surface of the cell. As the brush border and basement membrane contain glycoprotein, P.A.S. stains these structures as shown in Fig. 12.

No histological changes were found in sections of the kidney of rats that had been given a single intra-

venous dose of aminonucleoside 24 hours prior to sacrifice (Fig. 13). Only after 4 days following intravenous aminonucleoside were marked glomerular changes observed in the kidneys. The changes consisted of hyperplasia of the glomerular epithelial cells and were associated with an increased size of the glomeruli. The glomerular tufts were increasingly difficult to visualise individually, and were associated with a decrease in the size of capillary lumina. The basement membrane of some glomeruli were thickened, but this finding was not constant. No tubular changes were observed at this stage (Fig. 14). During the nephrotic state (7 days after intravenous aminonucleoside) marked renal changes were observed histologically (Fig. 15). The glomeruli at this stage were enlarged and swollen and were associated with epithelial cell hyperplasia, vacuolation, and basement membrane thickening. Many glomerular spaces contained a mucoproteinaceous material which often extended and filled renal tubules. Numerous renal tubular cells had cytoplasmic vacuolation, often associated with pyknosis of their nuclei. Similar histological changes were observed in epon embedded sections stained with toluidine blue.

Liver: Sections of rat liver contained numerous well demarcated lobules in which chords of hepatocytes

were separated by sinusoids and lined by Kupfer cells that converged on to a central vein. The bile ducts towards which the bile canniculi drain were situated at the periphery of the hepatic lobules in a fibrous septum associated with the hepatic artery and portal veins.

No abnormalities could be detected between normal and aminonucleoside treated liver sections fixed and embedded in paraffin. However in epon-embedded sections ratios of light hepatocytes to dark were increased over those of the controls. This pattern was observed as early as 24 hours following aminonucleoside and was more pronounced in the centrilobular and mid-zonal regions than in the peripheries of hepatic lobules (Figs. 16-17).

b) Electron Microscopy:

1) Kidney: In our material, no unequivocal ultrastructural changes were detected until four days had elapsed after injection of aminonucleoside. The changes were most prominent during the nephrotic stage of this disease.

Normal rat glomeruli (Fig. 18) often contained tufts of epithelial cells which lined the urinary space. The epithelial cells were separated from the glomerular capillaries by a distinct basement membrane. All these

structures were well visualised at the ultrastructural level. The glomerular basement membrane contained three distinct zones, which was made up of a central zone (lamina densa) and two less dense peripheral outer zones. (Lamina rara interna and lamina rara externa). The lamina densa under high power seemed to contain fine granules or fibrils, thereby suggesting cross sections of plate-like structures. The vascular surface of the basement membrane was in intimate contact with a thin layer of endothelial cell cytoplasm which was perforated by numerous pores. The glomerular epithelial cell was attached to the basement membrane by means of cytoplasmic foot processes, which were separated from other foot processes by basement membrane slits covered over by a fine membrane (slit membrane). The foot processes often contained small vesicles which looked like pinocytic vesicles. Numerous cytoplasmic organelles including mitochondria, ribosomes, golgi apparatus and ergastoplasm were found in these epithelial cells.

Mesangial cells situated between endothelial cells were observed in some glomerular sections, and were characterised by frequently having no basement membrane between their adjacent cells.

Renal tubular cells (Fig. 22) contained numerous cytoplasmic organelles particularly mitochondria. These cells had a complex infolding of their plasma membranes on their basilar surface, which was most striking in the proximal convoluted tubule. The proximal convoluted tubular epithelium had numerous regular projections on the luminal surface which formed a layer of microvilli and corresponded to the brush border observed by light microscopy.

Kidney sections from treated animals killed 24 hours after aminonucleoside administration (Fig. 19) showed no gross variance of ultrastructure as compared to normal. Some minor degrees of swelling of epithelial cell foot processes were observed in some glomeruli, but similar changes were also seen in kidney sections from untreated animals.

Significant ultrastructural changes were observed in the kidney four days after aminonucleoside administration and 2 days prior to proteinuria (Fig. 20). The principal changes at this stage occurred in the glomeruli with the epithelial cell foot processes merging and fusing to form cytoplasmic masses adjacent to the basement membrane. Not all the foot processes were affected, approximately three fourths remained

unfused. A number of glomerular epithelial cells contained collections of electron-dense inclusions of approximately the same size as mitochondria, but with no outlining membranes. In some areas the lamina densa of the basement membrane was not as distinct as in the normal and was associated with a reduction in the number of endothelial pores.

Following the development of proteinuria seven days after aminonucleoside administration, dramatic ultrastructural changes occurred in the glomeruli and tubules (Fig. 21). Most of the glomerular epithelial cell foot processes had become confluent and attached to the basement membrane. The epithelial cells, in addition to containing numerous granules and vacuoles also contained discrete, electron-dense bodies about 1μ in diameter, which corresponded to the P.A.S. positive granules identified by light microscopy. The lamina densa of the basement membrane during the nephrotic stage was less dense than normal, and was thickened in a number of areas. The thickened basement membranes often contained electron-dense particles approximately 0.1 to 0.2μ in diameter. Endothelial cell cytoplasmic hyperplasia was also observed in many cells.

Electron-dense bodies, similar to those seen in the glomerulus were found in the lumina of proximal

convoluted tubules and also in the cytoplasm of some of the proximal convoluted tubules (Fig. 23). Associated with these changes, fragmentation and vacuolar dilation of the cytoplasmic ergastoplasm was often observed particularly in the proximal convoluted tubular cells. No gross structural abnormalities were observed in mitochondria of renal cells at any stage of aminonucleoside nephrosis.

2) Liver: At the ultrastructural level normal hepatocytes exhibit a polygonal form which is usually irregular. Commonly, half of the sides face adjacent hepatocytes and the other half were exposed to the sinusoids. A bile capillary lumen was usually present between the apical surface of adjacent hepatocytes, while small inclusion spaces (space of Disse) were observed on the sinusoidal surfaces.

The nucleus occupied about 50% of the hepatocyte volume and was centrally placed in the cell. In osmium fixed tissues the nuclei contained a finely granular nucleoplasm of low density. The chromatin masses consisted predominantly of small granules about 270 A° in diameter which stained with varying degrees of intensity. These granules had a tendency to form aggregates which in most instances were in contact with the inner aspect of the nuclear membrane.

The nucleoli consisted predominantly of two types of material; one homogenous, containing short or fine (ca 60 A°) fibrils, the other granular, the granules being denser but smaller than the chromatin granules (ca 150 A°). Both the granular and non granular components of the nucleoli were intertwined into tortuous strands separated from each other by an amorphous material having the same density as the nucleoplasm.

The nuclear envelope consisted of two membranes separated by a space 100 to 140 A°. The pores in this nuclear envelope (ca 300 A°) were easily observed and were usually in an area of nuclear matrix which was low in density. The outer nuclear membrane was studded with ribosomes and in some areas was continuous with the rough endoplasmic reticulum of the cytoplasm. The inner membrane in contact with the nucleoplasm had no attached ribosomes.

The cytoplasm of rat hepatocytes characteristically contained parallel arrays of rough endoplasmic reticulum which occurred in complexes or bundles of up to 20 in which about 4 to 5 were seen in any medial section of a single cell. Each complex tended to extend from a zone in close proximity to the nuclear envelope to a zone

close to the zone surface. Occasional arrays of rough endoplasmic reticulum were found parallel to the nuclear envelope. The position and form of these arrays varied not only from one hepatocyte to another, but also in single hepatocytes, and often were related in orientation to the position of the golgi apparatus in the cytoplasm.

The ribosomes on the cisternal membranes, when cut transversely appeared to be spaced out at regular intervals, and did not seem to be attached to ribosomes that were present free in the hyaloplasm. The lumina of the cisternal spaces were of equal width in different units, and this uniformity persisted over the largest part of their length, but it was not uncommon to observe cisternae slightly dilated especially at their margins. The cisternae contained two types of materials which were observed particularly in the dilated portions, one being in the form of granules, the other being amorphous or finely fibrillar. These secretory materials accumulated at the terminal portions of the cisternae and were pinched off to become independent cytoplasmic vesicles. These vesicles lost their attached ribosomes (smooth endoplasmic reticulum) and migrated towards the golgi apparatus where they became incorporated. The Golgi complex consisted of flattened smooth membrane cisternae which often

contained granules varying in size from 300 to 1000 A°. Vesicles containing these granules originating from the golgi complex, were often seen in the cytoplasm and tended to be secreted into the sinusoidal space through the space of Disse.

Microbodies and lysosomes which develop as outgrowths from the golgi system were present in moderate amounts in hepatocytes, and predominated in the vicinity of the bile capillary lumen. Numerous mitochondria were present in the cytoplasm of rat hepatocytes predominantly in the mid-zone and periphery of the cell. The mitochondria seemed to be more numerous and compact in hepatocytes lining the periphery of the hepatic lobule in the vicinity of the portal and biliary tracts.

Rosettes of glycogen particles (ca 500 A°) were present in well fed animals and were related to the smooth endoplasmic reticulum. These particles were markedly reduced if the animals were starved prior to sacrifice. Most of the features of a normal hepatocyte are observed in Figure 24.

Treated rats from Groups 1 and 2, which had been starved prior to being killed, showed similar but more prominent changes than those rats of Group 3 that had been fed ad libitum up to the time of sacrifice. Electron micrographs of liver sections from Groups 1 and 2 are,

therefore presented.

The earliest changes from the normal in the liver were noticed six hours after the intravenous administration of aminonucleoside (Fig. 25-26). These changes consisted of a loss of regular arrays of endoplasmic reticulum in the cytoplasm associated with reticular vesiculation and a reduction of the number of free and membrane bound ribosomes. Prominent cisternal dilatation of the rough endoplasmic reticulum of hepatocytes was present 24 hours after a single intravenous injection of aminonucleoside (Fig. 27). The changes were noted particularly around the central vein and mid-zones of liver lobules. In liver sections chosen at random, one hepatocyte out of ten was involved in such a process (350 cells counted). Ribosomes were attached at this stage to the dilated endoplasmic vesicles, and free ribosomes seemed to be more numerous than normal throughout the hyaloplasm. In normal controls, similar changes were occasionally seen (about one hepatocyte in fifty, 400 cells counted). Mitochondrial structural deformities were seen 24 hours following aminonucleoside, but were not a constant finding (Fig. 28). Four days following aminonucleoside injection, most hepatocytes showed vesiculation of the rough endoplasmic reticulum with increased numbers of free ribosomes which sometimes formed cochleosome patterns (79) as seen in

Figure 29 and 30. (One out of three cells, 400 counted). Increased numbers of lysosomes and microbodies were also observed at this stage. During the nephrotic stage, (7 days after aminonucleoside) changes in hepatocytes were similar to those seen prior to proteinuria, except that the cytoplasmic disorganization of hepatocytes was widespread and associated with loss of endoplasmic reticular arrays. Increased numbers of ribosomes and polyribosomes was also observed in the hyaloplasm (Fig. 31). No structural changes were observed in the Kupfer cells lining the sinusoids following aminonucleoside administration.

2. Biochemical Studies:

a) Incorporation of (C^{14}) Glucosamine into Plasma Proteins of Rat: It has been shown by Moscarello et al (21,22) that (C^{14}) glucosamine incorporation into the trichloroacetic acid-insoluble fraction of rat plasma protein over an experimental period of two hours was increased as early as 24 hours following aminonucleoside administration. Five days after aminonucleoside the incorporation of (C^{14}) glucosamine into trichloroacetic acid-insoluble fraction was increased by about 100% over the incorporation in the case of the control rats.

This experiment was repeated, using a total of ten rats. Two of the rats served as controls. The test rats were as follows: 2 were injected with 5 μc of labelled (C^{14}) glucosamine 24 hours after aminonucleoside, 2 at 48 hours, 2 at 72 hours and 2 at 96 hours. All injections were given as previously described (see Methods) into the jugular vein and 0.5 ml. samples of blood were withdrawn from the same jugular vein at 1,2,3,4 and 5 hours after the administration of (C^{14}) glucosamine.

The results demonstrating the incorporation into trichloroacetic acid-insoluble counts (mainly glycoprotein) are shown in Diagram 4. These results confirm the initial experiments of Moscarello et al (3,22).

Because ultrastructural changes were observed in the liver as early as six hours after the injection of aminonucleoside, the incorporation of glucosamine (C^{14}) was investigated $6\frac{1}{2}$,$17\frac{1}{2}$ and 24 hours following the administration of the drug (kindly done by Miss M. Swensen). The results are presented in Diagram 5. It can be seen that a small but significant depression of the specific activity was observed at $6\frac{1}{2}$ and $17\frac{1}{2}$ hours. However, a significant increase of specific activity was observed 24 hours after the

injection of aminonucleoside as observed in previous experiments and represented in Diagram 4.

Diagram 4. Incorporation of (C^{14}) glucosamine into the trichloracetic acid-insoluble radioactive fraction of rat plasma after aminonucleoside administration.

Control: o——————o

o- - - - - -o 24 hours after aminonucleoside

x——— x 48 hours " " "

•·····o 72 hours " " "

o———o 96 hours " " "

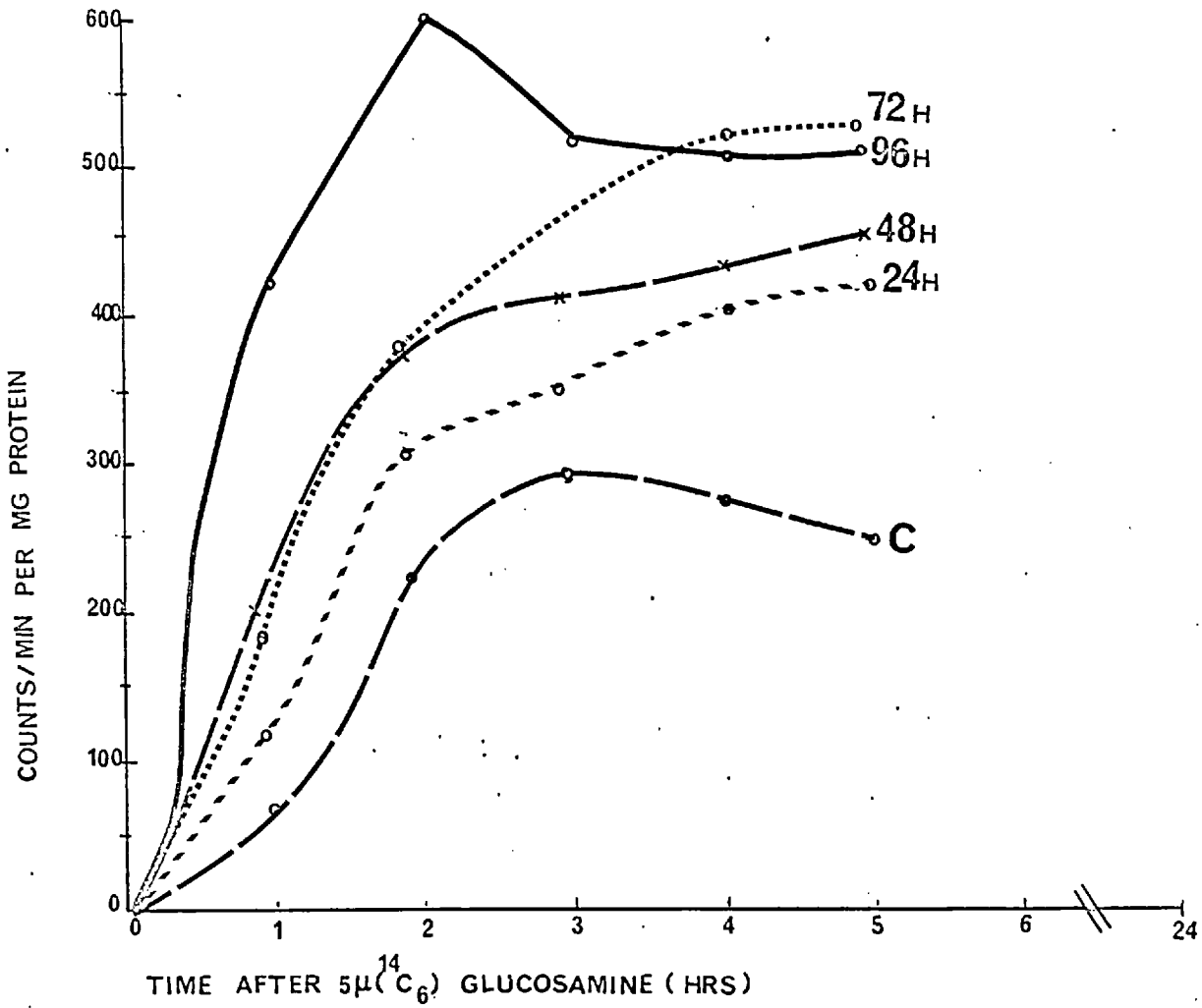

INCORPORATION OF (^{14}C) GLUCOSAMINE INTO TRICHLORACETIC ACID-INSOLUBLE RADIO-ACTIVITY OF RAT PLASMA AFTER AMINONUCLEOSIDE · CONTROL o—o ; AFTER AMINONUC-LEOSIDE, o—o 24h, x——x 48h, o·····o 72h, o——o 96h.

Diagram 4

Diagram 5.

Incorporation of (C^{14}) glucosamine into trichloroacetic acid-insoluble radioactivity of plasma from normal rats and rats treated with amino-nucleoside for $6\frac{1}{2}$, $17\frac{1}{2}$ and 24 hours.

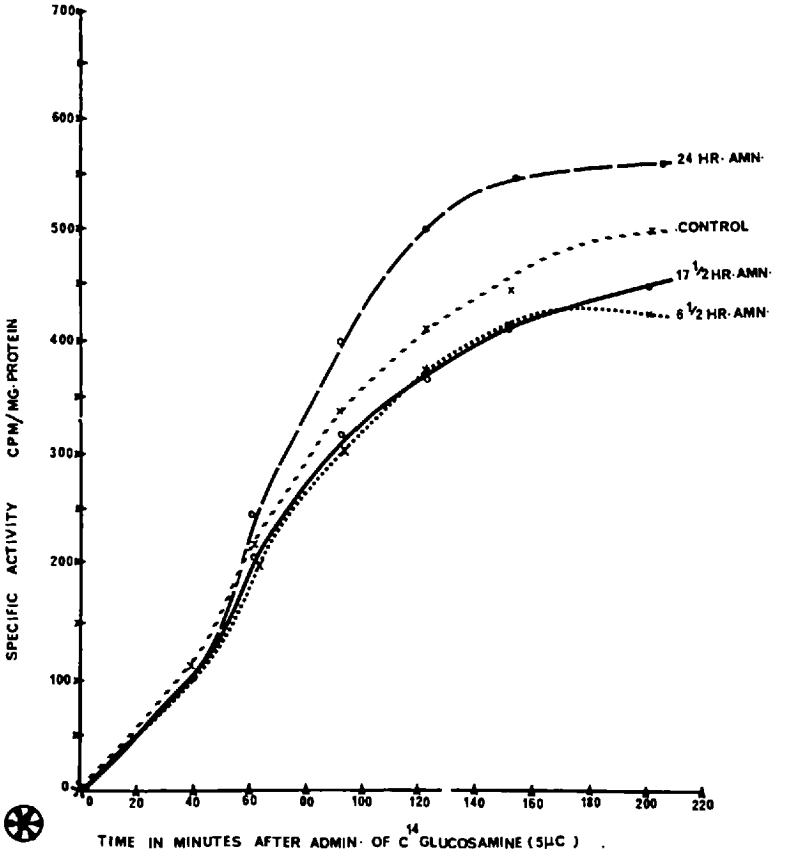

INCORPORATION OF C^{14} GLUCOSAMINE INTO RAT PLASMA GLYCOPROTEINS FOLLOWING INTRAVENOUS AMINONUCLEOSIDE·

5

b) Fractionation of Plasma Proteins Labelled with (C^{14}) Glucosamine: Rat serum (3 ml.) obtained from normal and aminonucleoside treated animals (4 days) was fractionated on Sephadex G-200 columns as described under Methods.

Rats were given 5 μc of C^{14} glucosamine intravenously through the jugular vein (under ether anaesthesia), and two hours later were exsanguinated by cardiac puncture. The blood was then centrifuged, and 3 ml. of the serum so obtained containing about 225 mg of protein was added to the Sephadex G-200 column for fractionation. The serum was eluted with 0.1 M Tris/HCL buffer at pH8 and 1 M NaCl at a rate of 15 ml/hr. and 15 ml. fractions were collected.

Protein concentration and radioactivity was determined for each fraction and the values obtained were then plotted against the eluant volumes. The void volume of the Sephadex column measured with dextran blue was 450 mls.

Three major protein peaks were found during the fractionation of normal serum (Diagram 6) which were similar to that found by Delozalova et al (80). The first fast peak was associated with the void volume and represented the macroglobulins. The intermediate peak between 600 and

800 ml. of eluant represented the globulin fraction. A large peak representing the albumin, transferrin, haptoglobin etc. fractions was the last of the three protein peaks eluted and came out at 950 to 1050 ml. of eluant.

The specific activities of plasma glycoprotein could be resolved into three major peaks when labelled plasma was fractionated on Sephadex G-200, but the labelled peaks so obtained did not coincide with the protein peaks (Diagram 6). The first specific activity peak coincided with the void volume and macroglobulin elution peaks. The second intermediate peak occurred at about 550 ml. elution, and was situated just before the globulin peak with some overlap. The third and most significant peak was present in the pre-albumin, α_2 globulin region.

The fractionation of rat serum from aminonucleoside treated animals demonstrated variations of protein and specific activity peaks compared to normal (Diagram 7). The three major protein peaks were still observed following fractionation, however, the relative concentration of protein in the macroglobulin and albumin peaks was reduced relative to the globulin peak.

The most significant finding was a marked increase of glycoprotein specific activity (75% over control) in the pre-albumin α_2 globulin peak area, no changes being observed in specific activities of other peaks. The band patterns obtained following the electrophoresis of normal and aminonucleoside treated rat serum on tris-borate starch at pH8 (Fig. 32), showed no changes.

Diagram 6.

Fractionation of 3 ml. of normal rat plasma on a Sephadex 200 column (4.2 x 80 cm) eluted with 0.1 M Tris/HCL buffer at pH8 and 1 M NaCl. Protein concentration and specific activities were determined for each 15 ml. fraction and plotted against eluant volume.

Void Volume: 450 ml.

Diagram 7.

Fractionation of 3 ml. of aminonucleoside treated rat plasma on a Sephadex 200 column (4.2 x 80 cm) eluted with 0.1 M Tris/HCL buffer at pH8 and 1 M NaCl. Protein concentration and specific activities were determined for each 15 ml. fraction and plotted against eluant volume.

Note the increased specific activity in the pre-albumin α_2 globulin region.

Void Volume: 450 ml.

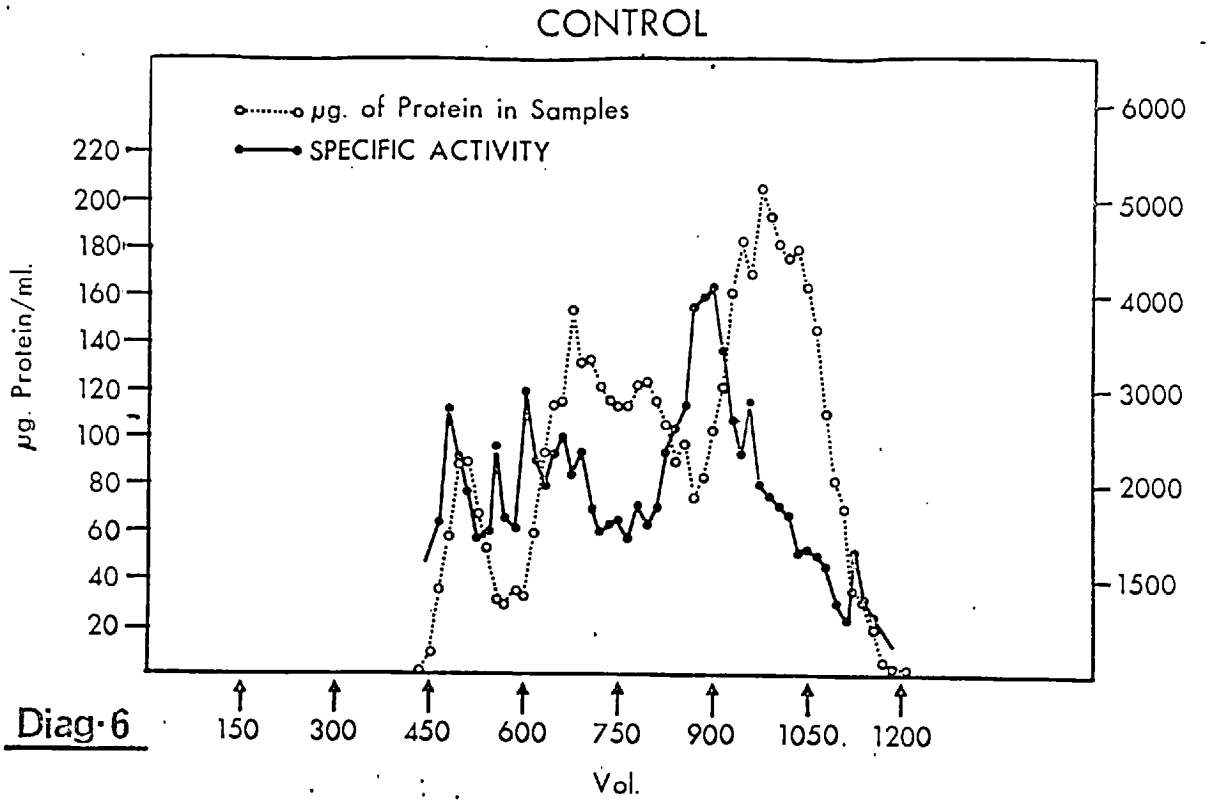
CONTROL
μg. of Protein in Samples
SPECIFIC ACTIVITY
μg. Protein/ml.
220
200
180
160
140
120
100
80
60
40
20
6000
5000
4000
3000
2000
1500
150
300
450
600
750
900
1050.
1200
Vol.

Diag·6

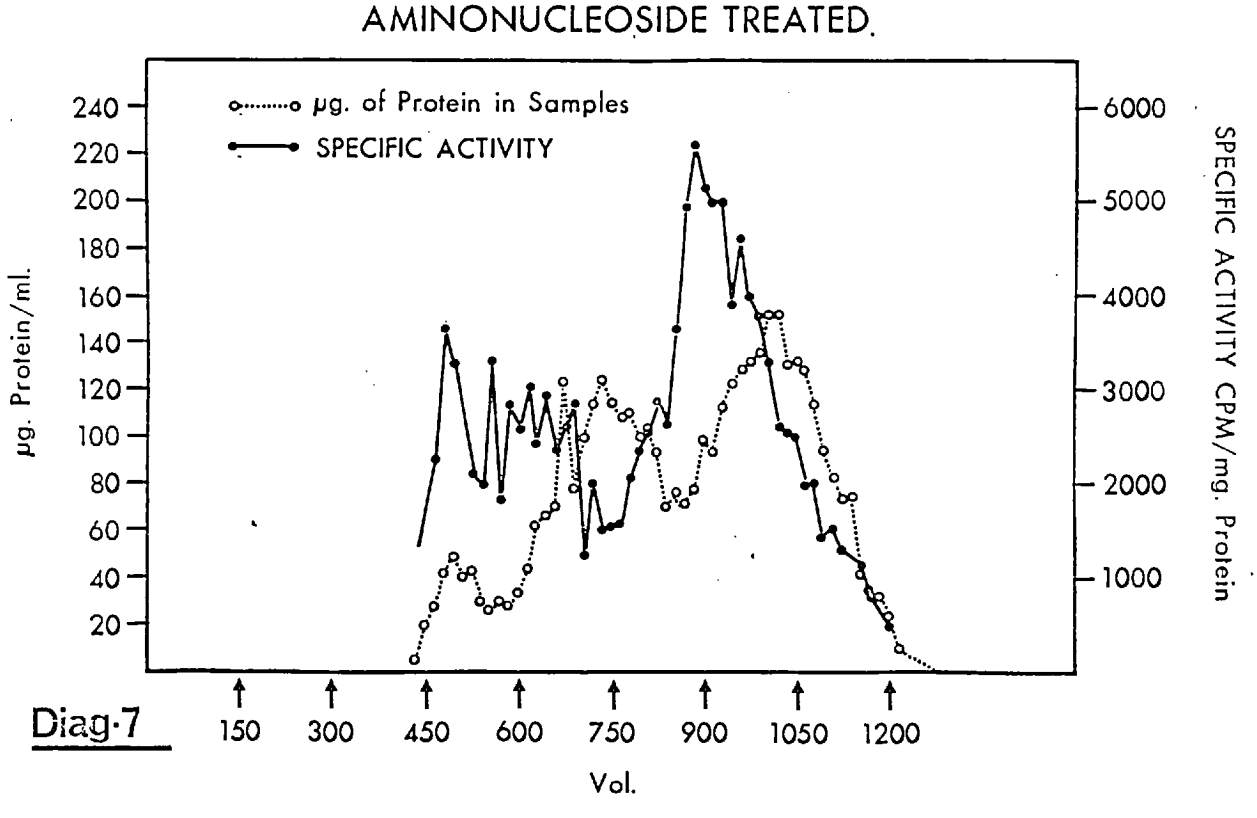
AMINONUCLEOSIDE TREATED.
μg. of Protein in Samples
SPECIFIC ACTIVITY
μg. Protein/ml.
240
220
200
180
160
140
120
100
80
60
40
20
6000
5000
4000
3000
2000
1000
SPECIFIC ACTIVITY CPM/mg. Protein
150
300
450
600
750
900
1050
1200
Vol.

Diag·7

c) <u>The Action of Labelled Radioactive Plasma Fractions on Isolated Rat Kidney Glomeruli</u>: Experiments were undertaken to determine the relationship of serum glycoproteins, and the glycoprotein constituents of the basement membrane of glomeruli. Labelled iodinated protein fractions were incubated with a crude mass of glomeruli, prepared by a modification of Steblay's method (77), to determine whether the labelled protein fraction had an affinity for glomeruli, and whether variations occurred with aminonucleoside. Normal and aminonucleoside serum fractions containing the labelled pre-albumin C^{14} glucosamine peaks were labelled with I^{131} according to the method of Greenwood et al (76). The iodinated protein fractions were separated from labelled inorganic I^{131} by eluting the mixture on a Sephadex-25 column with 0.1 M ammonium carbonate. In this system labelled protein is eluted with the void volume. (Diagram 8).

Diagram 8.

Separation of normal and aminonucleoside treated I^{131} labelled plasma fractions from (I^{131}) iodide on Sephadex G-25.

The separation was carried out by gel-filtration of an iodinated reaction mixture containing 1 mg of plasma fraction, sodium metabisulphite (240 μg), chloramine-T (800 μg), KI (5 mg) and approximately 1 mc of (I^{131}) iodide in a volume of 0.4 ml. The column (25 x 1 cm) of Sephadex G-25 was equilibrated with 0.1 M ammonium carbonate at pH 8.6, and pre-saturated with crystalline bovine plasma albumin (20 mg). Iodinated protein was eluted in the void volume (40 ml.) followed by a larger iodide peak.

1B: serum fraction from normal rat.

2B: serum fraction from aminonucleoside treated rat.

SEPARATION OF I^{131} PROTEIN FROM INORGANIC I^{131} IODIDES

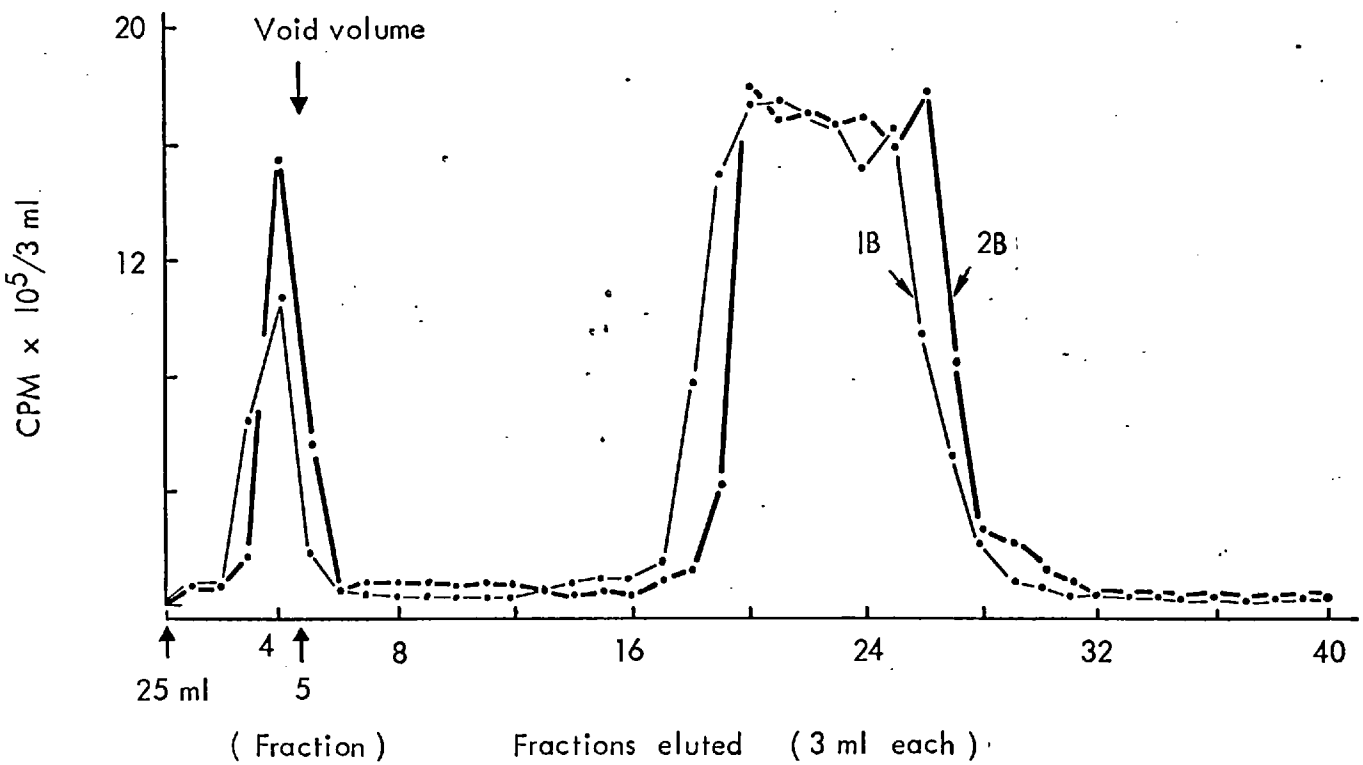

Diagram 8

Normal labelled plasma protein fractions were found to have some affinity for renal glomeruli (about 1 to 2% of total counts). This affinity was not modified by calcium ions (Diagram 9) or magnesium ions (Diagram 10). Incubation of iodinated plasma fractions with glomeruli that had been treated with trypsin and neuraminidase for 2 hours did not affect the adsorption of the labelled plasma fraction to the glomeruli (Diagram 11). Some decrease of protein adsorption was observed when the iodinated fractions were incubated with glomeruli that had been treated with elastase, kindly supplied by Dr. A. Hercz, (Diagram 11), however, the results could not be confirmed in other experiments. The adsorption of normal iodinated plasma protein fractions to suspensions of normal and aminonucleoside treated glomeruli of rats showed no significant difference. However, when I^{131} labelled plasma protein fraction (2B) from an aminonucleoside treated rat (4 days treatment) was added to a normal glomerular suspension, increased adsorption was observed which was 70% more than that of normal control glomerular suspensions incubated up to 2½ hours. (Fig. 12).

Diagram 9. The effect of calcium ions on the binding of 200λ iodinated plasma protein fractions (1B) (18,000 cpm) glomerular suspensions in phosphate buffer at pH 7.4 (80,000 glomeruli). Identical glomerular suspensions in phosphate buffer containing no calcium are used as controls. (Protein fractions incubated with glomeruli for 2½ hours).

THE EFFECT OF CALCIUM ION ON THE BINDING OF AN IODINATED PLASMA PROTEIN FRACTION (IB) TO GLOMERULI

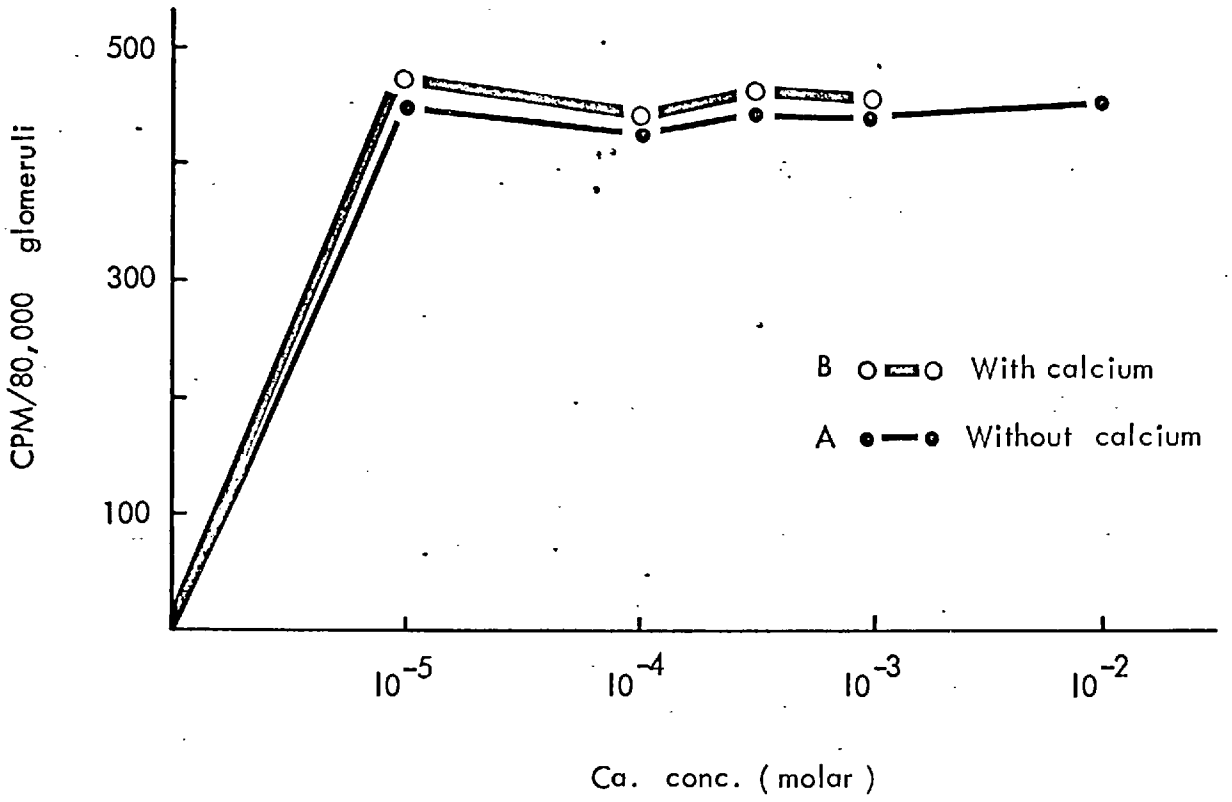

Diagram 9

Diagram 10. The effect of magnesium ions on the binding of 200μl iodinated plasma protein fraction 1B to glomerular suspensions in phosphate buffer at pH 7.4 (40,000 glomeruli). Identical glomerular suspensions in phosphate buffer containing no magnesium are used as controls. (Protein fractions incubated with glomeruli for 2½ hours).

THE EFFECT OF MAGNESIUM ION ON THE BINDING OF AN IODINATED PLASMA PROTEIN FRACTION (IB) TO GLOMERULI

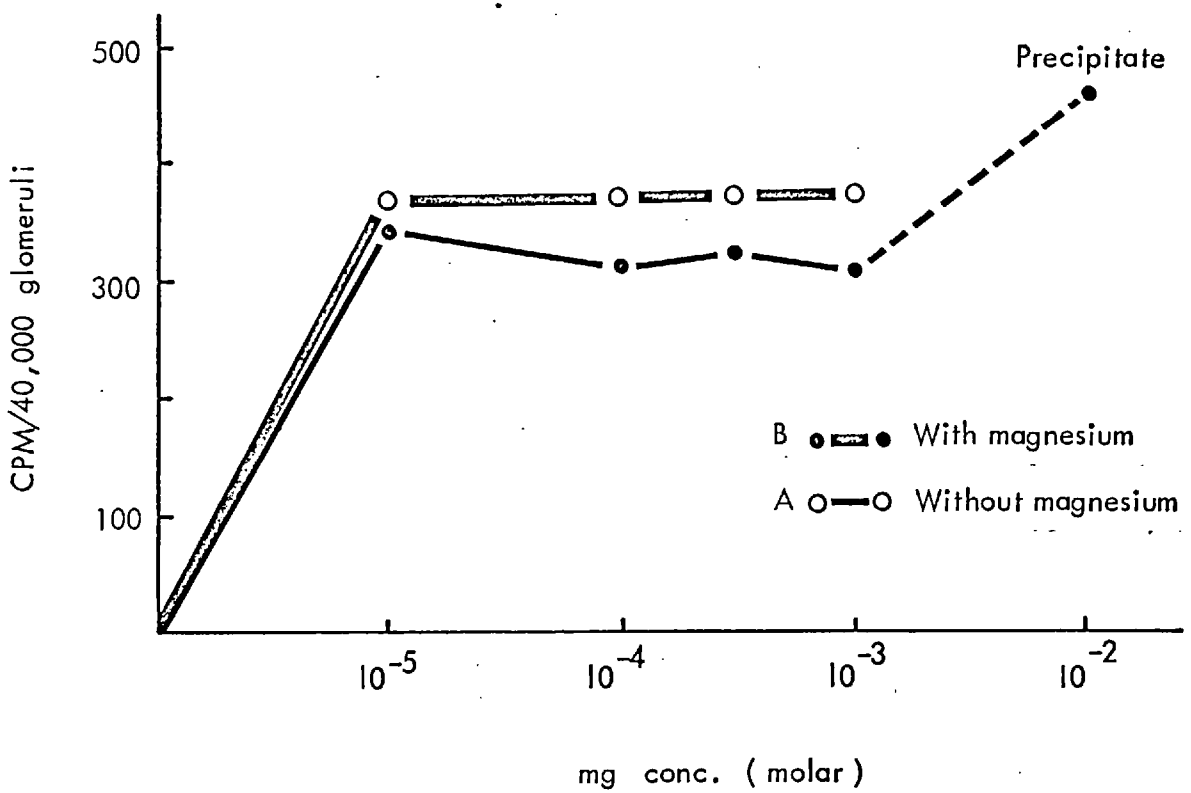

Diagram 10

Diagram 11. The binding of iodinated plasma protein fraction (1B) to glomerular suspensions treated for 2 hours with the enzymes neuraminidase, trypsin and elastase.

A)	control in Phos. Buffer at pH 7.4		
B)	glomeruli	Neuraminidase	1 μg
C)	glomeruli	Trypsin	10 μg
D)	glomeruli	Elastase	10 μg

THE BINDING OF IODINATED PLASMA PROTEIN FRACTIONS (IB)
TO GLOMERULAR SUSPENSIONS TREATED WITH VARIOUS ENZYMES

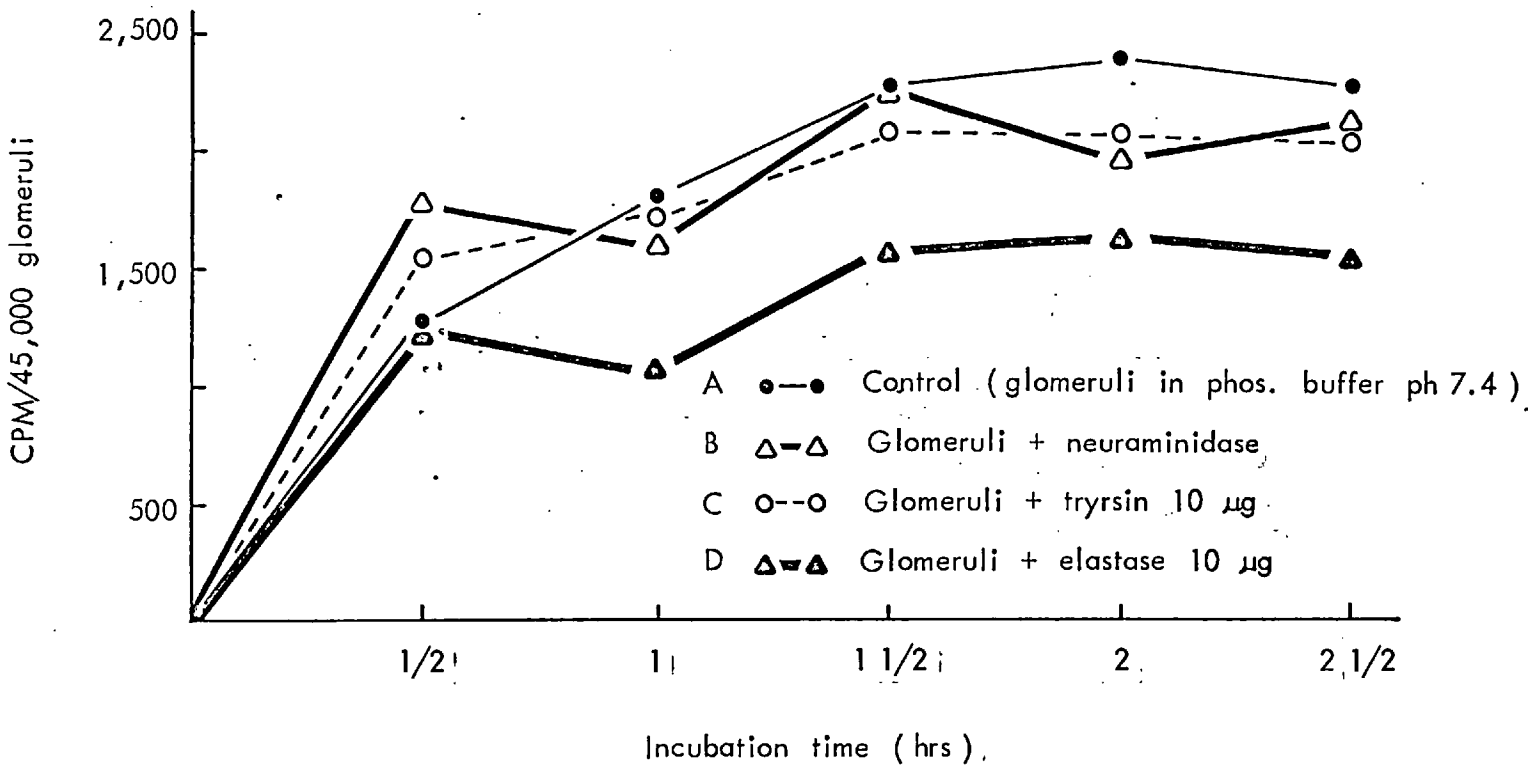

Diagram 11

Diagram 12. The binding of labelled iodinated plasma fraction (2B) from an aminonucleoside treated rat to a normal glomerular suspension is shown. Labelled protein adsorption is increased up to 70% compared to normal controls when incubated up to $2\frac{1}{2}$ hours. Glomerular suspensions (40,000) were in 0.5 M phosphate buffer at pH 7.4

A) fraction 1B (normal) 20,000 cpm
B) fraction 2B (aminonucleoside treated) 20,000 cpm.

THE BINDING OF I^{131} PROTEIN FRACTIONS TO GLOMERULAR SUSPENSIONS

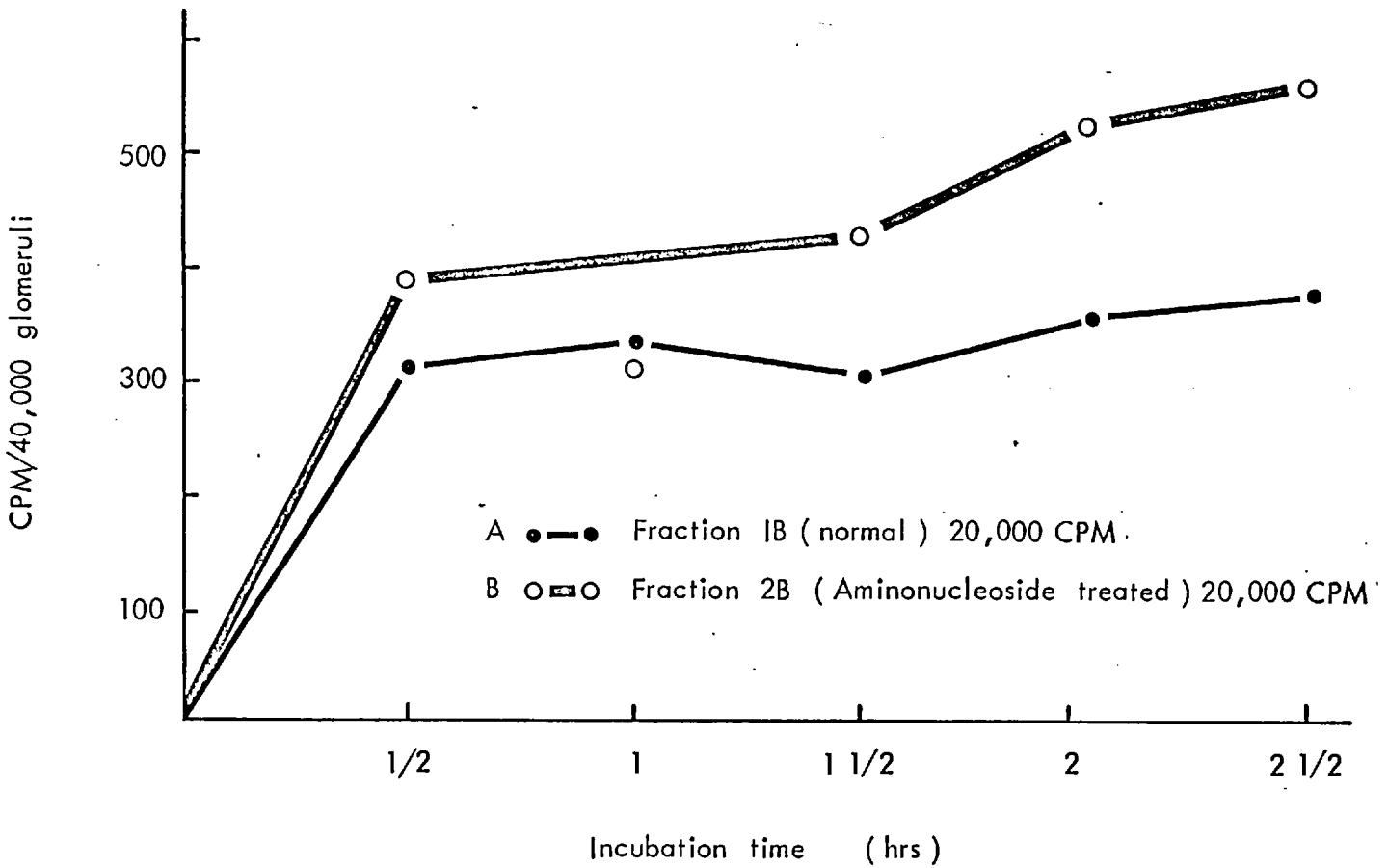

Diagram 12

Chapter V. DISCUSSION

1. The Effect of Aminonucleoside on HeLa Cells

Tissue culture studies were undertaken to demonstrate the inhibitory action of aminonucleoside on intra-cell processes.

The ultrastructural changes observed in HeLa cells following aminonucleoside in no way resembled those found in hepatocytes of rats given intravenous aminonucleoside and described in this thesis. This favoured our concept that the changes seen in hepatocytes may represent an indirect effect of aminonucleoside action. Studzinski et al (64) reported that aminonucleoside added to HeLa cell monolayers acted as an inhibitor of cellular RNA synthesis. When the concentration of aminonucleoside was relatively low the inhibition of RNA synthesis was selective, affecting principally the synthesis of ribosomal type of RNA (28s and 18s). At these low concentrations of aminonucleoside (<10 μg/ml of medium) HeLa cells continued to multiply at an unimpaired rate while the synthesis of ribosomal RNA and, to a lesser extent, transfer RNA was depressed. When higher concentrations of aminonucleoside were added to medium (>10 μg/ml), the synthesis of DNA

and other types of RNA (45s and 32s) was inhibited with a subsequent decrease of protein synthesis. At a concentration of 100 μg/ml. of medium, aminonucleoside caused complete inhibition of all RNA synthesis. At these concentrations, protein synthesis was also reduced but not inhibited, so that the cells remained viable.

Similar findings were reported earlier by Farnham (62) on mouse L cell fibroblasts, who demonstrated that aminonucleoside acted preferentially on ribosomal RNA synthesis. She suggested that aminonucleoside either as such or after incorporation into soluble-RNA acted as an analogue of uncharged soluble RNA which interfered with the cellular RNA synthesizing system (RNA polymerases). The uncharged soluble RNA would not by itself deplete the charged soluble RNA species, and would therefore support a relatively normal rate of protein synthesis.

Using HeLa cell tissue culture monolayers and a nutrient medium containing a high concentration of aminonucleoside (100 μg/ml), we confirmed some of the findings of the above investigators.

HeLa cell growth following aminonucleoside was greatly inhibited and was associated with a reduced rate of C^{14} leucine incorporation into HeLa cell

proteins. In contrast, the rate of C^{14} glucosamine incorporation into glycoprotein of aminonucleoside treated cells decreased only after a lag period of 10 hours. As glucosamine conjugation onto protein occurs on smooth endoplasmic reticulum, the lag period may represent the interval of time necessary to deplete the cell of available protein, newly synthesized proteins being inhibited by aminonucleoside at the ribosomal level.

At the ultrastructural level the most significant changes following aminonucleoside were observed in the nucleoli. No comparable changes were found in those HeLa cells grown at the same time in nutrient medium containing antibiotics but without aminonucleoside. Initially, a fragmentation and clumping of the fibrillar component of the nucleolus occurred, associated with a condensation of the granular component. Later, the segregation of nucleolar components became marked with the extrusion of compact fibrillar bodies from the nucleolus into the nucleoplasm. These extruded fibrillar bodies or nucleolar satellites were often surrounded by a ring of granular material. Associated with these changes, dense particulate bodies were observed particularly in the amorphous component of the nucleolus, and also the nucleoplasm but not in the cytoplasm. These particulate bodies were

repeatedly observed in the sites mentioned and therefore were not considered artifacts. The cytoplasm occasionally contained a number of abnormally shaped mitochondria, but these findings were not constant.

The ultrastructural changes observed were not unlike those seen in cells treated with actinomycin D (81,82,83,84). Similar changes were also reported in hepatocytes of rats treated with mithramycin C (85), in tissue culture cells infected with mycoplasma (86) and in Chang liver cells subjected to nuclear radiation (87). The nucleolar changes were interpreted as being related to a decrease of cellular RNA biosynthesis, and represented the direct or indirect site of action of the particular anti-metabolite or physical agent used.

Simard and Bernhard (88) postulated that nucleolar changes occurred only with those agents that interfered with the synthesis of DNA and RNA. They further demonstrated that agents that inhibit the synthesis of RNA by blocking RNA polymerases caused segregation of the nucleolar components, the separation being often directly proportional to their biological activity. Aminonucleoside may belong to this group of agents acting as an RNA polymerase

inhibitor by competing with dimethyladenosine for the active site of the enzyme (62). Recently, it has been postulated that the monomethyl aminonucleoside may be the active metabolite (89). It may well be that dimethyl or monomethyl aminonucleoside interferes with the methylation of 45s RNA and results in defective yields of 32s, 28s, and 16s types (90). The distribution of newly synthesized RNA in the nucleolus was demonstrated by Geuskens and Bernhard (91), who used actinomycin D treated cells and traced the incorporation of H^3 uridine by autoradiography. They showed that newly synthesized RNA (45s RNA) first appeared in the fibrillar zone and then migrated to the granular zone. Any defect of RNA synthesis will therefore interfere with the sequential synthesis of fibrillar and granular components, such as observed with aminonucleoside. As the ultrastructural changes observed in HeLa cells following aminonucleoside treatment, primarily involved the fibrillar component of the nucleolus, the changes correlate well with the biochemical evidence obtained by others demonstrating defective 45s RNA biosynthesis (90).

The exact mechanism of the segregation of fibrillar and granular components of the nucleolus is not known. However, as the nucleic acids are

intimately associated with proteins, a defect in either one or the other macromolecule could change their physico-chemical properties such as to cause nucleolar component dispersal instead of attraction. Such a defect in nucleoprotein may explain the presence of particulate bodies (Fig. 9-p).

The nucleolar changes observed in HeLa cells following aminonucleoside are therefore not specific, but may represent structural nucleolar alterations secondary to defective 45 S-RNA synthesis and nucleoprotein abnormalities.

2. The Effect of Aminonucleoside on the Rat

All rats given a single intravenous injection of aminonucleoside developed nephrosis after a latent period of six days. The ultrastructural changes in the kidney as described in this thesis conform to those previously described by Harkin et al (29,30) and Farquhar (39), even though in both latter experiments injections of aminonucleoside were given daily and subcutaneously, whereas we gave only a single intravenous dose.

No comparative study however, has been made on the ultrastructural changes observed in the liver during experimental nephrosis produced by any means. In particular, no study was found in which emphasis

was placed on the ultrastructural changes in the liver prior to the onset of proteinuria.

Hepatocytic changes were observed as early as six hours following intravenously administered aminonucleoside, and consisted of a loss of cytoplasmic architecture associated with vesiculation of the rough endoplasmic reticulum. At this stage decreased numbers of free and attached ribosomes were apparent. By 24 hours the vesiculation of the rough endoplasmic reticulum became more prominent and was associated with increased numbers of free and attached ribosomes.

These hepatocytic changes following aminonucleoside administration occurred at least 24 hours prior to the development of any ultrastructural renal glomerular abnormalities, and 5 days prior to proteinuria. Mitochondrial structural deformities were also observed associated with vesiculation of the endoplasmic reticulum, but were not a consistent finding.

It is well known that protein synthesis is associated with ribosome and polyribosome aggregates (92) and that glycoprotein conjugation occurs on the endoplasmic reticulum (93). Furthermore, the hepatic synthesis of serum glycoproteins has been definitely established by Sarcione (23,24), using a liver perfusion technique.

In the experiments described in this thesis, the specific activity of plasma glycoproteins was less than observed for the control animal, at a time ($6\frac{1}{2}$ hours) when ultrastructural changes were definitely established. The initial response of the liver appeared to have been a slight depression of plasma glycoprotein synthesis. A definite increase in specific activity was not observed until 24 hours after the injection of aminonucleoside, at a time when the ultrastructural changes were becoming progressively more pronounced.

The reason for the slight depression in glycoprotein synthesis is not understood. It may be that at six hours the concentration of aminonucleoside is relatively high in the hepatocyte resulting in disaggregation of polysomes, with a subsequent decrease in incorporation of glucosamine-C^{14}. By 24 hours, the concentration of the drug may be much less, resulting in aggregation of ribosomes into polysomes with a concomitant increase in glucosamine-C^{14} incorporation.

A reversible effect of cycloheximide, an inhibitor of protein synthesis, has been reported by Godchaux, Adamson and Herbert (94). At low concentrations cycloheximide promotes aggregation of ribosomes, while at higher concentrations, disaggregation. The effect

of aminonucleoside on polyribosome patterns of hepatocytes in sucrose density gradients are being studied in this laboratory and preliminary results indicate similar patterns (95). The exact mechanism of the stimulation of glycoprotein biosynthesis in rats treated with aminonucleoside and the possible relationship of this change to the nephrotic process are still not known.

It has been shown in the first part of this thesis that aminonucleoside acts as an inhibitor of ribosomal RNA synthesis and cell division of HeLa cells. Such an action may occur selectively in the kidney following aminonucleoside excretion with subsequent absorption and incorporation into renal cells. Interference with nucleic acid synthesis may occur because of the action of aminonucleoside as an adenine or adenosine analague and the subsequent depression of protein formation by renal cells.

This depression of renal protein synthesis may include the suppression of a postulated inhibitor of glycoprotein formation in the liver, similar to that postulated for the regulation of serum α-lipoprotein by the kidney (96). Interference with such a feedback mechanism may permit the rate

of hepatic glycoprotein synthesis to rise. With elevated serum levels of glycoprotein, the glomerular protein load may be increased and be associated with a functional impairment of the glomerular basement membrane. Alternatively, as one of the main constituents of the glomerular basement membrane is a glycoprotein (43) alteration of its physical and biochemical properties may be related to alterations in the level or nature of circulating serum glycoproteins. Evidence presented in this thesis does suggest that the biosynthesis of an α_2-globulin plasma fraction is increased following aminonucleoside, but whether this fraction is a normal increased fraction or an abnormal constituent of plasma could not be determined.

The basement membrane of the glomerulus is most probably formed by secretory products produced by both the endothelial and epithelial cell components of the glomerulus (46,47,48). If the endothelial cellular component is exposed to altered plasma glycoproteins, the endothelial cells may synthesize a basement membrane component with altered physico-chemical properties which may be more permeable to proteins (44,97). The epithelial changes observed therefore most probably represents a protective

cellular mechanism to prevent further protein loss through the basement membrane. In any case, the glomerular changes would probably be accentuated by altered renal cell metabolism due to the direct action of aminonucleoside as demonstrated for sodium transport by Yoshida et al (98). A critical level is reached when tubular cells can no longer reabsorb the increased protein load with resultant proteinuria.

On the other hand, aminonucleoside may act directly on hepatic cells with stimulation of glycoprotein synthesis. (Nucleolar changes seen in some cells (Figure 27) may be due to a direct action of aminonucleoside). The high levels of serum glycoproteins following increased hepatic activity may overload the renal resorptive mechanisms with eventual renal cell failure. However, there is no experimental evidence at present for such a direct action (62).

In conclusion, it seems possible from the experimental evidence that an intimate relationship may exist between renal and hepatic function in relation to glycoprotein synthesis and, if this mechanism is disturbed, nephrosis may occur as a terminal event in glycoprotein metabolic disorders.

The further use of aminonucleoside as an experimental tool may in the future give us a better insight into the mechanism involved in the development of chronic renal disorders, and also may reveal further hepato-renal relationships.

Chapter VI. SUMMARY

The biological action of aminonucleoside of puromycin, a dimethyl adenosine analogue, was studied on HeLa cells and the intact rat.

Ultrastructural nucleolar changes were observed in HeLa cells treated with aminonucleoside. Initially, a fragmentation and clumping of the fibrillar component of the nucleolus occurs, associated with a condensation of the granular component. This is then followed by the extrusion of the compact fibrillar component from the nucleolus with a further condensation of the granular component. The nucleolar changes were associated with a decrease of HeLa cell growth and an inhibition of C^{14} leucine and C^{14} glucosamine incorporation into HeLa cell proteins. These changes were not unlike those seen with other anti-metabolites such as actinomycin D. It is postulated that the changes observed are not specific for any one agent, but may indicate the site of defective 45s RNA synthesis in the nucleolus. It is further suggested that the segregation of nucleolar components is accentuated by nucleoprotein abnormalities. The effect of aminonucleoside on HeLa cells is in contrast to the effect in the rat where stimulation of

protein synthesis was observed rather than inhibition. Intravenous administration of a single dose of aminonucleoside produced a nephrotic syndrome in rats after a latent period of 6 days. During the latent period before proteinuria could be detected serum glycoprotein biosynthesis was found to be significantly increased as early as 24 hours after aminonucleoside.

In an attempt to correlate the biochemical changes, with possible morphological changes, ultrastructural examination of the liver and kidneys of rats in the pre-nephrotic stage was undertaken.

Hepatic cell changes were found as early as six hours following a single intravenous injection of aminonucleoside, and at least 48 hours prior to any ultrastructural renal changes, and five days prior to proteinuria. The hepatic cell changes essentially involved the endoplasmic reticulum and ribosomes and were representative of cells actively synthesizing proteins for export. These changes were associated with no significant hepatocytic nucleolar changes.

The ultrastructural changes observed in HeLa cells following aminonucleoside in no way resembled those found in hepatocytes of rats given aminonucleoside.

These observations favour the concept that the changes seen in the hepatocytes represent an indirect effect of aminonucleoside.

The experimental evidence suggests that hepatic glycoprotein biosynthesis may be regulated by the kidney through a feedback mechanism. When this hepato-renal mechanism is disturbed, nephrosis may occur as a terminal event in glycoprotein metabolic disorders.

ADDENDUM

Recently, we have obtained liver and kidney biopsies from a 23 year old man of Greek origin with a 3 month history of proteinuria associated with increasing oedema.

Sections of the kidney examined by light and electron microscopy were typical of those seen

in the advanced stage of membranous glomerulonephritis, and consisted of gross thickening of the basement membrane with fusion of epithelial cell foot processes.

Liver sections embedded in paraffin showed no gross abnormalities, however, epon embedded sections revealed marked vacuolation of most hepatocytes. At the ultrastructural level dilatation and disorganization of the rough endoplasmic reticulum was observed not unlike that seen in rats with experimental nephrosis. The cytoplasm of most hepatocytes also contained numerous membrane lined vesicles containing cerumen or lipofuchsin. These vesicles were often surrounded by lysosomes. In addition, numerous mitochondria contained filamentous or crystalline structures which were also observed in the hyaloplasm.

These preliminary observations in the human confirms our idea that a metabolic disorder involving the kidney, such as seen in the nephrotic syndrome, also involves the liver. The question however, whether the metabolic disorder in the liver precedes or is secondary to the renal lesion is still unanswered, and it will be crucial in understanding the pathogenesis of such diseases.

ACKNOWLEDGEMENTS

The author is greatly indebted to Dr. Mario Moscarello for providing the initial impetus, encouragement, advice and criticism during the course of this investigation.

Dr. Anne Marie Jezequel, Dr. J. Steiner, Dr. P. Conen, Dr. G. Simon and Dr. K. Miyai are thanked for their help in the field of electron microscopy. Miss M. Swensen, Mrs. M. Shreeve and Mr. H. Layne gave fine technical assistance, while Mrs. Jane Mercer is thanked for the thankless task of typing and assembly of this manuscript.

The author also wishes to express his gratitude to Professor A.C. Ritchie and Dr. J. Walter for encouragement and support.

The Medical Research Council of Canada supported the author as a Fellow during the course of this investigation.

REFERENCES

1. Frenk, S., Antonowicz, I., Craig, J.M. and Metcoff, J. (1955).
   Experimental nephrotic syndrome induced in rats by aminonucleoside renal lesions and body electrolyte composition.
   Proc. Soc. Exp. Biol. Med. 89, 424.

2. Dubach, U.C. (1964).
   Aminonucleoside-nephrose. Progress in Drug Research, 7, 341 (Birkhäuser Verlag, Basel).

3. Moscarello, M.A., Sutherland, L. and Jackson, S.H. (1966).
   Stimulation of (^{14}C) glucosamine incorporation into plasma proteins by aminonucleoside.
   Biochim. Biophys. Acta 127, 373.

4. Porter, J.H., Hewitt, R.I., Hasseltine, C.W., Krupa, G., Lowery, J.A., Wallace, W.C., Bohonos, S. and Williams, J.H. (1952).
   Achromycin: A new antibiotic having trypanocidal properties.
   Antibiol. Chemother. 2, 409.

5. Waller, C.W., Fryth, P.W., Hutchings, B.L. and Williams, J.H. (1953).
   Achromycin: The structure of the antibiotic puromycin.
   J. Amer. Chem. Soc. 75, 2025.

6. Baker, B.R., Joseph, J.P. and Williams, J.H. (1955).
   Puromycin synthetic studies VII Partial synthesis of amino analogues.
   J. Amer. Chem. Soc. 77, 1.

7. Baker, B.R., Shaub, R.E., Joseph, J.P. and Williams, J.H. (1955).
   Puromycin. Synthetic studies IX. Total synthesis.
   J. Amer. Chem. Soc. 77, 12.

8. Baker, B.R., Joseph, J.P. and Shaub, R.E. (1959).
   Aminodeoxyglycosidopurines. U.S. Patent 2852505, Sept. 16, 1958. To American Cyanamid Co.
   Chem. Abstr. 53, 8176c.

9. Fernandes, J.F. (1959).
Nucleoside and polynucleotide synthesis in trypanosoma cruzi.
Exp. Parasit. 8, 480.

10. Nakamura, M. and Jonsson, S. (1957).
The effect of antimetabolites on the growth of Endamoeba histolytica. 1. Purine and pyrimidine analogues.
Arch. Biochem. Biophys. 66, 183.

11. Bennett, P.L., Halliday, S.L., Oleson, J.J. and Williams, J.H.
The effect of aminoacid analogues of puromycin on mouse mammary tumours. Antibiotics Annual 1954-1955. Proceedings of the 2nd Annual Symposium on Antibiotics. Editors H. Welch and F. Marti-Ibanez (Medical Encylopedia Inc., Washington, D.C. 1955) p. 766.

12. Scholler, J., Phillips, F.S., Sternberg, St. S. and Bittner, J.J. (1956).
A comparative study of chemotherapeutic agents in spontaneous mammary adenocarcinomas of mice and in transplants of recent origin.
Cancer, 9, 240.

13. Van Meter, J.C., Snedeker, E.H., Moser, L.R. and Oleson, J.J. (1956).
Effect of aminonucleoside on ribonucleic acid content of mouse mammary adenocarcinoma in vivo.
Proc. Soc. Exp. Biol. Med. 93, 384.

14. Burchenal, J.H. 1. (1956).
Antimetabolites, Current Research in Cancer Chemotherapy. Report No. 4, Feb., p. 3.

15. Hewitt, R.I., Wallace, W.S., Gumble, A.R., Gill, E.R. and Williams, J.H. (1953).
Experimental chemotherapy of trypanosomiasis. (III) Effect of achromycin against trypanosome equiperdum and trypanosome cruzi.
Amer. J. Trop. Med. Hyg. 2, 254.

16. Sherman, J.F., Taylor, D.J. and Bond, H.W.
Puromycin (III) Toxicology and Pharmacology. Antibiol. Annual 1954-1955. 2nd Annual Symposium on Antibiotics. Editors H. Welch and F. Marti-Ibanez (Medical Encyclopedia Inc., Washington, D.C., 1955).

17. Ellis, A. (1942).
Natural history of Bright's disease; clinical, histological and experimental observations.
Lancet, 1, 1.

18. Dubach, V.C. and Recant, L. (1960).
Aminonucleosid-nephrose. Versuch einer biochemischen erklärung ätiologish verschiedener nephroseformen.
Klin. Wschr. 38, 1177.

19. Merchante, A., Ortega, R., Castro, H. and Jimenez Diaz, C. (1960).
Experimental kidney disease induced by a puromycin aminonucleoside.
Bull. Inst. Med. Res. Madrid, 13, 15.

20. Wilson, S.G.F., Hackel, D.B., Horwood, S., Nash, G. and Heymann, W. (1958).
Aminonucleoside nephrosis in rats.
Paediatrics, 21, 963.

21. Sakaguchi, H., Dachs, S., Grishman, E., Parometto, E., Saloman, M. and Churg, J. (1965).
Hepatic glomerulosclerosis. An electron microscopic study of renal biopsies in liver diseases.
Lab. Invest. 14, No. 5, 533.

22. Moscarello, M.A., Sutherland, L. and Jackson, S.H. (1967).
Stimulation of incorporation of glucosamine-1-^{14}C into rat plasma glycoproteins after renal damage.
Can. J. of Biochem. 45, 136.

23. Sarcione, E.J. (1963).
Synthesis of α1 acid glycoprotein by the isolated perfused rat liver.
Arch. Biochem. Biophys. 100, 516.

24. Sarcione, E.J. (1962).
Incorporation of glucose-C^{14} into plasma glycoprotein fractions by the isolated rat liver.
Biochem. 1, 1132.

25. Bucher, R. (1963).
Verlaufsformen der aminonucleosid-nephrose bei der ratte.
Z. Ges. Exp. Med. 136, 466.

26. Hoch-Ligeti, C. (1960).
Sequence of tissue, serum and urine changes in rats treated with aminonucleoside.
Brit. J. Exp. Path. 41, 119.

27. Spiro, D., Caulfield, J.B. and Craig, J. (1960).
Comparison of fine structural alterations in aminonucleoside nephrosis with human nephrosis.
(Abstract). Fed. Proc. 20, 407.

28. Hess, R. (1960).
Renal histochemistry of oxidative enzyme systems in aminonucleoside nephrosis.
Amer. J. Path. 37, 583.

29. Harkin, J.C. and Recant, L. (1958).
The earliest lesion in aminonucleoside nephrosis. An electron microscope study.
(Abstract). Amer. J. Path. 34, 559.

30. Harkin, J.C. and Recant, L. (1960).
Pathogenesis of experimental nephrosis. Electron microscopic observations.
Amer. J. Path. 36, 303.

31. Vernier, R.L., Papermaster, B.W. and Good, R.A. (1958).
Light and electron microscopic pathology of experimental aminonucleoside nephrosis. Relation to nephrosis in man.
(Abstract). Fed. Proc. 17, 463.

32. Vernier, R.L., Papermaster, B.W. and Good, R.A. (1959).
Aminonucleoside nephrosis 1. Electron microscopic study of the renal lesions in rats.
J. Exp. Med. 109, 115.

33. Lannigan, R., Kark, R. and Pollak, V.E. (1962).
The effect of a single intravenous injection of aminonucleoside of puromycin on the rat kidney: A light and electron microscopic study.
J. Path. Bact. 83, 357.

34. Feldman, J.D. and Fisher, E.R. (1961).
Chronic aminonucleoside proteinuria.
Lab. Invest. 10, 444.

35. Ericsson, J.L.E. and Andres, G.A. (1961).
Electron microscopic studies on the development of the glomerular lesions in aminonucleoside nephrosis.
Amer. J. Path. 39, 643.

36. Borowsky, B.A., Kessner, D.M., Hartroft, W. S., Recant, L. and Koch, M.B. (1961).
Aminonucleoside-induced chronic glomerulonephritis in rats.
J. Lab. Clin. Med. 57, 512.

37. Kortge, P., Palme, G. and Merker, H.J. (1961).
Licht und elektronmikroskopische untersochungen am glomerulum bei der aminonucleosid-nephrose der ratte.
Z. Ges. Exp. Med. 135, 167.

38. Movat, H.Z., Steiner, J.W. and Huhn, D. (1962).
The fine structure of the glomerulus in acute glomerulonephritis.
Lab. Invest. 11, 117.

39. Farquhar, M.G. and Palade, G.E. (1961).
Glomerular permeability. II. Ferritin transfer across glomerular capillary wall in nephrotic rats.
J. Exp. Med. 114(2), 699.

40. Movat, H.Z., Steiner, J.W. and Slater, R.J. (1961).
The fine structure of the glomerulus in Bright's disease. A clinical pathological study.
CIBA Foundation Symposium on Renal Biopsy.
p. 103.

41. Bucher, R. (1963).
Verlaufsformen der aminonucleosid-nephrose bei der ratte.
Z. Ges. Exp. Med. 136, 466.

42. Fiegelson, E.B., Drake, J.W., Recant, L.,Koch, M. and Grosswasser, N. (1957).
Experimental aminonucleoside nephrosis in rats.
J. Lab. Clin. Med. 50, 437.

43. Kefalides, N.A. and Winzler, R.J. (1966).
The chemistry of glomerular basement membrane and its relation to collagen.
Biochem. 5, No. 2, 702.

44. Chinard, F.P. (1952).
Deviation of expression for rate of formation of glomerular fluid (G.F.R.)
Amer. J. Physiol. 171, 578.

45. Kurtz, S.M. and Feldman, J.D. (1962).
Experimental studies on the formation of the glomerular basement membrane.
J. Ultrastructure Research 6, 19.

46. Jørgensen, F. (1967).
Electron microscopic studies of normal visceral epithelial cells.
Lab. Invest. 17, No. 2, 225.

47. Jørgensen, F. (1967).
Electron microscopic studies of normal glomerular basement membrane.
Lab. Invest. 17, No. 4, 416.

48. Pierce, G.B. and Nakane, P.K. (1967).
Antigens of epithelial basement membrane of mouse, rat and man.
Lab. Invest. 17, No. 5, 499.

49. Banson, B.B., Hartroft, W.S. and Recant, L. (1961).
Effect of choline on aminonucleoside nephrosis in rats: Effect of proteinuria on fatty liver of choline deficient rats.
Fed. Proc. 20, 288 (Abstract).

50. Banson, B.B., Hartroft, W.S. and Recant, L. (1962).
Enhancing effect of aminonucleoside-induced proteinuria on the dietary choline requirement of the rat.
J. Nutrit. 76, 247.

51. Lombardi, B. and Oler, A. (1967).
Choline deficiency fatty liver.
Lab. Invest. 17, No. 3, 308.

52. Dubach, U.C., Recant, L., Hatch, E. and Koch, M.B. (1960).
Sequence of development of hypercholesterolemia and hypoproteinuria in aminonucleoside nephrosis.
Proc. Soc. Exp. Biol. Med. 105, 592.

53. Marsh, J.B. and Drabkin, D.L. (1958).
Metabolic channeling in experimental nephrosis. V. Lipid metabolism in the early stages of the disease.
J. Biol. Chem. 230, 1083.

54. Dubach,U.C., Recant, L., Hatch, E. and Koch, M.B. (1961).
Negative feedback mechanism of cholesterol synthesis in experimental nephrosis.
Proc. Soc. Exp. Biol. Med. 106, 136.

55. Fiegelson, E.B., Drake, J.W., Recant, L. Koch, M.B. and Grosswasser, N. (1957).
Experimental aminonucleoside nephrosis in rats.
J. Lab. Clin. Med. 50, 437.

56. Metcoff, J., Kaiser, E., Yoshida, T., Yamashita, F. and Piccardo, M. (1960).
Further studies on metabolism during aminonucleoside nephrosis.
Proc. 11th Annual Conference Nephrotic Syndrome. Editor Jack Metcoff. 11, 164.

57. Dubach, U.C. and Recant, L. (1960).
Enzyme activity of isolated kidney glomeruli in two types of experimental nephrosis.
J. Clin. Invest. 39, 981 (Abstract).

58. Dubach, U.C. and Recant, L. (1962).
Glomeruläre fermente bei zwei verschiedener formen von nephrose.
Klin. Wschr. 40, 333.

59. Selsky, M.I. (1967).
Effects of puromycin aminonucleoside on growth and chloroplast development of euglena gracilis.
Exp. Cell Res. 47, 237.

60. Farnham, A.E. and Dubin, D.T. (1965).
Effect of puromycin aminonucleoside on RNA synthesis in L cells.
J. Mol. Biol. 14, 55.

61. Dickie, N., Alexander, C.S. and Nagasawa, H.T. (1965).
Inhibition of nucleic acid synthesis in escherichia coli B by puromycin aminonucleoside.
Biochim. Biophys. Acta 95, 156.

62. Farnham, A.E. (1965).
Effect of aminonucleoside (of puromycin) on normal and encephalomyocarditis (EMC) virus-infected L cells.
Virology, 27, 73.

63. Studzinski, G.P. and Ellem, K.A.O. (1965).
The relationship between cell division and RNA production studied with aminonucleoside of puromycin.
J. Cell Biol. 27, 102A (Abstract).

64. Studzinski, G.P. and Ellem, K.A.O. (1966).
Relationship between RNA synthesis, cell division, and morphology of mammalian cells.
J. Cell Biol. 29, No. 3, 411.

65. Eisenstadt, J. and Brawerman, G. (1964).
DNA from the chloroplast of euglena gracilis.
Biochim. Biophys. Acta 91, 477.

66. Brawerman, G. (1963).
A procedure for the isolation of RNA fractions resembling DNA with respect to nucleoside composition.
Biochim. Biophys. Acta 76, 322.

67. Eisenstadt, J. and Brawerman, G. (1964).
Template and ribosomal RNA associated with chloroplast and the cytoplasm of euglena gracilis.
J. Mol. Biol. 10, 392.

68. Eagle, H. (1955).
Nutritional needs of mammalian cells in tissue culture.
Science, 122, 501.

69. Puck, T.T., Cieciura, S.J. and Fisher, H.W. (1957).
Clonal growth in vitro of human cells with fibroblastic morphology. Comparison of growth and genetic characteristics of single and fibroblast-like cells from a variety of human organs.
J. Exp. Med. 106, 145.

70. Gomori, G. (1955).
Preparation of buffers for use in enzyme studies, in:
Methods of Enzymology, Vol. 1, Editors, S.P. Colowick, and N.O. Kaplan, p. 138. Academic Press Inc., New York.

71. Trump, B.F., Smuckler, E.A. and Benditt, E.P. (1961).
A method for staining epoxy sections for light microscopy.
J. Ultrastructure Research, 5, 343.

72. Lowry, O.H., Rosebrough, N.J., Farr, A.L. and Randall, R.J. (1951).
Protein measurement with the folin phenol reagent.
J. Biol. Chem. 193, 265.

73. Luft, J.H. (1961).
Improvement in epoxy resin embedding methods.
J. Biophys. Biochem. Cytol. 9, 409.

74. Karnovsky, M.J. (1961).
Simple method for staining with lead at high pH in electron microscopy.
J. Biophys. Biochem. Cytol. 11, 729.

75. Killander, J. (1964).
Separation of human heme- and hemoglobulin-binding plasma proteins, ceruloplasmin and albumin by gel filtration.
Biochim. Biophys. Acta 93, 1.

76. Greenwood, F.C., Hunter, W.M. and Glover, J.S. (1963).
The preparation of ^{131}I labelled human growth hormone of high specific radioactivity.
Biochem. J. 89, 114.

77. Steblay, R. (1958).
Isolation of human glomerular basement membrane and a study of its nephrotic properties.
Proc. of the 10th Annual Conference on Nephrotic Syndrome. Editor, J. Metcoff.

78. Smithies, O. (1959).
Biochem. J. 71, 585.

79. Steiner, J.W. and Baglio, C.M. (1963).
Electron microscopy of the cytoplasm of parenchymal liver cells in alph-naphthyl-isothiocyanate induced cirrhosis.
Lab. Invest. 12, 765.

80. Delozalova, V., Brada, Z., Kocent, A. (1964).
Host-tumour relationship. XII. Proteins of normal rat serum.
Neoplasma, 11, 151.

81. Journey, L.J. and Goldstein, M.N. (1961).
Electron microscope studies on HeLa cell lines sensitive and resistant to Actinomycin D.
Cancer Research, 21, 929.

82. Schoefl, G.I. (1964).
The effect of Actinomycin D on the fine structure of the nucleolus.
J. Ultrastructure Research, 10, 224.

83. Stenram, U. (1965).
Electron microscopic study on liver cells of rats treated with Actinomycin D.
Zeitschrift für Zellforschung, 65, 211.

84. Reynolds, R.C., Montgomery, P.O'B. and Hughes, B. (1964).
Nucleolar "caps" produced by Actinomycin D.
Cancer Research, 24, 1269.

85. Kume, F., Maruyama, S., D'Agostino, A.N. and Chiga, M. (1967).
Nucleolar change produced by Mithramycin in rat hepatic cell.
Exp. Mol. Path. 6, 254.

86. Jezequel, A.M., Shreeve, M.M. and Steiner, J.W. (1967).
Segregation of nucleolar components in mycoplasma-infected cells.
Lab. Invest. 16, 287.

87. Montgomery, P.O'B., Reynolds, R.C. and Cook, J.E. (1966).
Nucleolar "caps" induced by flying spot ultraviolet nuclear irradiation.
Amer. J. Path. 49, 555.

88. Simard, R. and Bernhard, W. (1966).
Le phenomene de la segregation nucleolaire: Speficite d'action de certain antimetabolites.
Int. J. Cancer, 1, 463.

89. Nagasawa, H.T., Swingle, K.F. and Alexander, C.S. (1967).
Metabolism of aminonucleoside-8-C^{14} in the rat and guinea pig.
Biochem. Pharmacol. 16, 2211.

90. Zimmerman, E.F. and Holler, B.W. (1967).
Methylation of 45S ribosomal RNA precursor in HeLa cells.
J. Mol. Biol. 23, 149.

91. Geuskens, M. and Bernhard, W. (1966).
Cytochimie ultrastructurale du Nucleole.
Exp. Cell Res. 44, 579.

92. Warner, J.R., Rich, A. and Hall, C. (1962).
Electron microscope studies of ribosomal clusters synthesizing haemoglobin.
Science, 138, 1399.

93. Lawford, G.R. and Schachter, H. (1966).
Biosynthesis of glycoprotein by liver.
J. Biol. Chem. 241, 5408.

94. Godchaux, III, W., Adamson, S.D. and Herbert, E. (1967).
Effects of cycloheximide on polyribosome function in reticulocytes.
J. Mol. Biol. 27, 57.

95. Kovacs, S. (1967).
Personal communication.

96. Lewis, L.A., Zuehlke, V., Nakamoto, S., Kolff, W.J. and Page, I.H. (1966).
Renal regulation of serum -lipoproteins.
New England J. Med. 275, 1097.

97. Huang, F., Hutton, L. and Kalant, N. (1967).
Molecular sieving by glomerular basement membrane.
Nature, 216, 87.

98. Yoshida, T., Metcoff, J., Kaiser, E. and Yamashita, F.F. (1961).
Metabolites in kidney, liver and muscle of rats with aminonucleoside nephrosis.
Proc. 12th Annual Conference on Nephrotic Syndrome. 12, 146.

Figures 2 to 3: Cultures grown on coverslips, fixed with Bouin's and stained with giemsa.

Figure 2 HeLa cells grown in normal Hanks' basal medium (Eagle) for 7 days form a complete cellular sheet on coverslip. The nuclei are round and oval and contain two to four large nucleoli irregular in shape and size.

X 650

Figure 3 HeLa cells grown in normal medium for 3 days, and then in medium containing aminonucleoside for 4 days are loosely scattered over the surface of the coverslip. The nuclei contain multiple spherical nucleoli of varying sizes.

X 650


2

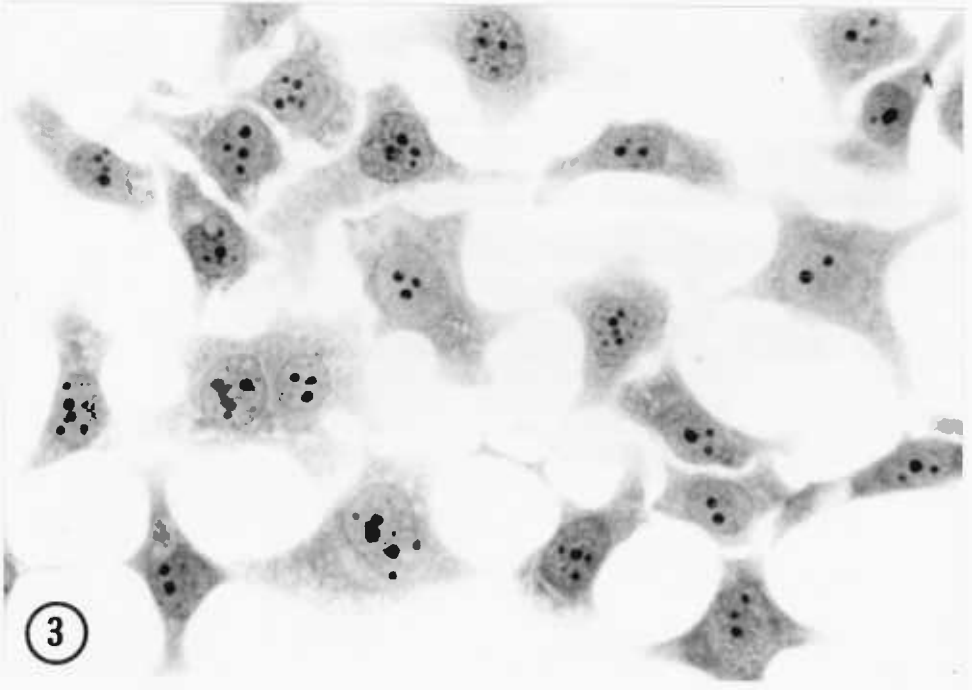
3

Figures 4 to 5: HeLa cells fixed in osmium and embedded in epon. Stained with toluidine blue.

Figure 4 Normal HeLa cells grown in Hanks' basal medium for 7 days.

X 430

Figure 5 HeLa cells grown in normal medium for 3 days and then in medium containing aminonucleoside for 3 days.

X 430

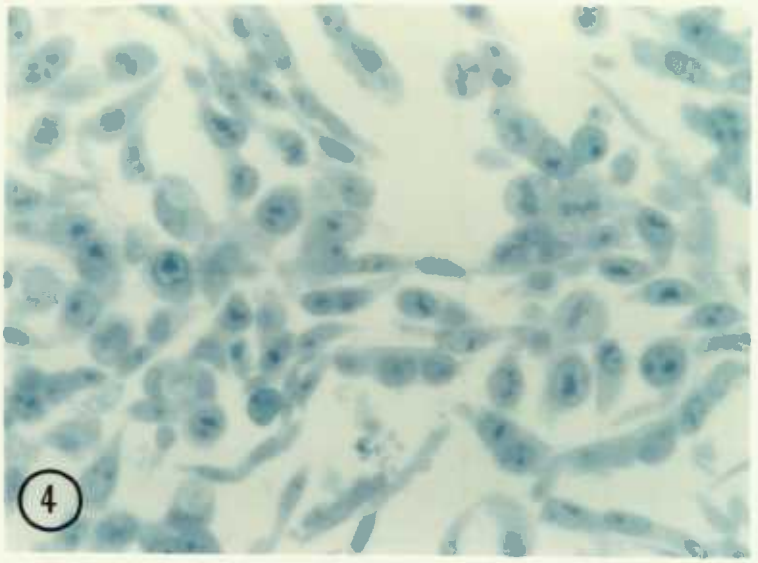
4

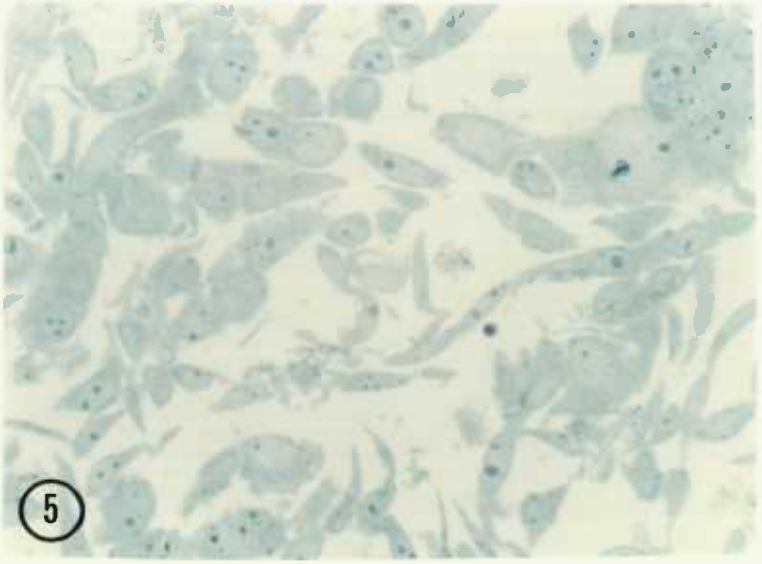
5

Figure 6 Normal 5 day HeLa cell showing the nucleus and nucleolar components. N: nucleus, Nu: nucleolus, f: fibrillar component, g: granular component, Go: golgi apparatus. Fixation with osmium tetroxide lead hydroxide stain.

X 24,500

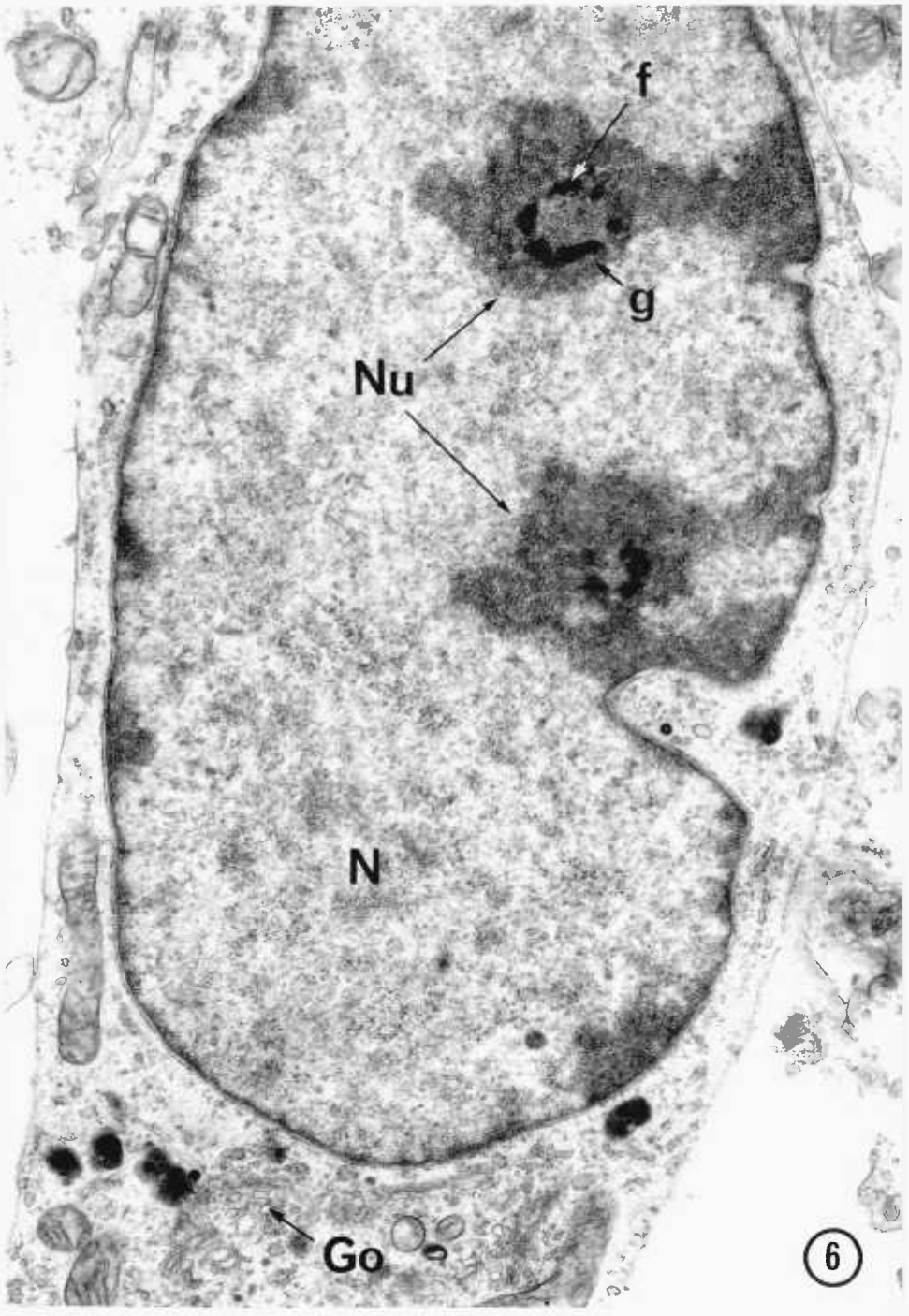
f
g
Nu
N
Go
6

Figure 6A Normal 5 day HeLa cell.

X 17,500

N: nucleus, M: mitochondria,

Mi: microvilli

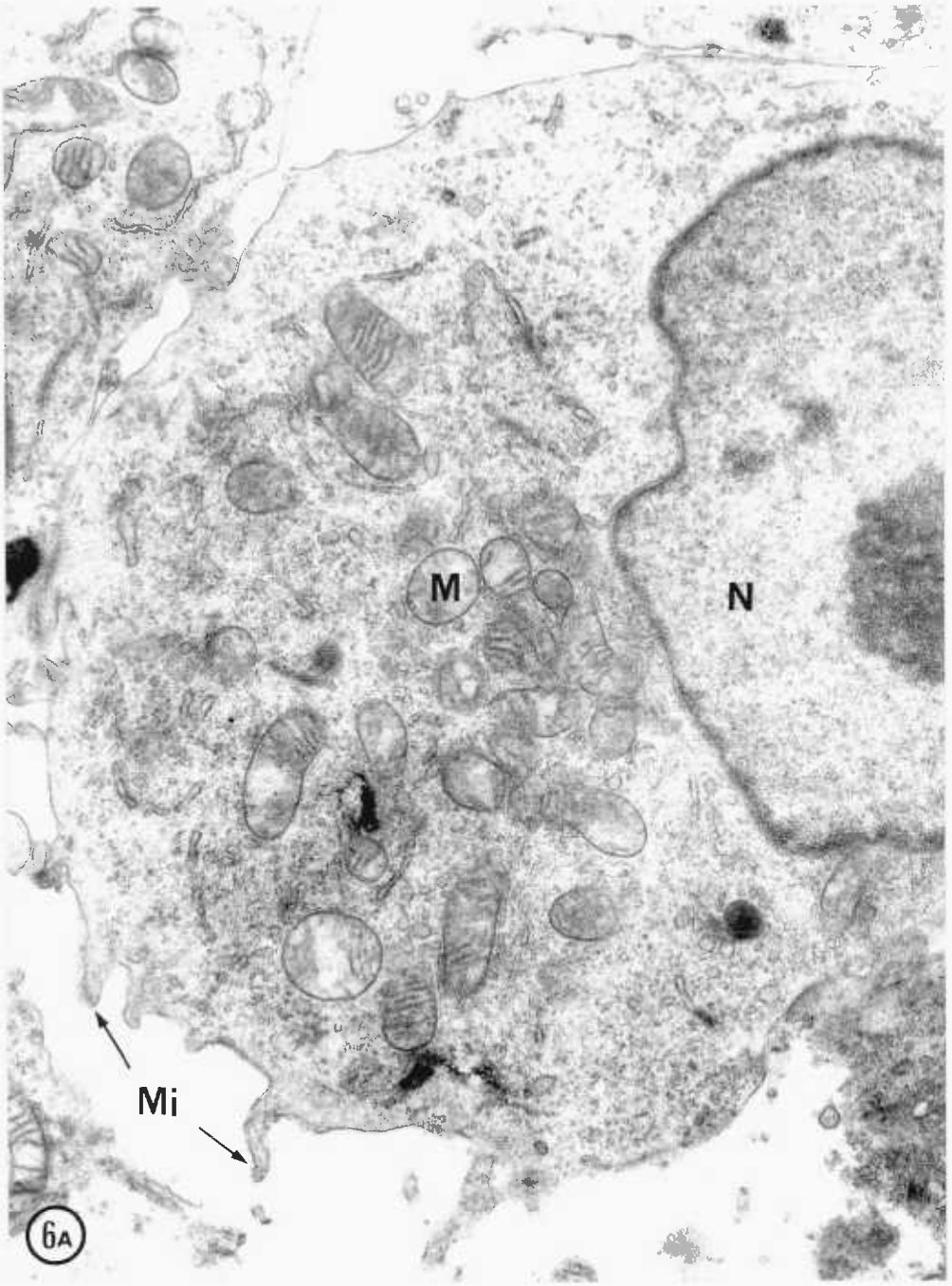
M
N
Mi
6A

Figure 7 Detail of a normal nucleolus in a 6 day HeLa cell.
Nm: nuclear membrane, g: granular component, f: dense fibrillar component, L: light granular component. Fixation with osmium tetroxide, lead hydroxide stain.
X 34,500

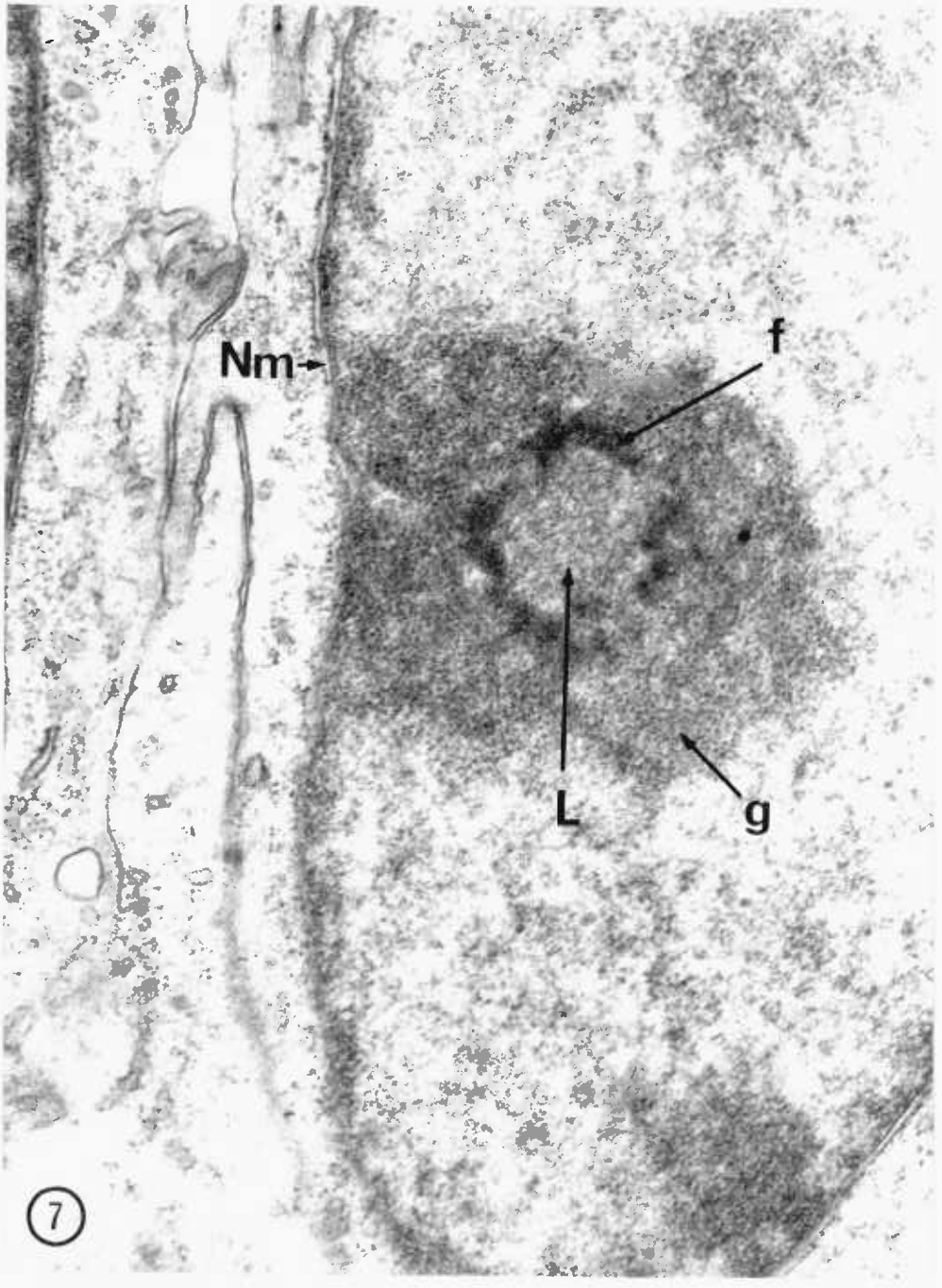
Nm
f
L
g
7

Figure 8 4 day HeLa cell grown in medium containing aminonucleoside (100 μg/ml) for 24 hours. Note the separation of the nucleolar components within the nucleolus.
g: granular component,
f: fibrillar component,
a: amorphous component.
Fixation with osmium tetroxide, lead hydroxide stain.
X 14,700

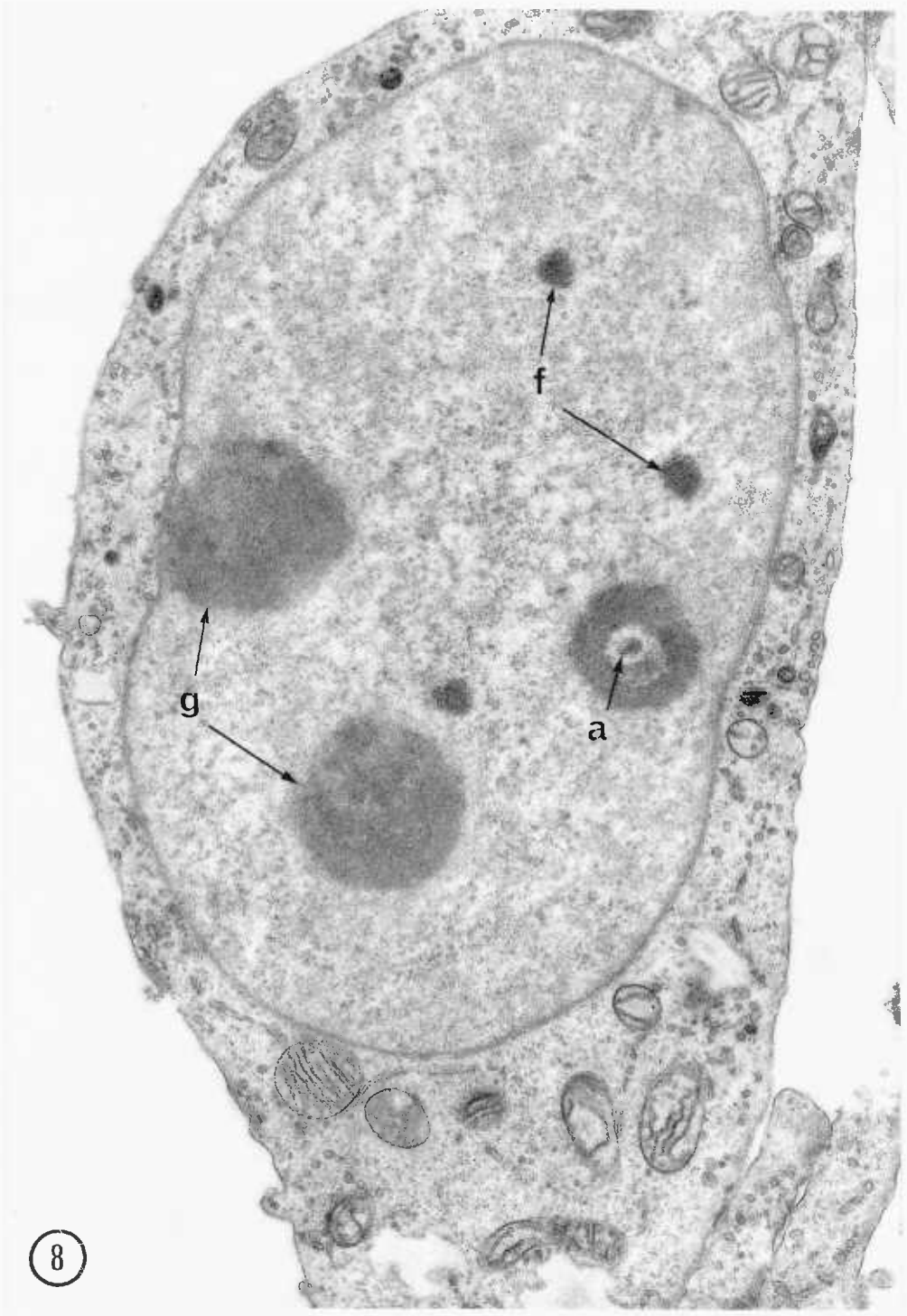
f
g
a
8

Figures 9 to 10: Details of nucleoli of HeLa cells exposed to medium containing aminonucleoside (100 μg/ml).

Figure 9 Nucleolus from HeLa cell exposed to aminonucleoside in medium for 48 hours. The fibrillar components have clumped and have migrated towards the periphery of nucleolus. The light amorphous nucleolar component contains a number of dense particles which are also present in the fibrillar component and the nucleoplasm. Fixed in osmium tetroxide. Stained with lead hydroxide. X 24,000.

Figure 10 Nucleolus from HeLa cell exposed to medium containing aminonucleoside for 60 hours, showing two compact fibrillar bodies that have separated from the nucleolus and are situated in the nucleoplasm. X 35,000. f: fibrillar component, g: compact granular component, a: amorphous component, p: particulate bodies.

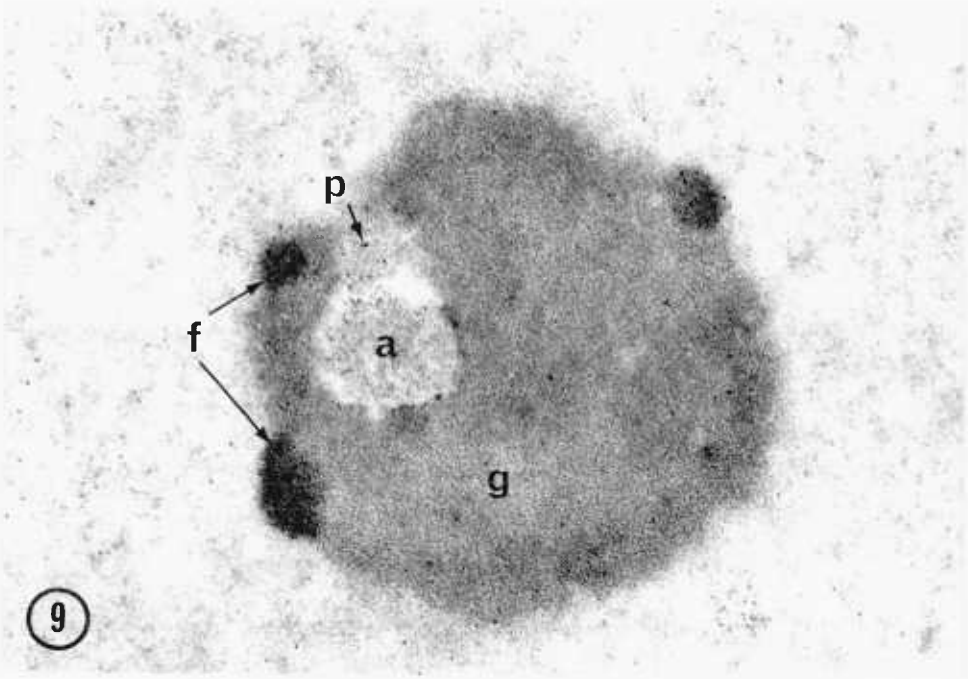
p
f
a
g
9

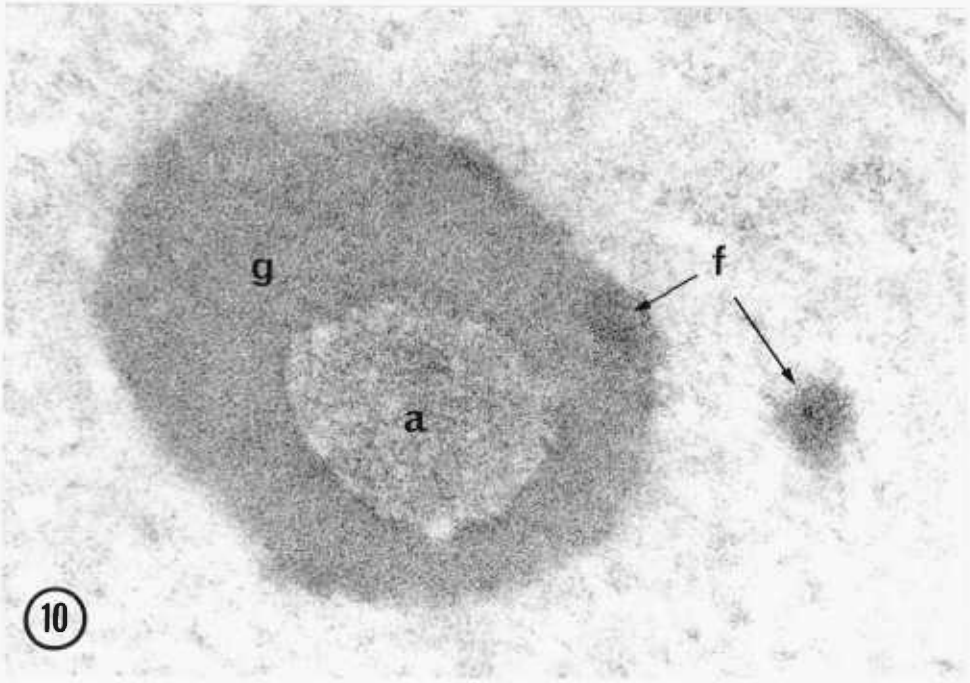
g
f
a
10

Figure 11 HeLa cells exposed to medium containing aminonucleoside for 72 hours showing complete separation of fibrillar and granular components in one cell. N: nucleus, f: fibrillar component, g: granular component. Fixed in osmium tetroxide, stained with lead hydroxide.

X 15,300

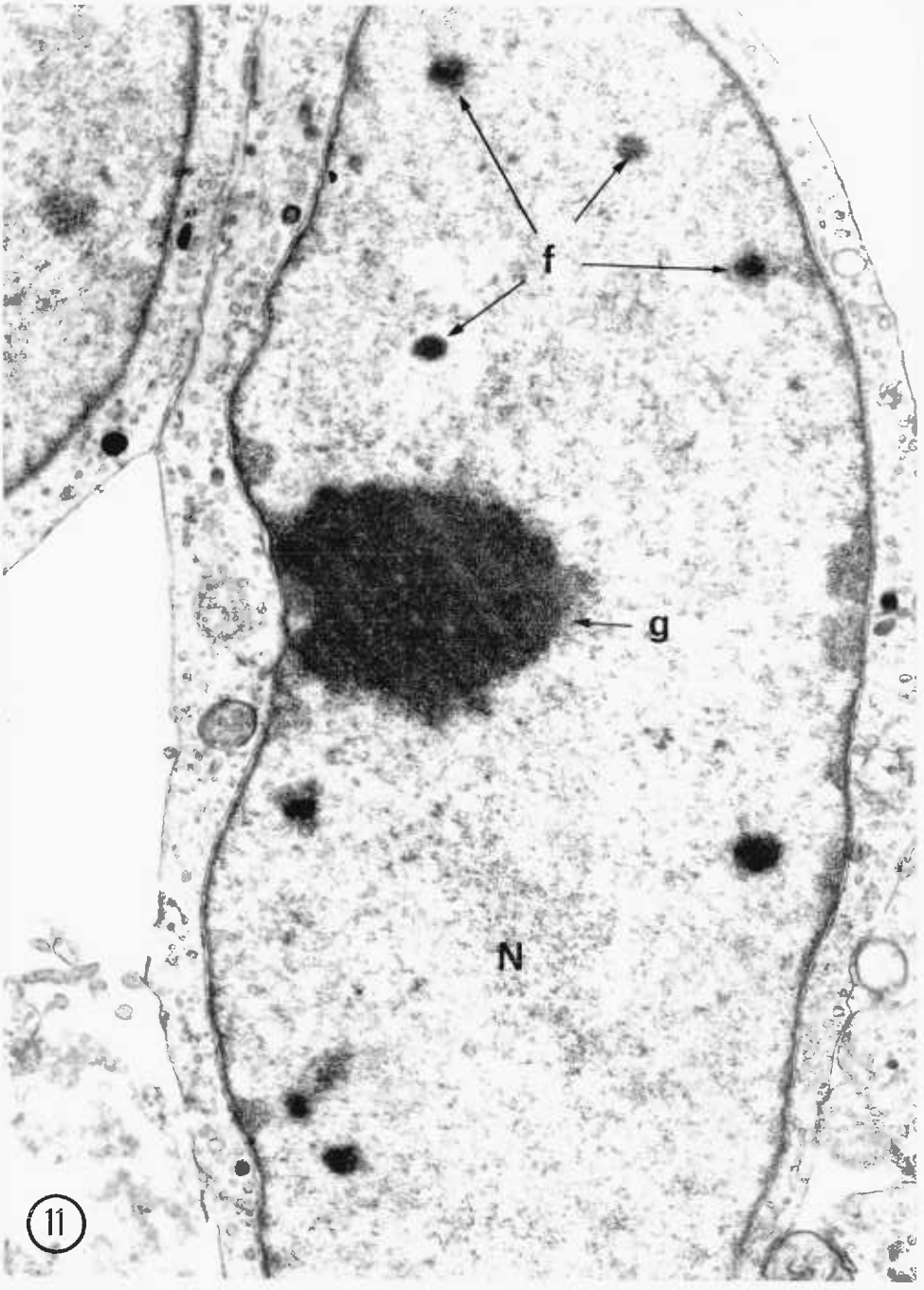
f
g
N
11

Figure 12 Normal glomerulus from rat kidney.
Stained with PAS.
X 430

Figure 13 Glomerulus from rat kidney treated with aminonucleoside for 24 hours.
Stained with PAS.
X 430

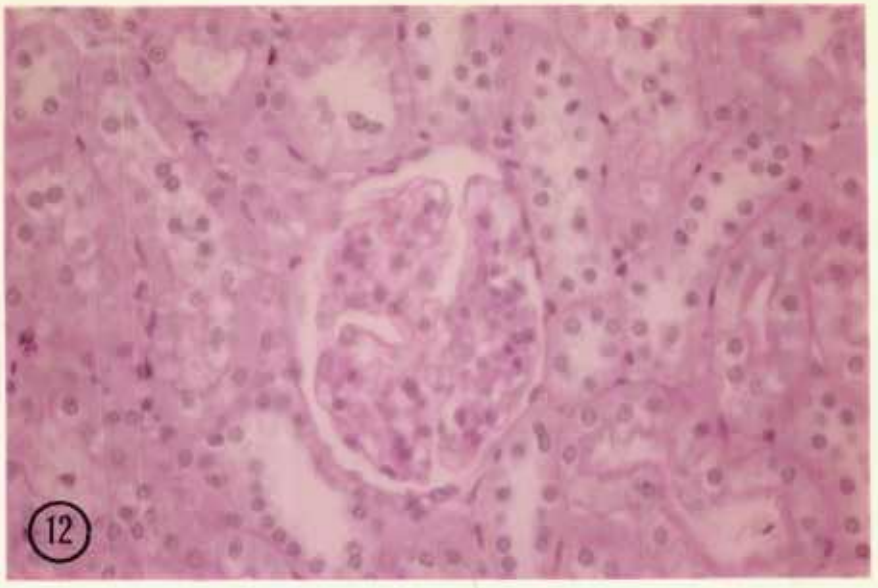
12

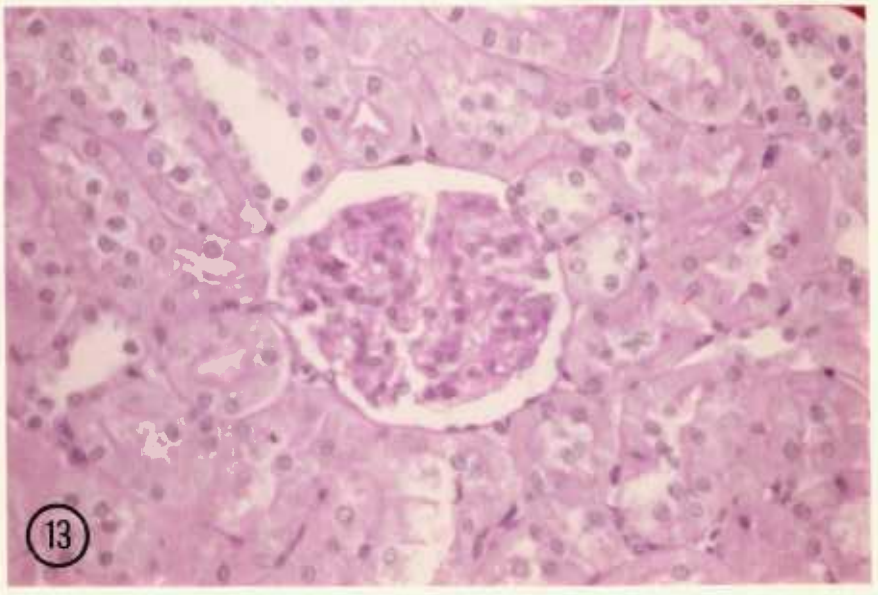
13

Figure 14 Glomerulus from rat treated with aminonucleoside for 4 days.
Stained with PAS.
X 430

Figure 15 Glomerulus from rat treated with aminonucleoside for 7 days during nephrotic stage.
Note mucoproteinaceous material in glomerular spaces.
Stained with PAS.
X 430

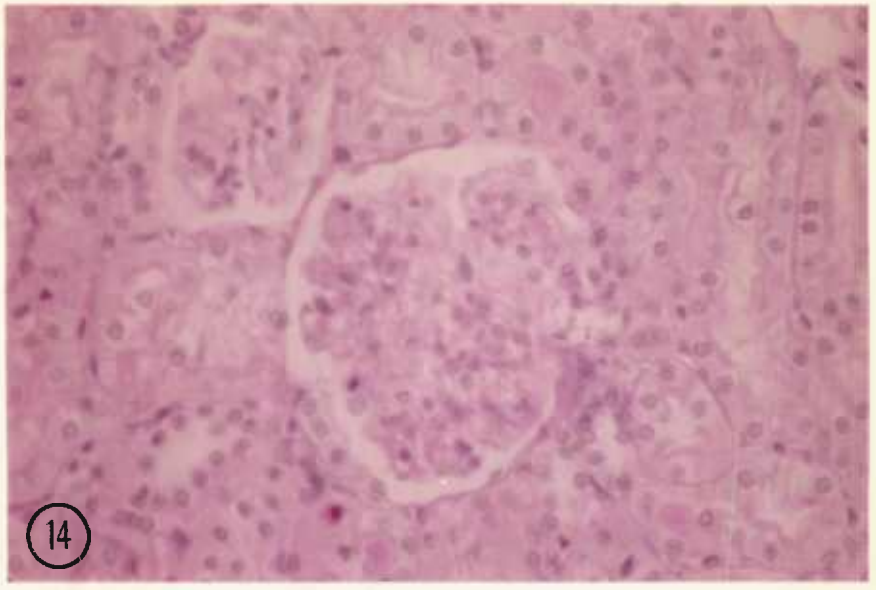
14

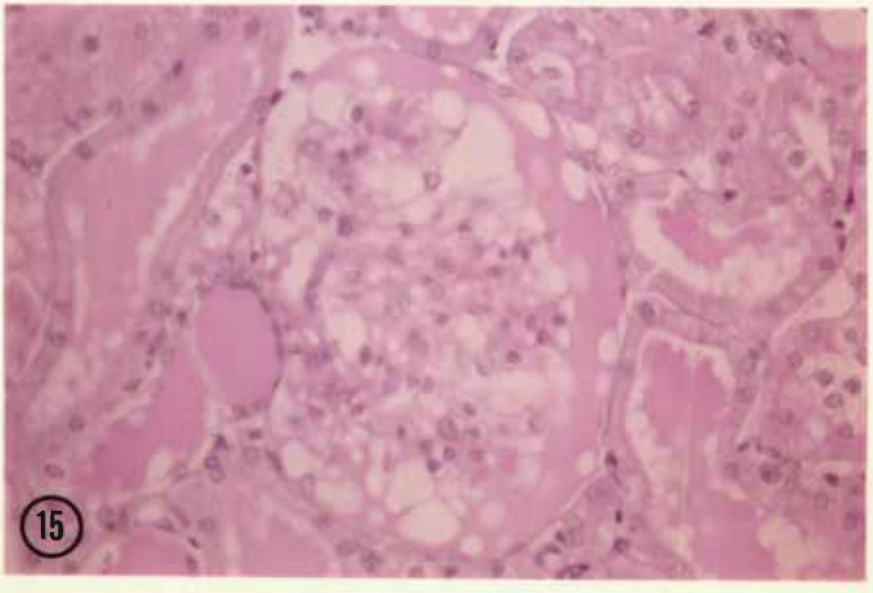
15

Figures 16 to 17: Liver sections fixed in osmium oxide and embedded in epon. Stained with toluidine blue.

Figure 16 Normal hepatocytes in rat liver section.

X 430

Figure 17 Hepatocytes of liver of rat treated with aminonucleoside for 24 hours. Note increase of light hepatocytes compared to dark hepatocytes.

X 430

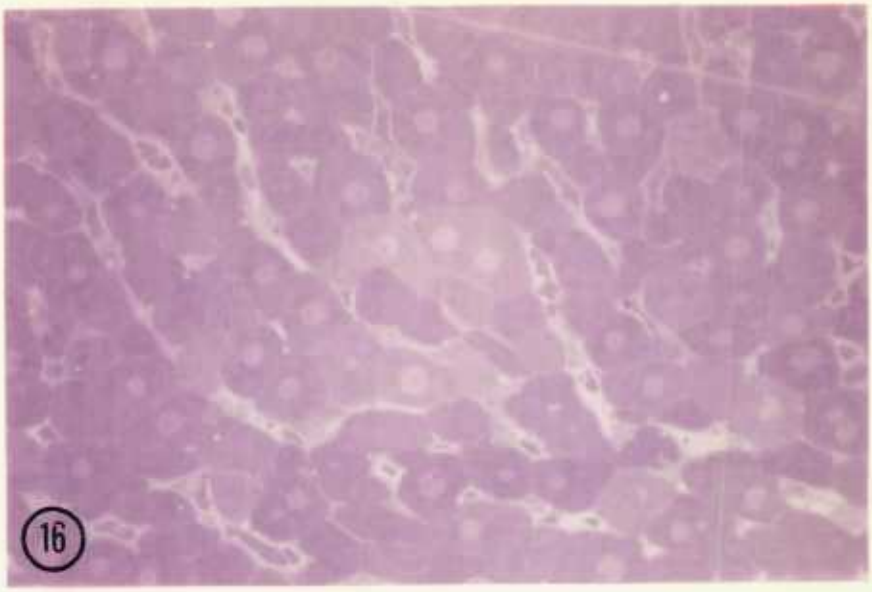
16

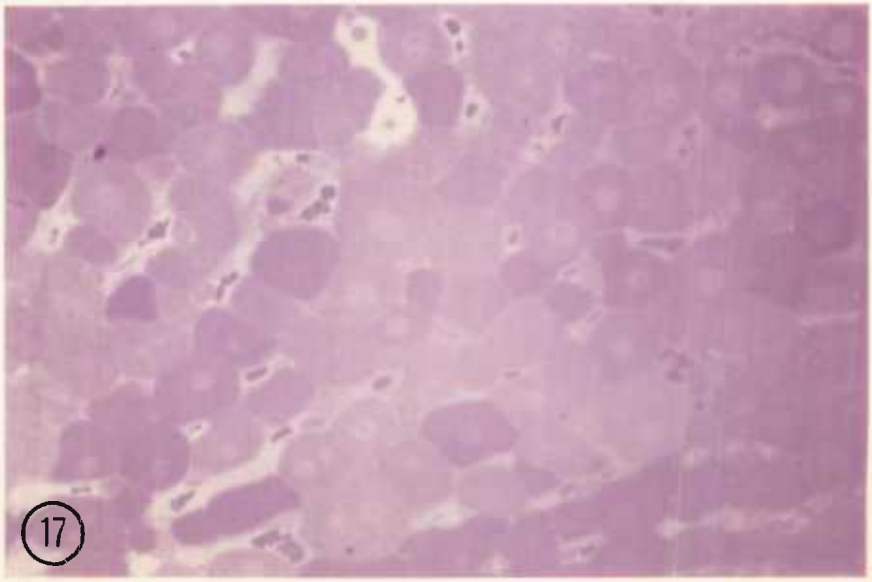
17

Figure 18 Portion of a normal glomerulus showing an epithelial cell with cytoplasmic extensions (foot processes) attached to basement membrane. A thin layer of endothelial cytoplasm with a number of pores, lines the vascular surface of the basement membrane.

X 15,000

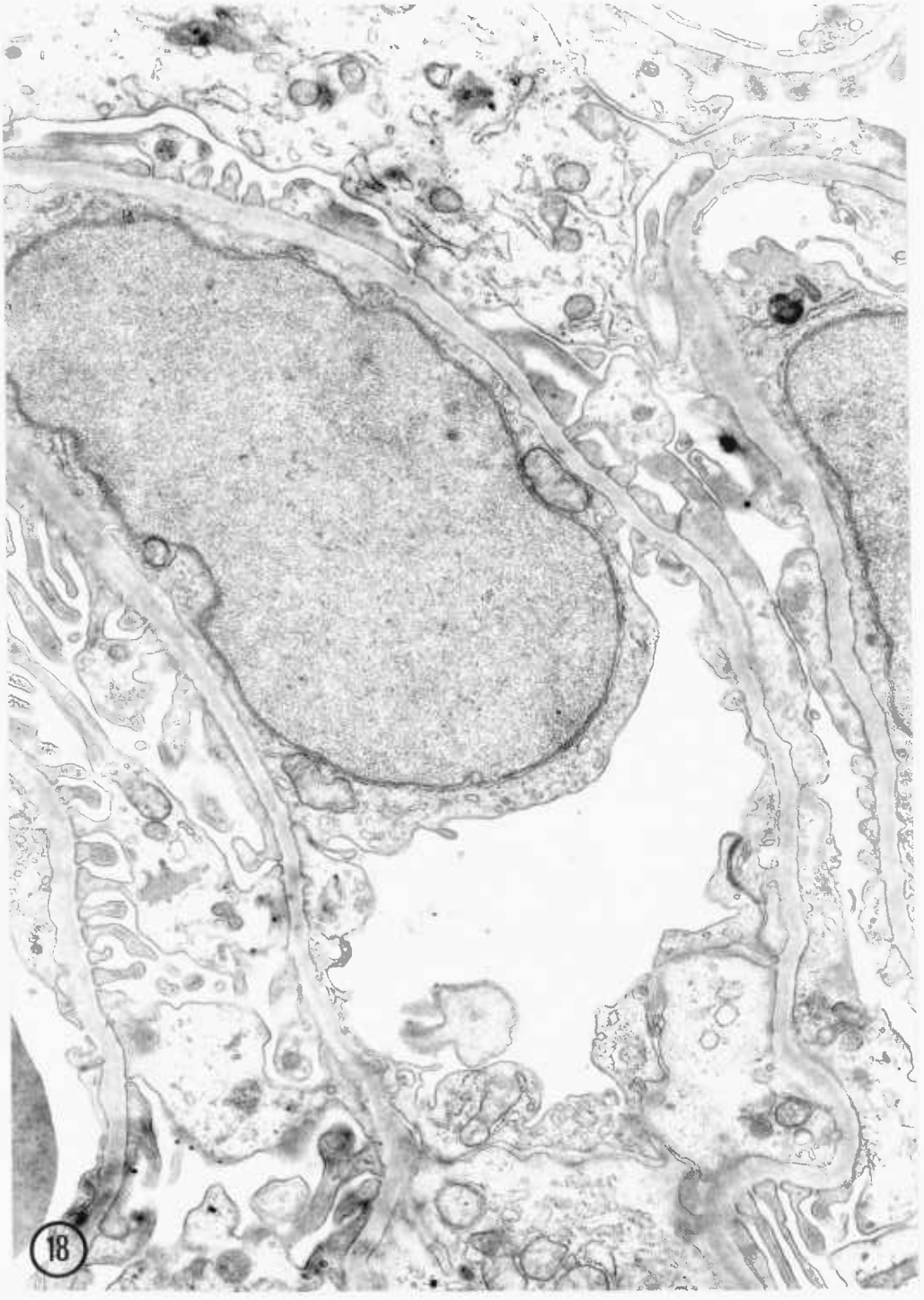
18

Figure 19 24 hours following aminonucleoside, no gross structural abnormalities are seen in glomerulus.

X 18,000

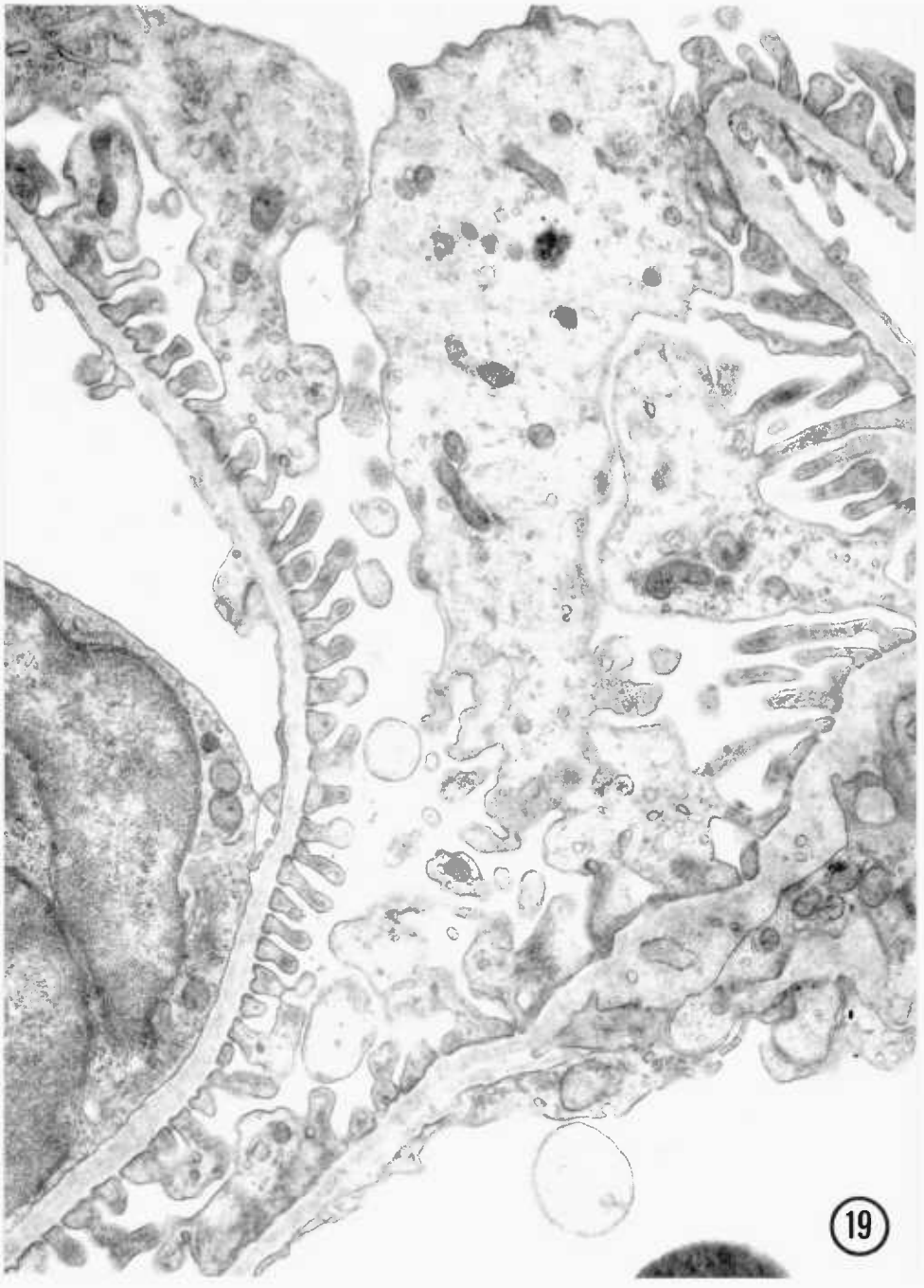
19

Figure 20 4 days after aminonucleoside, extension and thickening of epithelial cell foot processes along basement membrane is observed.

X 20,000

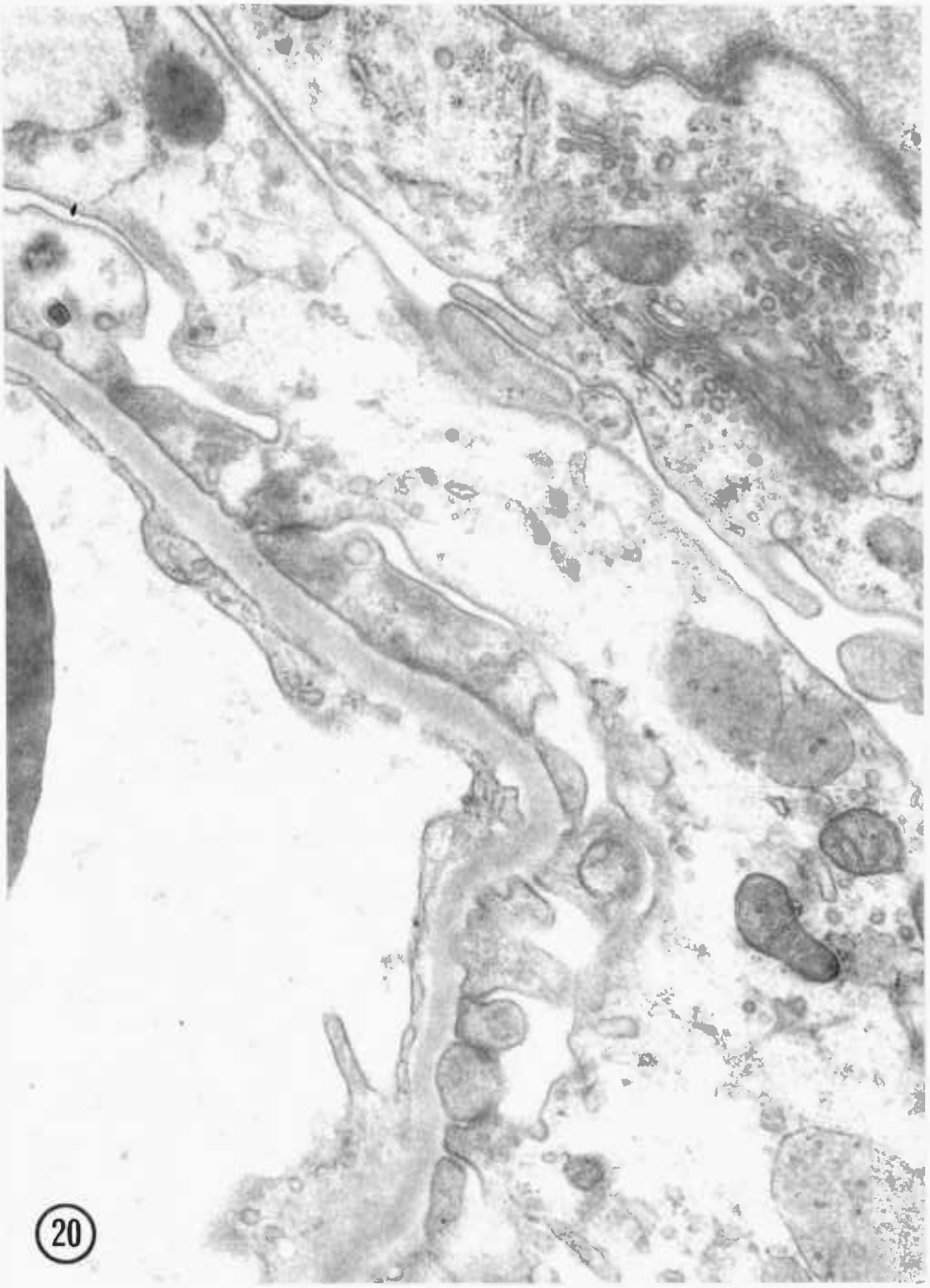

20

Figure 21 7 days after aminonucleoside, epithelial cell of glomerulus contains numerous cytoplasmic inclusions and is intimately attached to basement membrane with no intervening foot processes. Vascular endothelial cytoplasmic hyperplasia is also observed.

X 18,000

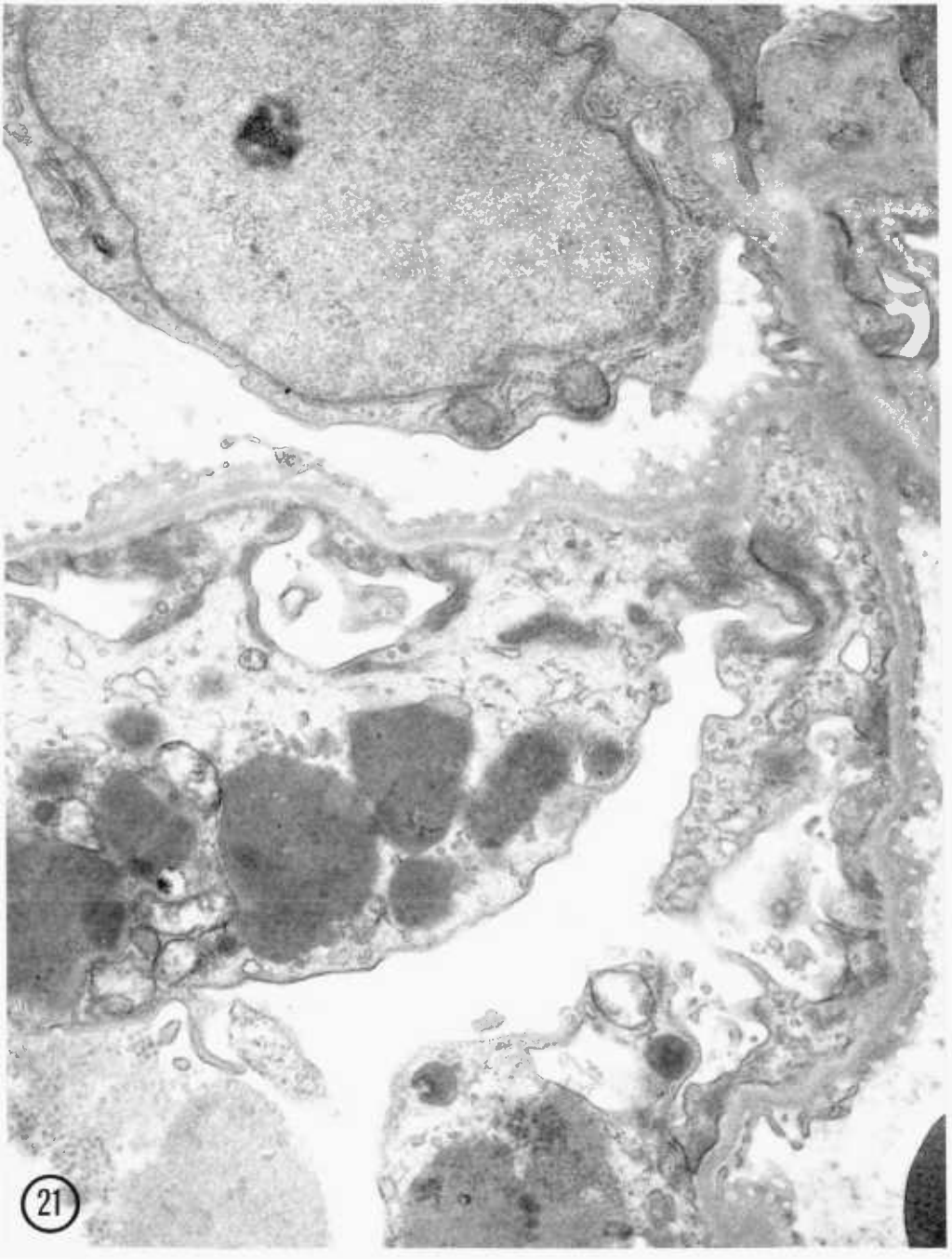
21

Figure 22 Ultrastructure of a normal proximal convoluted tubular cell of rat kidney. Note the microvilli of the brush border lining the tubular lumen.

X 9,650

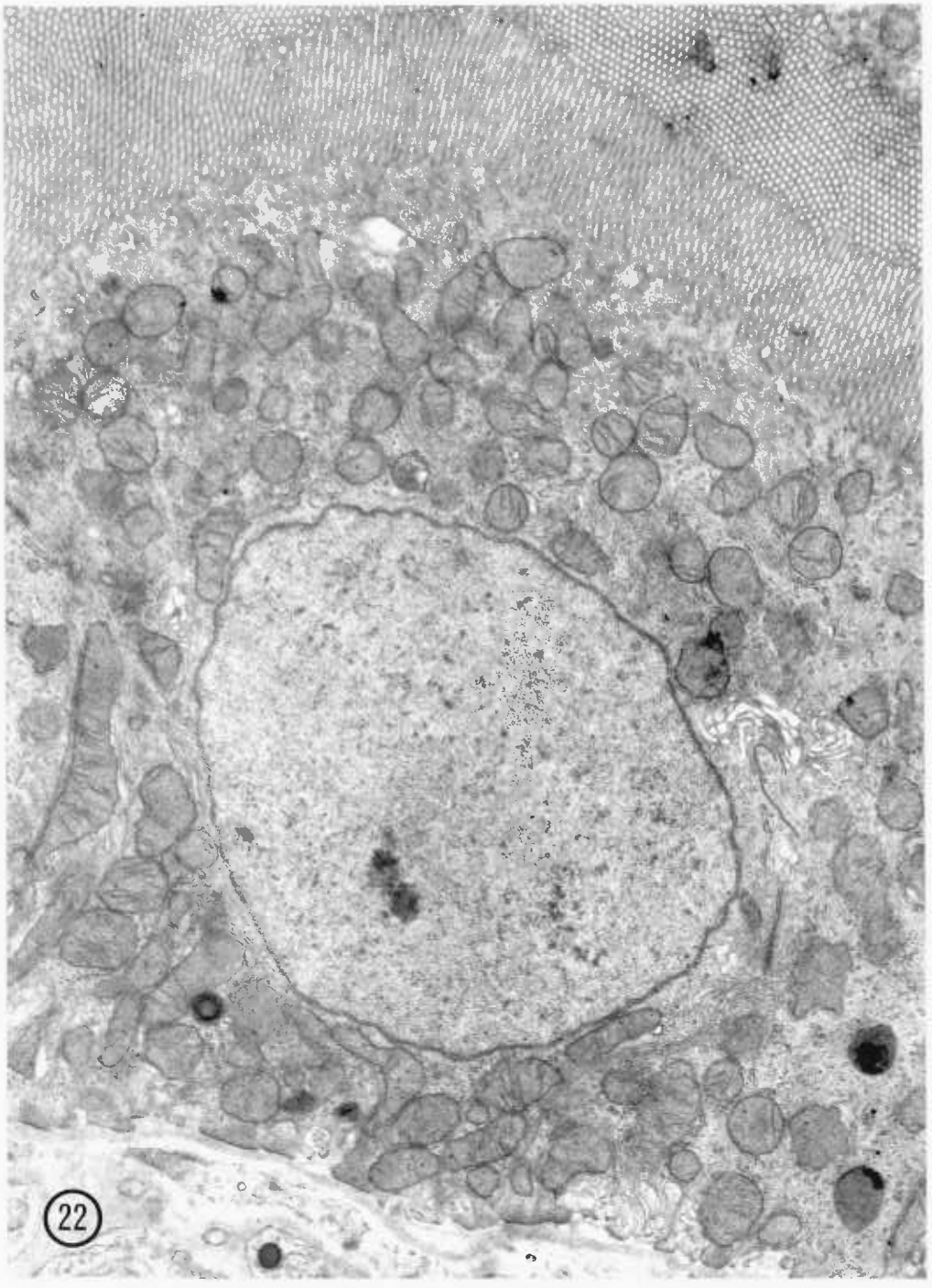
22

Figure 23 Proximal convoluted tubular cell four days after intravenous aminonucleoside. Note the vesicular dilatation of endoplasmic reticulum of cytoplasm X 7,500

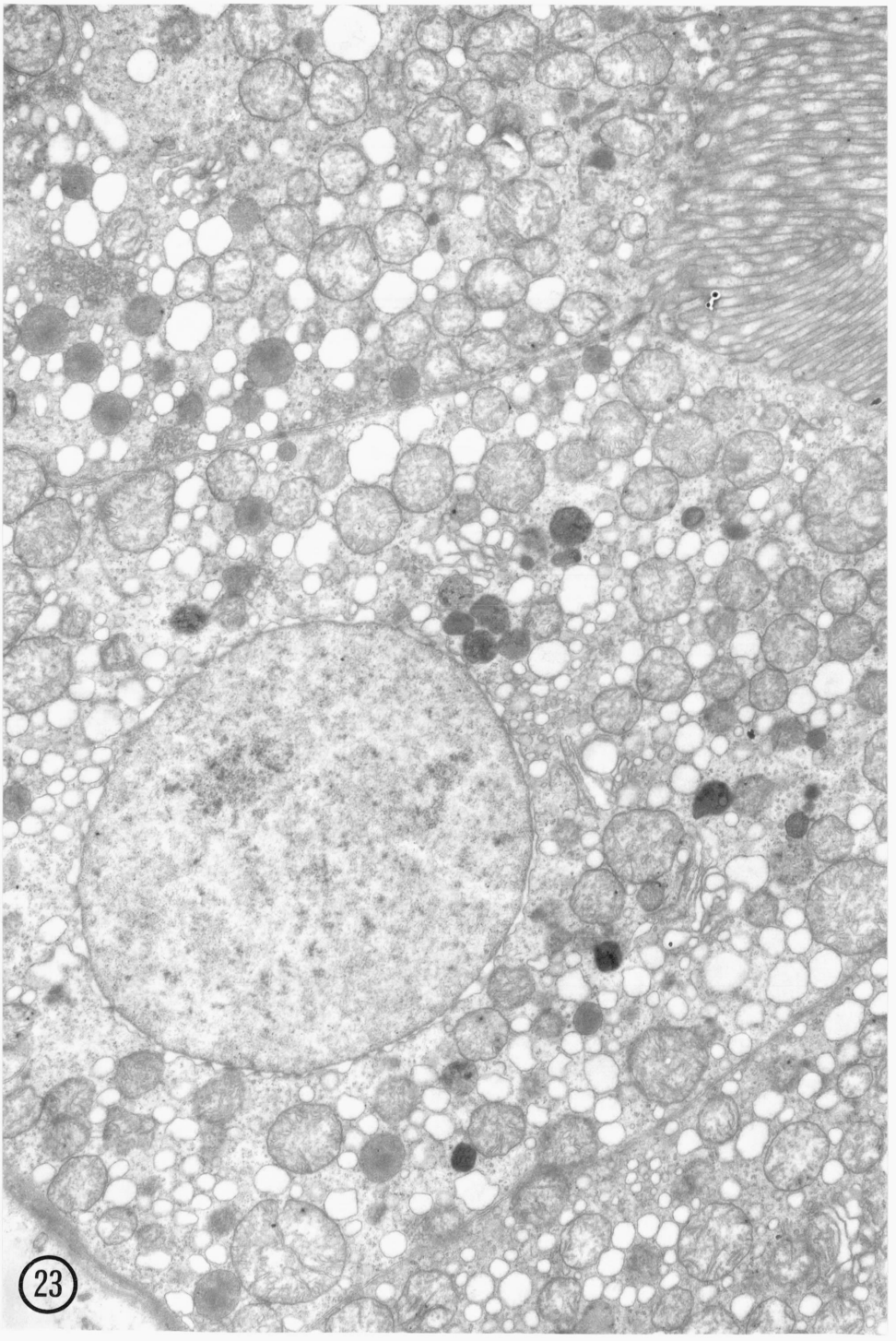
23

Figure 24 Normal starved rat hepatocyte showing cytoplasmic architecture with regular arrays of rough endoplasmic reticulum. Part of nucleus and nucleolus is also seen.

X 24,750

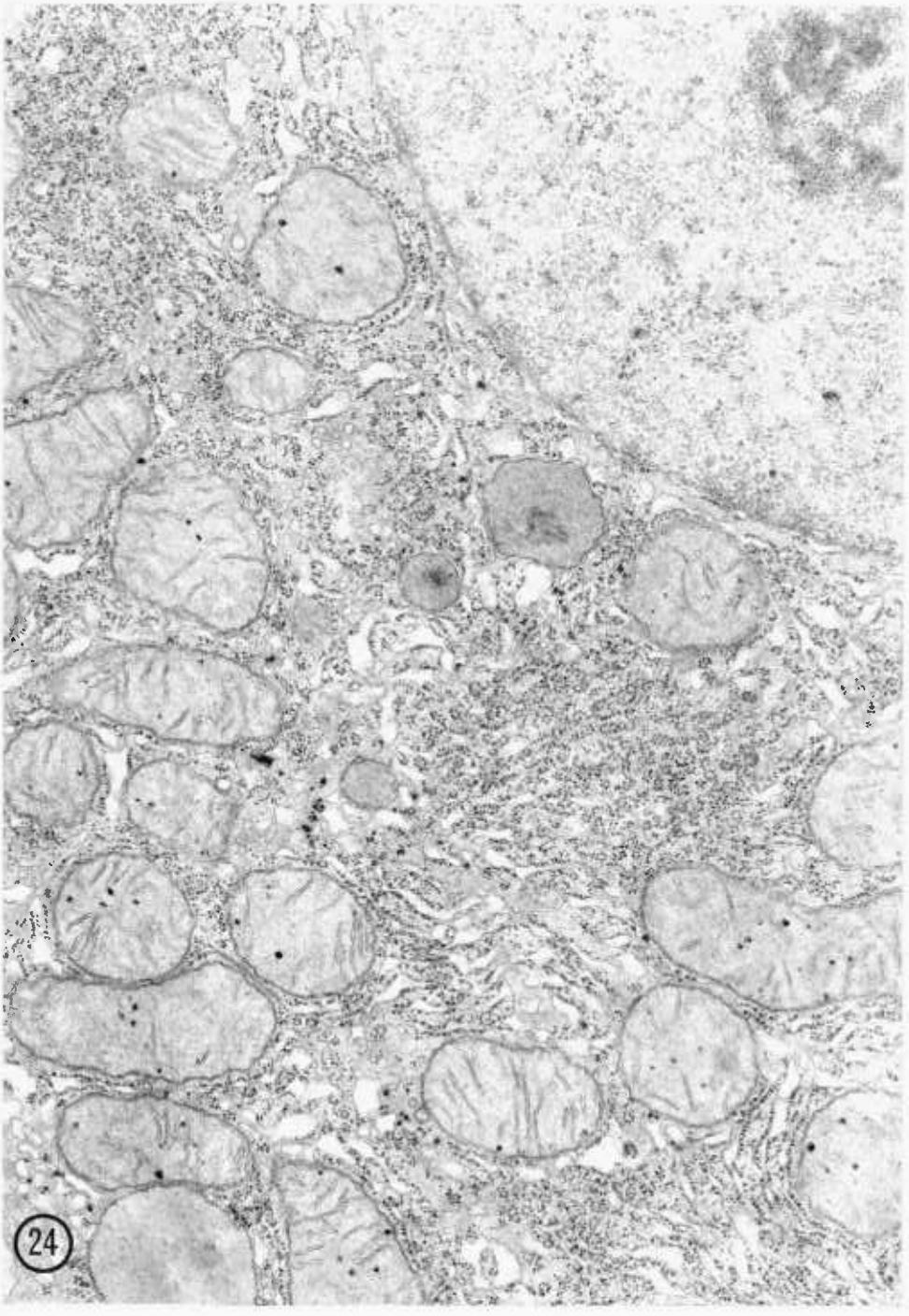
24

Figure 25 Hepatocyte 6 hours after aminonucleoside showing loss of regular cytoplasmic architecture with vesiculation of smooth and rough endoplasmic reticulum. Note moderate nucleolar component separation at this stage.

X 29,750

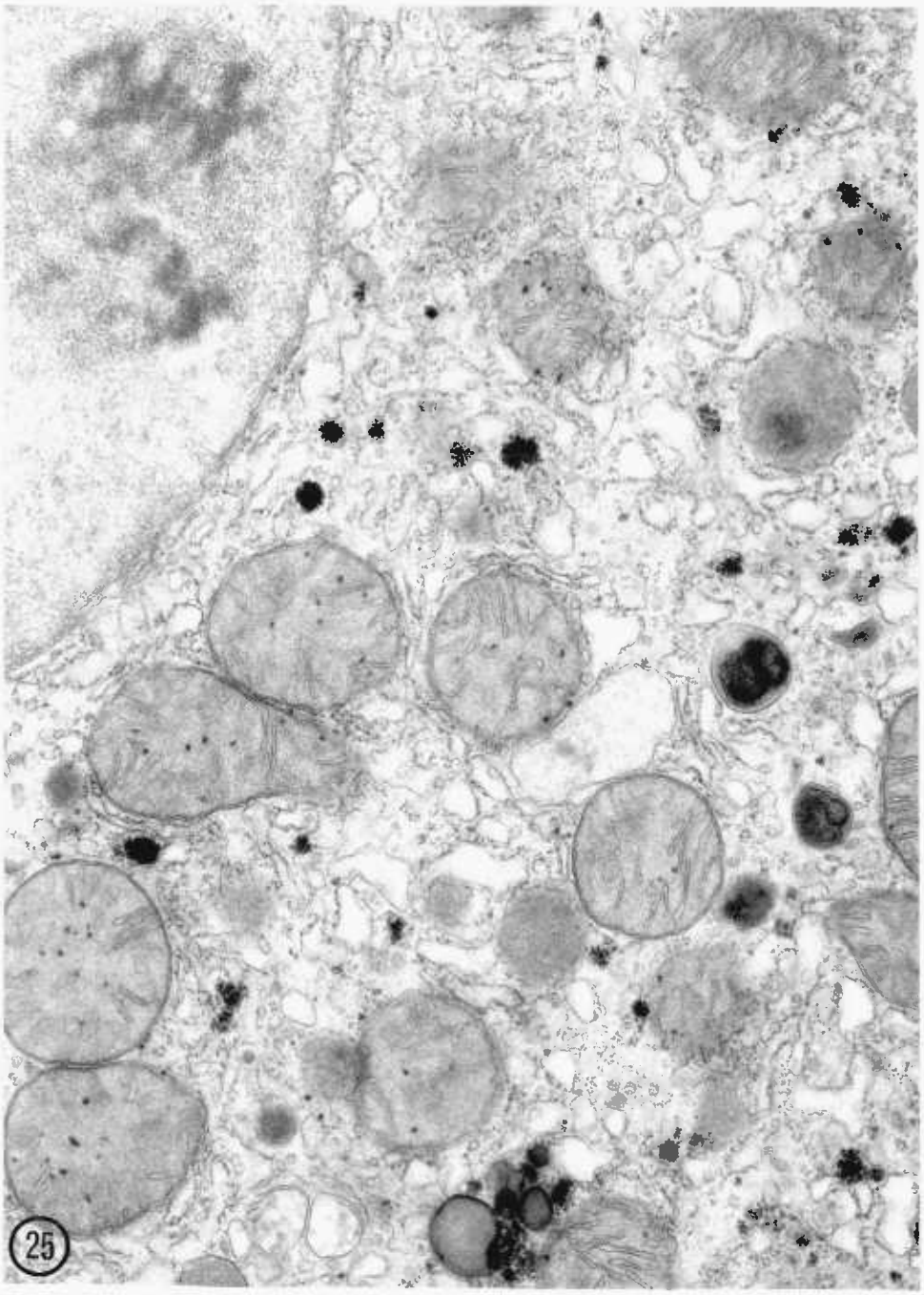
25

Figure 26 Cytoplasm of a hepatocyte 6 hours after aminonucleoside showing loss of regular cytoplasmic architecture with vesiculation of both smooth and rough endoplasmic reticulum.

X 34,000

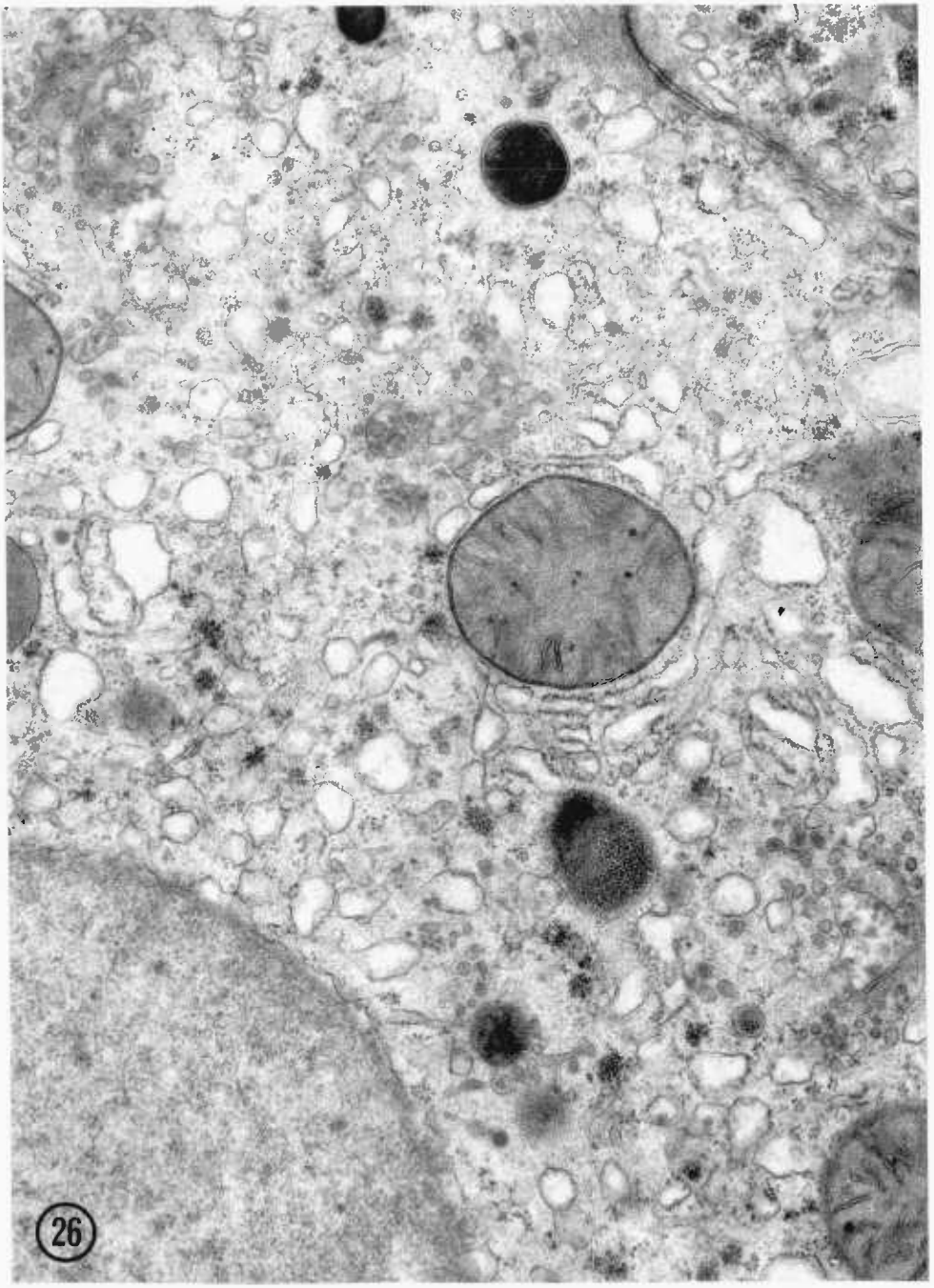
26

Figure 27 Hepatocyte 24 hours after amino-nucleoside showing gross dilation of endoplasmic reticulum. Separation of fibrillar and granular component of nucleolus is also observed.

X 19,250

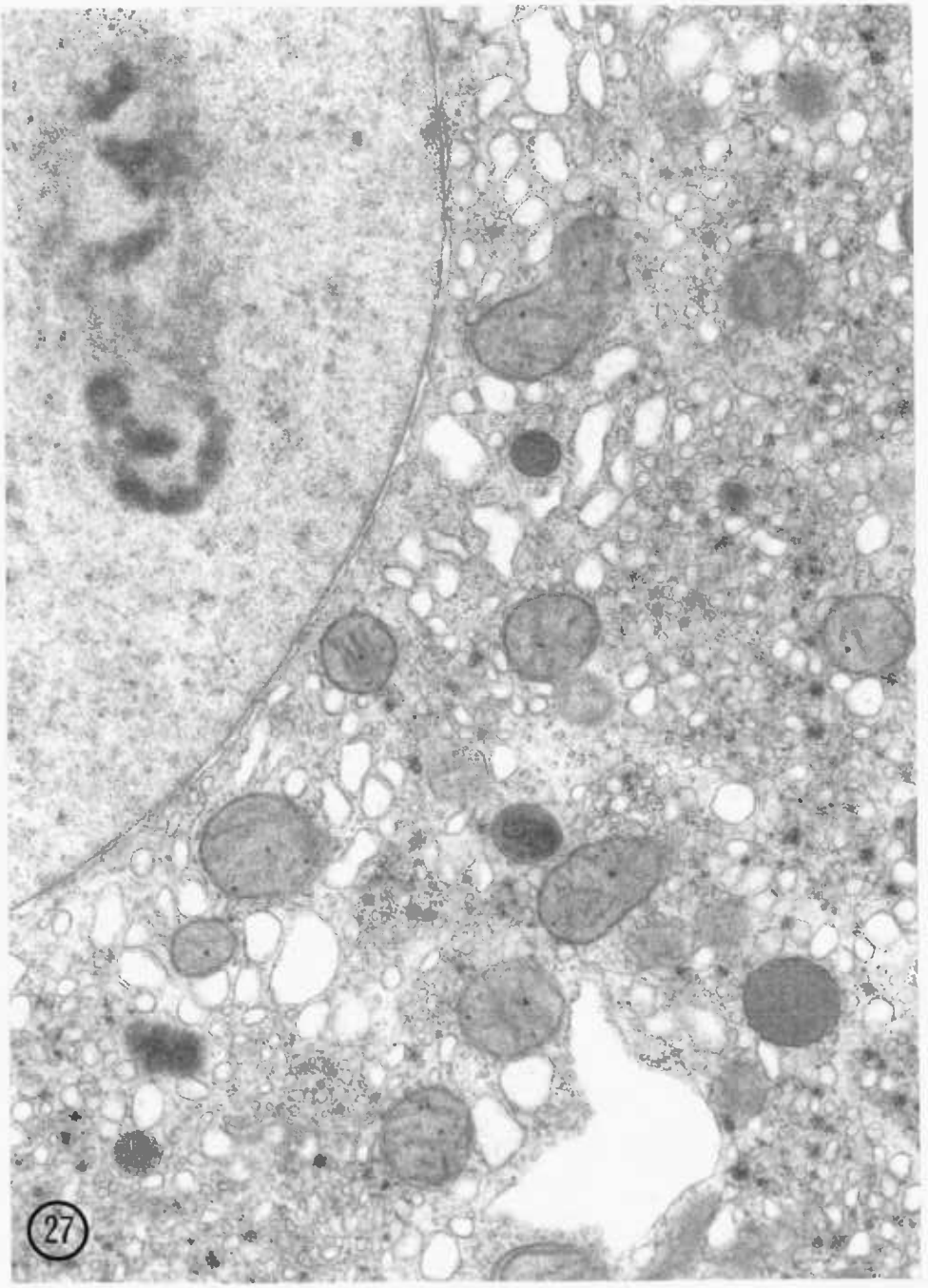
27

Figure 28 Cytoplasmic component of hepatocyte 24 hours after aminonucleoside to show dilation of rough endoplasmic reticulum associated with a number of abnormally shaped mitochondria.

X 18,000

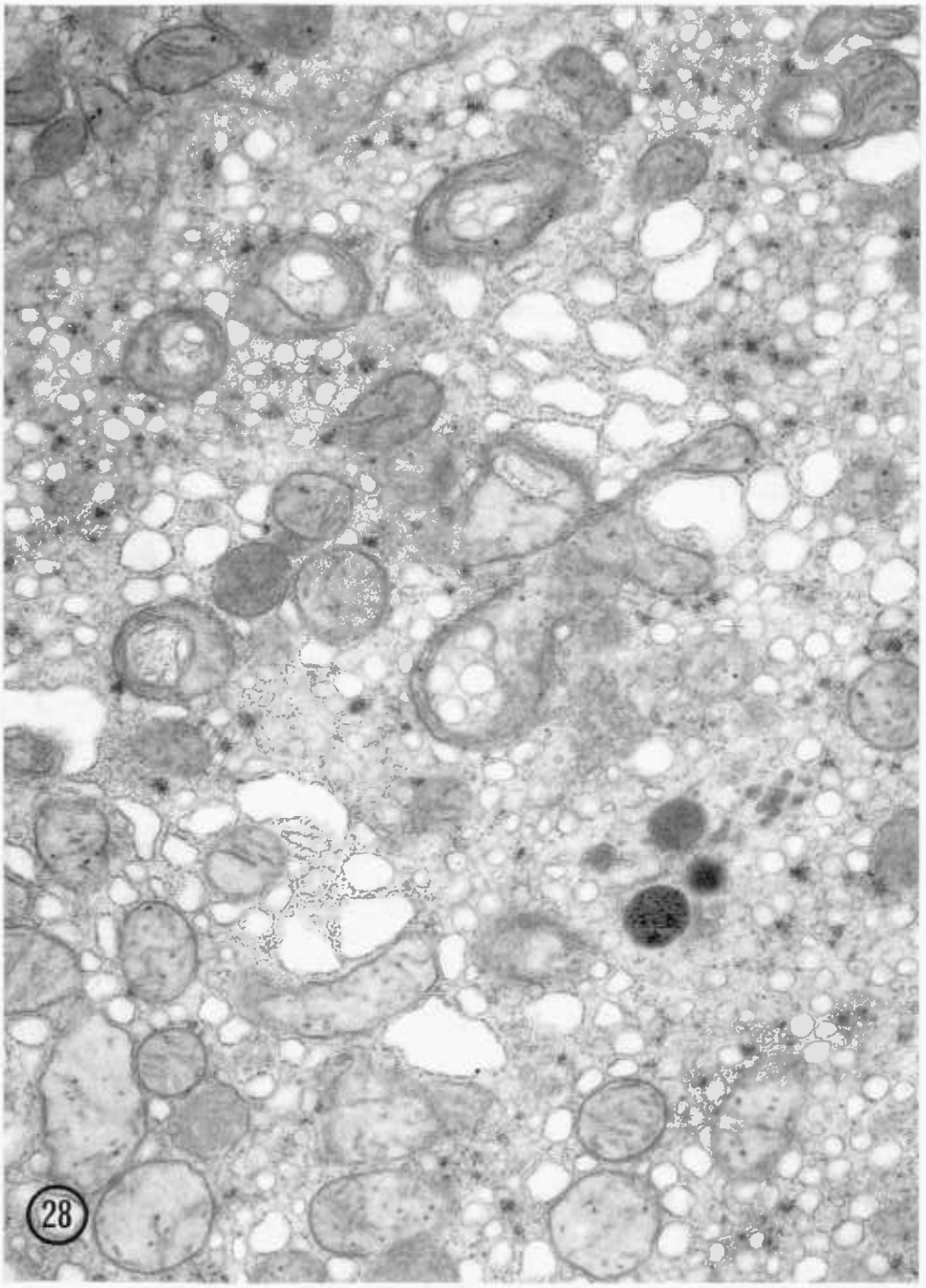
28

Figure 29 Cytoplasm of two adjoining hepatocytes with vesiculation of rough endoplasmic reticulum 4 days after aminonucleoside. Note proliferation of smooth endoplasmic reticulum (arrows) in hepatocytes.

X 17,250

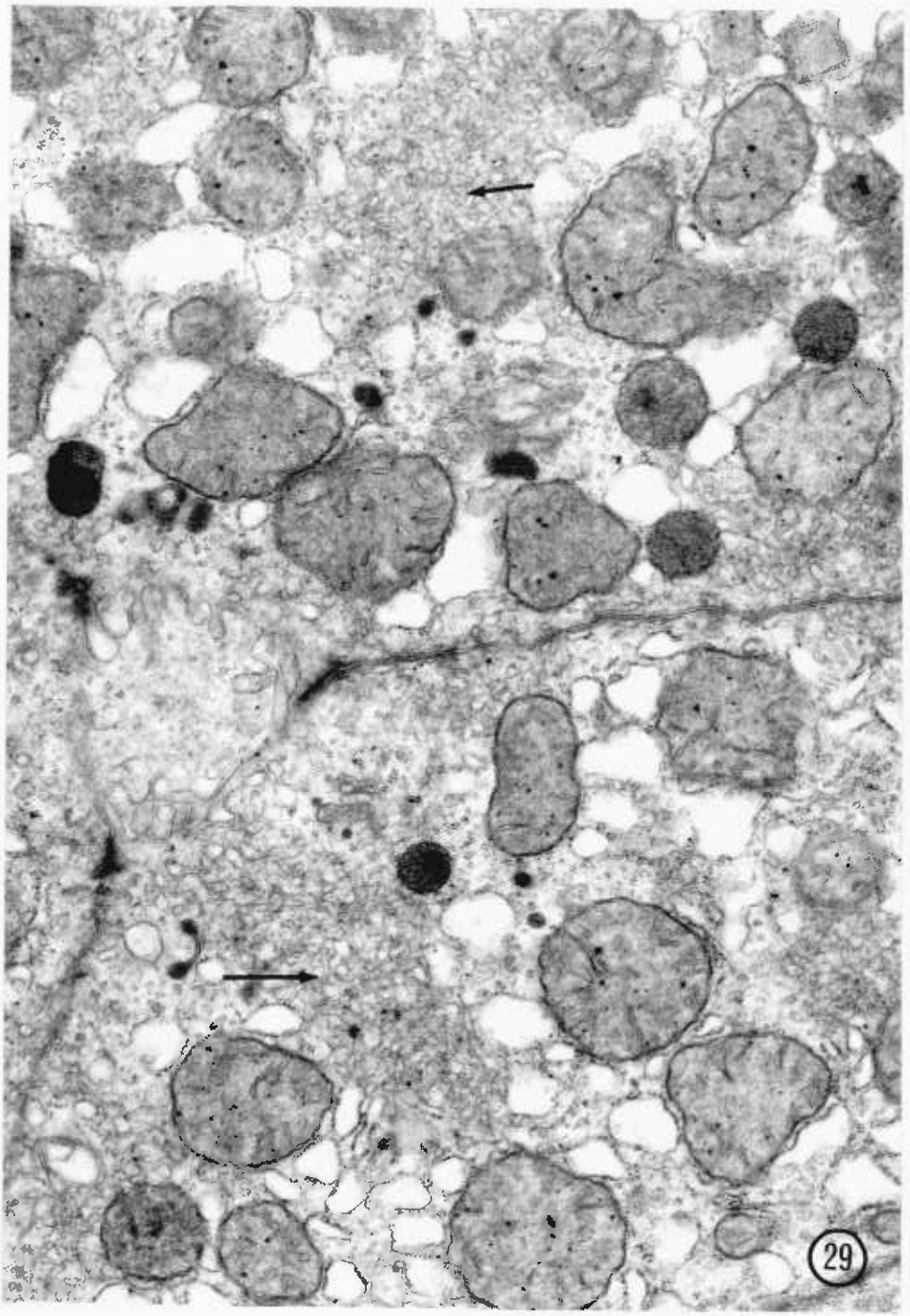
29

Figure 30 Cytoplasm of hepatocyte 4 days after aminonucleoside showing increased numbers of ribosomes in hyaloplasm.

X 18,000

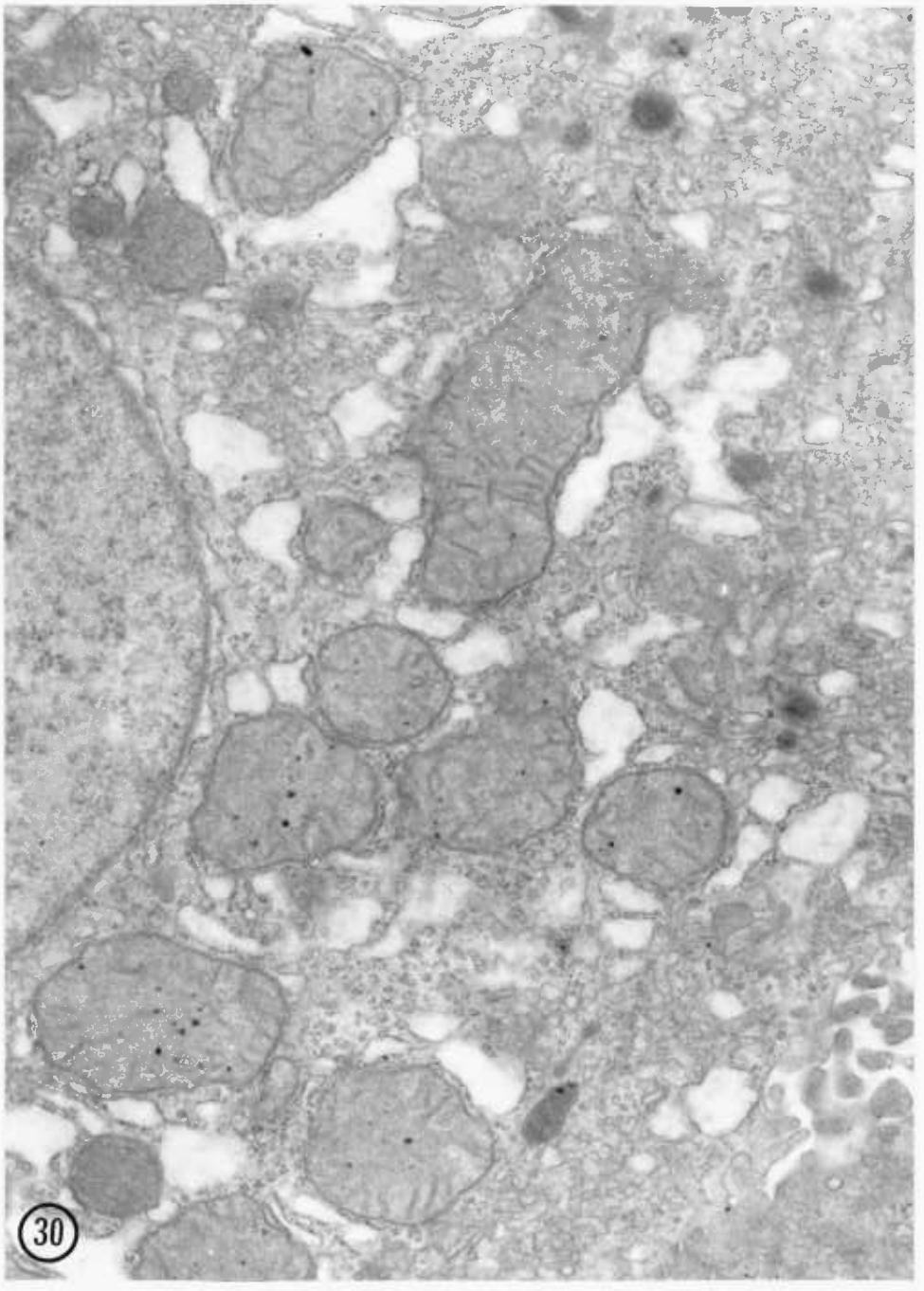
30

Figure 31 Section of a hepatocyte 7 days after aminonucleoside showing complete loss of regular cytoplasmic architecture with increased numbers of ribosomes in hyaloplasm.

X 34,000

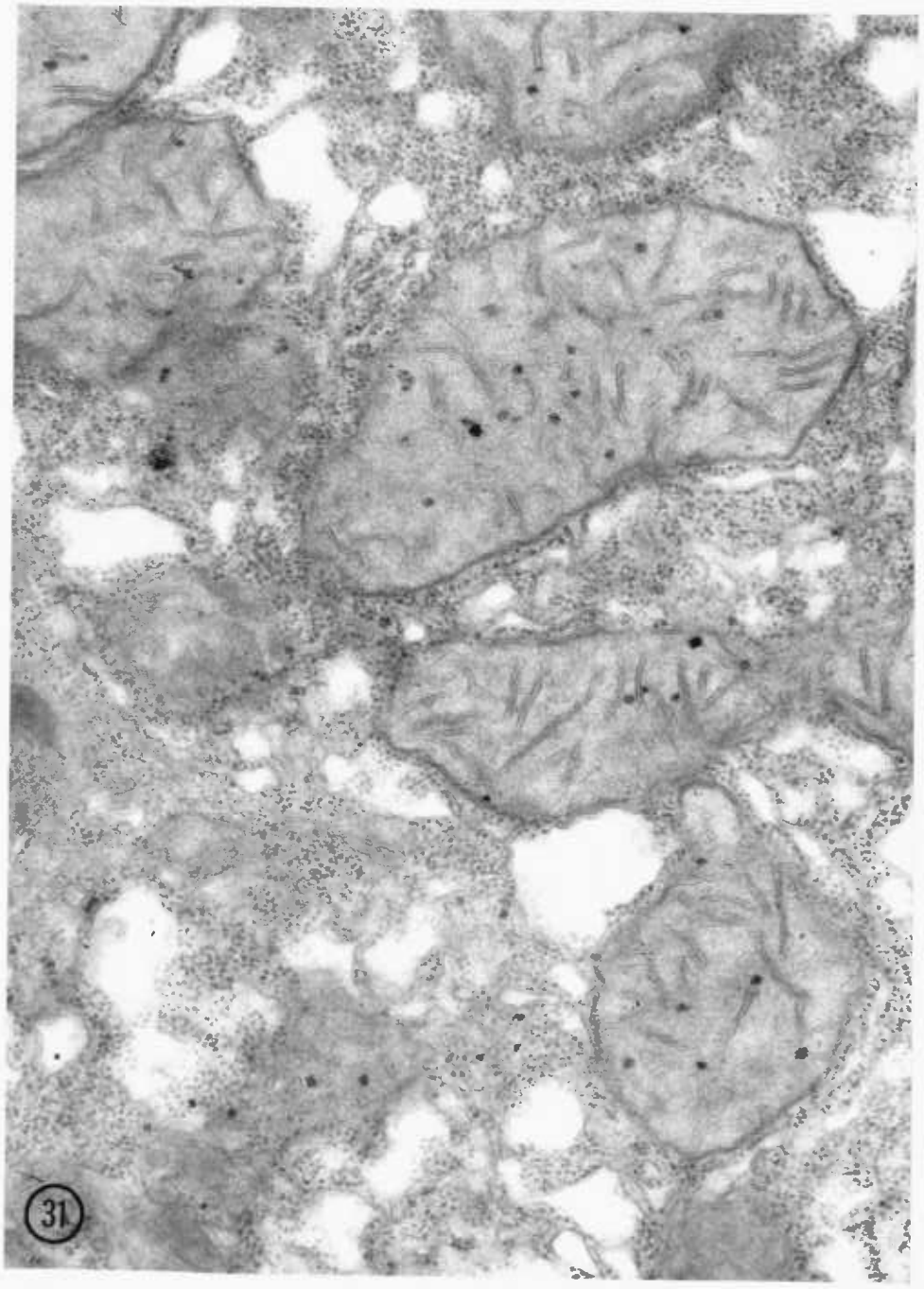
31

Figure 32 Electrophoresis of normal and aminonucleoside treated rat serum fractions.

Rat serum was first fractionated on a Sephadex G-200 column by elution with 0.1 M Tris/HCL buffer at pH8 and 1M NaCl. The serum fractions were then run on a Tris-Borate starch gel at pH8 for 24 hours at 120V (20 mA). Protein bands were stained with Amido Black.

Slots 1 - 5:

Fractions 31 - 50 control serum

Slots 2 - 6:

Fractions 31 - 50 aminonucleoside treated rat serum

Slots 3 - 7:

Fractions 50 - 80 control serum

Slots 4 - 8:

Fractions 50 - 80 aminonucleoside treated rat serum

STARCH GEL 139-67

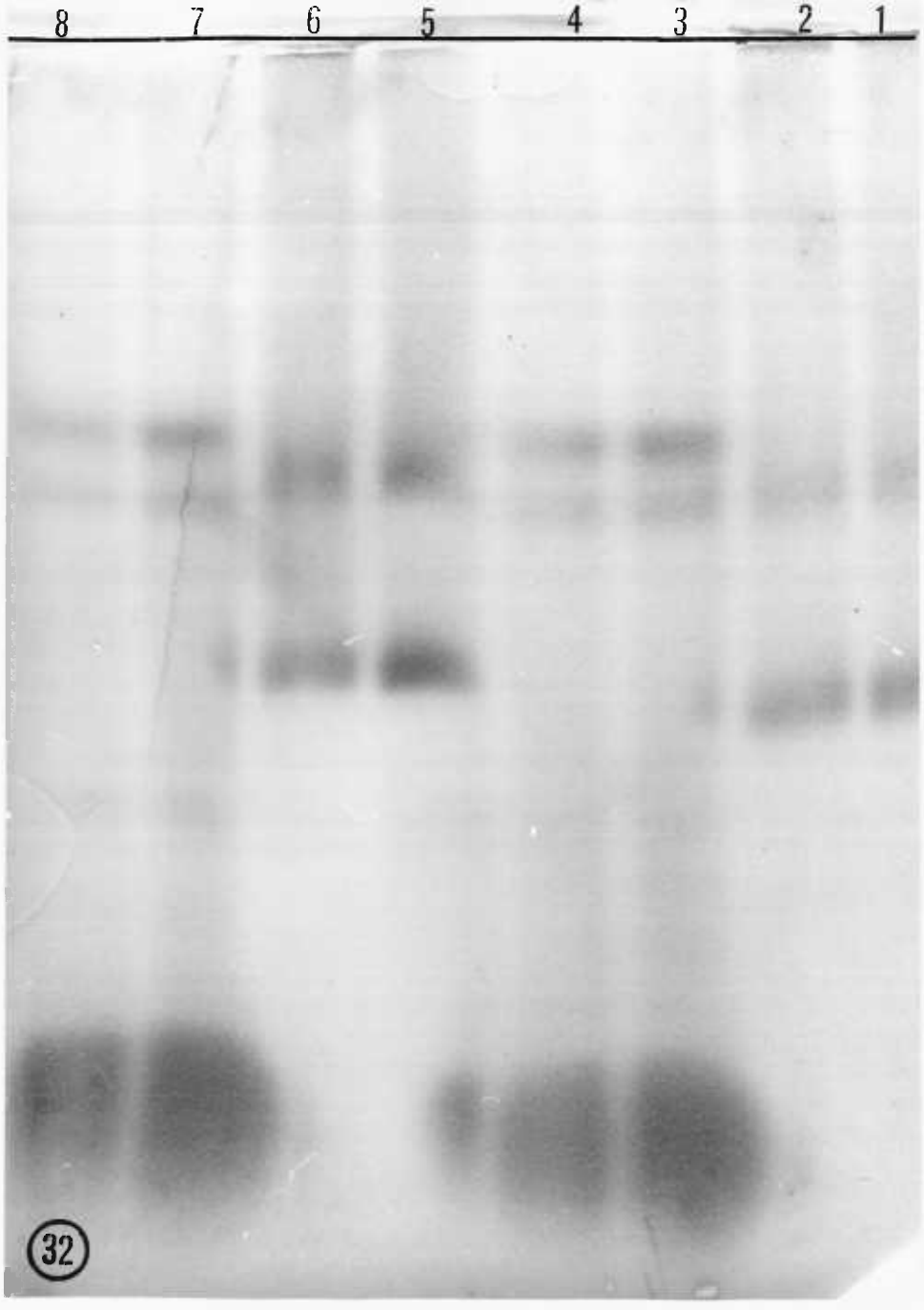

APPENDIX (PUBLISHED WORK)

1) Post Operative Blindness with Complete Recovery in a Patient with Sickle Cell Anaemia. (major contributor)

2) The Endocrine Cells of the Kidney.

3) Cardiac Myoglobin in Myoglobinuria.
This paper was written by me in collaboration with Dr. Moscarello who acted as supervisor.

4) Palaeo-Electronmicroscopy of Mummified Tissue.
This paper is the first published work on the ultrastructure of Egyptian mummified tissues.

5) Liver Ultrastructural and Biochemical Changes in the Prenephrotic Stage of Aminonucleoside Nephrosis.
This paper was written by me and published in collaboration with Dr. Moscarello. The paper reports my findings in the experimental nephrosis of rats induced by aminonucleoside and also described in this thesis.

6) The Ultrastructure of Mummified Skin Cells.

(*Reprinted from Nature, Vol.* 213, *No.* 5074, *pp.* 416–417, *January* 28, 1967)

Palaeo-electron Microscopy of Mummified Tissue

THE histology of Egyptian mummified tissues was first described by Ruffer in 1911 (refs. 1 and 2). He was able to demonstrate by light microscopy that some tissues were well preserved, when rehydrated and embedded in paraffin. Because some skin and muscle from a mummified hand of ancient Egyptian origin dating approximately 600 B.C. recently became available, it was of interest to extend this field to the ultrastructural level with electron microscopy.

The mummified material when unwrapped was dry and brittle, and easily disintegrated. Such material was rehydrated according to Ruffer's method. Small pieces of tissue 1–2 mm in length were suspended for 24 h from a platinum loop in small tubes containing Ruffer solution, consisting of a mixture of 30 ml. absolute alcohol, 50 ml. of distilled water and 20 ml. of a 5 per cent sodium carbonate solution. Following hydration, tissues tended to fragment and therefore had to be handled with great care.

After rehydration, small fragments of tissue were suspended in 0·1 molar phosphate buffer solution for 5 min, and then were fixed for 1 h in 1 per cent osmium tetroxide buffered with 0·1 molar phosphate buffer (*p*H 7·2). After dehydration in a graded series of ethanol solutions, the tissues were embedded in a mixture of 'Epon' and 'Araldite' (modification of Luft's method[3]). Sections were cut with a glass knife on a microtome and picked up on uncoated grids, stained with lead hydroxide according to the method of Karnovsky[4], and examined in an electron microscope. Micrographs were taken at initial magnification of 1,400–32,000 and were enlarged photographically as required. Thin sections of plastic embedded tissue were stained with toluidine blue according to the method of Trump, Smuckler and Benditt[5].

The distinct histological features of skin were seen in the embedded sections, stained with toluidine blue. Nucleated cells were most numerous at the epidermal and dermal junctions.

Fig. 1 is a low power micrograph of mummified skin at the epidermal and dermal junctions, with numerous cells mainly in the dermal area. The cells are markedly shrunk with large perinuclear and pericellular spaces. A number of cells with intracytoplasmic vacuoles can also be seen. Fig. 2 is a high power micrograph of a dermal cell with an intact nuclear and cytoplasmic membrane. The nuclear membrane contains some nuclear pores and in an occasional area is double. A membranous organelle,

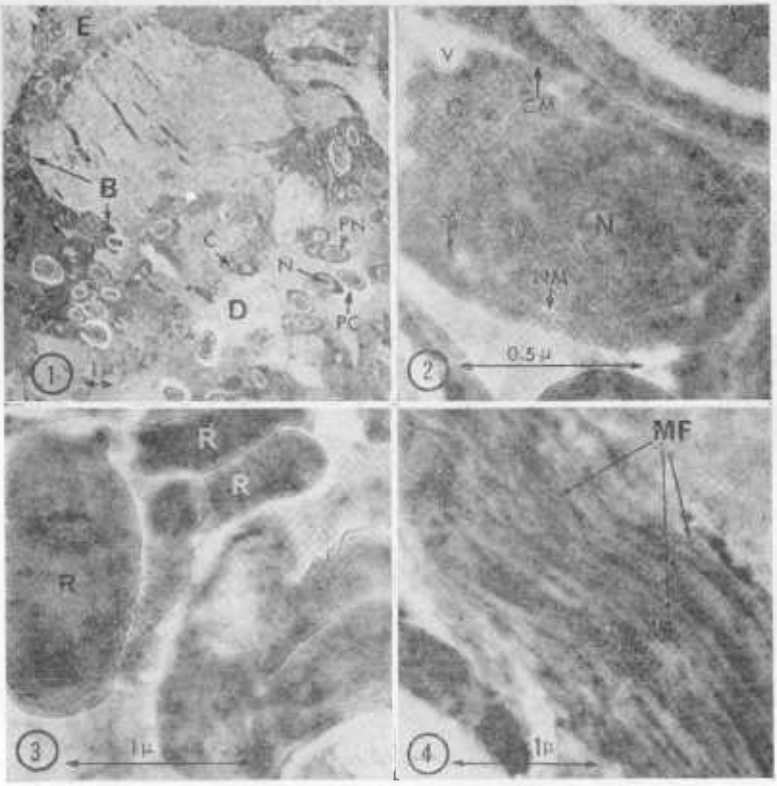

Fig. 1. Low power micrograph of mummified skin. *B*, Basal epidermal cell layer; *D*, dermis; *E*, epidermis; *N*, cell nucleus; *C*, cytoplasm; *PC*, pericellular space; *PN*, perinuclear space. (Lead hydroxide "stain".)

Fig. 2. Mummified dermal cell. *CM*, Cell membrane; *NM*, nuclear membrane; *M*, cytoplasmic organelle: *V*, vacuole. (Lead hydroxide "stain".)

Fig. 3. Three non-nucleated cells, possibly erythrocytes (*R*). (Lead hydroxide "stain".)

Fig. 4. Bundle of muscle fibres. *MF*, muscle fibres.

possibly a mitcohondrion, is also seen in the cytoplasm, which in addition contains a number of vacuoles of unknown origin. Two of the surrounding cells have pronounced perinuclear spaces. Fig. 3 shows three distinct intact cells which contain homogenous cytoplasm with occasional granules and no nuclei. These cells were surrounded by nucleated cells with perinuclear spaces, and possibly represent red blood cells in a small dermal vessel. Fig. 4 is a section showing a bundle of voluntary muscle fibres from the hand.

It is a credit to the ancient Egyptians that their method of mummification has so well preserved their dead, even at the cellular level. The marked shrinkage of cells observed in the processed tissue may have resulted, in part, from the soaking for 70 days in a brine bath which was commonly used in the mummification process in 600 B.C. (ref. 5). The perinuclear and cytoplasmic spaces are almost certainly artefacts following the crude rehydration process.

There has recently been an increased interest in the field of palaeopathology[6], and with the introduction of electron microscopy the examination of mummified material can be extended to the ultrastructural level. The pathology of mummified and even fossilized material may thus be compared with recent pathological specimens, and in the process infectious agents, such as viruses, bacteria and parasites, may be demonstrated.

I thank Miss Needler, of the Royal Ontario Museum, Toronto, who supplied the mummified material, Professor A. C. Ritchie for his assistance in the preparation of this manuscript, and Dr. Miyai, Mr. G. Doornewaard, Mr. H. Layne and Mrs. J. Cetkovski for their technical assistance.

PETER K. LEWIN*

Department of Pathology,
University of Toronto,
Banting Institute,
Toronto, Ontario.

Received December 16, 1966.

* Fellow of the Medical Research Council of Canada.

[1] Ruffer, M. A., *Histological Studies on Egyptian Mummies* (*Mémoires présentés a l'institut Egyptien*). *Le Caire*, **6**, Fasc. 3 (Mars, 1911).

[2] Ruffer, M. A., *Studies in the Paleopathology of Egypt* (University of Chicago Press, 1921).

[3] Luft, J. H., *J. Biophys. Biochem. Cytol.*, **9**, 409 (1961).

[4] Karnovsky, M. J., *J. Biophys. Biochem. Cytol.*, **11**, 729 (1961).

[5] Trump, B. F., Smuckler, E. A., and Benditt, E. P. A., *J. Ultrastruct. Res.*, **5**, 343 (1961).

[6] Elliot Smith, G., and Dawson, W. R., *Egyptian Mummies* (George Allen and Unwin, Ltd., London, 1924).

[7] Jarcho, Saul (ed.), *Human Paleopathology: Proc. Symp. Human Paleopathology* (Yale Univ. Press, New Haven and London, 1966).

Printed in Great Britain by Fisher, Knight & Co., Ltd., St. Albans.

Reprinted from EXPERIMENTAL AND MOLECULAR PATHOLOGY, Volume 8, No. 1, February, 1968

EXPERIMENTAL AND MOLECULAR PATHOLOGY **8**, 21–33 (1968)

Liver Ultrastructural and Biochemical Changes in the Prenephrotic Stage of Aminonucleoside Nephrosis[1]

P. K. LEWIN,[2] AND M. A. MOSCARELLO

Banting Institute, University of Toronto, 100 College Street, Toronto, Ontario, Canada; and Research Institute, The Hospital for Sick Children, 555 University Avenue, Toronto, Ontario, Canada

Received September 25, 1967

Our interest in hepatic function during experimental nephrosis was stimulated by the recent demonstration in our laboratory that plasma glycoprotein biosynthesis was enhanced in rats in which nephrosis had been induced by aminonucleoside (Moscarello *et al.*, 1966, 1967). The increase in glycoprotein biosynthesis was demonstrated before the onset of proteinuria. In fact, an increase in specific activity (cpm/mg protein) was observed as early as 24 hours after a single intravenous injection of aminonucleoside and 5 days before the onset of proteinuria.

Since it has been well established (Sarcione, 1962 1963) that plasma glycoproteins are synthesized in the liver and subsequently released to the plasma, the target of our investigations became the liver. We decided to study the liver at the ultrastructual level, at the same time combining this with biosynthetic studies on plasma glycoproteins, as had been similarly reported earlier (Moscarello *et al.*, 1966, 1967). This time, however, we focused our attention on the first 24 hours after a single intravenous injection of aminonucleoside.

Since no related ultrastructural hepatic changes have been reported in the nephrotic syndrome, we decided to determine by light and electron microscopy whether or not the functional hepatic changes reported earlier were reflected by structural alterations. In addition, we hoped to gain some insight into the sequence of events; i.e., if an ultrastructural change was found, did this precede or follow the functional alteration as determined by plasma glycoprotein biosynthesis.

MATERIALS AND METHODS

Ultrastructural Studies

Animals used were Wister male adult albino rats weighing approximately 300–350 gm. Four groups of animals were tested, each group containing four rats. One rat of each group was used as a control.

[1] Supported by a grant from the Medical Research Council of Canada (MA-1221). Presented in part at the Annual Meeting of the Canadian Federation of Biological Societies, Montreal, Quebec, July, 1967.

[2] Fellow, Medical Research Council of Canada.

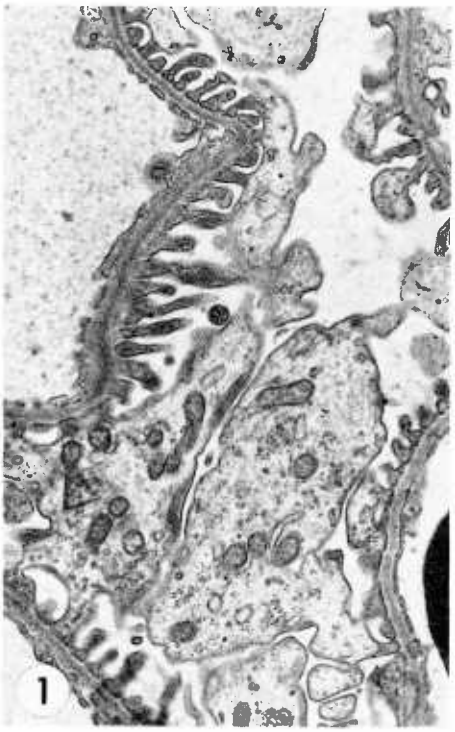
1

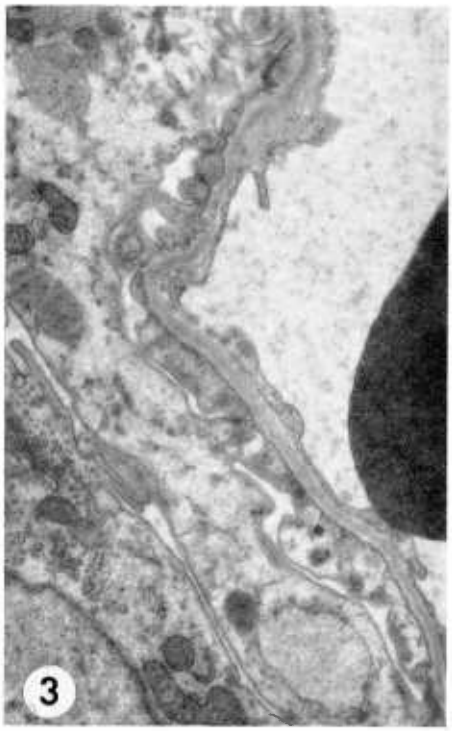
3

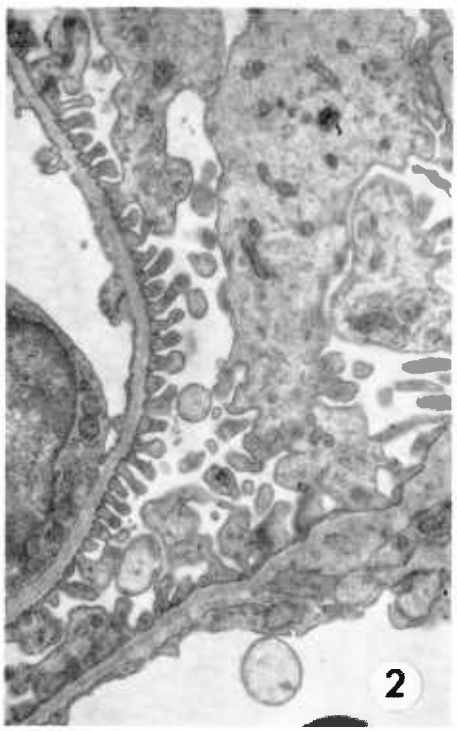
2

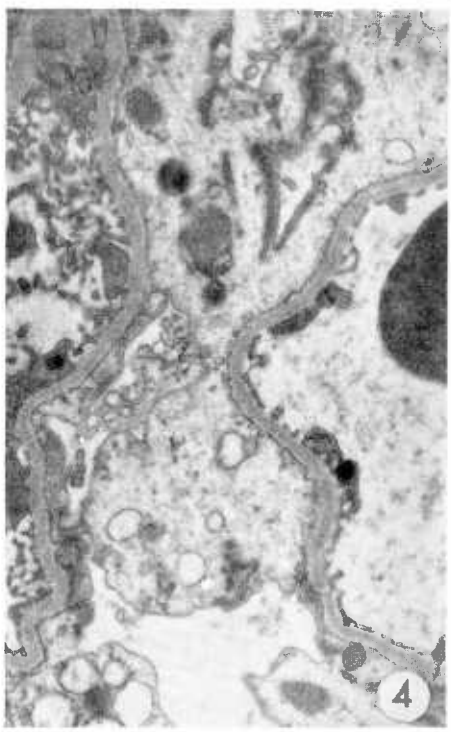
4

All the treated animals were given a single dose of 1.5 cc of a 1% aminonucleoside solution in 0.45% saline into the jugular vein. Rats of groups 1, 2, and 3 were decapitated 1, 4, and 7 days after receiving the drug. Groups 1 and 2 were starved for 14 hours prior to sacrifice; the other groups were fed *ad libitum*.

Animals from group 4 were sacrificed 1, 2, and 6 hours following intravenous aminonucleoside[3] injection.

Histologic techniques. Sections of livers and cortical areas of renal tissue were examined by light and electron microscopy. Tissues for light microscopy were fixed in Stieve's fluid (76 ml saturated mercuric chloride, 20 ml of 10% formalin, and 4 ml of glacial acetic acid), embedded in paraffin, and stained with hematoxylin-eosin and periodic acid-Schiff reagent (with and without diastase).

For electron microscopy, small fragments of liver and kidney tissue were fixed for one hour at 0°C in 1% osmium tetroxide buffered with 0.1 *M* phosphate buffer (pH 7.2). After dehydration in a graded series of ethanol solutions, the tissue was embedded in epon according to the method of Luft (1961) or in an epon-araldite mixture.

Sections were cut with glass or diamond knives on Porter-Blum or LKB microtomes, picked up on uncoated grids, stained with lead hydroxide by the method of Karnovsky (1961), and examined with an RCA EMU 3-G or JEM 6-C electron microscope.

Thin (0.5–1.0-μ) sections of plastic-embedded tissue were stained with toluidine blue by the method of Trump *et al.* (1961).

Biochemical Studies

The biosynthesis of plasma glycoproteins was examined, using glucosamine-1-C^{14} as outlined in our earlier reports (Moscarello *et al.*, 1966, 1967). Briefly, this procedure consists of the intravenous injection of 5 μc of glucosamine-1-C^{14} via the jugular vein. Blood samples (0.5 ml) were withdrawn from the vein at the appropriate intervals, and added to 0.5 ml cold 0.9% saline. The protein was precipitated with an equal volume of 20% trichloracetic acid. The precipitate was extracted with a mixture of chloroform: methanol: ether (2:1:1). The pellet was dissolved in 0.5 ml of 0.5 *N* sodium hydroxide. One portion (100 μl) was placed onto planchettes and counted in a Nuclear Chicago, gas-flow, low-background counter. A second portion

[3] Aminonucleoside: The aminonucleoside of puromycin 6-dimethylamino-9-(3′amino-2 deoxy-β-D-ribofuranosyl)-purine was obtained from the Lederle Medical Research Section, American Cyanamid Company.

FIG. 1. Portion of a normal glomerulus showing an epithelial cell with cytoplasmic extensions (foot processes) attached to basement membrane. A thin layer of endothelial cytoplasm with a number of pores, lines the vascular surface of the basement membrane. ×5,000.

FIG. 2. Twenty-four hours following aminonucleoside, no gross structural abnormalities are seen in glomerulus. ×6,000.

FIG. 3. Four days after aminonucleoside, extension and thickening of epithelial cell foot processes along basement membrane is observed. ×8,000.

FIG. 4. Seven days after aminonucleoside, epithelial cell of glomerulus contains numerous cytoplasmic inclusions and is intimately attached to basement membrane with no intervening foot processes. Vascular endothelial cytoplasmic hyperplasia is also observed. ×6,000.

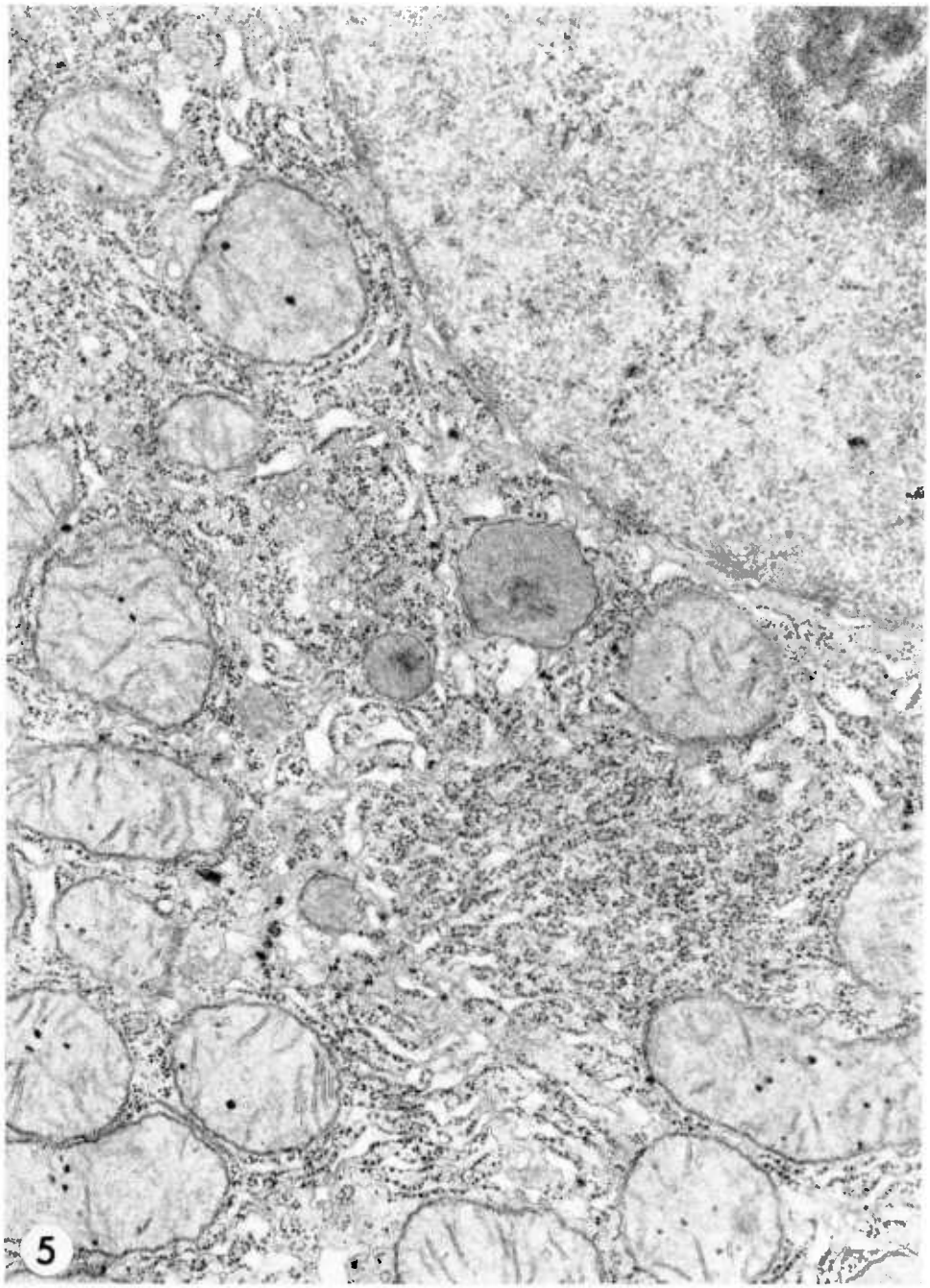

FIG. 5. Normal starved rat hepatocyte showing cytoplasmic architecture with regular arrays of rough endoplasmic reticulum. Part of nucleus and nucleolus is also seen. ×24,000.

(100 μl) was used for the determination of protein concentration by the method of Lowry *et al.* (1958). The specific activity was expressed as cpm/mg protein.

RESULTS

Light Microscopy

Kidney. The expected changes (glomerular hyperplasia and tubular vacuolation) as reported by others (Harkin and Recant, 1958, 1960) became manifest 4 days after administration of aminonucleoside. After 1 week these changes had not only become pronounced, but also thickening of the glomerular basement membrane was now clearly evident. Pyknosis of tubular epithelial cells was evident at this later stage.

Liver. In paraffin-embedded sections abnormalities could not be detected, but in the epon-embedded sections ratios of light to dark hepatocytes were increased over those of the controls. This pattern was observed as early as 24 hours following aminonucleoside injection and was more pronounced in the centrilobular and midzonal regions than in the peripheries of hepatic lobules.

Electron Microscopy

Kidney. In our material, no unequivocal ultrastructural changes were detected until 4 days had elapsed after injection of aminonucleoside. Sections from a treated animal killed 24 hours after aminonucleoside and from a normal control glomerulus are shown in Figs. 1 and 2. We have not excluded the possibility that minor degrees of swelling of podocytes and thickening of basement membrane sometimes present may be significant. Measurements would help clarify this point but were not considered pertinent to our general thesis.

Figure 3 shows the glomerulus 4 days after the rat had been given aminonucleoside. The glomerular epithelial cell is prominent and contains numerous cytoplasmic inclusions. The foot processes are thickened and in many places fused together. The central pars densa of the basement membrane is not as distinct as in the normal, and many of the endothelial pores have disappeared.

By 7 days, glomerular lesions were advanced and comparable to those previously reported by others (Harkin and Recant, 1958, 1960). Figure 4 shows an example of such changes in which the epithelial cell is intimately attached to the basement membrane with no intervening podocytes. The endothelial cell cytoplasm lining the basement membrane is hyperplastic at this stage.

Liver. Treated rats from groups 1 and 2, which had been starved prior to being killed, showed similar but more prominent changes than those rats of group 3 that had been fed *ad libitum* up to the time of sacrifice. Electron micrographs of liver sections from groups 1 and 2 are, therefore, presented.

The earliest changes from the normal (Fig. 5) in the liver were noticed 6 hours after intravenous administration of aminonucleoside (Fig. 6). These changes consisted of a loss of regular arrays of endoplasmic reticulum in the cytoplasm associated with reticular vesiculation.

Prominent cisternal dilatation of the endoplasmic reticulum of hepatocytes at the ultrastructural level was present 24 hours after intravenous aminonucleoside and was often associated with small vesicular and tubular cytoplasmic structures with

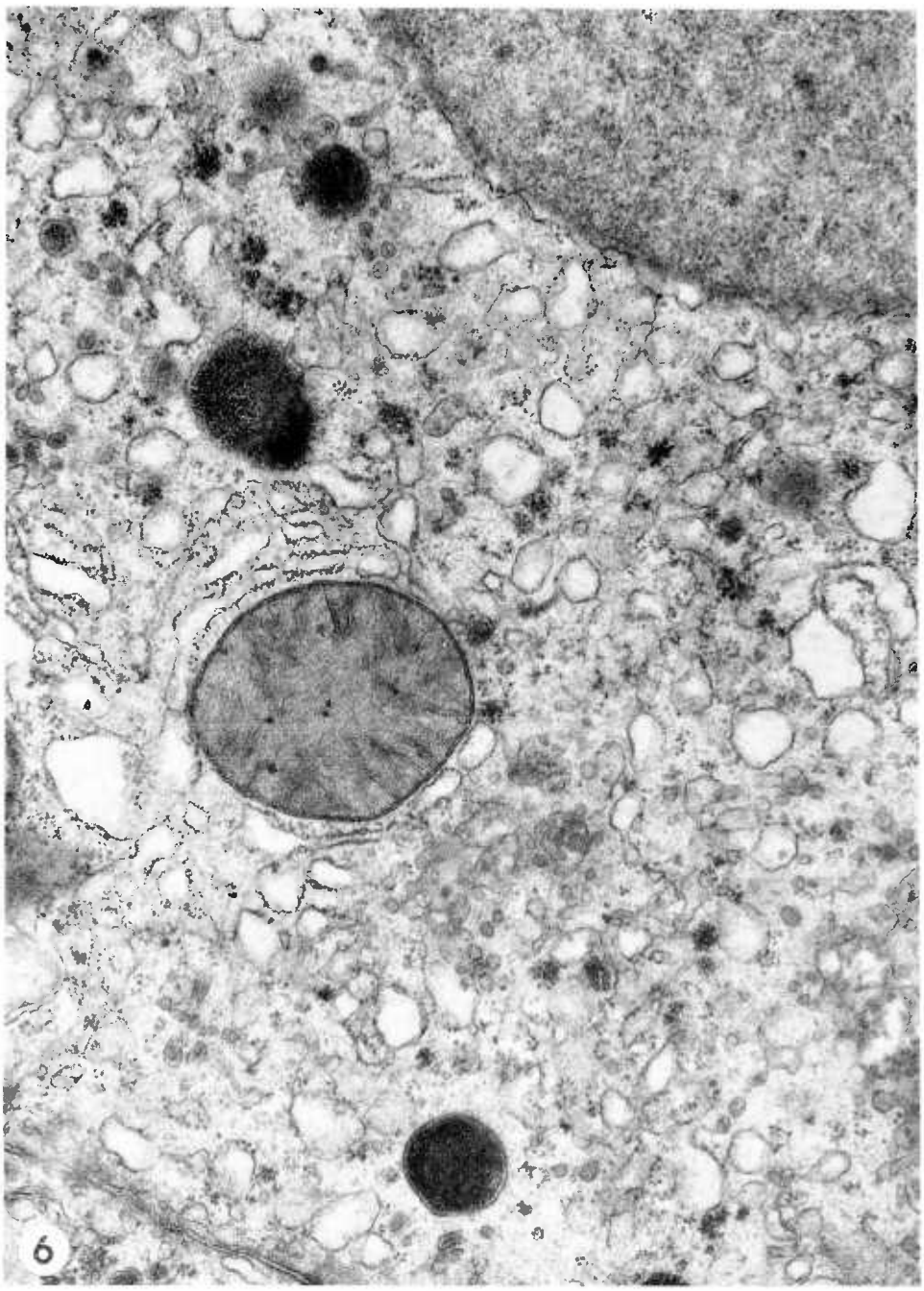

FIG. 6. Cytoplasm of a hepatocyte 6 hours after aminonucleoside showing loss of regular cytoplasmic architecture with vesiculation of both smooth and rough endoplasmic reticulum. ×24,500.

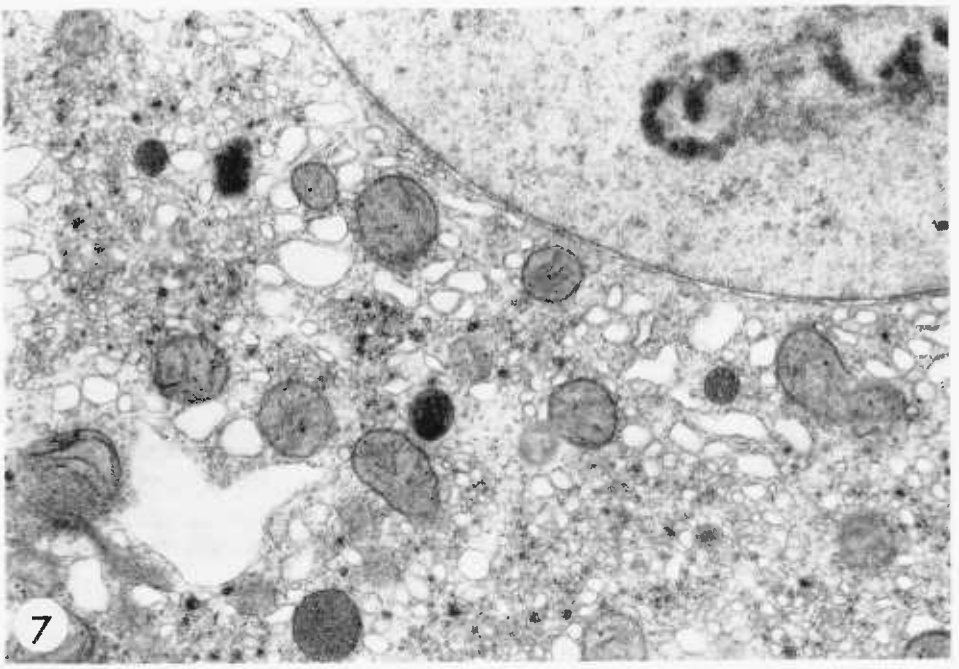

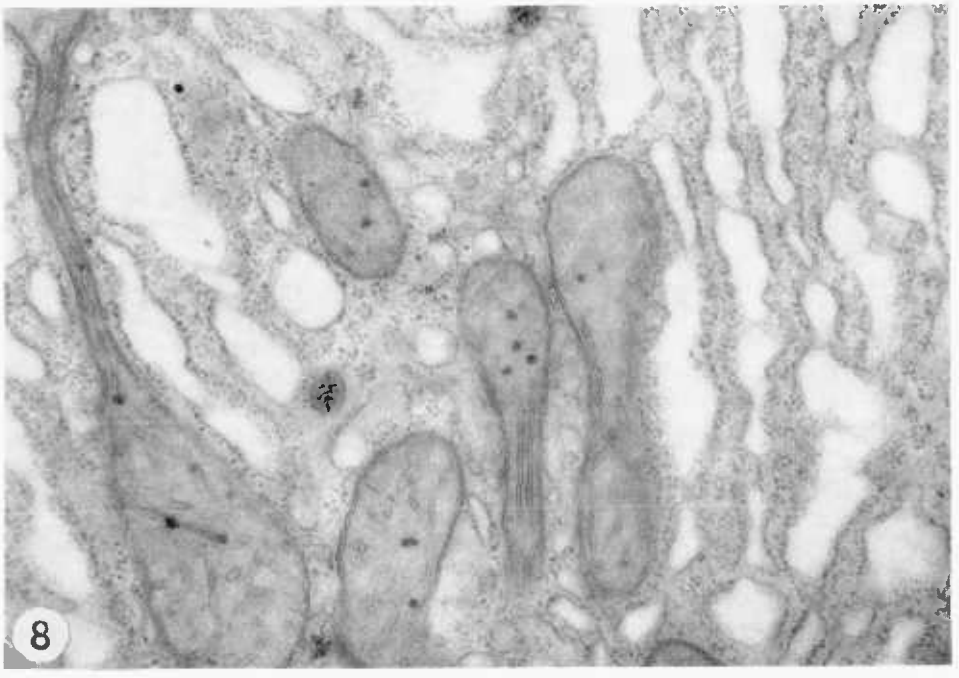

FIG. 7. Hepatocyte 24 hours after aminonucleoside showing gross dilatation of endoplasmic reticulum associated with small vesicular and tubular cytoplasmic structures. Separation of fibrillar and granular component of nucleolus is also observed. ×8,000.

FIG. 8. Cytoplasmic component of hepatocyte 24 hours after aminonucleoside to show dilatation of rough endoplasmic reticulum associated with a number of abnormally shaped mitochondria. ×26,000.

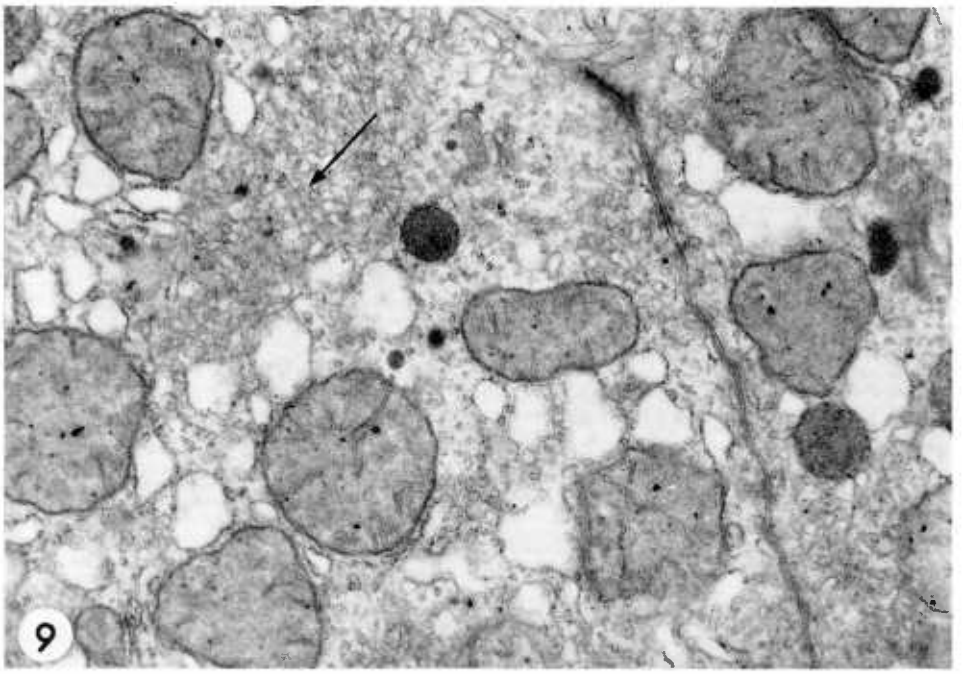

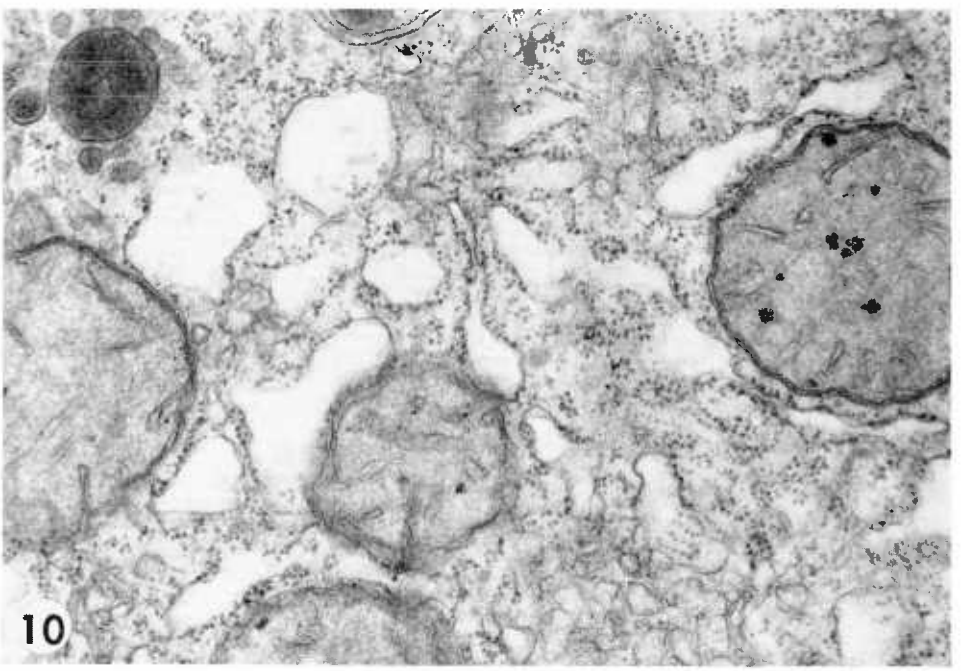

FIG. 9. Cytoplasm of two adjoining hepatocytes with vesiculation of rough endoplasmic reticulum 4 days after aminonucleoside is shown. Note an area of smooth endoplasmic reticulum(arrow) in one of the hepatocytes. ×13,000.

FIG. 10. Cytoplasm of hepatocyte 4 days after aminonucleoside showing increased numbers of ribosomes in hyaloplasm. ×30,000.

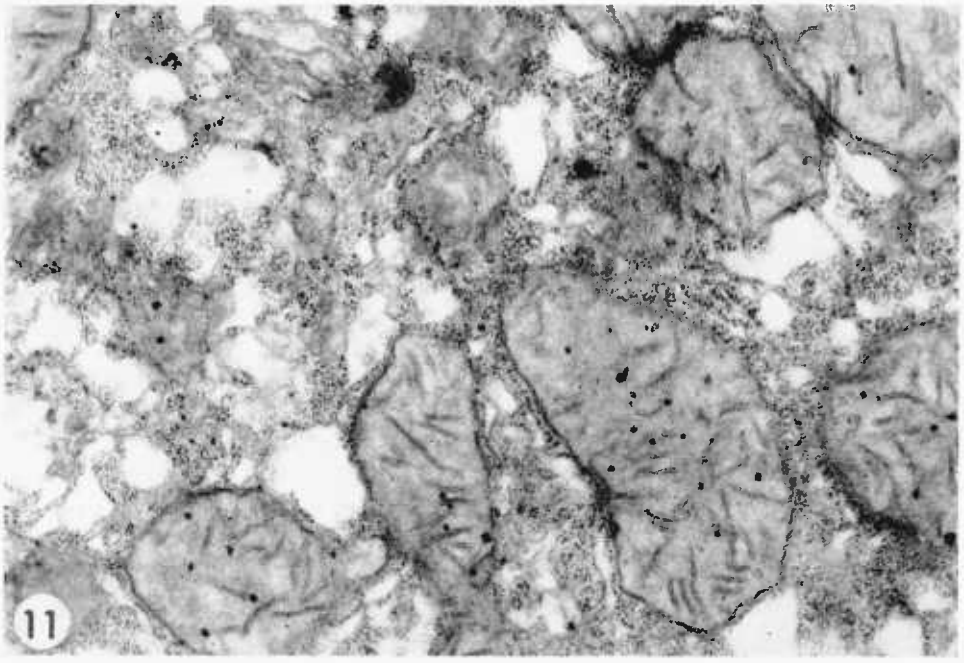

FIG. 11. Section of a hepatocyte 7 days after aminonucleoside showing complete loss of regular cytoplasmic architecture with increased numbers of ribosomes in hyaloplasm. ×22,000.

medium density (Fig. 7). The changes were noted particularly around the central vein and midzones of liver lobules. In liver sections chosen at random, one hepatocyte out of ten was involved in such a process (350 cells counted). Ribosomes were attached to the dilated endoplasmic vesicles and free ribosomes were often more numerous than normal throughout the hyaloplasm. In normal controls, similar changes were occasionally seen (about one hepatocyte in 50, with 400 cells being counted). Mitochondrial structural deformities were seen 24 hours following aminonucleoside, but were not constant (Fig. 8). Neither was an increase or decrease in the numbers of mitochondria observed. Four days following aminonucleoside injection, most hepatocytes showed vesiculation of the rough endoplasmic reticulum with increased numbers of free ribosomes which now sometimes formed cochleosome patterns (Steiner and Baglio, 1963) as seen in Figs. 9 and 10 (one out of three cells, 400 counted). Increased numbers of lysosomes and microbodies were also observed at this stage.

During the nephrotic stage, (7 days after aminonucleoside) changes in hepatocytes were similar to those seen prior to proteinuria, except that cytoplasmic disorganization of hepatocytes was widespread and was associated with increased numbers of ribosomes and polyribosomes in the hyaloplasm (Fig. 11).

Incorporation of Glucosamine-1-C^{14} into Plasma Glycoproteins

Because ultrastructural changes were observed in the liver as early as 6 hours after the injection of aminonucleoside, we studied the incorporation of glucosamine-1-C^{14} at $6\frac{1}{2}$, $17\frac{1}{2}$, and 24 hours following administration of the drug. The results are

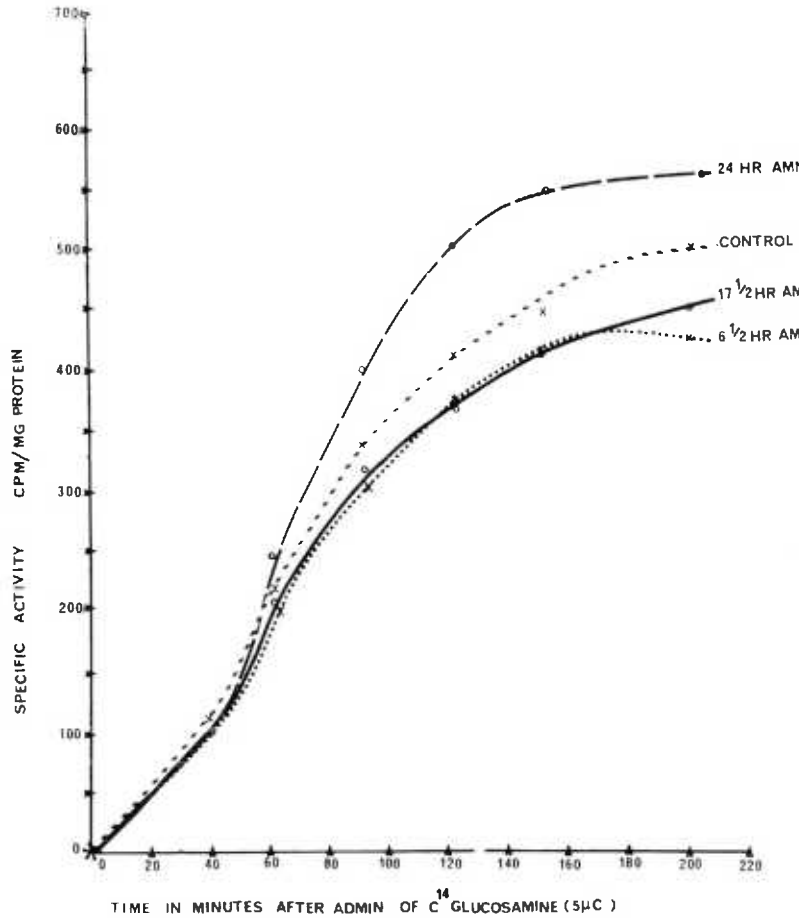

FIG. 12. Incorporation of glucosamine-1-C^{14} into rat plasma glycoproteins 6½, 17½, and 24 hours following intravenous administration of aminonucleoside.

presented in Fig. 12. It can be seen that a small but significant depression of the specific activity was observed at 6½ and 17½ hours. However, a significant increase of specific activity was observed 24 hours after the injection of aminonucleoside. The change observed at 24 hours was similar to that reported earlier (Mascarello *et al.*, 1966, 1967).

DISCUSSION

The ultrastructural changes in the kidneys described above conform to those previously reported by Harkin and Recant (1958, 1960) and Farquhar (1961), even though in both latter experiments subcutaneous injections of aminonucleoside were given daily, whereas we gave only a single intravenous dose.

No comparative study, however, has been made on the ultrastructural changes observed in the liver during experimental nephrosis produced by any means. In particular, no study was found in which emphasis was placed on the ultrastructural changes in the liver prior to the onset of proteinuria.

Hepatocytic changes were observed as early as 6 hours, following intravenously administered aminonucleoside, and became well established by 24 hours. The ultrastructural changes of hepatocytes essentially consisted of loss of regular cytoplasmic architecture associated with dilation of the rough endoplasmic reticulum and an increase in the numbers of free and attached ribosomes. These hepatocytic changes following aminonucleoside occurred at least 24 hours prior to the occurrence of any ultrastructural renal glomerular abnormalities, and 5 days prior to the onset of proteinuria.

Mitochondrial structural deformities were also observed associated with vesiculation of the endoplasmic reticulum, but were not a consistent finding.

It is well known that protein synthesis is associated with ribosome and polyribosome aggregates (Warner *et al.*, 1962) and that glycoprotein conjugation occurs on the endoplasmic reticulum (Lawford and Schachter, 1966). Furthermore, the hepatic synthesis of serum glycoproteins has been definitely established by Sarcione (1962, 1963) who used a liver perfusion technique.

In our experiments, the specific activity of plasma glycoproteins was less than observed for the control animal, at a time (6½ hours) when ultrastructural changes were definitely established. The initial response of the liver appeared to have been a slight depression of plasma-glycoprotein synthesis. A definite increase in specific activity was not observed until 24 hours after the injection of aminonucleoside, at a time when the ultrastructural changes were becoming progressively more pronounced.

The reason for the slight depression in glycoprotein synthesis is not understood. It may be that at 6 hours the concentration of aminonucleoside is relatively high in the hepatocyte resulting in disaggregation of polysomes, with a subsequent decrease in incorporation of glucosamine-C^{14}. By 24 hours the concentration of the drug may be much less, resulting in aggregation of ribosomes into polysomes with a concomitant increase in glucosamine-C^{14} incorporation.

A reversible effect of cycloheximide, an inhibitor of protein synthesis, has been reported by Godchaux *et al.* (1967). At low concentration cycloheximide promotes aggregation of ribosomes, while at higher concentrations, disaggregation. We are currently investigating the effect of aminonucleoside on polysome patterns in sucrose-density gradients.

The exact mechanism of the stimulation of glycoprotein synthesis in rats treated with aminonucleoside and the possible relationship of this change to the nephrotic process are still unknown.

It has been clearly shown that aminonucleoside acts as an inhibitor of ribosomal RNA-synthesis and cell division of hela cells (Studzinski and Ellem, 1966). Such an action may occur selectively in the kidney following aminonucleoside excretion with subsequent absorption and incorporation into renal cells. Interference with nucleic acid synthesis may occur because of the action of aminonucleoside as an adenine or adenosine analogue and the subsequent depression of protein formation by renal cells.

This depression of renal protein synthesis may include the suppression of a postulated inhibitor of glycoprotein formation. Interference with such a feedback mechanism may permit the rate of hepatic glycoprotein synthesis to rise. With elevated serum levels of glycoproteins their renal loading is increased, with functional im-

pairment of the glomerular basement membrane, perhaps as a direct result. In any case, such an effect would probably be accentuated by altered renal cell metabolism due to aminonucleoside as demonstrated for sodium transport by Yoshida *et al.* (1961). A critical level is reached when tubular cells can no longer reabsorb the increased protein load with resultant proteinuria. Bartlett *et al.* (1963) could not demonstrate such mechanisms using labeled aminonucleoside, and measuring specific activities of renal cell RNA and DNA fractions (Bartlett and Shelata, 1959; Bartlett, 1961), but he did demonstrate that aminonucleoside inhibited renal mitochondrial ATPase activity (Bartlett *et al.*, 1963). However, no studies have been reported to determine whether labeled nucleoside incorporation into renal RNA or DNA is increased or decreased following aminonucleoside.

On the other hand, aminonucleoside may act directly on hepatic cells with stimulation of glycoprotein synthesis. (Nucleolar changes seen in some cells [Fig. 7] may be due to a direct action of aminonucleoside.) The high levels of serum glycoproteins following increased hepatic activity may overload the renal protein-resorptive mechanisms with eventual renal cell failure. However, there is no experimental evidence at present for such direct action (Rabinovitz and Fisher, 1962; Nathans and Neidle, 1963; Farnham, 1965).

In conclusion, it seems possible from the experimental evidence that an intimate relationship may exist between renal and hepatic function in relation to glycoprotein synthesis and, if this mechanism is disturbed, nephrosis may occur as a terminal event in glycoprotein metabolic disorders.

SUMMARY

Recent work has shown that serum glycoprotein biosynthesis in the rat is significantly increased prior to proteinuria in experimental nephrosis following the administration of aminonucleoside. In an attempt to correlate the biochemical changes, with possible morphological changes, ultrastructural examination of the liver and kidneys of rats in the prenephrotic stage was undertaken.

Hepatic cell changes were found as early as 6 hours following a single intravenous injection of aminonucleoside, and at least 48 hours prior to any ultrastructural renal changes, and 5 days prior to proteinuria. Incorporation of C^{14}-glucosamine into plasma glycoproteins was depressed during the first 18 hours after aminonucleoside administration. By 24 hours, an increase of specific activity of plasma glycoproteins was observed.

ACKNOWLEDGMENT

The authors thank Dr. W. S. Hartroft and Professor A. C. Ritchie for their interest and suggestions. We also wish to express grateful appreciation for technical assistance freely given by Dr. A. M. Jézéquel, Dr. M. J. Phillips, Miss M. Swenson and Mrs. J. Cetkovski.

REFERENCES

Bartlett, P. (1961). Mechanism of aminonucleoside-induced nephrosis in the rat. *Proc. Soc. Exptl. Biol. Med.* **108**, 611–615.

Bartlett, P., Keegan, J., and Schaffer, H. (1963). Mechanism of aminonucleoside-induced nephrosis in the rat. *Proc. Soc. Exptl. Biol. Med.* **112**, 96–101.

Bartlett, P., and Shelata, S. (1959). Mechanism of amino-nucleoside-induced nephrosis in the rat. *Proc. Soc. Exptl. Biol. Med.* **102**,, 499–503.

Farnham, A. E. (1965). Effect of aminonucleoside (of puromycin) on normal and encephalomyocarditis (EMC) virus-infected L cells. *Virology* **27**, 73–79.

FARQUHAR, M. G., and PALADE, G. (1961). Glomerular permeability. *J. Exptl. Med.* **114** (2), 699–716.

GODCHAUX, W. III, ADAMSON, S. D., and HERBERT, E. (1967). The effects of cycloheximide on polyribosome function in reticulocytes. *J. Mol. Biol.* in press.

HARKIN, J. C., and RECANT, L. (1958). The earliest lesion in aminonucleoside nephrosis: an electron microscopic study. *Am. J. Pathol.* **34**, 559 (Abstract).

HARKIN, J. C., and RECANT, L. (1960). Pathogenesis of experimental nephrosis. Electron microscopic observations. *Am. J. Pathol.* **36**, 303–314.

KARNOVSKY, M. I. (1961). Simple methods for staining with lead at high pH in electron microscopy. *J. Biophys. Biochem. Cytol.* **11**, 629–732.

LAWFORD, G. R., and SCHACHTER, H. (1966). Biosynthesis of glycoprotein by liver. *J. Biol. Chem.* **241**, 5408–5418.

LOWRY, O. H., ROSEBROUGH, N. J., FARR, A. L., and RANDALL, R. J. (1951). Protein measurement with the folin phenol reagent. *J. Biol. Chem.* **193**, 265–275.

LUFT, J. H. (1961). Improvement in epoxy resin embedding methods. *J. Biophys. Biochem. Cytol.* **9**, 409–414.

MOSCARELLO, M. A., SUTHERLAND, L., and JACKSON, S. H. (1966). Stimulation of (^{14}C) glucosamine incorporation into plasma proteins by aminonucleoside. *Biochim. Biophys. Acta* **127**, 373–379.

MOSCARELLO, M. A., SUTHERLAND, L., and JACKSON, S. H. (1967). Stimulation of incorporation of glucosamine-1-^{14}C into rat plasma glycoproteins after renal damage. *Can. J. of Biochem.* **45**, 136–141.

NATHANS, D., and NEIDLE, A. (1963). Structural requirements for puromycin inhibition of protein synthesis. *Nature* **197**, 1076–1077.

RABINOVITZ, M., and FISHER, J. M. (1962). A dissociative effect of puromycin on the pathway of protein synthesis by Ehrlich ascites tumour cells. *J. Biol. Chem.* **237**, 477–481.

SARCIONE, E. J. (1962). Incorporation of Glucose-C^{14} into plasma glycoprotein fractions by the isolated rat liver. *Biochemistry* **1**, 1132–1135.

SARCIONE, E. J. (1963). Synthesis of α_1 acid glycoprotein by the isolated perfused rat liver. *Arch. Biochem. Biophys.* **100**, 516–519.

STEINER, J. W., and BAGLIO, C. M. (1963). Electron microscopy of the cytoplasm of parenchymal liver cells in alpha-naphthyl-isothiocyanate induced cirrhosis. *Lab. Invest.* **12**, 765–769.

STUDZINSKI, G. P., and ELLEM, K. (1966). Relationship between RNA synthesis, cell division, and morphology of mammalian cells. *J. Cell Biol.* **29**, 411–421.

TRUMP, B. F., SMUCKLER, E. A., and BENDITT, E. P. A. (1961). A method for staining epoxy sections for light microscopy. *J. Ultrastruct. Res.* **5**, 343–348.

WARNER, J. R., RICH, A., and HALL, C. (1962). Electron microscope studies of ribosomal clusters synthesizing hemoglobin. *Science* **138**, 1399–1403.

YOSHIDA, T., METCOFF, J., KAISER, E., and YAMASHITA, F. F. (1961). Metabolites in kidney liver, and muscle of rats with aminonucleoside nephrosis. *Proc. 12th Ann. Conf. Nephrotic Syndrome* **12**, 146.

REPRINT

THE ENDOCRINE CELLS OF THE KIDNEY

P. K. LEWIN, M.B., M.R.C.S.

VOL. XIX, NO. 10, PAGES 836-840,
NOVEMBER, 1963

Medical Services Journal

VETERANS AFFAIRS BUILDING, OTTAWA, CANADA

The Endocrine Cells of the Kidney

P. K. Lewin*, M.B., M.R.C.S.

The mammalian kidney is one of the main organs of excretion of non-volatile soluble metabolites, and also a controller of the "milieu interieure" so well propounded by Claude Bernard. In recent years great interest has been aroused in the endocrine secretion of certain kidney cells, pioneered by the works of Goormaghtigh and Goldblatt. These cells are quite distinct from the cell nests of supra-renal cortical tissue often found in the substance of the kidney.

Renin secretion from the kidney was first demonstrated by Braun-Menendez and Covian in Argentina and further elucidated by Pickering.

With the above in mind some preliminary experiments were performed in 1957 to demonstrate endocrine cells in the kidney, on the principle that if endocrine cells did exist, these would be independent of the tubular system and therefore survive, and in some cases hypertrophy, in unilateral experimental hydronephrosis. The following is a summary of these experiments, and some of the interesting results obtained.

Experimental Work

Mice were operated on under nembutal anaesthesia administered intraperitoneally, and the ureters tied unilaterally near the kidney pelvis. One of the mice had the renal artery and vein, on the side of ureteric ligation, clamped for ten seconds. The animals recovered well from the effects of the operation and were kept alive for nineteen days.

On necroscopy there was gross hydronephrosis in the ligated kidneys, with compensatory enlargement of the opposite kidneys.

Under these conditions the juxtaglomeruler cells of Goormaghtigh were not visible in the control kidney sections, nor was there any apparent increase of

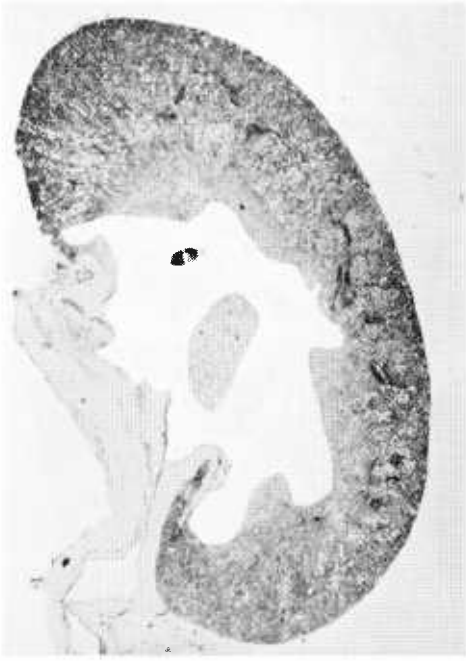

Figure 1. Section of mouse kidney showing hydronephrosis and vascular hypertrophy. Magnification × 10. H. & E. stain.

*Central Middlesex Hospital, London, Eng. Formerly Captain with Royal Canadian Army Medical Corps, 1 Canadian Base Medical Unit, Germany.

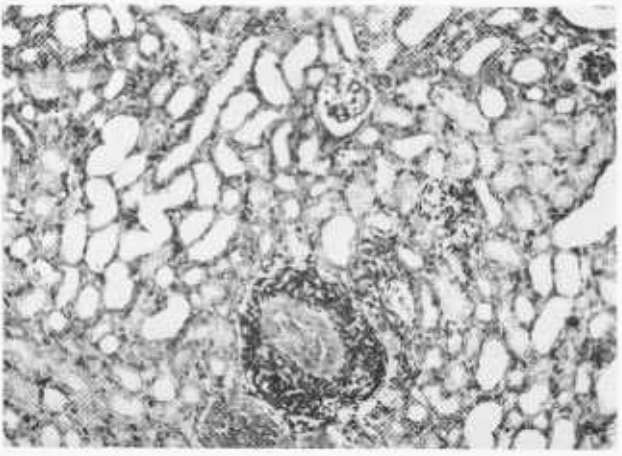

FIGURE 2. Perivascular infiltration. Magnification × 40. H. & E. stain.

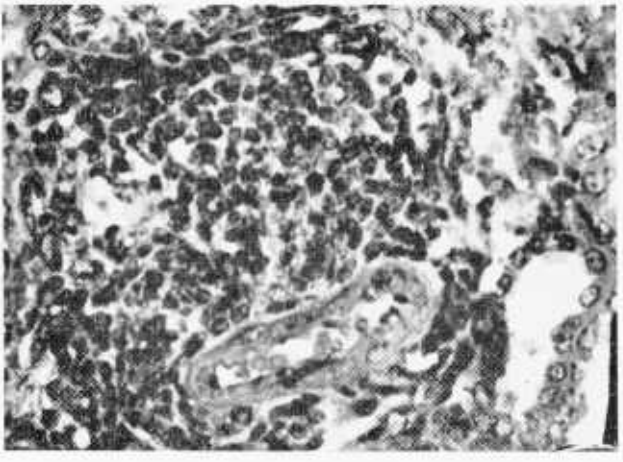

FIGURE 3. Perivascular cells seen in more detail surrounding vessel. Magnification × 100. H. & E. stain.

arteriolar epithelioid cuffing near the entrance of the arteriole into the glomeruli of the hydronephrotic kidneys.

This disappointment was counterbalanced by the presence of numerous highly polychromatic small ovoid nucleated cells resembling lymphocytes surrounding the smaller arteries and arterioles. (See Figures 1, 2 and 3.) These infiltrations were surrounded by collagen. In addition there was marked hypertrophy of vessels, with tubular degeneration present to an advanced degree.

The compensatory kidneys were also markedly vascular and had similar but not so marked arteriolar cellular perivascular cuffing. Glomeruli were also surrounded by a few of these cells. The kidney in which temporary vascular occlusion was applied showed engorgement of glomeruli,

and gross tubular degeneration. No marked cellular perivascular cuffing occurred, and the vessels did not look hypertrophied. However there was marked hypertrophy of the cellular layer of the glomerulus, and the parietal layer of Bowman's capsule contained demilunar cell masses with clear cytoplasm. (The glomeruli looked similar in histology to that seen in the progressive stage of Ellis Type II glomerulonephritis.) Possibly there is some relationship between the above finding and the initial temporary clamping of the renal artery and vein.

Comments

Goormaghtigh demonstrated in his various experiments the proliferation of the media of the afferent arterioles in ischaemic kidneys. This fact amongst others was the groundwork of his theory of endocrine function in the media of kidney arterioles. In the light of experimental data on renal ischaemia, histological examinations reveal that the granular afibrillar cells of the media are responsible for the formation of a vasopressor substance. The discovery of the glandular activity of the afibrillar smooth muscle cells of the afferent arterioles supports the idea of a musculo-endocrine mechanism with vasomotor activity, independent of the nervous system. These cells are now often referred to as the cells of the juxta-glomerular apparatus.

It was the initial purpose of our project to determine whether on ureteric ligation any increase of the juxtaglomerular apparatus was apparent. Due to experimental limitation this fact could not be demonstrated. The cuffing of arteries and arterioles by lymphocytic type of cells, and the increase of the cellular layer of Bowman's capsule of the glomeruli in the kidney subjected to anoxia, give rise to speculation whether these cells may have endocrine properties.

It is of interest that perivascular cellular infiltration is often noticed in human hydronephrotic and eclamptic toxaemic kidneys, but their presence has never been fully explained. The demilunar cellular masses cupping the glomeruli are seen in kidneys where progressive chronic glomerulitis is present, often with hypertension.

One may therefore postulate that the above group of cells may have endocrine functions, similar to that of the juxtaglomerular apparatus, independent of the nervous system. These cells may be under the control of the pituitary or suprarenal gland and their secretions act as a regulatory inhibitory feedback to maintain the so-called 'milieu interieure'. One of the cellular secretions may possibly be renin and another may be hypertensinogen, and excess of secretory activity of these cells may thus be one of the multiple causes of hypertension.

Summary

1. Experimental unilateral hydronephrosis was produced in mouse kidneys in order to study endocrine cells independent of the renal tubular system.

2. In experimental hydronephrotic kidneys, perivascular lymphocytic type of infiltration occurred. Cellular proliferation was noticed in the glomerular capsule of an anoxic kidney.
3. It is postulated that these cells may have endocrine properties.
4. A tentative scheme is shown of the possible relationship with other endocrine glands.

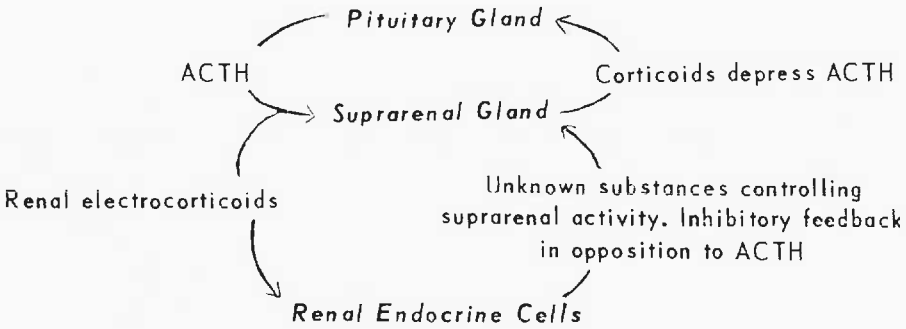

Acknowledgements

I want to thank Dr. E. A. Wright, Reader in Pathology at St. Mary's Hospital, London, England, for encouragement and guidance rendered in the above experiments, and Mrs. Spink for assistance in the laboratory.

REFERENCES

1. Goormaghtigh, N. Existence of an endocrine gland in the media of renal arterioles. Proc. Soc. Exper. Biol. & Med. 42:688, '39.
2. Goormaghtigh, N. Histological changes in ischemic kidney with special reference to juxtaglomerular apparatus. Amer. J. Path. 16:409, '40.
3. Goormaghtigh, N. La fonction endocrine des artérioles rénales. Rev. belge sc. méd. 16:65, '45.
4. Goormaghtigh, N. Facts in favour of an endocrine function of the renal arteries. J. Path. & Bact. 57:392, '45.
5. Goormaghtigh, N. Renal arteriolar changes in anuric crush syndrome. Am. J. Path. 23:513, '47.
6. Goldblatt, H. Experimental hypertension induced by renal ischemia. Harvey lecture, Bull. New York Acad. Med. 14:523, '38.
7. Friedman, M., and Kaplan, A. Studies concerning site of renin formation in kidney; renin content of mammallian kidney following specific necrosis of proximal convoluted tubular epithelium. J. Exp. Med. 77:65, '43.
8. Dunihue, F. W. The effect of adrenal insufficiency and desoxycorticosterone acetate on the juxtaglomerular apparatus. Anat. Rec. 103:442, '42.
9. Hartroft, P. M., and Hartroft, W. S. The effects of dietary factors and administration of D.C.A. on the juxtaglomerular apparatus. Anat. Rec. 12:39, '52.
10. Selye, H., and Stone, H. Pathogenesis of the cardiovascular and renal changes which usually accompany malignant hypertension. J. Urol. 56:399, '46.
11. McManus, J. F. A. Further observations on the glomerular root of the vertebrate kidney. Quart. J. Micro. Sci. 88:39, '47.
12. Wilson, W. A new staining method for demonstrating the granules of the juxtaglomerular complex. Anat. Rec. 112:497, '52.

13. White, H. P. W. Pathology of hydronephrosis. Brit. J. Surg. 13:247, '25.
14. Hinman, F., and Hepler, A. B. Experimental hydronephrosis; effect of changes in blood pressure and blood flow on its rate of development; splanchnotomy, increased intrarenal blood pressure and flow; diuresis. Arch. Surg. 11:578, '25.
15. Megibow, R. S., Katz, L. N., and Rodbard, S. Mechanism of arterial hypertension in experimental hydronephrosis. Am. J. Med. Sc. 204:340, '42.
16. Altschul, R. M. V., and Fedor, S. Vascular changes in hydronephrosis. Amer. Heart J. 46:291, '53.
17. Trueta, J., et al. Renal pathology in light of recent neurovascular studies. Lancet 2:237, '46.
18. Badenoch, A. W., and Darmady, E. M. Effects of temporary occlusion of renal artery in rabbits and its relationship to traumatic uraemia. J. Path. & Bact. 59:79, '47.
19. Grollman, A., et al. Intermittent peritoneal lavage in nephrectomized dogs and its application to human being. Arch. Int. Med. 87:379, '51.
20. Braun-Menendez, E., and Covian, M. R. Rev. Soc. Argent. de Biol. 24:44, '48.
21. Pickering, G. W. High blood pressure. Churchill, London. '55.
22. Gellman, D. D. Reversible hypertension and unilateral renal artery disease. Quart. J. Med., Oxf. 27:103, '58.
23. Flower, M. A. The role of the kidney in experimental hypertension. *In* Ciba Foundation. Hypertension: humoral and neurogenic factors. Churchill, London. '54. p. 155.
24. Berman, L. B., and Schreiner, G. E. Clinical and histological spectrum of the nephrotic syndrome. Amer. J. Med. 24:249, '58.
25. Dieckmann, W. J., McCartney, C. D., and Harrod, J. P. Kidney biopsies in multiparous patients with vascular renal diseases in pregnancy. Amer. J. Obstet. Gynec. 75:634, '58.

Reprinted from
THE CANADIAN MEDICAL ASSOCIATION JOURNAL
94, 129-131, January 15, 1966

Cardiac Myoglobin in Myoglobinuria

P. K. LEWIN, M.B., M.R.C.S* and M. A. MOSCARELLO, M.D.,†
Toronto

ABSTRACT

Studies were undertaken to determine whether significant abnormalities were present in cardiac myoglobin in a case of primary paroxysmal myoglobinuria.

No qualitative abnormality was found in cardiac myoglobin from a patient with myoglobinuria, compared to normal controls, using urea starch gel electrophoresis. Quantitative analysis, however, revealed depletion of cardiac myoglobin in the patient with myoglobinuria.

It is considered that the basic defect in primary paroxysmal myoglobinuria is not related to myoglobin *per se*, and although evidence is lacking, an autoimmune process, as encountered in some of the hemolytic anemias, may be involved in this condition.

SOMMAIRE

On a cherché à déterminer s'il y avait présence d'anomalies notables de la myoglobine cardiaque dans un cas de myoglobinurie paroxystique primaire.

Par rapport à des témoins, on n'a découvert aucune anomalie qualitative de la myoglobine cardiaque chez un malade présentant une myoglobinurie. La méthode d'analyse utilisait l'électrophorèse au gel d'amidon additionné d'urée. Par contre, l'analyse quantitative a révélé une déplétion prononcée de la myoglobine cardiaque chez ce malade.

On estime que le trouble profond dans la myoglobinurie paroxystique primaire n'est pas attribuable à la myoglobine en soi, et, bien qu'on n'en aît aucune preuve, un processus auto-immun, qu'on observe notamment dans les formes d'anémies hémolytiques, peut jouer un rôle dans la pathologie qui nous occupe.

PRIMARY paroxysmal myoglobinuria is a condition of unknown etiology, first described by Meyer-Betz[1] in 1911 and since reported with increasing frequency.

The pathological process involves striated muscle which suddenly undergoes lysis, releasing large amounts of myoglobin into the circulation. Bowden *et al.*[2] termed this condition acute recurrent rhabdomyolysis, and reported a number of cases from the Research Institute of The Hospital for Sick Children, Toronto, showing strong genetic relationships. Hed[3] and Wheby and Miller[4] also described a number of cases with familial tendencies.

Other authors, such as Bailie[7] and Perkoff,[5, 6] have suggested that abnormalities in myoglobin exist in the myoglobinurias. With this observation in mind, investigations were undertaken to determine whether abnormalities existed in cardiac myoglobin of autopsy material from a case of acute paroxysmal myoglobinuria.

From the Research Institute, The Hospital for Sick Children, Toronto, Ontario.
*Assistant Resident, Hospital for Sick Children, Toronto.
†Assistant Scientist, Hospital for Sick Children, Toronto.

CASE HISTORY

A 45-year-old dye-setter was admitted to the Wellesley Hospital, Toronto, on March 20, 1965, with generalized muscular aches, dark brown urine and a low urinary output. He had been transferred from a hospital in Orillia on the same day. Two weeks before admission he had developed an upper respiratory tract infection with stuffiness in his head, headache and general malaise, but no cough. His wife had similar symptoms. On March 18, he became quite short of breath and developed severe aches and pains in his abdomen and extremities which were aggravated by body movement. His urine had been dark for 24 hours. Tetracycline therapy was begun at home and he was admitted to hospital in Orillia on March 19.

Ever since childhood, following exercise, he had noted aching joints and muscles, along with weakness. He sometimes had to be carried home from school. In the Army during World War II he was investigated for these complaints and was thought to have methemoglobinemia. Attacks of muscular aching would come on suddenly following exertion, as often as five to six times per year. They usually lasted 24-48 hours, with spontaneous recovery. His urine would become dark and scanty in amount. The last attack was one month prior to admission.

Laboratory studies revealed the following: His hemoglobin was 15.8 g. % and his leukocyte count was 16,700 per c.mm. with a normal differential count. The serum potassium was 5.7 and the CO_2 content was 16.9 mEq./l.

After admission to hospital despite restriction of fluid intake and chemotherapy with an oral chelating agent (Kayexalate) and an osmotic diuretic (Osmitrol), the patient developed increasingly severe oliguria. Peritoneal dialysis was carried out on March 23, without clinical improvement, and the patient died suddenly, 12 hours after dialysis, following a generalized clonic seizure.

EXPERIMENTAL PROCEDURES

Cardiac muscle was obtained from autopsy material from young adults who had died in automobile accidents, and from the above patient with myoglobinuria. The muscle was stored at —20° C. for 48 hours before extraction.

Cardiac myoglobin was extracted using essentially the method of Ginger, Wilson and Schweigert.[8]

(a) *Preparation of cardiac myoglobin*: 50 g. of cardiac muscle was "blended" (Onmimix) in 50 ml. of distilled water and allowed to remain in the cold room (2°-5° C.) overnight. The supernatant obtained after centrifugation was adjusted to pH 7.0 to which was added 12.5 ml. of saturated basic lead acetate. The precipitate was removed by centrifugation. The phosphate ion concentrate was adjusted to 3M (pH 6.6) by the addition of monohydrogen and dihydrogen potassium phosphate. The precipitate was removed by centrifugation and the supernatant was dialysed against eight changes of distilled water. The material from the dialysis bag was brought to 85% saturation with ammonium sulfate. The precipitate was collected by centrifugation and the supernatant, which contained the myoglobin in ammonium sulfate, was dialysed against 10 changes of distilled water. The contents of the dialysis bag were lyophilized in some cases. However, this had the effect of rendering the myoglobin insoluble. For column chromatography the contents of the bag were used without dialysis.

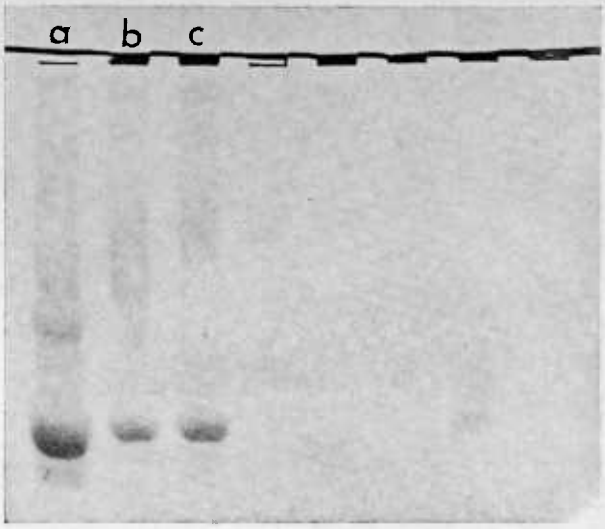

Fig. 1.—Urea-starch gel at pH 3.4 showing (from left to right) (a) cardiac myoglobin as prepared; (b) and (c) DEAE chromatography of myoglobin: (b) fraction 82-84; (c) fraction 85-87.

(b) *Column Chromatography*: Myoglobin was chromatographed on DEAE-cellulose columns equilibrated with 0.005 M tris buffer (pH 7.85); myoglobin, 13 mg., was applied to a column 2.5 x 18 cm. and eluted according to the method described by Perkoff *et al.*[9]

(c) *Starch Gel Electrophoresis*: The vertical starch gel method described by Smithies[10] was used throughout. Tris-borate gels were used at pH 8.6. After slicing, half the gel was stained with benzidine and half with amido black. Urea starch gels (pH 3.4) were prepared by the method of Smithies, Connell and Dixon.[11]

(d) *Protein Determination*: The Lowry modification of the Folin method was used.[12]

RESULTS

Myoglobin Extracted from Normal Heart Muscle

The electrophoretic findings on a typical preparation are shown in Fig. 1, a photograph of a urea starch gel. In slot (a) the supernatant, after ammonium sulfate precipitation, shows one heavy band and at least three light bands.

When such a myoglobin preparation is chromatographed on DEAE-cellulose, as described above, one major component is present, as seen in slots (b) and (c) of Fig. 1. This material was shown not to be hemoglobin but to stain positively with benzidine after electrophoresis in tris-borate starch

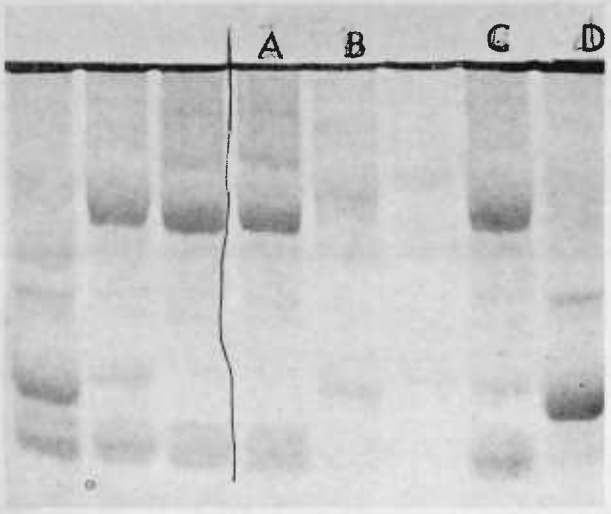

Fig. 2.—Urea-starch gel, pH 3.4, of cardiac myoglobins. (a) Fraction precipitated by 85% ammonium sulfate from a case of paroxysmal myoglobinuria. (b) Supernatant from (a). (c) Fraction precipitated by 85% ammonium sulfate from normal cardiac muscle. (d) Supernatant from (c).

gel at pH 8.6. A soret band was found at 417 mμ. and a protein peak at 280 mμ.

Myoglobin Extracted from a Case of Myoglobinuria

In Fig. 2, a urea-starch gel preparation, myoglobin extracted from normal cardiac muscle, is contrasted with the electrophoretic findings in the case of myoglobinuria described above. Comparing the patterns found in slots A and B with those in slots C and D, it can be seen that they are qualitatively similar. The major myoglobin band, M1, in slot D is also present in slot B.

When a comparison was made of the amounts of myoglobin extracted from normal heart muscle and cardiac muscle from the case of myoglobinuria, the following results were obtained: After 28 different extractions from as many independent samples of heart muscle, we obtained between 150 and 200 mg. of myoglobin per 100 g. of tissue. In the case of myoglobinuria, we obtained only 10 to 20 mg. of myoglobin per 100 g. of cardiac muscle.

Myoglobin Isolated from the Urine in a Case of Myoglobinuria

Urine was collected from a neonate who developed myoglobinuria following a prolonged convulsive episode. The baby survived and its myoglobinuria has subsequently cleared.

The urine was dialysed against six changes of distilled water and brought to 85% saturation with ammonium sulfate by addition of solid ammonium sulfate. The precipitate was removed by centrifugation and the supernatant was dialysed against 10 changes of distilled water. The myoglobin solution was lyophilized.

The material isolated from the urine behaved like normal myoglobin on starch gel electrophoresis.

DISCUSSION

Myoglobin extracted by the method described above yields distinct zone electrophoretic patterns. The major component was identified as myoglobin by column chromatographic and starch gel characteristics, and by the presence of a soret band at 417 mμ.

Myoglobin extracted from cardiac autopsy material in a case of paroxysmal myoglobinuria showed no abnormality in urea-starch gel pattern as compared with the normal controls, i.e. the major and most of the minor components were present. The basic defect in this condition most probably is not related to myoglobin *per se* but to the other muscle components. Although evidence is lacking, some autoimmune process as seen in some of the hemolytic anemias with hemolysis may be involved here.

As demonstrated quantitatively, acute myoglobin depletion of muscle tissue, including myocardium, occurs in myoglobinuria. The resultant hypomyoglobinosis gives rise to relative cellular anoxia with serious and often fatal consequences.

The fact that we were able to obtain only minute amounts of myoglobin from cardiac muscle in our case of myoglobinuria is direct confirmation of data presented by Bowden *et al.*[2] These authors consider that myoglobinuria can best be thought of as recurrent rhabdomyolysis, a term which they feel more correctly describes the pathological condition.

The isolation of myoglobin from urine in a neonate with myoglobinuria showed essentially the same pattern on urea-starch gel as that extracted from cardiac muscle.

SUMMARY

Investigation of a case of primary paroxysmal myoglobinuria revealed no qualitative abnormality, in cardiac myoglobin, as compared to that of normal controls, on urea-starch gel zone electrophoresis.

Acute depletion of cardiac myoglobin in patients with myoglobinuria occurs, as demonstrated quantitatively, with a resultant state of hypomyoglobinosis.

We wish to thank Dr. M. Shulman, Chief Coroner of Metropolitan Toronto, for cardiac autopsy material; Dr. A. H. Squires of the Wellesley Hospital, Toronto, for cardiac muscle in the case of myoglobinuria; Dr. M. Miskin for sending us urine samples in the case of neonatal myoglobinuria, and Dr. T. C. Brown for the autopsy specimen and sections.

Dr. S. Hartroft is thanked for general use of laboratory facilities and constructive criticism.

REFERENCES

1. MEYER-BETZ, F.: *Deutsch. Arch. Klin. Med.*, **101**: 85, 1911.
2. BOWDEN, D. H. *et al.*: *Medicine (Balt.)*, **35**: 335, 1956.
3. HED, R.: *Acta Med. Scand.* (Suppl. 303), **151**: 1, 1955.
4. WHEBY, M. S. AND MILLER, H. S., JR.: *Amer. J. Med.*, **28**: 599, 1960.
5. PERKOFF, G. T.: *Clin. Res.*, **11**: 115, 1963 (abstract).
6. *Idem.*: *New Eng. J. Med.*, **270**: 263, 1964.
7. BAILIE, M. D.: *Ibid.*, **271**: 186, 1964.
8. GINGER, I. D., WILSON, G. D. AND SCHWEIGERT, B. S.: *Journal of Agricultural and Food Chemistry*, **2**: 1037, 1954.
9. PERKOFF, G. T. *et al.*: *J. Biol. Chem.*, **237**: 2820, 1962.
10. SMITHIES, O.: *Biochem. J.*, **71**: 585, 1959.
11. SMITHIES, O., CONNELL, G. E. AND DIXON, G. H.: *Amer. J. Hum. Genet.*, **14**: 14, 1962.
12. LOWRY, O. H. *et al.*: *Biol. Chem.*, **193**: 265, 1951.

therapy alone, using a combination of a diuretic and a suitable antibiotic. The results of a preliminary trial upon 15 patients have been recorded, and in 11 of these satisfactory progress was obtained. No side-effects have resulted from treatment.

For reasons outlined, the regime is thought to overcome some of the problems of the more recognized forms of treatment, and is a particularly useful means by which the busy general practitioner, who is usually without ancillary aid, can be stimulated to become interested in the treatment of leg ulcers.

Though, fortuitously perhaps, no further treatment was required in two patients, the regime is to be regarded more as a smooth induction to subsequent "traditional" therapy than as an alternative.

I would like to thank Dr. Napier Thorne, without whose advice, help, and encouragement this paper would not have materialized.

DAVID B. FOX, M.A., M.B., B.Chir.

Varicose Ulcer Clinic,
Prince of Wales Hospital,
Tottenham.

REFERENCES

Anning, S. T. (1954). *Leg Ulcers and Their Treatment.* Churchill, London.
Lorch, Diana (1961). *Practitioner*, 187, 67–73.
Thorne, Napier A. (1958). "Practical Politics in the Treatment of Leg Ulcers, *Nursing Times.*

Medical Memoranda

Post-operative Blindness, with Complete Recovery, in a Patient with Sickle-cell Anaemia

Among the various neurological complications in patients with sickle-cell anaemia transient blindness has been rarely reported (Hughes *et al.*, 1940; Margolies, 1951; Greer and Schotland, 1962). The following is a history of a girl with sickle-cell anaemia who post-operatively developed severe neurological symptoms including blindness.

CASE REPORT

An 11-year-old Nigerian girl with known sickle-cell anaemia (SS) was admitted to our wards for repair of a large inguinal hernia. She had been generally well, complaining only of transient vague pains of undetermined cause in her upper and lower limbs. History revealed that she had never had any typical crises. On admission she was a tall thin negro girl in no distress. She was not jaundiced, her blood-pressure was 100/60 mm. Hg, and auscultation revealed a soft apical systolic murmur. *X*-ray examination of the chest showed moderate cardiac enlargement and clear lung fields. An electrocardiogram was within normal limits. Neurological examination revealed no abnormality. Her haemoglobin was 8 g./100 ml. It was 9.8 g./100 ml. one month before the operation. The operation was performed under general anaesthesia, which was induced with thiopentone sodium ("pentothal") and suxamethonium chloride ("scoline"). She was intubated and anaesthesia was maintained with a mixture of nitrous oxide, oxygen, and halothane. Gallamine triethiodide, atropine, and neostigmine were also given. The operation lasted about 30 minutes and was uneventful, except that the incisional oozing was less than normal for the first three or four minutes. She regained consciousness after one hour and then slept for 12 hours.

On awakening she complained that she could not see. She was jaundiced. Her consciousness alternated between being orientated and able to respond to simple questions, and refusing to respond or responding inappropriately. She could not see objects or distinguish light from darkness. Both papillary reflexes were sluggish. Nystagmus was not present. The fundi were normal except for a slight tremor of the disk. Our neurological consultant, who noted this, considered the phenomenon to be strongly in favour of organic disease and against hysteria—an alternative we were considering at that point. Her tendon reflexes were equal and active and both plantar responses were flexor. She was generally weak but had no paralysis. Her haemoglobin was 8.2 g./100 ml. and the total bilirubin was 9.7 mg./100 ml. Her blood-pressure was 100/60 mm. Hg.

The clinical picture suggested a possible occlusion of cerebral vessels with aggregated sickle cells. In order to lessen the likelihood of further occlusions, she was given intranasal oxygen and also a 50% solution of magnesium sulphate intravenously six-hourly for three days (H. Lehmann, personal communication). On the second post-operative day she developed a right pleural effusion. A culture of the effusion was sterile. Lumbar puncture was not performed, as it was thought that the procedure might aggravate the neurological condition during the acute stage. On the fourth post-operative day she began to recognize objects placed near her. At the same time her ankle clonus became sustained, but both plantar responses remained flexor. Weakness persisted in all limbs; this was more pronounced in the arms. By the fifth post-operative day her haemoglobin had dropped to 6.5 g./100 ml. She was then transfused with 360 ml. of packed red cells.

Her vision steadily improved and no visual abnormality could be detected four weeks after operation. Concomitantly her mental state returned to normal, the ankle clonus disappeared, and her muscular tone improved. She was discharged five weeks after operation in a satisfactory physical and mental state. The only remaining clinical sign was a slight incoordination of fine movements of the upper limbs. The haemoglobin was 10 g./100 ml.

COMMENT

The neurological manifestations were probably due to cerebral intravascular sickling induced by low oxygen tension during anaesthesia. The transitory nature of the various symptoms and signs as occurred in this case is characteristic of patients with sickle-cell anaemia (Margolies, 1951). The apparent full recovery from the neurological disturbances seen in these patients can be explained on the basis of an initial occlusion of a vessel, whether by thrombus or sludge formation (some authors also maintain that the vessels go into spasm), with resultant impairment of the oxygen supply to a part of the brain, leading to neurological shock. The degree of recovery depends on the availability of collateral supply to the area involved and the reopening of the occluded vessel.

In conclusion the following points should be considered before operating on a patient with sickle-cell anaemia. (1) Elective procedures should be avoided if possible. (2) The choice of anaesthetic should take into account the tendency for red-cell sickling with anoxia, and the hypotensive effect of certain anaesthetics.

We thank Mr. Michael Harmer and Dr. Thomas Stapleton for their help.

PETER LEWIN, M.B.
ROBERT A. GOODELL, Jr., M.D.

Paddington Green Children's Hospital,
London.

REFERENCES

Greer, M., and Schotland, D. (1962). *Neurology (Minneap.)*, 12, 114.
Hughes, J. G., Diggs, L. W., and Gillespie, C. E. (1940). *J. Pediat.*, 17, 166.
Margolies, M. P. (1951). *Medicine (Baltimore)*, 30, 357.

PETER K. LEWIN—(20)—C. M. A. J. Galley 1
— Short Communication — — 3 Blocks —

4 Pages

The Ultrastructure of Mummified Skin Cells

PETER K. LEWIN, M.B., M.R.C.S.,* *Toronto*

RECENT work has shown that mummified tissues examined by electron microscopy show remarkable preservation at the ultrastructural level.[2]

A further extension of this work is presented, using material obtained from the skin of a mummified hand of ancient Egyptian origin to which a date of approximately 600 B.C. has been assigned.

METHOD

Mummified material when unwrapped is dry and brittle, and disintegrates easily. Such material can be rehydrated according to Ruffer's method.[4]

(a) *Rehydration.*—Small pieces of tissue about 1 to 2 mm. in length were suspended for 24 hours from a platinum loop in small tubes containing Ruffer's solution, consisting of a mixture of 30 c.c. of absolute alcohol, 50 c.c. of distilled water and 20 c.c. of a 5% sodium carbonate solution. Following hydration, tissues tended to fragment and had to be handled with great care.

(b) *Electron microscopy.*—Following rehydration, small fragments of tissue were suspended in 0.1 M phosphate buffer solution for five minutes, and then were fixed for one hour in 1% osmium tetroxide buffered with 0.1 M phosphate buffer (pH 7.2). After dehydration in a graded series of ethanol solutions, the tissues were embedded in an Epon-Araldite mixture (modification of Luft's method.[3]) Sections were cut with a glass knife on Porter-Blum or LKB microtomes and picked up on uncoated grids, stained with lead hydroxide by the method of Karnovsky[1] and examined with an R.C.A. EMU 3-F or JEM 5-C electron microscope. Micrographs were taken at initial magnification of 1400 to 32,000 and were enlarged photographically to the desired size. Thin sections of plastic-embedded tissue were stained with toluidine blue by the method of Trump, Smuckler and Benditt.[6]

OBSERVATIONS

Light microscopy.—The distinct histological features of skin were seen in embedded Epon-Araldite sections, stained with toluidine blue. Nucleated cells were most numerous at the epidermal [illegible]rmal junctions.

epidermal and dermal junctions.

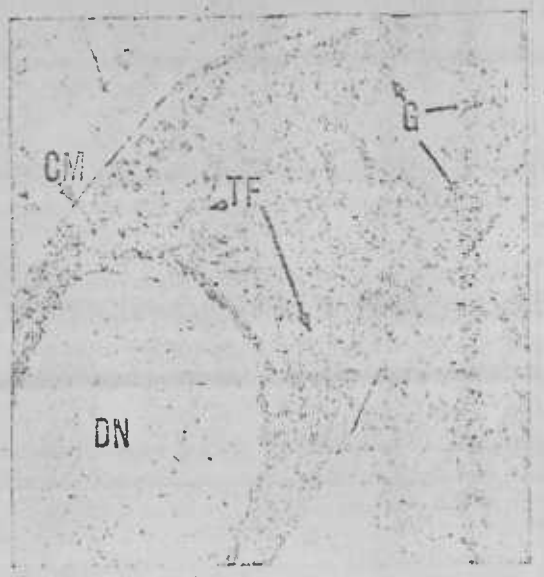

Fig. 1.—Mummified basal epidermal cell. CM: cell membrane; DN: distintegrated nucleus; TF: tonofilaments; G: granules. (Lead hydroxide stain, × 52,000.)

Electon microscopy.—Fig. 1 is an electron micrograph of a basal epidermal cell showing remnants of tonofilaments, and a number of cytoplasmic granules which may be pigment granules. The nucleus is disintegrated.

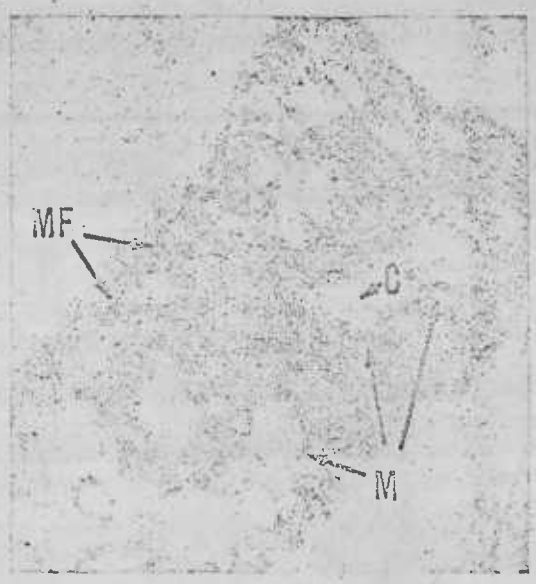

Fig. 2.—Mummified epidermal cell. M: membranous organelles; C: christa; MF: membranous filament. (Lead hydroxide stain, × 54,000.)

Fig. 2 is a micrograph of an epidermal cell showing numerous membranous organelles and a few membranous filaments. Some of the organelles have a double membrane and are most probably mitochondria; a christa-like structure is present in one of them.

From the Department of Pathology, University of Toronto, Banting Institute, Toronto, Ontario.
*Fellow of the Medical Research Council of Canada.
Reprint requests to: Dr. P. K. Lewin, Room 114, Banting Institute, 100 College Street, Toronto 2, Ontario.

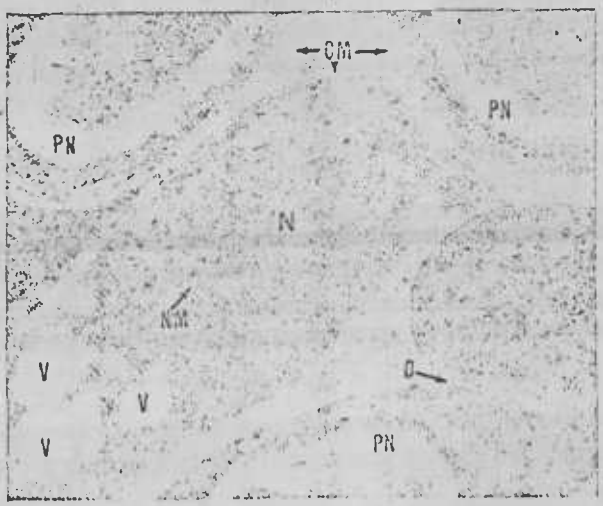

Fig. 3.—Mummified epidermal cells from stratum spinosum. NM: nuclear membrane; CM: cytoplasmic membrane; V: vacuoles; N: nucleus; PN: perinuclear space; D: desmosome-like structure. (Lead hydroxide stain, × 65,000.)

Fig. 3 is an electron micrograph of cells from the stratum spinosum of the epidermis. The central cell contains an intact nuclear membrane and a number of cytoplasmic vacuoles of unknown origin. The surrounding cells have pronounced perinuclear spaces and are in contact with the central cell cytoplasmic membrane. In one area of cell contact a desmosome-like structure is present.

Comment

Although the cellular components of mummified tissues were markedly shrunken, preservation at the ultrastructural level was such that cellular components of the skin epidermis could be determined. Further improvements may be made by using better rehydration techniques.[5]

Electron microscopy of mummified tissues may be a useful tool in comparative anthropology and could be utilized in the investigation of certain pathological processes present in some of our mummified ancestors. Such investigations may be of great interest to those studying the history of certain diseases in man.

Summary Skin from an Egyptian mummified hand was processed for electronmicroscopy to determine its state of preservation at the ultrastructural level. Although mummified cells were greatly shrunken, most were intact with recognizable cellular components. It is suggested that electronmicroscopy of such tissues may be useful in the field of comparative anthropology.

Résumé On a préparé la peau prélevée sur une main de momie Egyptienne en vue de son examen au microscope électronique. Cet examen avait pour objet d'établir l'état de sa conversation au point de vue de son ultra-structure. Bien que les cellules momifiées aient été considérablement rétrécies, la plupart étaient intactes et permettaient d'identifier les composants cellulaires. L'auteur estime que l'examen de ces tissus au microscope électronique peut avoir son utilité dans de domaine de l'anthropologie comparée.

I am indebted to Miss Needler of the Royal Ontario Museum, Toronto, who supplied the mummified material, and to Professor A. C. Ritchie for assistance. Dr. Jézéquel, Mr. G. Doornewaard and Mrs. J. Cetkovski gave technical help.

References

1. Karnovsky, M. J.: *J. Biophys. Biochem. Cytol.*, 11: 729, 1961.
2. Lewin, P. K.: *Nature*, 213: 416, 1967.
3. Luft, J. H.: *J. Biophys. Biochem. Cytol.*, 9: 409, 1961.
4. Ruffer, M. A.: Studies in Palaeopathology of Egypt, edited by R. L. Moodie, University of Chicago Press, Chicago, 1921.
5. Sandison, A. T.: The story of mummified and dried human tissue. *In:* Science in archeology; a comprehensive survey of progress and research, edited by D. Brothwell and E. Higgs, Thames and Hudson Ltd., London, 1963, p. 413.
6. Trump, B. F., Smuckler, E. A. and Benditt, E. P.: *J. Ultrastruct. Res.*, 5: 343, 1961.