

Embolization of pulmonary AVMs: no consistent effect on pulmonary artery pressure

**^{1,2}Claire L Shovlin PhD FRCP, ² Hannah C Tighe BSc, ²Rachel J Davies BA MRCP, ¹ J
Simon R Gibbs MD FRCP, ³James E Jackson FRCR, FRCP.**

¹NHLI Cardiovascular Sciences, Imperial College London, and ²Respiratory Medicine and
³Department of Imaging, Hammersmith Hospital, London W12 0NN, UK.

Running Title: Pulmonary AVMs and PAP

Address for correspondence and reprint requests:

Dr Claire Shovlin PhD FRCP
NHLI Cardiovascular Sciences Unit
Imperial College London
Hammersmith Hospital
Du Cane Road
London
W12 0NN, UK.

PHONE 011-44-208-383-1000
FAX 011-44-208-383-1640
EMAIL: c.shovlin@imperial.ac.uk

Abstract 199 Word count 2938 (abstract, text and Tables)

ABSTRACT

Question: Increasing evidence supports the use of embolization to treat pulmonary arteriovenous malformations (AVMs). Most pulmonary AVM patients have hereditary haemorrhagic telangiectasia (HHT), a condition that may be associated with pulmonary hypertension. We tested whether PAVM embolization increases pulmonary artery pressure (PAP) in patients without baseline severe pulmonary hypertension.

Methods: PAP were measured at the time of PAVM embolization in 143 individuals, 131 (92%) of whom had underlying HHT. Angiography/embolization was not performed in four individuals with severe pulmonary hypertension, whose systemic arterial oxygen saturation exceeded levels usually associated with dyspnoea in PAVM patients.

Results: In 143 patients undergoing PAVM embolization, PAP was significantly correlated with age, with the most significant increase occurring in the upper quartile (age >58yr). In 43 patients with repeated measurements, there was no significant increase in PAP as a result of embolization. In half, embolization led to a fall in PAP. The maximum rise in PAP mean was 8mmHg. Test balloon occlusion was performed in one of these individuals, and did not predict the subsequent rise in PAP following definitive embolization of the pulmonary AVMs.

Conclusions: In this series which excluded patients with severe pulmonary hypertension, PAP was not increased significantly by PAVM embolization.

Key words: brain abscess, hypoxaemia, nose bleeds, right to left shunt, oxygen saturation, stroke,

INTRODUCTION

Does embolization of pulmonary arteriovenous malformations (AVMs) precipitate pulmonary hypertension (PH)?

The reason this question is important is that for individuals with pulmonary AVMs, embolization is an effective means of reducing lifetime risks of paradoxical embolic stroke and brain abscess [1, 2], improving oxygenation [3-17], and treating pulmonary AVM-related haemoptysis [16, 18, 19]. Conversely, embolization may be expected to elevate pulmonary artery pressure (PAP), since pulmonary AVMs are abnormal dilated vessels between pulmonary arteries and veins that provide low resistance pathways for pulmonary blood flow [20].

The question of whether pulmonary AVM embolization increases PAP is particularly pertinent since most individuals with pulmonary AVMs have underlying hereditary haemorrhagic telangiectasia (HHT). Typically recognised by nose bleeds, mucocutaneous telangiectasia and visceral AVMs [21], HHT may be associated with pulmonary hypertension (PH) [9, 22-30]. The secondary causes of PH in HHT are diverse, as in the normal population [31], but PH particularly occurs either as a true pulmonary arterial hypertension (PAH) phenotype [9, 22, 28-30], or in the context of high output cardiac failure secondary to hepatic AVMs, when PH may be reversible after hepatic AVM treatment [32]. The frequencies of PAH and hepatic AVMs differ with HHT genotype: HHT is caused by mutations in at least five genes including *endoglin* (HHT type 1) and *ALK-1* (HHT type 2), with pulmonary AVMs most common in HHT type 1 [33]. PAH phenotypes are more common in HHT type 2 [22, 28, 29] than HHT type 1 [30]. Hepatic AVMs are also more frequent in HHT type 2 [33].

Of more than 700 reported pulmonary AVM embolizations reported [1-18, 34-42], data on PAP measurements pre and post embolization are scarce [9, 11, 17, 32]. In three of the four reported cases [9, 17, 32], each selected from larger series, PAP increased post embolization,

while in the fourth [11] it was unchanged. There is also a report of worsening PH after surgical resection of a pulmonary AVM [43].

We have previously reported that in our population of pulmonary AVM patients, 92% of whom had HHT, the overall prevalence of pulmonary hypertension is low [44]. We hypothesised that in contrast to the limited data in the literature, pulmonary AVM embolization would not increase PAP. Here we report the results of a retrospective study in the series of pulmonary AVM patients reported recently [2], performed to determine whether pulmonary AVM embolization affected pulmonary artery pressure, and whether it may be safe to extend our embolization practice to individuals with severe PH.

METHODS

Study population

All studies were ethically approved by the Hammersmith, Queen Charlotte's, Chelsea, and Acton Hospital Research Ethics Committee (LREC 00/5764), and performed as part of routine clinical management of individuals with pulmonary AVMs.

SaO₂ were measured as previously described [2, 4, 45]. For SaO₂ values reported here, recordings were made every 60 seconds for 10 minutes standing, since SaO₂ in the erect posture correlates better with right to left shunt [45]. All patients with pulmonary AVMs of a size amenable to embolization treatment underwent pulmonary angiography with a view to embolization, unless there was a major medical contraindication. In view of theoretical concerns, angiography/embolization was not considered for four women referred to the service with severe pulmonary hypertension and well preserved oxygen saturations. Pulmonary angiography was performed as previously described [4] in unmedicated, conscious patients who had not been fluid-restricted pre-procedure. Systolic, diastolic and mean PAP were recorded routinely prior to contrast injection via a multi-sidehole catheter (Grollman pigtail catheter (William Cook Europe, Bjaeverskov, Denmark)). Measurements were repeated

immediately after embolization in the subgroup of individuals with higher PAP. In the majority of patients, only a single angiography/embolization session was required [2].

Statistics

Statistical analyses were performed using Prism 4 and InStat (Graph Pad Inc). For SaO₂, the last four minutes readings for erect postures were entered as replicate data for each of the pre and post embolization data. Quartile group data were incorporated from the full series of 219 pulmonary AVM patients, as reported in reference [2].

Age was expected to influence PAP, since catheterisation data at rest in two groups of healthy individuals (17 aged 16-28yr [46]; 15 aged 61-83 yr [47]) demonstrated significantly higher PAP systolic (mean 24.47 vs 19.94, $p=0.003$, Mann Whitney) and PAP mean (mean 16.13 vs 13.65, $p=0.026$) in the older group. This has also been supported by more recent echocardiography data [48]. In our series, associations of PAP measurements with age were performed using Spearman rank analyses and linear regression. The patients were also stratified into age-quartile groups, and interquartile differences analysed by one way analysis of variance (ANOVA) with post test correction for linear trend.

In order to test whether PAP was elevated following embolization of pulmonary AVMs, PAP measurements recorded pre-embolization were studied in all patients with at least two PAP measurements. 39 pairs of consecutive PAP measurements recorded at the outset of at least two embolization sessions were available from 35 patients. In addition, nine pairs of PAP measurements recorded pre and post embolization in the same session were available for eight patients with pre-existing mild to moderate pulmonary hypertension, in whom the repeat measurements during the same procedure had been justified as part of their clinical management. To test the null hypothesis that embolization of pulmonary AVMs does not increase PAP, measurements pre and post embolization, and pre and age-adjusted post

embolization measurements, were analysed by two tailed paired t-test, and significance assessed at false discovery rate (FDR)=0.05 level [49].

RESULTS

Patient populations

Patient ages ranged from 8 to 78yr at the time of embolization (Figure 1a). In patients undergoing embolization, baseline SaO₂ erect ranged from 73 to 98%, with a median value of 93% as in the full population reported in reference [2] (Figure 1b). For the four individuals who did not undergo embolization due to severe pre-existing PH, SaO₂ (erect) was in the upper two quartiles of the full pulmonary AVM population, at levels for which the majority of individuals with did not experience dyspnoea [2] (Figure 1b).

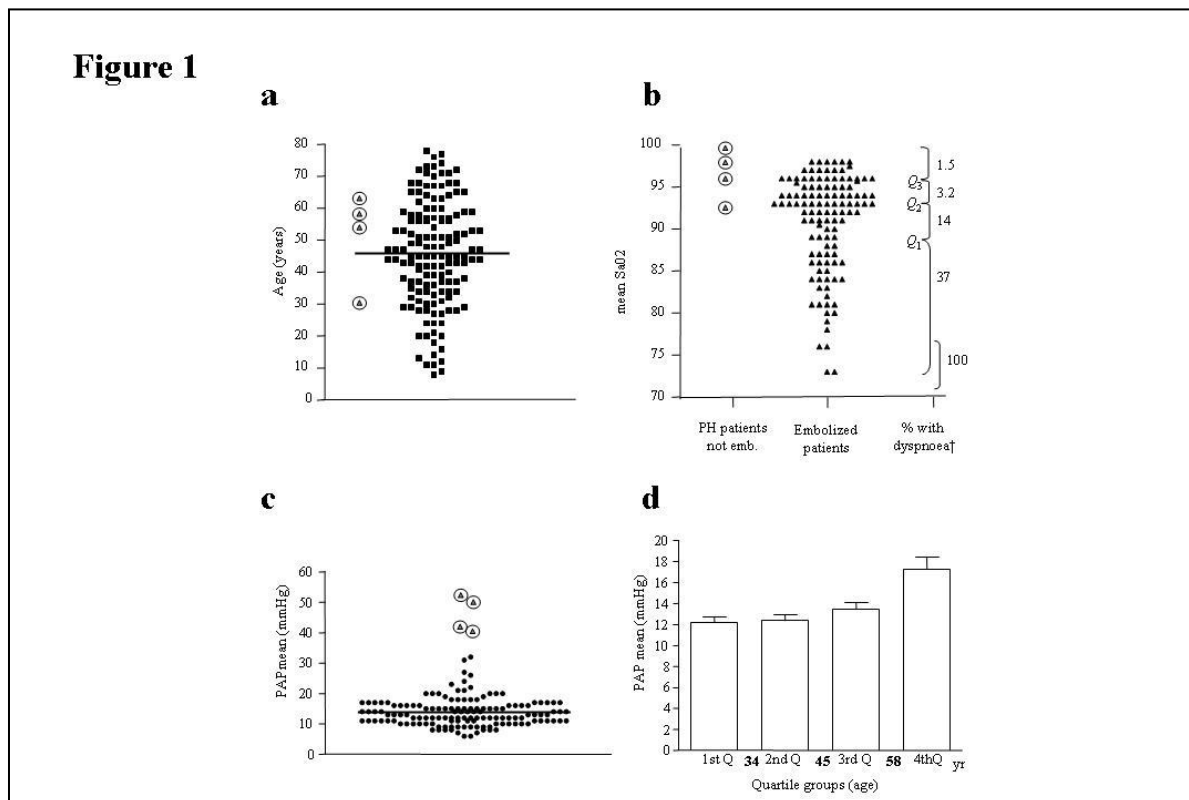


Figure 1: Baseline characteristics of study population

Comparison of a) age, b) baseline SaO₂ (erect), and c) PAP mean for the 143 patients undergoing embolization (plain symbols), and the four patients not offered embolization (ringed symbols). For b), † symptomatic dyspnoea, and quartile groups are as reported for the 219 pulmonary AVM patients in reference [2]. d) Age-dependent increase in PAP mean in 143 patients with pulmonary AVMs.

Baseline PAP measurements (PAP systolic, diastolic and mean) varied widely as illustrated in Table 1a and Figure 1c. The distribution of the embolized patients was skewed (Figure 1c), but nevertheless, the four patients who were not offered embolization represented significant outliers. Further details of their haemodynamic variables are presented in Table 1b.

Table 1: Pulmonary haemodynamic variables in pulmonary AVM patients

a: 143 patients undergoing embolization of pulmonary AVMs

PAP (mmHg)	Median (Q1, Q3)	Mean (range)	Normal range [50]
PAP systolic	23 (19-27)	23.6 (13-60)	13-26
PAP diastolic	7 (5-9)	7.2 (0-30)	6-16
PAP mean	13 (11-16)	13.5 (6-45)	7-19

b: Four PH patients not undergoing pulmonary AVM embolization

PH Case	Age	SaO ₂ erect (%)	RAP	RVEDP	PAP sys	PAP ds	PAP mean	PC Wedge †	CO (litres/min)	CI (litres/min/m ²)	PVR (dyn sec/cm ⁵) ‡
#144	64	100	12	10	74	21	41	17	7.0	4.0	272
#145	30	95	0	8	80	30	50	2	3.3	2.3	1160
#146	59	97.5	23	9	70	40	52	25	3.1	1.7	396
#147	53	92	12	9	55	38	40	18	7.8	4.6	274

Legend: Q1, Q3: interquartile range. RAP, right atrial pressure; RVEDP, right ventricular end diastolic pressure; sys, systolic; ds, diastolic; CO, cardiac output; CI, cardiac index; PVR, pulmonary vascular resistance. Normal ranges [50]: † 5-13mmHg, ‡ 11-99 dyn s/cm⁵. Note the variety of PH phenotypes in this population: Case #144

has post capillary PH; case #145 has a PAH profile, and the other two cases display a mixed profile. High output cardiac failure secondary to hepatic AVMs was present in cases #144 and #146.

Univariate analysis of first recorded PAP measurements in the 143 embolized patients indicated that all three PAP measurements were influenced by age. For age and PAP mean, the Spearman r correlation was 0.33 (95% confidence intervals 0.17, 0.47; $p < 0.0001$), and PAP mean could be described by the equation $\text{PAP mean} = 9.88 + 0.107 * [\text{age}]$, $r^2 = 12.33\%$, $p < 0.0001$. One way analysis of variance (ANOVA) indicated significant differences in PAP between age-quartile groups (Figure 1d). Post-test analysis confirmed a linear trend ($p < 0.0001$), with significant increases occurring between the third (45-58yr) and upper (>58 yr) age quartiles (Figure 1d).

Effect of embolization

In order to test whether PAP was elevated following embolization of pulmonary AVMs, PAP measurements recorded pre-embolization were studied in all 43 patients for whom post embolization measurements were also available, either from consecutive sessions (35 patients), or from the same embolization session (8 patients).

For the 35 patients in whom measurements were made prior to consecutive embolization sessions, SaO_2 increased in all except one of the patients following embolization ($p < 0.0001$, Figure 2a). In contrast, there was no significant change in PAP as a result of embolization (Figure 2b). There was a trend towards higher PAP post embolization, but this was in part accounted for by increased patient age, as measurements were recorded at a mean interval of 19.9 (range 2-121) months.

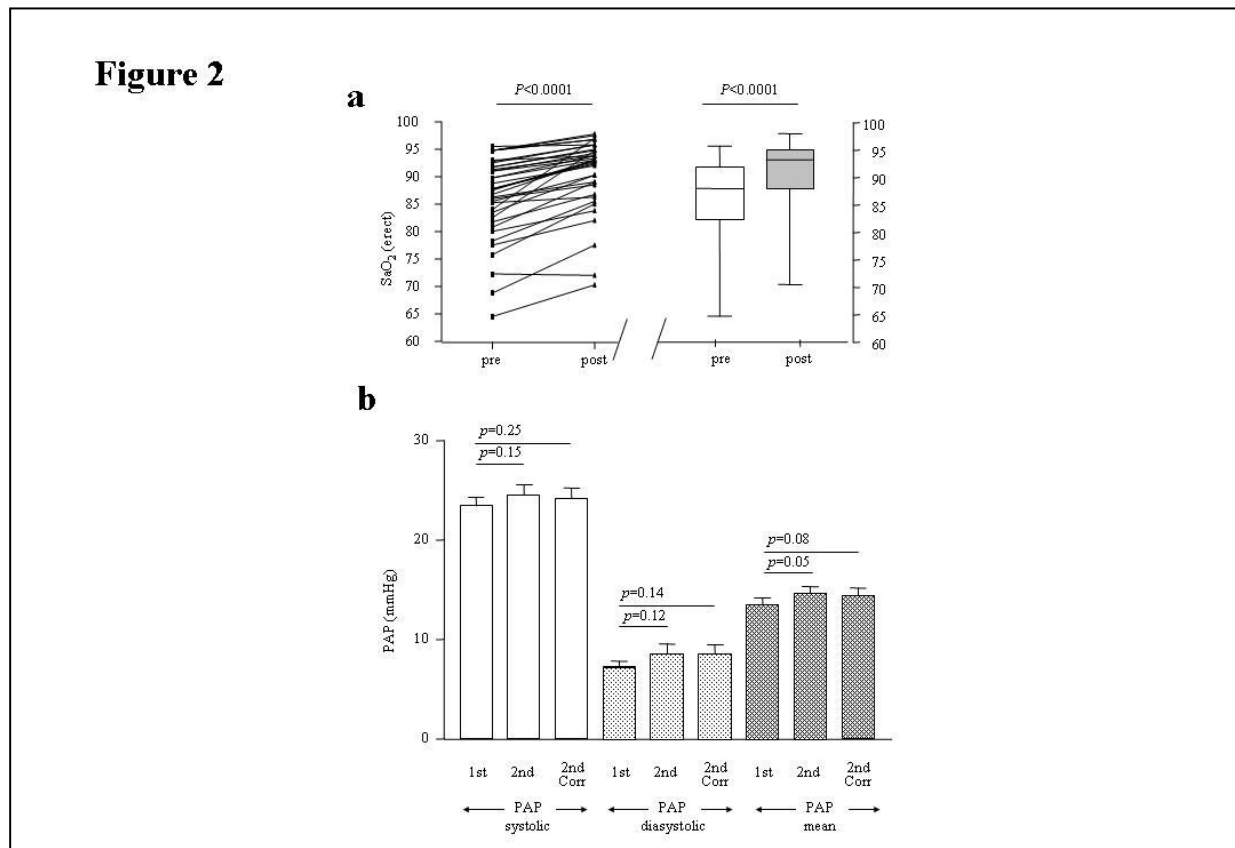


Figure 2: Effects of pulmonary AVM embolization

a) SaO₂ (erect) and b) PAP mean recorded at consecutive embolisation sessions in 35 patients. In b), age adjusted figures were calculated by $PAP\ mean = 9.88 + 0.107 \cdot [age]$ as defined in the population (see text). Overall p values did not reach significance at FDR=0.05 level [49].

Recognising that the pooled groups may have masked individual changes, individual PAP responses were examined in a subgroup of 15 patients with PAP mean in the upper quartile. In this small group, embolization resulted in a highly significant improvement in SaO₂ ($p < 0.0001$, Figure 3a). In contrast, PAP measurements recorded at a mean interval of 26 (range 13-80) months demonstrated no consistent trend, and no significant difference between pre and post embolization measurements ($p=0.76$, Figure 3b). Comparable findings were observed with PAP systolic and PAP diastolic (data not shown).

These measurements addressed whether embolization led to a sustained change in PAP. In order to explore whether there were any acute changes in PAP, nine pairs of PAP measurements recorded pre and post embolization in the same session were examined. Embolization resulted in a consistent and highly significant improvement in SaO₂ ($p=0.0039$, Figure 3c). Again PAP responses to pulmonary AVM embolization varied between individuals. In half of all patients, post embolization PAP mean was lower than prior to embolization, and overall there was no significant difference as a result of embolization ($p=0.93$, (Figure 3d). Comparable findings were observed with PAP systolic and PAP diastolic (data not shown).

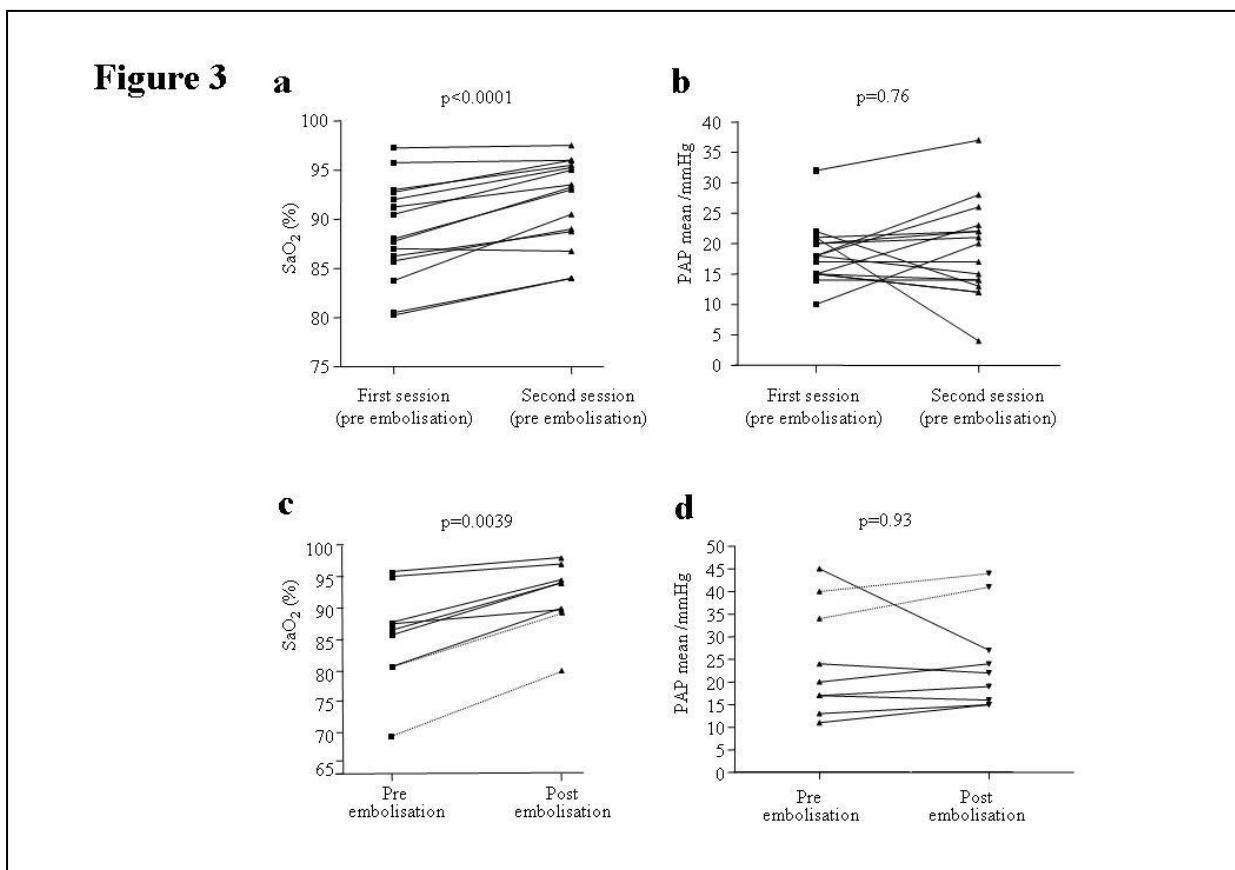


Figure 3: Individual patient details

a) SaO₂ (erect) and b) PAP mean recorded at consecutive embolisation sessions in subgroup of 15 patients with pre-existing elevated PAP mean (≥ 16 mmHg). c) SaO₂ (erect) and d) PAP mean recorded pre and post embolisation at same session in 8 patients with pre-existing elevated PAP mean (≥ 16 mmHg). The two measurements for the patient with test balloon occlusion reported in Table 2 are illustrated by dotted lines.

While overall, there were no significant increase in PAP as a result of embolization, within both groups there were occasional individuals in whom PAP did increase, by up to 8mmHg between consecutive sessions, and up to 4mmHg during the same session. It may be helpful to be able to identify these rare individuals prior to embolization. Others have suggested test occlusion of the pulmonary AVM before definite embolization [32]. This technique was tried for one patient early in the series. Balloon occlusion increased SaO₂ to a similar degree as eventual complete embolization (Table 2). This test occlusion did not significantly increase PAP whereas PAP were significantly higher following maximal embolization.

Table 2: Comparison of balloon test occlusion and pulmonary AVM embolization

Date	Day 0 pre	Day 0 (post balloon)	Day 8 pre Session 1	Day 8 post PAVM emb.	Day 169 pre Session 2	Day 169 post PAVM emb.	Change post balloon	Change post complete emb.
SaO ₂ (%)	67	85	69	80	81	89	+18	+22
PAP sys (mmHg)	47	50	54	60	57	63	+3	+16
PAP d/s (mmHg)	0	0	24	32	27	35	0	+35
PAP mean (mmHg)	22	25	34	41	36	44	+3	+22

Legend: Emb. Embolization. Test occlusion (stable for 5 minutes), and subsequent data following two separate PAVM embolization sessions in a 65 year old man with pulmonary hypertension secondary to left ventricular disease. The embolization sessions reduced the right to left shunt from 18% to 13.3% (session 1), then to undetectable levels (session 2). In session 1, embolization was curtailed due to the rise in PAP.

DISCUSSION

The key finding of this study was that embolization of pulmonary AVMs did not lead to a consistent increase in resting PAP in a series which excluded individuals with severe pulmonary arterial hypertension.

The strengths of the study included the relatively large patient group, correction for age which could have been an important confounding variable in assessments over consecutive embolization sessions, and strong evidence of embolization efficacy. Weaknesses include the retrospective nature of the study, and reliance on measurements performed for clinical purposes such that pulmonary vascular resistance (PVR) measurements, and same-session repeat measurements following embolization were not available for the majority of patients. In addition, the study was only powered to address consistent changes pre and post embolization.

Within the study limitations, in our series, embolization of pulmonary AVMs did not generally increase PAP, even in the setting of mild-to-moderate pre-existing pulmonary hypertension. No patient developed clinical PAH (i.e. right-heart failure) after embolization in this series

We were surprised by the significant fall in PAP in one patient with pre-existing pulmonary hypertension attributed to left ventricular disease. We were also initially surprised to see that embolization did not lead to a consistent increase in PAP in other patients, since effective embolization occludes vessels that provide a lower resistance to flow than the rest of the pulmonary vasculature [20]. None of the patients illustrated in Figure 3 were known to have hepatic AVMs, and this may explain the differences between our results and those of others. Importantly however, noting that embolization leads to a reduction in cardiac output [11, 17], our data suggest that the fall in cardiac output can have a greater effect on PVR than occlusion of individual pulmonary AVMs.

While our data indicate that pulmonary AVM embolization does not necessarily lead to elevated PAP, PAP did rise in occasional individuals, rises which in this series, were not predicted by test balloon occlusion pre embolization. It is important to recognise that in the setting of severe PAH and HHT-associated hepatic AVMs, there are reports that embolization of pulmonary AVMs may precipitate fatal increase in PAP [32]. Furthermore, in addition to the previously reported cases, clinical PAH did develop in another patient in our series [2] in the years following pulmonary AVM resection and embolization at another institution.

Our interpretation of these considerations, and our observations from the series reported here and elsewhere [2], is that for patients with pre-existing severe pulmonary arterial hypertension, the risks of pulmonary AVM embolization outweigh potential benefits: The main indications for pulmonary AVM embolization are to reduce the risk of paradoxical embolic stroke, and, for individuals with hypoxaemia, to improve dyspnoea, and exercise tolerance. We have recently shown that the risk of paradoxical embolic stroke is substantially lower in individuals with higher PAP [2]. Furthermore, the data reported here serve as a reminder that pulmonary AVMs generally result in symptomatic dyspnoea only when resting SaO₂ are <80%, suggesting perhaps that symptomatic relief should not be expected for patients with pulmonary hypertension and SaO₂ >90% as was the case in all four excluded patients in our series. In our experience, the most difficult judgements relate to individuals with elevated pulmonary artery pressure and major haemoptysis, a consideration that was not required for the four individuals with PH in this series.

In summary, these data are a useful adjunct to case reports indicating increased PAP post embolization, and indicate that embolization may be undertaken with caution in the presence of pre-existing mild to moderate pulmonary hypertension in selected individuals.

ACKNOWLEDGEMENTS

This work was supported by donations from families and friends of HHT patients. We are also grateful for support from the NIHR Biomedical Research Centre Funding Scheme. The funding sources played no part in the decision to submit the manuscript for publication. We thank Dr Karen Sheares for provision of two sets of haemodynamic data for Table 1b.

REFERENCES

1. Hewes RC, Auster M, White RI. Cerebral embolism- first manifestation of pulmonary arteriovenous malformation in patients with hereditary hemorrhagic telangiectasia. *Cardiovasc Intervent Radiol* 1985; 8: 151-5.
2. Shovlin CL, Jackson JE, Jenkins IH, Bamford K, Benjamin A, Ramadan H, Kulinskaya E. Primary determinants of ischaemic stroke and cerebral abscess are unrelated to severity of pulmonary arteriovenous malformations in HHT. *Thorax* 2007 Nov 2 [Epub ahead of print].
3. Cottin V, Plauchu H, Bayle J-Y, Barthelet M, Revel D, Cordier JF. Pulmonary arteriovenous malformations in patients with hereditary hemorrhagic telangiectasia. *Am J Respir Crit Care Med* 2004;169(9):994-1000.
4. Gupta P, Mordin C, Curtis J, Hughes JMB, Shovlin CL, Jackson JE. Pulmonary arteriovenous malformations: Effect of embolization on right-to-left shunt, hypoxaemia and exercise tolerance in 66 patients. *Am J Roent* 2002;179:347-55.
5. Taylor B, Cockerill E, Manfredi F, Klatte E. Therapeutic embolization of the pulmonary artery in pulmonary arteriovenous fistula. *Am J Med* 1978;64:360-365.
6. Terry P, White R, Barth K, Kaufman S, Mitchell S. Pulmonary arteriovenous malformations: Physiologic observations and results of balloon embolisation. *N Engl J Med* 1983;308:1197-1200.
7. Hartnell G, Allison D. Coil embolization in the treatment of arteriovenous malformations. *J Thoracic Imaging* 1989;4:81-85.
8. Jackson J, Whyte M, Allison D, Hughes J. Coil embolization of pulmonary arteriovenous malformations. *Cor Vasa* 1990;32:191-196.
9. Pennington D, Gold W, Gordon R, Steiger D, Ring E, Golden J. Treatment of pulmonary arteriovenous malformations by therapeutic embolization. *Am Rev Resp Dis* 1992;145:1047-1051.
10. Dutton JAE, Jackson JE, Hughes JMB, Whyte MKB, Peters AM, Ussov W, Allison DJ. Pulmonary arteriovenous malformations: results of treatment with coil embolization in 53 patients. *Am J Roent* 1995;165:1119-1125.

11. Andrivet P, Lofaso F, Carette M-F, Allegrini J, Adnot S. Haemodynamics and gas exchange before and after coil embolization of pulmonary arteriovenous malformations. *Eur Respir J* 1995;8:1228-1230.
12. Haitjema TJ, Overtom TTC, Westermann CJJ, Lammers JWJ. Embolisation of pulmonary arteriovenous malformations: results and follow-up in 32 patients. *Thorax* 1995;50:719-723.
13. Andersen PE, Kjeldsen AD, Oxhøj H, Vase P, White R. Embolotherapy for pulmonary arteriovenous malformations in patients with Hereditary Haemorrhagic Telangiectasia. *Acta Radiologica* 1998;39:723-726.
14. Lee D, White R, Egglin T, Pollak J, Fayad P, Wirth J, et al. Embolotherapy of large pulmonary arteriovenous malformation: long term results. *AnnThor Surg* 1997;64:930-40.
15. Sagara K, Miyazono N, Inoue H, Ueno K, Nishida H, Nakajo M. Recanalization after coil embolotherapy of pulmonary arteriovenous malformations: Study of long term outcome and mechanism for recanalization. *Am J Roent* 1998;170:727-730.
16. Gershon A, Faughnan M, Chon K, Pugash R, Clark J, Bohan M, et al. Transcatheter embolotherapy of maternal pulmonary arteriovenous malformations during pregnancy. *Chest* 2001;119:470-477.
17. Terry P, Barth K, Kaufman S, White R. Balloon embolization for the treatment of pulmonary arteriovenous fistulas. *New Engl J Med* 1980;302:1189-1190.
18. Ference BA, Shannon TM, White RI Jr, Zawin M, Burdge CM. Life-threatening pulmonary hemorrhage with pulmonary arteriovenous malformations and hereditary hemorrhagic telangiectasia. *Chest*. 1994; 106:1387-90
19. Shovlin CL, Simonds AK, Hughes JMB. Pulmonary disease and cor pulmonale. In: Oakley C, Warnes CA Eds. Heart disease and pregnancy, 2nd edition. Oxford, Blackwell 2007, 151-172.
20. Whyte MKB, Hughes JMB, Jackson JE, Peters AM, Hempleman SC, Moore DP, Jones HA. Cardiopulmonary response to exercise in patients with intrapulmonary vascular shunts. *J Appl Physiol* 1993;75(1):321-328.

21. Shovlin CL, Guttmacher AE, Buscarini E, Faughan M, Hyland R, Westermann CJJ, Kjeldsen AD, Plauchu H. Diagnostic criteria for hereditary haemorrhagic telangiectasia (Rendu-Osler-Weber syndrome). *Am J Med Genet.* 2000; **91**: 66-67.
22. Trembath R, Thomson J, Machado R, Morgan N, Atkinson C, Winship I, et al. Clinical and molecular features of pulmonary hypertension in hereditary hemorrhagic telangiectasia. *New Engl J Med* 2001;345:325-334.
23. Sapru R, Hutchison D, Hall J. Pulmonary hypertension in patients with pulmonary arteriovenous fistulae. *Br Heart J* 1968;31:559.
24. le Roux B, Gibb B, Wainwright J. Pulmonary arteriovenous fistula with bilharzial pulmonary hypertension. *Br Heart J* 1970;32:571-4.
25. Trelle E, Johansson BW, Linell F, Ripa J. Familial pulmonary hypertension and multiple abnormalities of large systemic arteries in Osler's disease. *Am J Med* 1972;53:50-63.
26. Chow L, Chow W, Ma K. Pulmonary arteriovenous malformation. Progressive enlargement with replacement of the entire right middle lobe in a patient with concomitant mitral stenosis. *Med J Aus* 1993;158:632-634.
27. Olivieri C, Lanzarini L, Pagella F, Semino L, Corno S, Valacca C, et al. Echocardiographic screening discloses increased values of pulmonary artery systolic pressure in 9 of 68 unselected patients affected with hereditary hemorrhagic telangiectasia. [*Genetics in Medicine.* 2006;8:183-190.
28. Harrison RE, Flanagan JA, Sankelo M, Abdalla SA, Rowell J, Machado RD, et al. Molecular and functional analysis identifies ALK-1 as the predominant cause of pulmonary hypertension related to hereditary haemorrhagic telangiectasia. *J Med Genet* 2003;40:865-871.
29. Abdalla SA, Gallione CJ, Barst RJ, Horn EM, Knowles JA, Marchuk DA, et al. Primary pulmonary hypertension in families with hereditary haemorrhagic telangiectasia. *Eur Respir J* 2004;23:373-7.
30. Chaouat A, Coulet F, Favre C, Simonneau G, Weitzenblum E, Soubrier F, Humbert M. Endoglin germline mutation in a patient with hereditary haemorrhagic telangiectasia and dexfenfluramine associated pulmonary arterial hypertension. *Thorax* 2004;59:446-448.

31. Simonneau G, Galie N, Rubin L, Langleben D, Seeger W, Dominighetti G, Gibbs JSR, et al. Clinical classification of pulmonary hypertension. *J Am Coll Cardiol* 2004;43(12 Suppl):5S-12S.
32. Haitjema T, ten Berg J, Overtom J, Ernst J, Westermann CJJ. Unusual complications after embolization of a pulmonary arteriovenous malformation. *Chest* 1996;109:1401-1404.
33. Letteboer TG, Mager JJ, Snijder RJ, Koeleman BP, Lindhout D, Ploos van Amstel JK, Westermann CJJ. Genotype-phenotype relationship in hereditary haemorrhagic telangiectasia. *J Med Genet* 2006;43:371-7.
34. Porstmann W. Therapeutic embolization of arteriovenous pulmonary fistulas by catheter technique. In: Kelop O, Editor. Current concepts in pediatric radiology. Berlin: Springer; 1977. 23-31.
35. Kaufman S, Strandberg J, Barth K, Gross G, White R. Therapeutic embolization with detachable silicone balloons: Long term effects in swine. *Invest Radiol* 1978;14:157-161.
36. Barth K, White R, Kaufman S, Terry P, Roland J-M. Embolotherapy of pulmonary arteriovenous malformations with detachable balloons. *Radiology* 1982;142:599-606.
37. Remy-Jardin M, Wattine L, Remy J. Transcatheter occlusion of pulmonary arterial circulation and collateral supply: failures, incidents, and complications. *Radiology* 1991;180:699-705.
38. Pollak J, Egglin T, Rosenblatt M, Dickey K, White R. Clinical results of transvenous systemic embolotherapy with a neuroradiologic detachable balloon. *Radiology* 1994;191:477-482.
39. Saluja S, Sitko I, Lee DW, Pollak J, White RI. Embolotherapy of pulmonary arteriovenous malformations with detachable balloons: long term durability and efficacy. *J Vasc Intervent Radiol* 1999;10:883-889.
40. Faughnan ME, Thabet A, Mei-Zahav M, Colombo M, Maclusky I, Hyland RH, et al. Pulmonary arteriovenous malformations in children: outcomes of transcatheter embolotherapy. *J Pediatr Surg* 2004;145:826-31.

41. Pollak JS, Saluja S, Thabet A, Henderson KJ, White RI. Clinical and anatomic outcomes after embolotherapy of pulmonary arteriovenous malformations. *Journal of Vascular and Interventional Radiology* 2006;17:35-45.
42. Cottin V, Chinet T, Lavolé A, et al. Pulmonary arteriovenous malformations in hereditary hemorrhagic telangiectasia patients: a series of 126 patients. *Medicine (Baltimore)* 2007;86(1):1-17.
43. Rodan BA, Goodwin JD, Chen JT, Ravin CE. Worsening pulmonary hypertension after resection of arteriovenous fistula. *Am J Roentgenology* 1981;137:864-867.
44. Shovlin CL, Sulainam NL, Govani FS, Jackson JE, Begbie ME. Elevated Factor VIII in hereditary haemorrhagic telangiectasia (HHT): association with venous thromboembolism. *Thromb Haemost* 2007;98:1031-9.
45. Thompson RD, Jackson J, Peters AM, Doré CJ, Hughes JMB. Sensitivity and specificity of radioisotope right-left shunt measurements and pulse oximetry for the early detection of pulmonary arteriovenous malformations. *Chest* 1999;115:109-113.
46. Holmgren A, Jonsson B, Sjostrand T. Circulatory data in normal subjects at rest and during exercise in recumbent position, with special reference to the stroke volume at different work intensities. *Acta Physiol Scand* 1960;49:343-363.
47. Granath A, Strandell T. Relationships between cardiac output, stroke volume and intracardiac pressure at rest and during exercise in supine position and some anthropometric data in healthy old men. *Acta Medica Scandinavica* 1964;176:447-466.
48. McQuillan MM, Picard MH, Leavitt M, Weyman AE. Clinical correlates and reference intervals for pulmonary artery systolic pressure among echocardiographically normal subjects. *Circulation* 2001;104:2792-2802.
49. Benjamini Y, Hochberg Y. Controlling the False Discovery Rate: a practical and powerful approach to multiple testing. *J Roy Stats Soc (B)* 1995;57:289-300.
50. Naeije R. Pulmonary vascular function. In: Peacock AJ, Rubin LJ, editors. *Pulmonary Circulation*. London: Arnold; 2004. p. 3-13.

