

Sim, D. A., Keane, P. A., Zarranz-Ventura, J., Fung, S. S. M., Powner, M. B., Platteau, E., Bunce, C. V., Fruttiger, M., Patel, P. J., Tufail, A. & Egan, C. A. (2013). The effects of macular ischemia on visual acuity in diabetic retinopathy. *Investigative Ophthalmology & Visual Science*, 54(3), pp. 2353-2360. doi: 10.1167/iovs.12-11103



**CITY UNIVERSITY
LONDON**

[City Research Online](http://www.city.ac.uk/researchonline)

Original citation: Sim, D. A., Keane, P. A., Zarranz-Ventura, J., Fung, S. S. M., Powner, M. B., Platteau, E., Bunce, C. V., Fruttiger, M., Patel, P. J., Tufail, A. & Egan, C. A. (2013). The effects of macular ischemia on visual acuity in diabetic retinopathy. *Investigative Ophthalmology & Visual Science*, 54(3), pp. 2353-2360. doi: 10.1167/iovs.12-11103

Permanent City Research Online URL: <http://openaccess.city.ac.uk/15237/>

Copyright & reuse

City University London has developed City Research Online so that its users may access the research outputs of City University London's staff. Copyright © and Moral Rights for this paper are retained by the individual author(s) and/ or other copyright holders. All material in City Research Online is checked for eligibility for copyright before being made available in the live archive. URLs from City Research Online may be freely distributed and linked to from other web pages.

Versions of research

The version in City Research Online may differ from the final published version. Users are advised to check the Permanent City Research Online URL above for the status of the paper.

Enquiries

If you have any enquiries about any aspect of City Research Online, or if you wish to make contact with the author(s) of this paper, please email the team at publications@city.ac.uk.

The Effects of Macular Ischemia on Visual Acuity in Diabetic Retinopathy

Dawn A. Sim,^{1,2} Pearse A. Keane,^{1,2} Javier Zarranz-Ventura,^{1,2,4} Simon Fung,¹ Michael B. Powner,² Elise Platteau,^{1,3} Catey V. Bunce,^{1,2} Marcus Fruttiger,² Praveen J. Patel,^{1,2} Adnan Tufail,^{1,2} and Catherine A. Egan¹

PURPOSE. To investigate the impact of diabetic macular ischemia (DMI) on visual acuity (VA), through the analysis of novel fluorescein angiography (FA) parameters.

METHODS. Data were retrospectively collected over a 6-month period. DMI severity was graded using Early Treatment Diabetic Retinopathy Study (ETDRS) protocols. Custom software was used to quantify areas of the foveal avascular zone (FAZ), and of capillary nonperfusion over the papillomacular nerve fiber layer bundle, and temporal macula, and associations tested with VA.

RESULTS. A total of 488 patients with type 2 diabetes mellitus and FAs of sufficient quality to allow detailed quantitative analyses were included. ETDRS-DMI severity was graded as: none, 39.7%; questionable, 18.4%; mild, 25.2%; moderate, 11.0%; and severe, 5.6%. Median FAZ areas were 0.19 mm² (interquartile range [IQR], 0.13–0.25); 0.25 mm² (IQR, 0.18–0.32); 0.27 mm² (IQR, 0.19–0.38); 0.32 mm² (IQR, 0.25–0.54); and 0.78 mm² (IQR, 0.60–1.32), respectively, and were significantly different between all grades ($P < 0.002$), apart from “questionable” versus “mild” grades. Significant association of VA to FAZ area was observed only in the moderate ($\beta = 0.406$, SE = 0.101, $P = 0.001$) and severe ($\beta = 0.299$, SE = 0.108, $P = 0.006$) subgroups, but not in milder ETDRS-DMI grades. A strong association with VA was observed in cases with papillomacular ischemia ($\beta = 1.123$, SE = 0.355, $P = 0.005$), independent of FAZ size or the presence of macular edema.

CONCLUSIONS. Diabetic macular ischemia is associated with reduced VA in eyes with moderate to severe ETDRS-DMI grades of ischemia but preserved in milder grades. In addition, we

describe the independent association of papillomacular nerve fiber bundle ischemia with reduced VA. (*Invest Ophthalmol Vis Sci.* 2013;54:2353–2360) DOI:10.1167/iovs.12-11103

Diabetic macular ischemia (DMI) is an important cause of visual impairment in patients with diabetic retinopathy^{1,2}—in large part due to the devastating and irreversible visual loss that it causes in a minority of cases.³ DMI is best-visualized using fluorescein angiography (FA), and is characterized by enlargement and disruption of the foveal avascular zone (FAZ), and by retinal capillary loss in other, noncontiguous areas of the macula (“capillary drop-out”).^{4–6} Standards for assessment of DMI severity were first established in the Early Treatment Diabetic Retinopathy Study (ETDRS) in the 1980s.⁵ Since then, numerous studies have demonstrated a link between the presence of DMI and the loss of visual function.^{3,7–10} Furthermore, other studies suggest that, in patients receiving treatment for diabetic macular edema (DME), the coexistence of DMI may have an adverse effect on outcomes, or limit the benefits of treatments, regardless of whether the treatment consists of laser photocoagulation or intravitreal pharmacotherapies.^{2,11,12}

Although the deleterious effects of DMI—both from clinical studies, and from the weight of experience in clinical practice—are well established, much remains uncertain. In particular, the effects of DMI on visual function are ill defined, with some patients demonstrating near normal levels of visual acuity in the presence of profound ischemia.³ Such patients can experience sudden and severe decreases in visual acuity with small increases in disease severity; in most cases, the tipping point for such changes is not obvious. In addition, the effects of DMI on treatment outcomes remain equivocal. Although some small studies have suggested a negative effect,^{2,11,12} larger prospective studies, such as ETDRS and the RESTORE study, have not demonstrated clear associations between decreased treatment benefit and increased macular ischemia.^{13,14} These contrasting results may be related, in part, to the adoption in many studies of simplified DMI grading schemes, commonly eschewing detailed quantitative analyses of capillary loss for qualitative analysis of the FAZ.^{12,15} Finally, due to the requirement of angiography for its evaluation, DMI has not been studied in the pivotal epidemiological studies of diabetic retinopathy.^{16–18} Thus, the prevalence and natural history of this condition remains unknown.

In this report, we perform in-depth qualitative and quantitative analyses of macular ischemia, both in the central macula and paramacular areas, in a large cohort of patients with type 2 diabetes mellitus. We also correlate these changes with visual acuity in an effort to determine their visual significance and to identify novel parameters of interest for future clinical trials.

From the ¹Moorfields Eye Hospital NHS Foundation Trust, London, United Kingdom; the ²University College London, Institute of Ophthalmology, London, United Kingdom; the ³Department of Ophthalmology, Ghent University Hospital and Ghent University, Ghent, Belgium; and the ⁴Department of Ophthalmology, Clínica Universidad de Navarra, Pamplona, Navarra, Spain.

Supported by Fight For Sight UK, Grant 1987 (DAS, MF); the Department of Health's NIHR Biomedical Research Centre for Ophthalmology at Moorfields Eye Hospital and UCL Institute of Ophthalmology (PAK, PJP, CAE, DAS, AT); and a Spanish Retina and Vitreous Society (Sociedad Española de Retina y Vítreo, SERV) grant (JZV).

Submitted for publication October 8, 2012; revised December 10, 2012 and January 22, 2013; accepted February 18, 2013.

Disclosure: **D.A. Sim**, None; **P.A. Keane**, None; **J. Zarranz-Ventura**, None; **S. Fung**, None; **M.B. Powner**, None; **E. Platteau**, None; **C.V. Bunce**, None; **M. Fruttiger**, None; **P.J. Patel**, None; **A. Tufail**, None; **C.A. Egan**, None

Corresponding author: Catherine A. Egan, Moorfields Eye Hospital NHS Foundation Trust, 162 City Road, London EC1V 2PD, UK; Catherine.Egan@moorfields.nhs.uk.

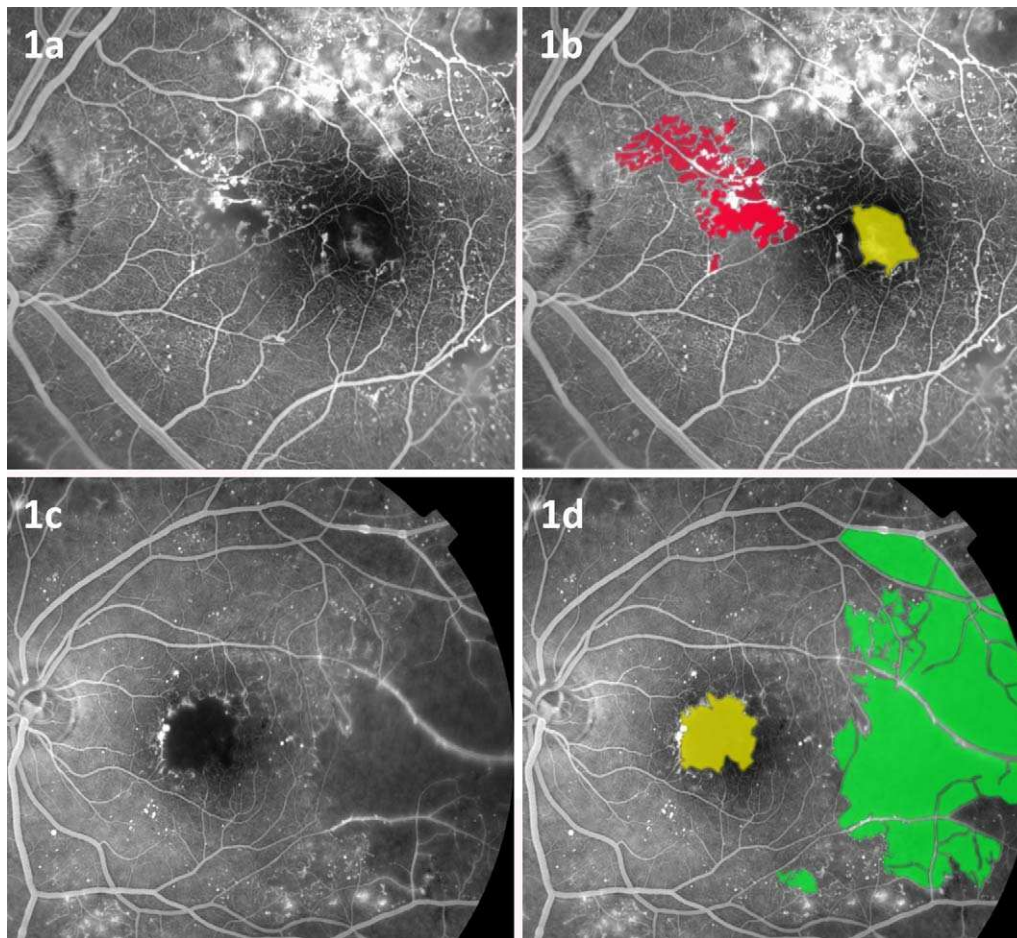


FIGURE 1. (a) An example of an early phase fundus FA image centered at the macula demonstrating papillomacular capillary dropout, noncontiguous with the FAZ. (b) Annotated image of (a) with papillomacular ischemia highlighted in *red* and the enlarged FAZ highlighted in *yellow*. (c) An example of an early phase FA image demonstrating temporal capillary dropout noncontiguous with the FAZ. (d) Annotated image of (c) with temporal ischemia highlighted in *green* and the enlarged FAZ highlighted in *yellow*.

MATERIALS AND METHODS

Inclusion Criteria and Data Collection

Clinical and imaging data were collected retrospectively over a 6-month time period, from patients attending a single consultant-led (CE) medical retinal clinic, with a focus on diabetic eye disease. Approval for data collection and analysis was obtained from the Moorfields Eye Hospital research and ethics committee and adhered to the tenets set forth in the Declaration of Helsinki.

Consecutive patients referred from the United Kingdom National Screening Committee (UK NSC) - Diabetic Eye Screening Programme, with a diagnosis of type 2 diabetes mellitus, who underwent an FA within 6 months of the study period were included. (Patients with Type 1 diabetes mellitus are being analyzed in a separate study.) Patient demographic data, visual acuities, and retinopathy/maculopathy grades (at the time of FA), were obtained from the UK NSC standardized electronic reports, a grading system which has been described in more detail elsewhere.²⁰ Patient age at time of attendance, and presence of ocular comorbidity, were obtained from diagnostic labels, electronic patient records and FAs. Patients with ocular comorbidities—including retinal arterial or venous occlusion, epiretinal membrane, neovascular AMD, inherited macular disease, intermediate and posterior uveitis, or macular scarring of any etiology—were excluded.

In most cases, FA images were obtained on the date of attendance in the clinic; however, patients were also included in the study if angiography had been performed within 6 months of the study

attendance date. In patients with bilateral disease of symmetrical severity, a single eye was selected using permuted-block randomization for inclusion in the study. In patients with bilateral asymmetrical disease, the eye with the greatest degree of ischemic maculopathy was selected.

Acquisition and Analysis of Fluorescein Angiograms

Grading Methods for Macular Ischemia. All angiographic images were acquired with a digital retinal camera system (Topcon TRC 50IX; Topcon Medical Systems, Inc., Paramus, NJ). FA images centered on the macula were chosen for optimal focus and intensity levels, which allowed visualization of macular capillaries. No image manipulation was performed prior to grading. Macular ischemia was dual-graded by two masked assessors (DAS and EP) using protocols and standard photographs from ETDRS Report No. 11.⁵ According to these criteria, DMI was classified as none, questionable, mild, moderate, or severe. In the case of disagreement between graders, open adjudication was used to resolve the final grading decision.

Grading Methods for Temporal and Papillomacular Ischemia. The presence of additional areas of capillary nonperfusion, noncontiguous with the FAZ, was also noted at the time of grading, “papillomacular ischemia” was defined by its location within the nasal quadrant of the ETDRS grid and/or the area of retina bordered by the temporal edge of the optic disc and the nasal edge of the FAZ, along the

papillomacular nerve fiber raphe (Figs. 1a, 1b, 2a, 2b). “Temporal ischemia” was defined as the area located one disc diameter temporal to the central fovea and within the superior and inferior temporal vascular arcades (Figs. 1c, 1d, 2a). The boundaries of these areas were visualized in postmortem human eye tissue which was fixed in paraformaldehyde 4% and the retinal nerve fiber layer immunostained with tubulin beta III. The locations of both “PM” and “temporal” areas were defined according to distinctive patterns of the retinal nerve fiber layer, (illustrated in Fig. 2) and overlaid onto equivalent areas on FA images.

Quantification of the FAZ and Other Areas of Capillary Nonperfusion. Quantitative analysis of all images was performed using a validated image viewer and grading software package (“GRADOR”; Doheny Image Reading Center, Los Angeles, CA) that facilitates planimetric measurements. Using this software, the areas of the FAZ, and other areas of capillary nonperfusion, were assessed in square millimeters (mm^2). Temporal and papillomacular ischemia were calculated in a similar fashion.

Statistical Analysis

Clinical and imaging data were analyzed with frequency and descriptive statistics. Snellen visual acuities were converted to logMAR (logarithm of the minimum angle of resolution) visual acuity for the purposes of statistical analysis. The Mann-Whitney *U* test and Spearman’s correlation (ρ) were used to assess the relationships areas of ischemia and visual acuity. Normality of the variables was examined using histograms. As anticipated, distribution of visual acuity and FAZ measurements were negatively skewed and traditional regression analyses could not be applied to the data set. No simple transformation of data redressed the skewness.

Multivariable quantile regression analysis was used to test for associations between logMAR visual acuity and each of the following: age, sex, retinopathy grade, diabetic macular edema, FAZ measurements, and noncontiguous areas of ischemia. Quantile regression is a statistical approach to model different sample percentiles or “quantiles” of an outcome variable with respect to predictor variables, and is robust to nonparametric distributions of data. This approach has been described in more detail elsewhere.²¹ Briefly, the interpretation of quantile regression is similar to linear regression, but where linear regression models the mean of the outcome variable, quantile regression models selected percentiles (e.g., the 0.50 quantile [the median, or 50th percentile]). In this study, we analyzed the 0.10, 0.25, 0.50, 0.75, and 0.90 quantiles. This allowed the analysis of more complex relationships between variables (such as VA), which may have unequal variation for different ranges of another variable (e.g., FAZ). We developed models for each DMI ischemia grade, and further adjusted for potential confounders such as age (continuous variable); sex; retinopathy grade; and the presence of diabetic macular edema (categorical variables). “ β ” indicates the quantile regression coefficient and *P* values < 0.05 were considered statistically significant. Statistical analysis was performed using statistical software (R 2.15.0; <http://cran.r-project.org>, in the public domain), with the addition of the “quantreg” package.

RESULTS

Baseline Characteristics

Electronic records of 2051 appointments were screened, and 488 patients with type 2 diabetes met the inclusion criteria. The male to female ratio was 5:4, and mean age was 64.2 years (SD = 12.6). An attempt was made to grade both eyes for severity of DMI. In 401 patients, FA images were of sufficient quality to allow DMI grading in both eyes; in an additional 52 patients, DMI grading was possible in a single eye only. In 35 patients, FA images were of insufficient quality to permit grading of DMI in either eye. Forty-six patients were then excluded due to the

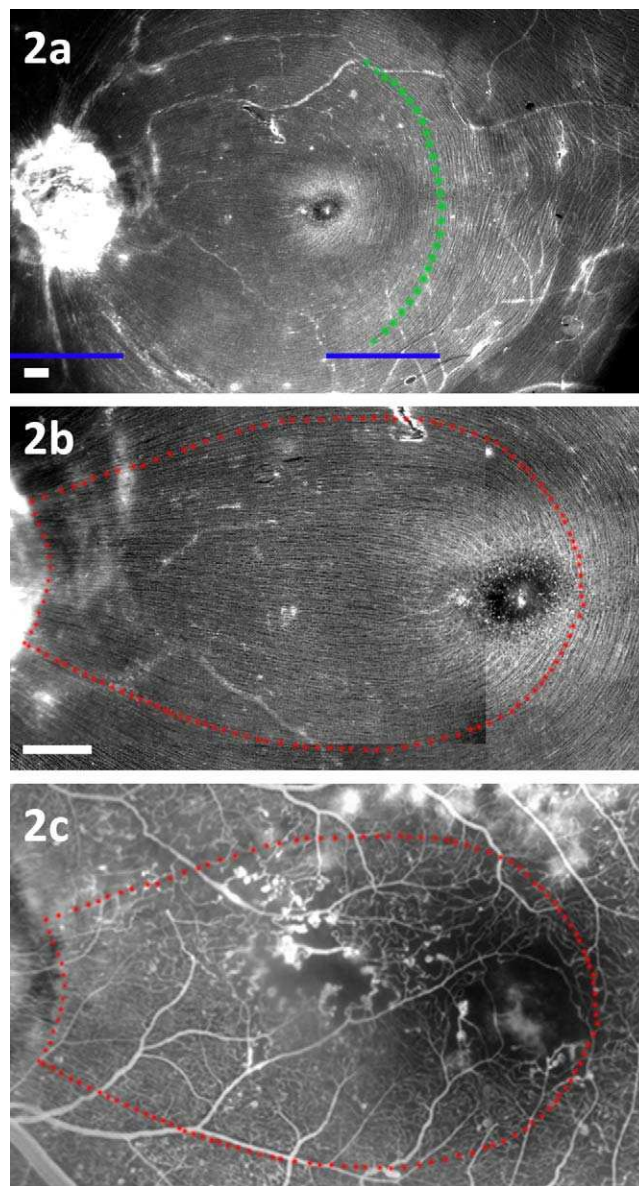


FIGURE 2. (a) Tubulin beta III immunostaining of the retinal nerve fiber layer in postmortem human eye tissue. After fixation in 4% paraformaldehyde for 24 hours, the retina was dissected and whole mounted for immunohistochemistry. The *dotted green line* delineates the boundary for temporal ischemia, located one disc diameter temporal to the central fovea. *Solid blue lines* represent one disc diameter. *Solid white scale bars* equal to 0.5 mm. (b) The *dotted red line* delineates the boundary for the papillomacular area where increased density of nerve fibers/axons originating from the FAZ are located. *Solid white scale bars* equal to 0.5 mm. (c) Overlay of equivalent papillomacular boundary onto FA depicting areas of capillary dropout.

presence of ocular comorbidities. In total, 408 eyes from 408 patients were included in the analysis. For this assessment of DMI severity, substantial intergrader agreement was demonstrated, with a weighted kappa of 0.704. (SE = 0.087, 95% confidence interval [CI] = 0.535–0.874).

Symmetry of Disease

Within the 401 patients where both eyes were gradable, 249 patients (62.1%) had bilaterally symmetrical macular ischemia.

TABLE 1. Patient Demographics and Clinical Characteristics of Patients with and without DMI

	No DMI, n = 162	DMI, n = 246	P Value
Age, y, mean (SD)	62 (11.4)	64 (12.2)	0.07
Sex, n, female/male	72/90	105/141	0.63
Eye, n, right/left	84/78	126/120	0.94
FAZ area, mm ² , median (IQR)	0.19 (0.13–0.25)	0.29 (0.20–0.42)	<0.001
Retinopathy grades (%) ^a			
No DR, n = 44	24 (54.5)	20 (45.5)	0.83
Mild-moderate NPDR, n = 139	75 (54.0)	64 (46.0)	0.85
Severe NPDR, n = 67	27 (40.3)	40 (59.7)	1.48
PDR, n = 158	36 (22.8)	122 (77.2)	3.39
Maculopathy grades (%)			
No DME/CSME, n = 113	55 (48.7)	58 (51.3)	1.05
DME, non-CSME; n = 120	53 (44.2)	67 (55.8)	1.44
CSME, n = 175	54 (30.6)	121 (69.4)	2.24

The difference in grade between the asymmetrical eyes was as follows: no more than one grade in 107 patients (26.7%); two grades in 32 (8%); three grades in 12 (3%); and four grades in 1 (0.2%). Where there was symmetrical disease, one eye was randomized for analysis. In asymmetrical disease (154 patients [37.9%]), the eye with the most severe DMI grade was selected.

Prevalence of Diabetic Macular Ischemia

Overall Prevalence and Severity of Diabetic Macular Ischemia by ETDRS-DMI Grade. In the 407 eyes analyzed, 162 eyes (39.7%) had none; 75 (18.4%) questionable; 103 (25.2%) mild; 45 (11.0%) moderate; and 23 (5.6%) had severe ETDRS-DMI grades.

Prevalence of DMI (by ETDRS Grade) within Different Severity Grades of Retinopathy and Maculopathy. DMI was most prevalent in eyes with proliferative diabetic retinopathy (PDR; 122/158 eyes [77.2%]); clinically significant macular edema (CSME; 121/175 eyes [69.4%]); and in eyes with DME, but without CSME (67/120 eyes [55.8%]). An increase in the proportion of eyes with DMI in relation to eyes with no DMI, expressed as the “DMI: No DMI” ratio, was seen in patients with severe nonproliferative PDR (NPDR) and PDR, and across all maculopathy grades (Table 1).

Increasing FAZ Area with ETDRS-DMI Severity Grades. As expected, the median FAZ area increased with grade of ETDRS-DMI severity. Median FAZ areas were 0.19 mm² (interquartile range [IQR], 0.13–0.25) in “none”; 0.25 mm² (IQR, 0.18–0.32) in “questionable”; 0.27 mm² (IQR, 0.19–0.38) in “mild”; 0.32 mm² (IQR, 0.25–0.54) in “moderate”; and 0.78 mm² (IQR: 0.60–1.32) in “severe” ETDRS-DMI grades. Highly significant differences in median FAZ area were seen

TABLE 2. Comparing Median FAZ Area (mm²) between all DMI Subgroups

DMI Subgroups	P Values				
	None	Questionable	Mild	Moderate	Severe
None					
Questionable	<0.001*				
Mild	<0.001*	0.18			
Moderate	<0.001*	<0.001*	0.002*		
Severe	<0.001*	<0.001*	<0.001*	<0.001*	

P values significant at 1% levels are indicated with *.

across all subgroups of DMI, with the exception of “questionable” versus “mild” ETDRS-DMI grades (Table 2, Fig. 3).

Prevalence of Temporal and/or Papillomacular Ischemia. Temporal and papillomacular areas of ischemia were calculated using templates derived from nerve fiber layer analysis in the postmortem human eye, and superimposed on FA images. The median area of temporal ischemia was 3.62 mm² (IQR, 2.10–6.66), and was present in 112/408 eyes (27.5%), while the median area of papillomacular ischemia was 0.38 mm² (IQR, 0.13–0.60) and was present in 34/408 eyes (8.3%). Both temporal and papillomacular ischemia were most prevalent in higher ETDRS-DMI grades. This was most notable for temporal ischemia, which was present in 20/23 eyes (87.0%) in the severe subgroup; 19/45 eyes (42.2%) in moderate; 41/103 eyes (39.8%) in mild; 22/75 eyes (29.3%) in questionable; and 10/162 eyes (6.2%) in none. Papillomacular ischemia was also more frequently seen with increasing severity of ETDRS-DMI subgroups, with 8/23 eyes (34.8%) in severe; 7/45 eyes (15.6%) in moderate; 11/103 eyes (10.7%) in

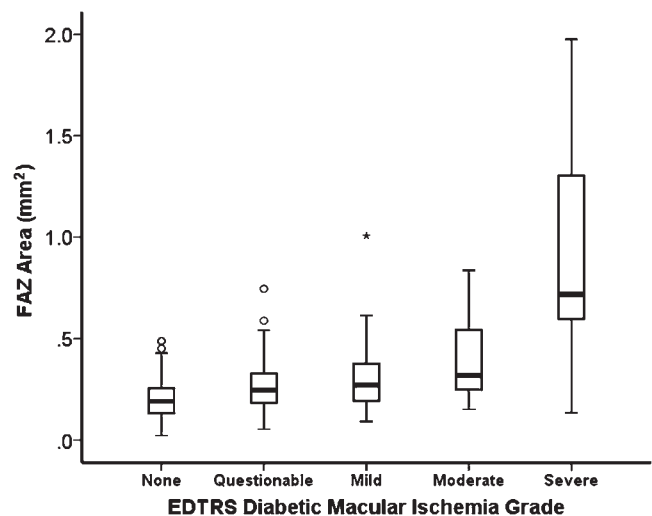


FIGURE 3. Box-plots of FAZ area (mm²) in different EDTRS grades of DMI: none, questionable, mild, moderate, and severe. The top of the box represents the 75th percentile, the bottom of the box represents the 25th percentile, and the line in the middle represents the 50th percentile. The whiskers represent the highest and lowest values that are not outliers or extreme values. Circles beyond the whiskers represent outliers and extreme values.

TABLE 3. Comparing Median Visual Acuities (LogMar) between all DMI Subgroups

DMI Grade	P Value for VA				
	None	Questionable	Mild	Moderate	Severe
None					
Questionable	0.651				
Mild	0.143	0.527			
Moderate	<0.001**	0.02*	0.03*		
Severe	<0.001**	<0.001**	<0.001**	0.04*	

P values significant at 5% level are indicated with * and ** at 1% level.

mild; 3/75 eyes (4.0%) in questionable; and 0/162 eyes in none.

Visual Significance of Macular Ischemia

Relationship between Visual Acuity and ETDRS-DMI Severity Grade. Median logMAR visual acuity (VA) was 0.2 (IQR, 0–0.3; Snellen 20/32) in eyes with “none”; 0.2 (IQR: 0–0.5; Snellen 20/32) questionable; 0.2 (IQR: 0.2–0.5; Snellen 20/32) mild; 0.5 (IQR: 0.2–0.6; Snellen 20/63) moderate; and 0.6 (IQR: 0.3–0.8; Snellen 20/80) with severe ETDRS-DMI grades. Significant differences in VA were observed between moderate and severe ETDRS-DMI grades compared with all other grades (Table 3).

Relationship between FAZ Size and Visual Acuity. Overall, we found no evidence any correlation between VA and FAZ area (mm²) ($\rho = 0.061, P = 0.219$). However, when the data were stratified by severity of ischemia, quantile regression models revealed a statistically significant association between VA and FAZ area (mm²) in all quantiles for eyes with moderate and severe ETDRS-DMI grades (Table 4, Fig. 4A). Severe DMI showed the strongest association with quantile regression coefficient, $\beta = 0.406$ (SE = 0.101, $P < 0.001$), at the 50th percentile. In moderate DMI, the greatest association was also observed at the 50th percentile, $\beta = 0.299$ (SE = 0.108, $P < 0.006$). The effects of FAZ area on VA on moderate and severe ETDRS-DMI grades for different quantiles are summarized in Table 4 and Figure 4A. No relationships were observed between VA and FAZ area for milder grades of ischemia.

Relationship of Temporal and Papillomacular Ischemia with Visual Acuity. We investigated whether papillomacular and temporal ischemia had a significant impact on VA after adjustment for FAZ area. A higher than expected association was observed in papillomacular ischemia at the

25th, 50th, 75th, and 90th quantile regression lines (Table 5, Fig. 4B), with a quantile regression coefficient of $\beta = 1.12$ (SE = 0.355, $P = 0.005$) at the 50th percentile. Thus, papillomacular ischemia has an impact on VA independent of FAZ size. This effect was maintained after adjusting for potential confounders such as DME (Table 6). No relationship was observed with temporal ischemia.

DISCUSSION

In this retrospective, cross-sectional study, we perform detailed quantitative analyses of FA images obtained from a large cohort of patients with type 2 diabetes mellitus. Using this approach, we estimate the prevalence of DMI and, when present, evaluate its visual significance. We also highlight novel angiographic parameters that, if confirmed in future longitudinal studies, may be of value for monitoring of disease, both in clinical practice and in clinical trials.

In this study, we determined the prevalence of DMI in a cohort of patients with type 2 diabetes mellitus attending a tertiary referral medical retina clinic (i.e., patients with some level of diabetic retinopathy and/or maculopathy). In this cohort, 16.6% had macular ischemic changes in the moderate to severe range, considerably higher than previously reported.¹⁹ However, the prevalence determined in our study may be more typical of those seen by retina specialists in routine clinical practice, and cannot be compared with prospective clinical trials such as ETDRS, which excluded patients with active proliferative and severe nonproliferative diabetic retinopathy. We also report the prevalence of DMI in patients with different clinical grades of diabetic maculopathy and/or retinopathy. Coexisting pathology—i.e., DME and DMI—is common in diabetic retinopathy and perhaps unsurprisingly, some evidence of DMI was seen in 69.4% of cases with CSME; of these, 19.4% were found to have DMI in the moderate to severe range. Eyes with PDR (both treated and untreated) and severe NPDR were found to have evidence of DMI in the majority of cases (PDR: 77.2% [$n = 122$]; severe NPDR: 59.7% [$n = 40$]). DMI, though less commonly seen across all other grades of NPDR, was still present in 46% of eyes ($n = 64$) with mild to moderate NPDR, and 45.5% of eyes ($n = 20$) with no diabetic retinopathy (DR) of interest. All 20 eyes (4.9% of the study population) with no DR and concurrent DMI had some degree of macular edema (CSME: 15 eyes; DME: 5 eyes). Although the association between DME/CSME is well established, it can also occur at any level of diabetic retinopathy. However, there may be alternative explanations for this finding: First, as the grades of DR were based on clinical examination, there remains a possibility that mild or nontreatable DR (such as the presence of microaneurysms

TABLE 4. Association between Visual Acuity and FAZ Area (mm²) Stratified by EDTRS DMI Severity Grades for Five Different Quantiles

DMI Grade	10th Quantile			25th Quantile			50th Quantile			75th Quantile			90th Quantile		
	β	SE	P Value	β	SE	P Value	β	SE	P Value	β	SE	P Value	β	SE	P Value
Questionable, $n = 75$	0.041	0.064	0.530	0.001	0.123	0.994	<0.001	0.030	0.992	0.097	0.142	0.497	0.406	0.186	0.030
Mild, $n = 103$	0.019	0.063	0.757	0.199	0.123	0.107	0.013	0.044	0.763	0.110	0.081	0.177	0.246	0.122	0.044
Moderate, $n = 45$	<u>0.224</u>	0.083	0.007**	0.199	0.093	0.034*	<u>0.299</u>	0.108	0.006**	<u>0.257</u>	0.099	0.009**	<u>0.289</u>	0.117	0.014**
Severe, $n = 24$	<u>0.326</u>	0.083	<0.001**	0.303	0.142	0.034*	<u>0.406</u>	0.101	<0.001**	<u>0.359</u>	0.118	0.002**	<u>0.299</u>	0.128	0.020*

Coefficient (β) and SE are reported for 10%, 25%, 50%, 75%, and 90%. Coefficients that are significant at 5% level are bold, and those at the 1% level are bold and underlined. P values significant at 5% level are indicated with * and ** at 1% level. Standard errors are obtained using 1000 bootstrap replications. The DMI grade values presented adjust for age (continuous variable); sex; retinopathy grade; and the presence of macular edema (categorical variable).

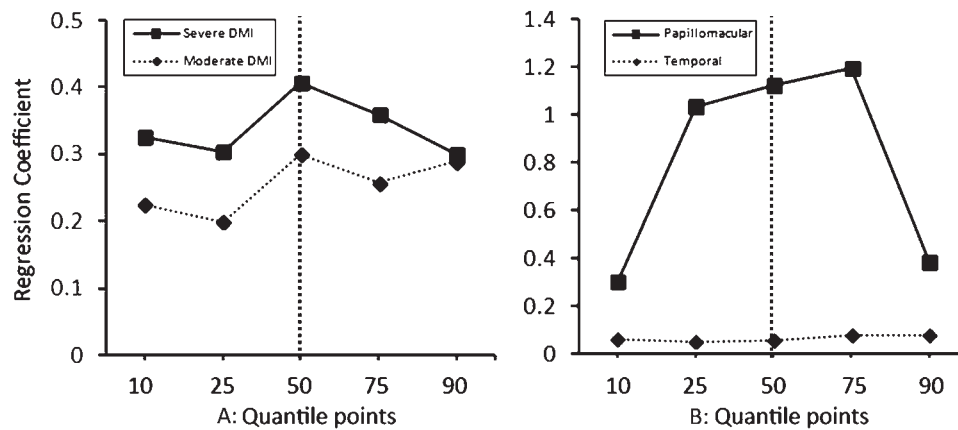


FIGURE 4. (A) Line plot of quantile regression coefficients (vertical dotted line represents the median regression coefficient) of visual acuity with FAZ area (mm²) in the moderate (dotted line) and severe (solid line) subgroups of DMI, after adjustment for age, sex, retinopathy grade, and the presence of DME. (B) Line plot of quantile regression coefficients (vertical dotted line represents the median regression coefficient) of visual acuity with papillomacular and temporal ischemia area (mm²), after adjustment for age, sex, retinopathy grade, the presence of DME and FAZ area (mm²).

only) may have been missed. Second, the majority of these 20 eyes had either questionable or mild ETDRS-DMI grades (questionable: 5 eyes; mild: 10 eyes; moderate: 5 eyes), the FAZ capillaries of these eyes may represent variants of normal, and may reflect the sensitivity of qualitative grading. For this reason, we constructed our models that assessed the effects of ischemia on visual acuity, based on the FAZ size rather than the ETDRS-DMI grades alone.

Consistent with previous studies, we observed increasing FAZ area in eyes with more severe grades of DMI.^{6,22-24} Some studies have reported that the relationship between FAZ size and DMI severity occurs from the earliest stages of NPDR,^{6,24} while others have observed this relationship only in more advanced disease.^{25,26} This discrepancy is most likely due to the large intersubject variability of the FAZ, ranging between 0.05 and up to 1.98 mm² in nondiseased subjects.^{6,24,25,27,28} In this study, the mean FAZ area of eyes without DMI fell on the higher side of previously reported normal ranges, consistent with the hypothesis that the FAZ may be affected in early disease.

In addition to assessing the prevalence of ETDRS-defined DMI grades, we also evaluated its visual significance. In particular, we modeled the effects of FAZ size on VA, an area where previous findings have been contradictory.^{6,22-26} On preliminary analysis, we found no significant association between increases in FAZ area and decreases in VA. However, with more sophisticated modeling, with stratification by grade of ETDRS-defined grades of DMI severity, robust

associations were found for patients with moderate or severe DMI. This relationship was particularly strong for patients with severe DMI (Fig. 4A). Our results confirm, therefore, a definite link between macular ischemia and visual function; but only in the approximately 15% of patients with moderate to severe DMI.

In this report, we also investigated a number of novel angiographic parameters, including two regions of noncontiguous retinal capillary loss we hypothesized to be of functional significance. Moreover, in this process, we developed methods for standardized quantification of these areas. First, we examined temporal ischemia: an area which has been observed clinically to act as a driver of macular edema, and has been previously associated with angle neovascularization in patients with PDR.²⁹ Secondly, we evaluated papillomacular ischemia: an area where the capillary network overlies and supplies the nerve fibers of the papillomacular bundle, originating from the central macula or fovea (Figs. 1, 2). We hypothesized that ischemia in these locations, which contain a high density of axons originating from the macula, may have an association with reduction in VA. We observed a strong significant association between papillomacular ischemia and VA, independent of the FAZ size, and clinical covariates such as DME, suggesting that the location of macular ischemic changes plays a critical role in its effects on visual function.

Our study has a number of strengths, combining standardized qualitative and quantitative assessment of FA images, with

TABLE 5. Association between Visual Acuity and Area of Papillomacular or Temporal Ischemia (mm²) for Five Different Quantiles after Adjusting for FAZ Area (mm²) as a Covariate

Area of Ischemia	10th Quantile			25th Quantile			50th Quantile			75th Quantile			90th Quantile		
	β	SE	P Value	β	SE	P Value	β	SE	P Value	β	SE	P Value	β	SE	P Value
Papillomacular, n = 34	0.302	0.586	0.612	1.036	0.500	0.050*	1.123	0.355	0.005**	1.193	0.381	0.005**	0.383	0.547	0.002**
Temporal, n = 112	0.060	0.017	0.001	0.051	0.015	0.002	0.056	0.026	0.039*	0.075	0.0401	0.079	0.075	0.0454	0.110

Coefficient (β) and SE are reported for 10%, 25%, 50%, 75%, and 90%. Coefficients that are significant at 5% level are bold, and those at the 1% level are bold and underlined. P values significant at 5% level are indicated with * and ** at 1% level. Standard errors are obtained using 1000 bootstrap replications. Area of ischemia values adjust for sex; retinopathy grade; the presence of macular edema (categorical variables); age; and FAZ area (mm²; continuous variables).

TABLE 6. Multivariable Median Regression between Visual Acuity and Area of Papillomacular Ischemia (mm²) Adjusting for FAZ Area (mm²) and Other Clinical Covariates

	Median Regression Coefficient	Standard Error	P Value
Papillomacular ischemia	<u>1.123</u>	0.341	0.004**
FAZ area	0.178	0.259	0.501
Sex	0.17	0.162	0.291
Age	0.01	0.012	0.401
DME			
No DME	0.193	0.271	0.485
CSME	0.310	0.485	0.530
Treated CSME	0.106	0.252	0.679

The median regression coefficient is reported with standard errors obtained using 1000 bootstrap replications. Coefficients that are significant at 5% level are bold, and those at the 1% level are bold and underlined. *P* values significant at 5% level are indicated with * and ** at 1% level.

a large sample size, in an area with a relative paucity of data. We used FA grading software, equipped with standard planimetric tools, which allowed quantification of novel morphological parameters, and combined these measurements with detailed statistical analysis. As anticipated, data regarding VA and areas of ischemia were negatively skewed, with 39.7% of patients in our cohort not having any evidence of DMI. As a result, the application of linear regression would have a substantial leverage on the slope of mean regression lines. Our application of quantile regression is more robust to outliers and allowed for an increased depth of analysis in the examination of an inferential target, such as VA, in a given proportion of the population. For example, patients with small or large FAZ areas may respond differently to ischemia with corresponding changes to visual acuity. Multivariable quantile regression analysis also accounted for concurrent DME, a confounder of the relationship between DMI and VA, often overlooked in other studies.

Our study also has a number of limitations. First, the retrospective cross-sectional nature of the work results in an inherently biased selection of patients, particularly as patients with more severe disease are those more likely to undergo angiographic assessment. Despite this, our patient population is likely representative of those seen in routine clinical practice, and those enrolled into clinical trials. At present, figures for the “true” prevalence of DMI would require FA acquisition in population-based epidemiological studies. Such estimates are unlikely to be derived prior to the widespread introduction of noninvasive angiographic techniques. Secondly, we did not examine systemic parameters such as duration of diabetes, or blood glucose control, which, as observed in natural history studies with diabetic retinopathy, is likely to play a role in DMI.^{16–18} We did however, investigate the relationship of DMI with severity of diabetic retinopathy and observed an increased prevalence of DMI in both proliferative disease and macular edema. The independence of this relationship with systemic parameters will need to be addressed in future prospective natural history studies. Lastly, a further limitation is our reliance on Snellen visual acuities, the limitations of which have been well documented.^{30,31}

In summary, in patients with type 2 diabetes mellitus attending a tertiary referral medical retina clinic, 41.8% of eyes had evidence of DMI, while 16.6% of eyes had evidence of moderate to severe DMI. DMI can sometimes be seen in eyes with early retinal disease and, when present, appears

symmetrical in the majority of cases. The presence of moderate to severe DMI was also associated with impairment of visual function. The presence of papillomacular ischemia was particularly associated with VA reduction—this parameter may be of particular interest for future evaluation in prospective studies. No effective treatment currently exists for patients with visual loss attributable to DMI—such a patient group may be an appropriate first target for the development of cellular therapies in diabetic retinopathy.

References

- Klein R, Klein BE, Moss SE. Visual impairment in diabetes. *Ophthalmology*. 1984;91:1-9.
- Ticho U, Patz A. The role of capillary perfusion in the management of diabetic macular edema. *Am J Ophthalmol*. 1973;76:880-886.
- Bresnick GH, De Venecia G, Myers FL, et al. Retinal ischemia in diabetic retinopathy. *Arch Ophthalmol*. 1975;93:1300-1310.
- Bresnick GH, Condit R, Syrjala S, et al. Abnormalities of the foveal avascular zone in diabetic retinopathy. *Arch Ophthalmol*. 1984;102:1286-1293.
- Classification of diabetic retinopathy from fluorescein angiograms. ETDRS report number 11. Early Treatment Diabetic Retinopathy Study Research Group. *Ophthalmology* 1991; 98(suppl 5):807-822.
- Mansour AM, Schachat A, Bodiford G, Haymond R. Foveal avascular zone in diabetes mellitus. *Retina*. 1993;13:125-128.
- Arend O, Wolf S, Harris A, Reim M. The relationship of macular microcirculation to visual acuity in diabetic patients. *Arch Ophthalmol*. 1995;113:610-614.
- Arend O, Remky A, Evans D, et al. Contrast sensitivity loss is coupled with capillary dropout in patients with diabetes. *Invest Ophthalmol Vis Sci*. 1997;38:1819-1824.
- Unoki N, Nishijima K, Sakamoto A, et al. Retinal sensitivity loss and structural disturbance in areas of capillary nonperfusion of eyes with diabetic retinopathy. *Am J Ophthalmol*. 2007;144: 755-760.
- Tyrberg M, Ponjavic V, Lovestam-Adrian M. Multifocal electroretinogram (mfERG) in patients with diabetes mellitus and an enlarged foveal avascular zone (FAZ). *Doc Ophthalmol*. 2008; 117:185-189.
- Jonas JB, Martus P, Degenring RF, et al. Predictive factors for visual acuity after intravitreal triamcinolone treatment for diabetic macular edema. *Arch Ophthalmol*. 2005;123:1338-1343.
- Chung EJ, Roh MI, Kwon OW, Koh HJ. Effects of macular ischemia on the outcome of intravitreal bevacizumab therapy for diabetic macular edema. *Retina*. 2008;28:957-963.
- Focal photocoagulation treatment of diabetic macular edema. Relationship of treatment effect to fluorescein angiographic and other retinal characteristics at baseline: ETDRS report no. 19. Early Treatment Diabetic Retinopathy Study Research Group. *Arch Ophthalmol*. 1995;113:1144-1155.
- Mitchell P, Bandello F, Schmidt-Erfurth U, et al. The RESTORE study: ranibizumab monotherapy or combined with laser versus laser monotherapy for diabetic macular edema. *Ophthalmology*. 2011;118:615-625.
- Conrath J, Giorgi R, Raccach D, Ridings B. Foveal avascular zone in diabetic retinopathy: quantitative vs qualitative assessment. *Eye*. 2005;19:322-326.
- Varma R, Torres M, Pena F, et al. Prevalence of diabetic retinopathy in adult Latinos: the Los Angeles Latino eye study. *Ophthalmology*. 2004;111:1298-1306.
- Wong TY, Klein R, Islam FM, et al. Diabetic retinopathy in a multi-ethnic cohort in the United States. *Am J Ophthalmol*. 2006;141:446-455.

18. Klein R, Klein BE, Moss SE, Linton KL. The Beaver Dam Eye Study. Retinopathy in adults with newly discovered and previously diagnosed diabetes mellitus. *Ophthalmology*. 1992;99:58-62.
19. Nguyen QD, Brown DM, Marcus DM, et al. Ranibizumab for diabetic macular edema: results from 2 phase III randomized trials: RISE and RIDE. *Ophthalmology*. 2012;119:789-801.
20. Mackenzie S, Schmermer C, Charnley A, et al. SDOCT imaging to identify macular pathology in patients diagnosed with diabetic maculopathy by a digital photographic retinal screening programme. *PLoS One*. 2011;6:e14811.
21. Hao L, Naiman DQ. *Quantile Regression*. Thousand Oaks, CA: SAGE Publications, Inc.; 2007.
22. Bresnick GH, Condit R, Syrjala S, et al. Abnormalities of the foveal avascular zone in diabetic retinopathy. *Arch Ophthalmol*. 1984;102:1286-1293.
23. Arend O, Wolf S, Jung F, et al. Retinal microcirculation in patients with diabetes mellitus: dynamic and morphological analysis of perifoveal capillary network. *Br J Ophthalmol*. 1991;75:514-518.
24. Conrath J, Giorgi R, Raccah D, Ridings B. Foveal avascular zone in diabetic retinopathy: quantitative vs qualitative assessment. *Eye (Lond)*. 2005;19:322-326.
25. Sander B, Larsen M, Engler C, et al. Early changes in diabetic retinopathy: capillary loss and blood-retina barrier permeability in relation to metabolic control. *Acta Ophthalmol (Copenb)*. 1994;72:553-559.
26. Hilmantel G, Applegate RA, van Heuven WA, et al. Entoptic foveal avascular zone measurement and diabetic retinopathy. *Optom Vis Sci*. 1999;76:826-831.
27. Sleightholm MA, Arnold J, Kohner EM. Diabetic retinopathy: I. The measurement of intercapillary area in normal retinal angiograms. *J Diabet Complications*. 1988;2:113-116.
28. Dubis AM, Hansen BR, Cooper RF, et al. The relationship between the foveal avascular zone and foveal pit morphology. *Invest Ophthalmol Vis Sci*. 2012;53:1628-1636.
29. Hamanaka T, Akabane N, Yajima T, et al. Retinal ischemia and angle neovascularization in proliferative diabetic retinopathy. *Am J Ophthalmol*. 2001;132:648-658.
30. Hussain B, Saleh GM, Sivaprasad S, Hammond CJ. Changing from Snellen to LogMAR: debate or delay? *Clin Exp Ophthalmol*. 2006;34:6-8.
31. Kniestedt C, Stamper RL. Visual acuity and its measurement. *Ophthalmol Clin North Am*. 2003;16:155-170, v.