

RVC OPEN ACCESS REPOSITORY – COPYRIGHT NOTICE

This is the peer reviewed version of the following article:

Cardy, T. J.A., Lam, R., Peters, L. M., McLaren, P. J., Matas Riera, M. and De Decker, S. (2017), Successful medical management of a domestic longhair cat with subdural intracranial empyema and multifocal pneumonia. *Journal of Veterinary Emergency and Critical Care*. doi:[10.1111/vec.12566](https://doi.org/10.1111/vec.12566)

This article may be used for non-commercial purposes in accordance with [Wiley Terms and Conditions for Self-Archiving](#).

The full details of the published version of the article are as follows:

TITLE: Successful medical management of a domestic longhair cat with subdural intracranial empyema and multifocal pneumonia

AUTHORS: Cardy, T J A; Lam, R; Peters, L M; McLaren, P J; Riera, M M; De Decker, S

JOURNAL TITLE: *Journal of Veterinary Emergency and Critical Care*

PUBLISHER: Wiley, for Veterinary Emergency and Critical Care Society

PUBLICATION DATE: 12 January 2017 (online)

DOI: 10.1111/vec.12566

1 **Successful medical management of a domestic longhair cat with subdural intracranial**
2 **empyema and multifocal pneumonia**

3

4 Thomas J.A. Cardy, BSc, BVetMed, PhD; Richard Lam, BVSc, MvetMed, DipECVDI;

5 Laureen M. Peters, Dr. med. vet; Philippa J McLaren BVMS, MVS, MANZCVS,

6 DipACVP; Màrian Matas Riera DVM, DipECVO; Steven De Decker, DVM, PhD,

7 MvetMed, DipECVN;

8

9 Royal Veterinary College, University of London, Department of Clinical Science and
10 Services, Hawkshead Lane, North Mymms, Hertfordshire AL97TA, United Kingdom

11

12 Corresponding author: Thomas Cardy*

13 Tel.: +44(0)1707666366; fax: +44(0)1707649384

14 *E-mail address:* tcardy@rvc.ac.uk

15

16 *Please note that offprints will not be available from the authors

17

18 **Acknowledgements:** This case was presented in part as an Abstract (poster) at the 27th
19 Symposium of the European College of Veterinary Neurology (ECVN), Madrid, 18th-20th
20 September 2014.

21

22 **Conflict of interest:** No funding was received for this study and the authors declare no
23 conflict of interest

24

25 **Running title:** Medical management of subdural empyema in a cat

26

1 **Abstract**

2 **Objective:** To describe a case of successful medical management of subdural intracranial
3 empyema and multifocal pneumonia in a domestic longhaired cat.

4
5 **Case Summary:** A 7-year-8-month-old male neutered domestic longhair cat presented with
6 tachypnea, respiratory compromise, vestibular ataxia, obtundation, left-sided head tilt and multiple
7 cranial nerve deficits. Neuroanatomical localisation was multifocal with central vestibular
8 involvement. Magnetic resonance imaging (MRI) of the head indicated diffuse subdural empyema,
9 mainly affecting the middle cranial fossa and the right cerebrum. Analysis of cerebrospinal fluid
10 revealed degenerate neutrophils with a mixed population of intracellular bacilli. Computed
11 tomography (CT) of the thorax was suggestive for multifocal pneumonia. Aggressive medical
12 management with IV fluids, oxygen supplementation, mannitol boluses, dexamethasone, and
13 broad-spectrum antibiotics was started. The cat demonstrated gradual improvement within 24
14 hours of starting treatment. General physical and neurological examinations nine weeks after
15 initiating treatment did not reveal any abnormalities. A CT examination performed at this time
16 revealed resolution of the cat's pulmonary lesions. The cat was still free of clinical signs nine
17 months after treatment was started.

18
19 **New or unique information provided:** Subdural empyema is infrequently reported in cats and has
20 high mortality rates even following surgical treatment. This is the first reported case of successful
21 medical management of a cat with subdural empyema and suggests that aggressive medical
22 management should be attempted in cats that are not considered surgical candidates.

23 **Key words:** brain abscess, bacterial meningitis, MRI, CT, antibiotics, corticosteroids

24

25 **Introduction**

26 Bacterial infection of the central nervous system (CNS) in cats is rare and can arise from
27 multiple sources including direct extension from adjacent structures, inoculation via bite wounds,
28 trauma or iatrogenic means.¹⁻⁵ Although haematogenous spread from distant foci and migration of
29 foreign bodies can also occur, these routes of intracranial infection have not yet been reported in
30 cats.⁶⁻¹⁰ Bacterial infection can result in diffuse meningoencephalomyelitis as well as focal
31 parenchymal abscesses and empyema in epidural or subdural spaces.^{4,6} Reports of subdural
32 empyema are limited with only six reports in cats.^{1,3,6} Prognosis is considered poor and even with
33 aggressive surgical and medical treatment mortality rates are reported to be as high as 75%.^{1,3,6}
34 This report describes the first case of successful medical management of subdural empyema and
35 multifocal pneumonia in a cat.

36

37 **Case description**

38 A seven-year and eight-month-old, 3.9 kg, male neutered domestic longhair cat presented
39 following a three-week history of weight loss (0.8 kg) and a four-day history of progressive
40 lethargy and inappetence. In the 48 hours before presentation the cat developed a worsening
41 generalized ataxia and obtundation. General physical examination revealed revealed the cat to be
42 normothermic (38.3°C) with a grade II/VI left apical systolic heart murmur. The cat was
43 tachypnoeic with increased respiratory effort and right-sided serous ocular and nasal discharge.
44 No lesions were noted in the oropharyngeal cavity and both ear canals were clear with visible
45 intact tympanic membranes. Neurological examination revealed mild obtundation, vestibular
46 ataxia with falling to the left, left-sided head tilt, vertical nystagmus of the left eye (oculus sinister),
47 external ophthalmoplegia of the right eye (oculus dexter), anisocoria with a mydriatic right pupil,

48 absent right-sided palpebral and corneal reflexes, and decreased sensation of the right side of the
49 face. A multifocal lesion with central vestibular involvement was suspected. The onset,
50 progression, clinical examination findings and multifocal neuroanatomical localization were most
51 suggestive of infectious/inflammatory disease (Intracranial empyema, FIP, mycotic granuloma,
52 and toxoplasmosis) or neoplastic causes (lymphoma).

53

54 CBC revealed a mature neutrophilia (leukocytes: $21.74 \times 10^9/l$, Reference interval (RI): 5.5-
55 19.5, neutrophils: $19.43 \times 10^9/l$, RI: 2.5-12.5) and mild anaemia with no evidence of regeneration
56 (haematocrit 29%). Results of a biochemistry profile, venous blood gas and electrolytes and
57 coagulation parameters were within normal limits. Feline immunodeficiency virus antibody and
58 feline leukaemia virus antigen tests were negative as was Toxoplasma serum IgG/IgM antibody
59 testing. The cat was up to date with routine vaccinations and parasite treatments. Magnetic
60 resonance imaging (MRI) of the brain was performed under general anaesthesia using a 1.5 Tesla
61 magnet^a, which included sagittal and transverse T2-weighted (T2W) sequences, transverse T2*-
62 weighted and T2-weighted fluid-attenuated inversion recovery (FLAIR) sequences. Transverse,
63 sagittal, and dorsal plane T1-weighted (T1W) images were obtained before and after IV
64 administration of gadolinium contrast^b. On T2W images there was marked thickening and
65 hyperintensity of the meninges, mostly around the right cerebrum and extending to the ventral
66 aspect of the brain and brainstem (Figure 1A, B). Ventral to the cerebrum and brainstem on the
67 right side there was separation of the pachymeninges and leptomeninges with a hypointense fluid
68 accumulation (Figure 1A, B). T1W images obtained after contrast administration showed marked
69 enhancement of the meninges but no enhancement of the accumulated fluid within the meninges
70 (Figure 1 C, D). There was swelling of the right cerebrum with a midline shift and mild

71 displacement of the cerebellum into the foramen magnum (Figure 1A, B). These MRI findings
72 were most consistent with a diffuse meningitis and predominantly right-sided subdural empyema.<sup>2-
73 4,12,13</sup> No evidence of otitis media/interna or retrobulbar abscessation was identified. Computed
74 tomography (CT) of the thorax and abdomen performed with a 16-slice scanner^c revealed 12 well-
75 defined, rounded nodules in the left and right caudal and right middle lung lobes (Figure 2). All
76 lesions demonstrated uniform contrast enhancement after IV administration of iohexol^d
77 (Omnipaque, 240mg I/mL, GE Healthcare; Belgium). The abnormal thoracic CT findings were
78 most consistent with a multifocal pneumonia. Abdominal CT findings were within normal limits.

79

80 Mannitol^e (0.5mg/kg, IV over 20 minutes) was administered before a cisternal
81 cerebrospinal fluid (CSF) puncture was performed. Only a limited amount of CSF could be
82 collected due to its abnormal viscous nature. Determination of total nucleated cell counts, protein
83 concentration, and culture were therefore not possible. A direct smear was prepared, which
84 demonstrated moderate numbers of degenerate neutrophils along with lesser numbers of
85 macrophages and occasional lymphocytes, scant to moderate erythrocytes and smeared nuclear
86 debris. Long filamentous beading rods and occasional thicker bacilli were present both
87 extracellularly and within neutrophils (Figure 2). The cytological diagnosis was septic suppurative
88 inflammation with multiple Gram-positive bacterial species. Urine collected by cystocentesis and
89 blood samples taken from three different venous sites at hourly intervals did not identify any
90 microorganisms after 72 hours of aerobic and anaerobic culture. The owner declined performing
91 a bronchoalveolar lavage.

92

93 Subdural empyema is considered to be a neurosurgical emergency but due to the diffuse nature
94 and challenging location of the lesion surgery was not felt to be a feasible treatment option in this
95 case.^{3,4} Consequently intensive medical management and supportive care was initiated. For the
96 first 24 hours following general anaesthesia the cat was placed on continuous ECG and
97 oscillometric blood pressure monitoring with supplemental flow by oxygen.^{14,15,16} Respiration
98 rate, oxygen saturation (pulse oximetry) and Modified Glasgow Coma Scale (MGCS) were
99 measured every hour.^{14,15,16} Analyses of arterial blood gas, venous blood gas and electrolytes were
100 performed every six hours. Throughout this period oxygen saturation and partial pressures of
101 oxygen and carbon dioxide remained largely within normal limits meaning that respiratory support
102 other than flow-by oxygen was not required.^{15,16} During the first 24 hours the cat received three
103 boluses of mannitol^e (0.5g/kg, IV over 20 minutes) due to clinical signs suggestive of increases in
104 intracranial pressure. These signs included a worsening vestibular ataxia, non-invasive blood
105 pressure measurements between 180mmHg and 220mmHg, heart rate between 90 and 120 beats
106 per minute and episodes of marked obtundation with a concurrent reduction in MGCS from 15 to
107 10. The cat further received IV fluids (compound sodium lactate at 3ml/kg/hr), clindamycin^f (20
108 mg/kg, IV, q24h), enrofloxacin^g (5mg/kg, IV, q24h) and dexamethasone^h (0.2mg/kg, IV, q24h).
109

110 The cat started to demonstrate gradual improvement from 24 hours after initiating treatment and
111 continuous ECG and oscillometric blood pressure monitoring were stopped. After 48 hours of
112 treatment corticosteroid administration was discontinued and the cat was started on oral antibiotics
113 including clindamycinⁱ (11mg/kg, PO, q24h) and enrofloxacin^j (5mg/kg, PO, q24). At 48 hours
114 the cat was grooming and feeding itself and respiratory rate and effort had returned to normal.
115 After five days of hospitalisation the cat was discharged. The cat demonstrated mild vestibular

116 ataxia and head tilt at this time. Neurological examination three weeks after discharge
117 demonstrated further improvement with only mild vestibular ataxia present. General physical and
118 neurological examinations nine weeks after discharge were within normal limits. A CT
119 examination performed at that time demonstrated resolution of the earlier observed pulmonary
120 changes. Following discharge oral enrofloxacin was continued for one month and clindamycin was
121 continued for three months due to its activity against Gram-positive bacteria and anaerobes.
122 Telephone follow-up with the owner revealed that the cat was still free of clinical signs nine
123 months after discharge from our hospital.

124

125 **Discussion**

126 This case report describes successful medical treatment of a cat with subdural intracranial
127 empyema and concurrent multifocal pneumonia. This has not yet been reported to the best of the
128 authors' knowledge. Subdural empyema is considered a neurosurgical emergency.^{3,4} Because of
129 the extensive nature of the infection, including the ventral aspects of the cerebrum and brainstem,
130 the cat in this report was not considered a good surgical candidate.

131

132 Subdural empyema is a specific condition where empyema occurs within the boundaries
133 of the dura mater and arachnoid.^{3,11,12} Six reports in cats have been documented with only one
134 animal surviving following aggressive surgical and medical treatment.^{1,3,6} In agreement with the
135 case presented here, all reported cats with intracranial empyema presented following initial periods
136 of general systemic illness with lethargy, inappetence and weight loss.^{1-3,6} These cases invariably
137 experienced subsequent acute neurological deterioration with evidence of increased intracranial
138 pressure and brainstem compression. All cats were reported as being obtunded with evidence of

139 vestibular deficits and in the majority of cases ataxia and/or paresis.^{1-3,6} Of note is that only one
140 previously reported cat demonstrated pyrexia.³ These findings are in agreement with the clinical
141 presentation of the case presented here in which an initial history of lethargy, inappetence and
142 weight loss rapidly progressed to marked neurological signs.

143

144 MRI is considered the most effective diagnostic tool for empyema with characteristic
145 imaging findings that are consistent across human and veterinary medicine: a crescent or lentiform-
146 shaped extra-axial collection of fluid that is hyperintense relative to brain parenchyma on T2W
147 images and hypointense on T1W images. The lesions have strong ring enhancement following
148 contrast administration.^{2-4,11,12} This lentiform appearance is attributed to the purulent fluid
149 conforming to the subdural space and in some cases, as seen in the present report, can extend over
150 almost an entire cerebral hemisphere (Figure 1).² In contrast to epidurally located lesions, subdural
151 empyema can cross cranial suture lines. Extension is however limited by dural folds; such as the
152 falx cerebri and tentorium cerebelli.¹³ This can explain why the infection was limited to only one
153 cerebral hemisphere.

154

155 As with previous reports, blood and urine cultures were not found to be diagnostic and in
156 half of cases haematological and biochemical changes are limited to an inflammatory leukogram
157 and mild-regenerative anemia.^{1-3,6} Route of infection has been identified in 4/6 previously
158 published cases: retrobulbar abscess (two cases), bite wound (one case), and extension from
159 tympanic bulla (one case).¹⁻³ In this case there was no evidence of otitis media/interna,
160 oropharyngeal lesions, retrobulbar abscesses or bite wounds but a multifocal pneumonia was
161 identified on CT images. Although bacterial pneumonia can be associated with haematogenous

162 spread it cannot be concluded that the subdural empyema and pneumonia in this case were
163 associated as it was not possible to obtain bacterial culture from both sites.¹⁷ In previous reports
164 bacterial cultures from the sub-dural space at necropsy most commonly identified a polymicrobial
165 growth with at least one anaerobic bacteria (*Fusobacterium spp.*, *Bacterioides spp.*, and
166 *Actinomyces spp.*).^{1-3,6} In this case the benefits of trying to obtain a definitive diagnosis with a
167 cisternal CSF sample were felt to outweigh the potential risks of performing the procedure. MRI
168 signs of increased intracranial pressure were considered relatively mild but as a precaution
169 mannitol was administered prior to CSF sampling and the cat was intensively monitored post-
170 sampling. Direct smears from CSF in the current case identified a polymicrobial infection with
171 Gram-positive organisms. However there was insufficient sample to allow culture and it was
172 therefore impossible to provide a definitive identification of the organisms involved.

173

174 Although subdural empyema is expected to disrupt the blood-brain barrier and facilitates
175 drug penetration, the concentration of antimicrobials within the CSF can still be limited.¹⁸
176 Consequently clindamycin and enrofloxacin were chosen as antibiotic therapy because both drugs
177 cross the blood-brain barrier and in combination provide excellent broad-spectrum bactericidal
178 antimicrobial activity.¹⁹ It is currently unclear how long antibiotic treatment should be continued
179 in cases of feline subdural empyema. The duration of treatment in this case was based on
180 recommendations of medical management of subdural empyema in humans and spinal empyema
181 in dogs.^{18,20} Dexamethasone was administered immediately after a diagnosis of subdural empyema
182 was made. This was based on studies in people with bacterial meningitis, which support the use of
183 short-term anti-inflammatory doses to lower intracranial pressure and reduce CNS
184 inflammation.^{21,22}

185

186 **Conclusions**

187 This case report suggests that subdural empyema in cats can be effectively treated by
188 aggressive medical management resulting in complete resolution of clinical signs. It also highlights
189 that thorough examination for concurrent distant infections is warranted in a cat with subdural
190 empyema.

191

192 **Footnotes**

193 ^a Gyroscan Intera; Philips Medical Systems, Surrey, UK

194 ^b Gadovist, 1mmol/mL gadobutrol; Bayer, Berkshire, UK.

195 ^c Mx8000 IDT; Philips Medical Systems, Surrey, UK

196 ^d Omnipaque, 240mg I/mL; GE Healthcare; Buckinghamshire, UK

197 ^e Polyfusor K; Fresenius Kabi, Cheshire, UK

198 ^f Dalacin C; Pharmacia, Kent, UK

199 ^g Baytril; MSD Animal Health, Buckinghamshire, UK

200 ^h Dexafort; MSD Animal Health, Buckinghamshire, UK

201 ⁱ Antirobe; Zoetis, London, UK

202 ^j Baytril; MSD Animal Health, Buckinghamshire, UK

203

204 **References**

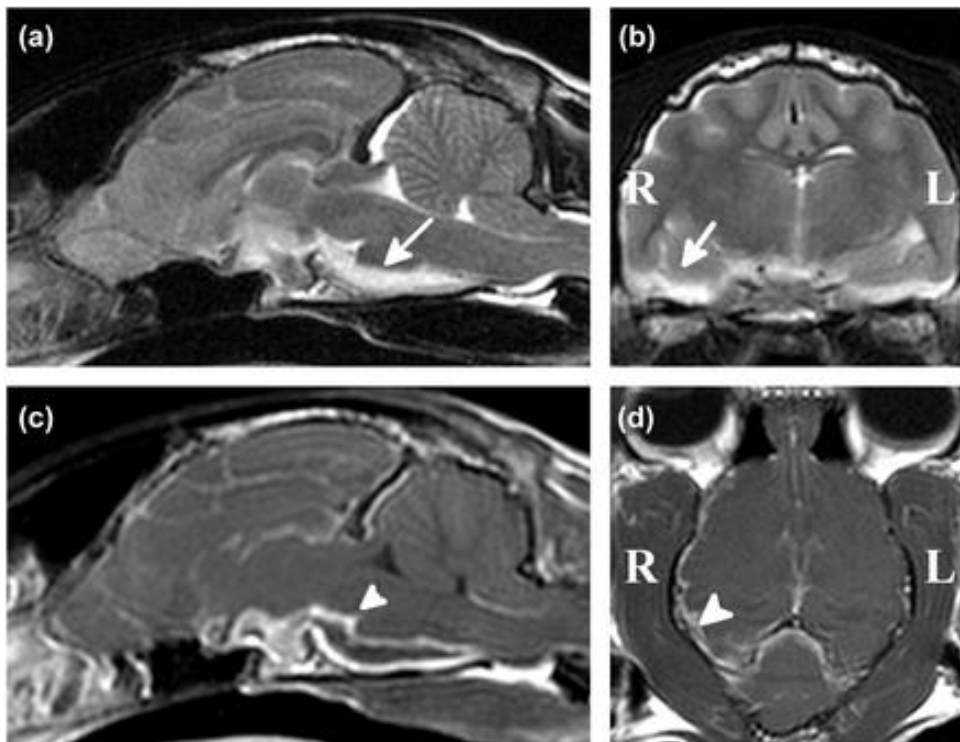
- 205 1. Klopp LS, Hathcock JT, Sorjonen DC. Magnetic resonance imaging features of brain stem
206 abscessation in two cats. *Vet Radiol Ultrasound* 2000; 41: 300–307.
- 207 2. Sturges BK, Dickinson PJ, Kortz GD, et al. Clinical signs, magnetic resonance imaging
208 features, and outcome after surgical and medical treatment of otogenic intracranial
209 infection in 11 cats and 4 dogs. *J Vet Intern Med* 2006; 20: 648–656.
- 210 3. Barrs VR, Nicoll RG, Churcher RK, et al. Intracranial empyema: literature review and two
211 novel cases in cats. *J Small Anim Pract* 2007; 48: 449–454.
- 212 4. Costanzo C, Garosi LS, Glass EN, et al. Brain abscess in seven cats due to a bite wound:
213 MRI findings, surgical management and outcome. *J Feline Med Surg* 2011; 13: 672–680.
- 214 5. Wouters EG, Beukers M, Theyse LF. Surgical treatment of a cerebral brain abscess in a
215 cat. *Vet Comp Orthop Traumatol* 2011; 24: 72–75.
- 216 6. Dow SW, Le Couteur RA, Henik RA, et al. Central nervous system infection associated
217 with anaerobic bacteria in two dogs and two cats. *J Vet Intern Med* 1988; 2: 171–176.
- 218 7. Nykamp SG, Steffey MA, Scrivani PV et al. Computed tomographic appearance of
219 epidural empyema in a dog. *Can Vet J* 2003; 44: 729–731.
- 220 8. Bach JF, Mahoney OM, Tidwell AM, et al. Brain abscess and bacterial endocarditis in a
221 Kerry Blue Terrier with a history of immune-mediated thrombocytopenia. *J Vet Emerg
222 Critic Care (San Antonio)* 2007; 17: 409–415.
- 223 9. Mateo I, Lorenzo V, Muñoz A, Pumarola M. Brainstem abscess due to plant foreign body
224 in a dog. *J Vet Intern Med* 2007; 21: 535–538.

- 225 10. Linon E, Geissbühler U, Karli P et al. Atlantoaxial epidural abscess secondary to grass awn
226 migration in a dog. *Vet Comp Orthop Traumatol* 2014; 27: 155–158.
- 227 11. Rich PM, Deasy NP, Jarosz JM. Intracranial dural empyema. *Br J Radiol* 2000; 73: 1329–
228 1336.
- 229 12. Horikawa T, MacKillop E, Bahr A. Presumptive Subdural Empyema in a Dog. *J Am Anim*
230 *Hosp Assoc* 2014; 50: 291–295.
- 231 13. Hecht S, Adams WH. MRI of brain disease in veterinary patients part 2: Acquired brain
232 disorders. *Vet Clin North Am Small Anim Pract* 2010; 40: 39–63.
- 233 14. Linda Barton. Respiratory Failure. In: Silverstein D, Hopper K (eds). *Small Animal*
234 *Critical Care Medicine*. 2nd ed Missouri: Saunders Elsevier, 2009, pages 64–67.
- 235 15. Elisa M. Mazzaferro. Oxygen Therapy. In: Silverstein D, Hopper K (eds). *Small Animal*
236 *Critical Care Medicine*. 2nd ed Missouri: Saunders Elsevier, 2009, pages 78–81.
- 237 16. Difazio J, Fletcher DJ. Updates in the Management of the Small Animal Patient with
238 Neurologic Trauma. *Vet Clin North Am Small Anim Pract* 2013; 43: 915–940.
- 239 17. Macdonald ES, Norris CR, Berghaus RB et al. Clinicopathologic and radiographic features
240 and etiologic agents in cats with histologically confirmed infectious pneumonia: 39 cases
241 (1991-2000). *J Am Vet Med Assoc* 2003; 223: 1142–1150.
- 242 18. Honda H, Warren DK. Central nervous system infections: meningitis and brain abscess.
243 *Infect Dis Clin North Am* 2009; 23: 609–623.
- 244 19. Patricia M. Dowling. Antimicrobial Therapy of Selected Organ Systems. In: Giguère S,
245 Prescott JF, Dowling PM (eds). *Antimicrobial Therapy in Veterinary Medicine*. 5th ed
246 Oxford: Wiley Blackwell, 2013, pages 395–419.

- 247 20. de Stefani A, Garosi LS, McConell, et al. Magnetic resonance imaging features of spinal
248 epidural empyema in five dogs. *Vet Radiol Ultrasound* 2008; 49: 135–140.
- 249 21. Meijvis SC, Hardeman H, Remmelts HH, et al. Dexamethasone and length of hospital stay
250 in patients with community-acquired pneumonia: a randomised, double-blind, placebo-
251 controlled trial. *Lancet* 2011; 377: 2023–2030.
- 252 22. Ziai WC, Lewin JJ 3rd. Update in the diagnosis and management of central nervous system
253 infections. *Neurol Clin* 2008; 26: 427–468.
- 254

255 Figure Legends:

256 Figure 1: T2-weighted sagittal (A) and transverse plane (B) MR images of cat brain. Sagittal (C)
257 and dorsal (D) plane T1W images following IV administration of gadolinium contrast media. On
258 T2W images there is marked thickening and hyperintensity of the meninges around the right
259 cerebrum extending to the ventral aspect of the brain and brainstem (Figure 1A, B). Ventral to
260 the right temporal lobe, adjacent to the right occipital lobe and ventral to the brainstem there is
261 separation of the pachymeninges with T2W hyperintense and T1W hypointense material (Figure
262 1A, B). Meninges show marked contrast enhancement (White arrow heads, Figure 1C, D) whilst
263 the T1W hypointense separation of the pachymeninges and leptomeninges did not enhance after
264 contrast administration (Figure 1 C, D).

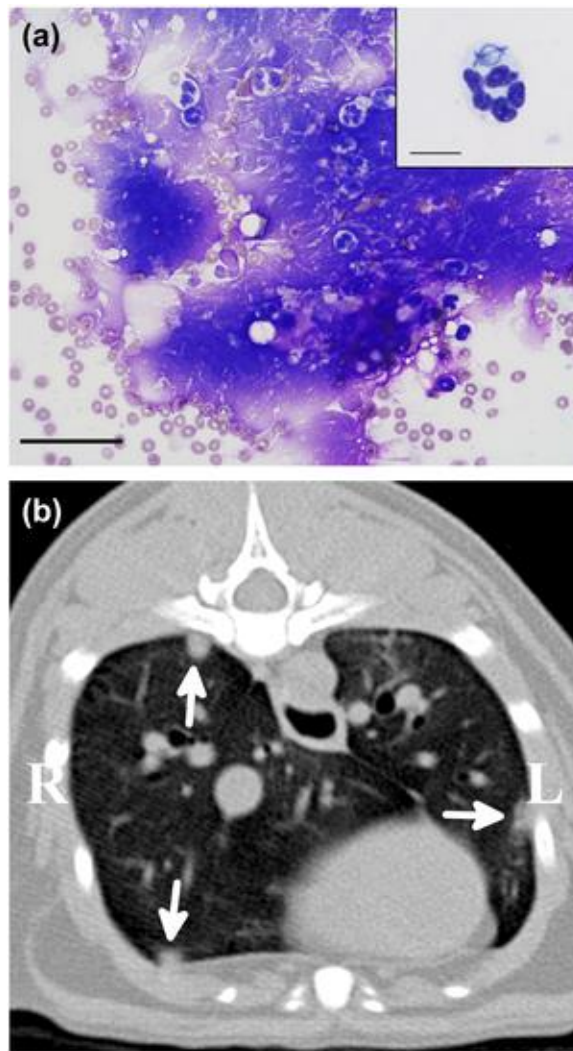


265

266

267

268 Figure 2: (A) variably degenerate neutrophils against a background of smeared nuclear debris
269 and erythrocytes. Modified Wright's Giemsa, bar = 50 μ m. Inset: Neutrophil containing several
270 beaded rods, bar = 10 μ m. (B): Transverse CT image of the thorax showing multiple pulmonary
271 nodules in right and left lung lobes (White arrow heads)



272