

Wilson, C.M., D'Ath, P.J., Parmar, D.N. & Sykakis, E. (2014). Keratoconus and granular dystrophy. BMJ Case Reports, doi: 10.1136/bcr-2014-205584



**CITY UNIVERSITY  
LONDON**

[City Research Online](http://www.city.ac.uk/researchonline)

**Original citation:** Wilson, C.M., D'Ath, P.J., Parmar, D.N. & Sykakis, E. (2014). Keratoconus and granular dystrophy. BMJ Case Reports, doi: 10.1136/bcr-2014-205584

**Permanent City Research Online URL:** <http://openaccess.city.ac.uk/3874/>

### **Copyright & reuse**

City University London has developed City Research Online so that its users may access the research outputs of City University London's staff. Copyright © and Moral Rights for this paper are retained by the individual author(s) and/ or other copyright holders. All material in City Research Online is checked for eligibility for copyright before being made available in the live archive. URLs from City Research Online may be freely distributed and linked to from other web pages.

### **Versions of research**

The version in City Research Online may differ from the final published version. Users are advised to check the Permanent City Research Online URL above for the status of the paper.

### **Enquiries**

If you have any enquiries about any aspect of City Research Online, or if you wish to make contact with the author(s) of this paper, please email the team at [publications@city.ac.uk](mailto:publications@city.ac.uk).

## **A Case of Keratoconus and Granular Dystrophy**

Dr. Clare M Wilson – Department of Visual Neuroscience, UCL Institute of  
Ophthalmology, 11-43 Bath Street, London, EC1V 9EL, United  
Kingdom

**and**

Department of Ophthalmology, Whipps Cross University Hospital, Barts Health,  
Whipps Cross Road, Leytonstone, London, E11 1NR, United Kingdom

Dr. Penny J D'Ath – Division of Optometry & Visual Science, City University London,  
Northampton Square, London, EC1V 0HB, United Kingdom

Dr. Eviropidis Sykakis - Department of Ophthalmology, Whipps Cross University  
Hospital, Barts Health, Whipps Cross Road, Leytonstone, London, E11 1NR,  
United Kingdom

Dr. Dipak N Parmar - Department of Ophthalmology, Whipps Cross University  
Hospital, Barts Health, Whipps Cross Road, Leytonstone, London, E11 1NR  
United Kingdom

**Key words:** Keratoconus, Granular Dystrophy, Contact Lenses, Ophthalmology

## **Abstract**

Concurrent bilateral keratoconus and granular dystrophy is reported in a 32 year old patient with decreased vision. Initially contact lenses were attempted unsuccessfully to treat the conditions. There are a handful of other reports of these combined pathologies in the literature, and the likelihood of a chance cause or possible genetic linkage between the conditions is discussed.

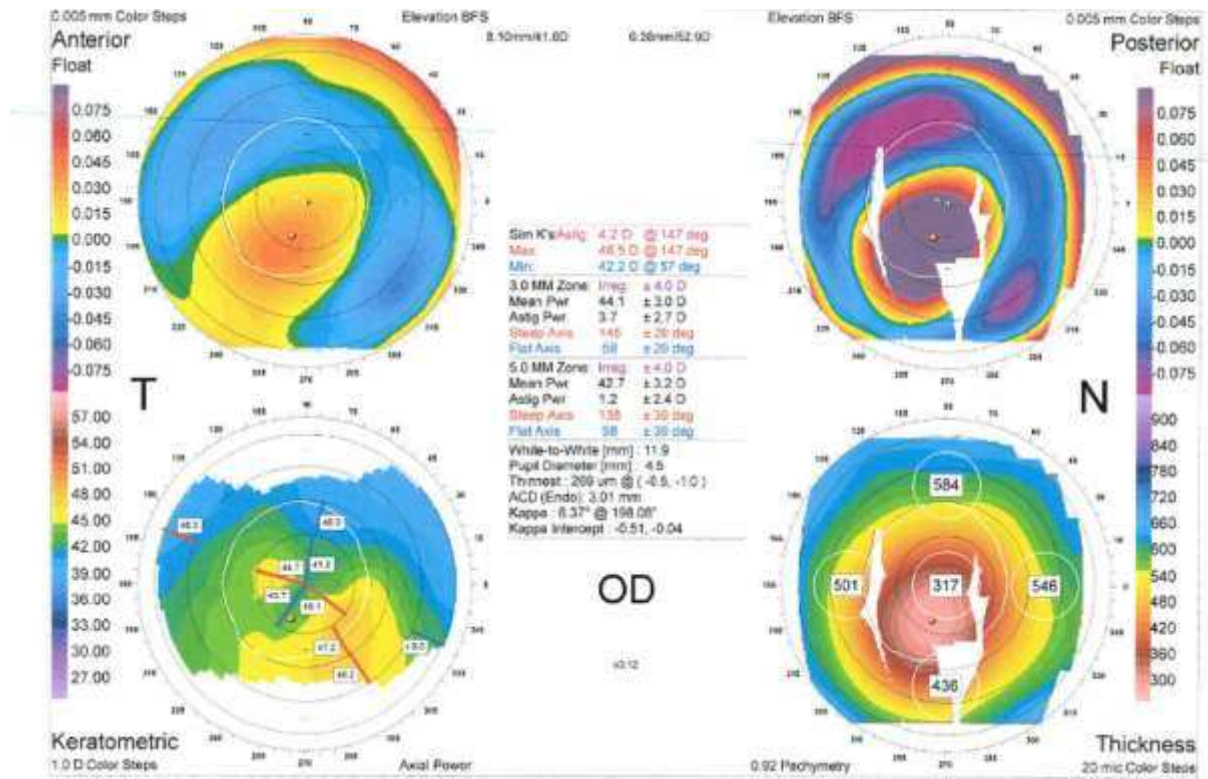
## **Background**

The combination of keratoconus and granular dystrophy has been previously reported in the literature. In a 10-year period at Wills Eye Hospital from January 1997 to December 2006, 51 cases of keratoconus combined with corneal dystrophy were seen. Of these cases, 53% had Fuchs dystrophy. Anterior basement membrane dystrophy was seen in a quarter of these patients. Further patients had posterior polymorphous dystrophy and a solitary case had granular dystrophy.<sup>1</sup> A report in *Cornea* in 2002 described a 15 year old Italian boy with bilateral keratoconus and granular dystrophy.<sup>2</sup> A family in Japan is reported to have autosomal dominant keratoconus and granular dystrophy, the mother and her two sons have the unusual combination of diseases.<sup>3</sup>

It seems that as there are more cases of this combination in the literature, it is increasingly likely that this is not purely a chance event but possibly a genetic or molecular linkage between the two exists. Keratoconus should be considered in cases of granular dystrophy in which the extent of the visual deterioration cannot be explained by the amount of corneal deposits and haze. Anterior segment OCT can provide a confirmatory diagnosis as it gives a combined output of pachymetry, stromal visualisation and keratometry.

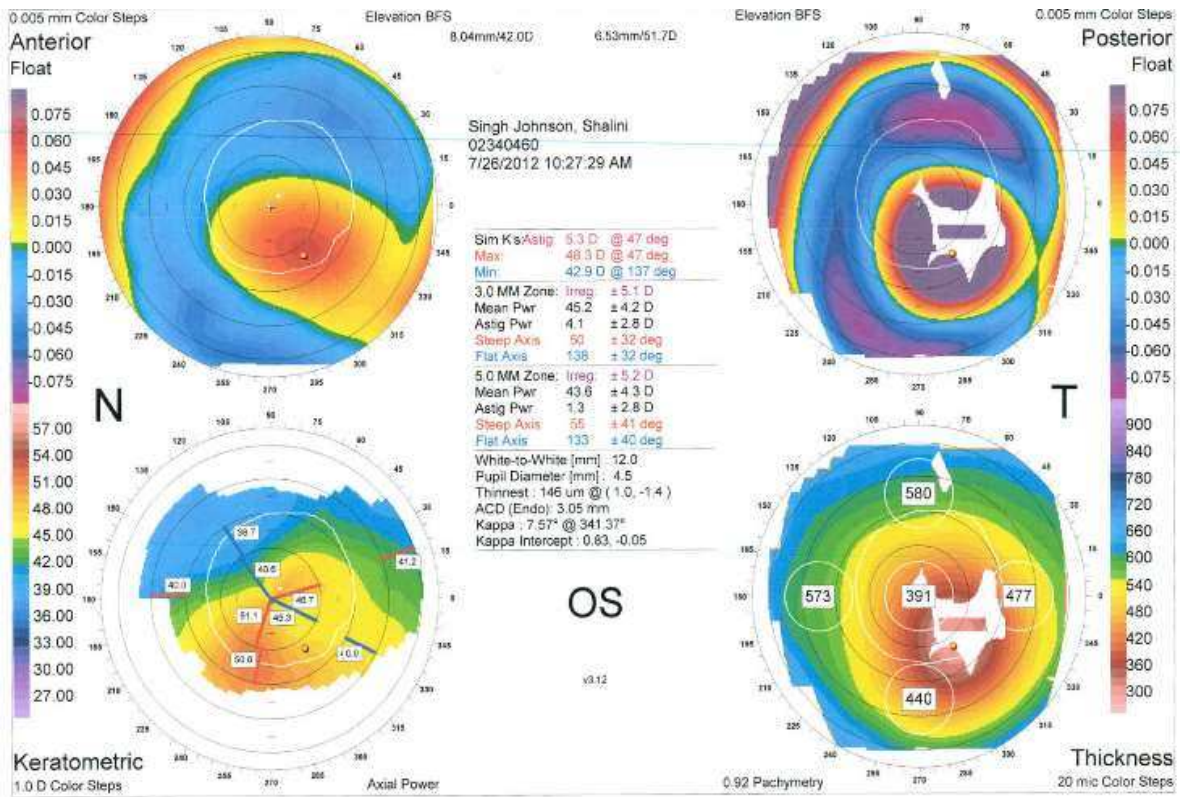
**Figure 1A**

Right eye Orbscan taken in July 2012 reveals steep K's and corneal thinning



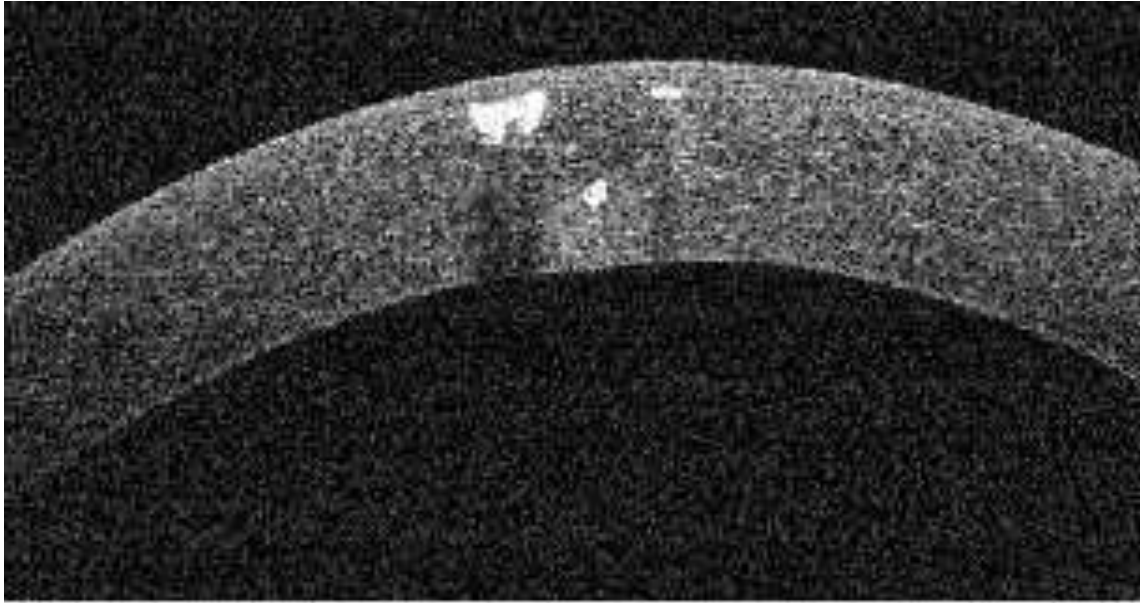
**Figure 1B**

Left eye Orbscan taken in July 2012 reveals steep K's and corneal thinning



## Figure 2

Right eye Optovue™ Anterior Segment OCT Granular deposits throughout anterior and posterior stroma



## Case presentation

A 32 year old lady who works in retail presented to the corneal clinic following observation of bilateral corneal crystalline deposits by her optometrist. Her sister had noticed white deposits on her eyes, and commented that they had gradually worsened. Her father also had a similar problem, but had never undergone any corneal surgery. Her vision was decreased, and she had worn glasses since the age of 20, yet found these no longer improved the vision adequately. She had previously attempted contact lens wear, but had not tolerated them.

On examination in 2007, her vision was 6/12 with glasses improving to 6/7.5 with a pinhole OD and 6/15 with glasses improving to 6/9.5 with a pinhole OS. There were central snowflake opacities in the anterior stroma of both corneas with clear intervening areas between the lesions.

## **Investigations**

Pachymetry from Orbscans performed in July 2012 measured thinned corneas (OD 317µm centrally, thinnest 269µm; OS 391µm centrally, thinnest 146µm) and topography revealed a maximum steepness of the cornea of 48.3D OD and 46.5D OS (Figure 1A and B). An Optovue™ anterior segment OCT scan illustrates the stromal granular deposits (Figure 2).

After examining the patient, she was asked to consent to her son having a corneal examination also, having explained the hereditary nature of the dystrophy. There were no signs of pathology in the boy's eyes.

## **Treatment**

At the time of diagnosis of keratoconus and granular dystrophy in May 2007, her keratometry readings showed very distorted mires. She was fitted with RGP contact lenses that became uncomfortable after one year, stopping use in August 2008. Repeat topography at that time showed that the right eye had stabilised, but the left eye had progressed mildly. She had a baby boy and was coping well with a vision of 6/12 with spectacle correction at her next follow up in November 2009. She was started on Celluvisc 0.5% (Carmellose), Allergan Ltd for dry eyes.

## **Outcome and follow-up**

This lady is currently satisfied with her vision of 6/12 right and left when corrected with spectacles. However, there are options of surgical interventions in the future if the condition progresses to an unacceptable level for her. A close watch will be kept on the vision and cornea of her son.

## **Discussion**

Keratoconus is a corneal ectasia in which bilateral anterior protrusion of the central cornea develops leading to myopia and corneal astigmatism. Histologically, there are focal

disruptions of the basement membrane and Bowman's layer, central stromal thinning and anterior stromal scarring. A Fleischer ring may develop from iron deposition in the basal epithelial layers and acute stromal oedema, or hydrops, may occur secondary to spontaneous breaks in Descemet's membrane.

Corneal dystrophies were named as a group of inherited, bilateral, symmetric, slowly progressive corneal diseases in the late 19<sup>th</sup> century. The first dystrophies to be described were granular and macular by Groenouw and lattice by Biber. Since these discoveries over a century ago, the phenotypic nomenclature has proved ineffective, due to genotypic analyses. The term "inherited corneal diseases" is now preferred, following the reclassification process that was initiated in 2005 at the World Cornea Congress meeting, and has since been published by the Committee for Classification of Corneal Dystrophies (IC3D).<sup>4</sup> Within this document, granular dystrophy is classified as a Category 1 dystrophy, meaning it is "a well-defined dystrophy in which the gene has been mapped and identified and specific mutations are known".

Granular dystrophy is an autosomal dominant stromal dystrophy with onset in childhood, sometimes evident as young as two years of age and involving the entire cornea. Granular dystrophy is due to mutation on chromosome 5q31. Light microscopy shows stromal deposits from deep epithelium to Descemet's membrane and hyaline opacities that stain with Masson trichrome, immunohistochemistry reveals that the deposits react to transforming beta-induced protein (keratoepithelin), confocal microscopy shows hyper-reflective opacities and transmission electron microscopy detects rod-shaped bodies.

The aetiology of keratoconus is more challenging to discern. One in seven (14%) keratoconus patients have a family history of the disease.<sup>5</sup> Many loci have been discerned by linkage studies to be linked with keratoconus. Unfortunately these have all been analysed under a monogenic assumption, and as it appears that keratoconus is multifactorial, involving more than one gene loci and environmental factors, a di- and polygenic model



should perhaps be used in future linkage studies. cDNA libraries and gene expression arrays have also been utilised to compare gene expression in patients with and without keratoconus to identify up or down-regulated genes.<sup>6</sup> Biochemical corneal changes in keratoconus patients include decreased collagen content, decreased inhibitors of proteolytic enzymes – alpha-1-proteinase inhibitor and alpha-2-macroglobulin, and alterations in tissue inhibitors of metalloproteinases. Transcription factor Sp1 is found in KC corneas, but not in normal corneas.<sup>7</sup>

Keratoconus has been associated with numerous genetic systemic disorders, most of which fall in to one of the following four subgroups: connective tissue disorders with abnormal collagen elasticity, abnormal retinal function with oculodigital stimulation, associated with atopy or eczema and eye rubbing, or low mental function associated with oculodigital stimulation. So, there is either an underlying connective tissue disorder or oculodigital stimulation. A single yet convincing case report linking eye rubbing to keratoconus is that of a boy with paroxysmal atrial tachycardia who rubbed his left eye from the age of five years to stimulate the oculocardiac reflex to revert to sinus rhythm. On ocular examination aged 11, his refraction was plano in his right eye and -18.00/+2.00 with keratometry of 53.00/55.50 in his left eye. Once he was told to correct the arrhythmia pressing on the carotid sinus, and not to rub the eye, there was no further progression of keratoconus.<sup>8</sup>

Evidence also exists to suggest that the traditional description of keratoconus as a non-inflammatory condition is questionable. IL-1 receptor sites are increased in cultured keratoconus stromal cells, and IL-6 and tumour necrosis factor-alpha have been shown to be overexpressed in the tears of patients with keratoconus.<sup>7</sup> These raised inflammatory mediators could have been caused by eye rubbing, or they could induce such behaviour - a chicken or egg type dilemma.

Keratoconus was first described by Professor Burchard Mauchart in 1748. 1/2000 people have keratoconus in the United States,<sup>9</sup> hence it is one of the most frequent causes for

penetrating keratoplasty and anterior lamellar keratoplasty. A genetic tool for diagnosing the condition early would be preferable as riboflavin/UVA-crosslinking has been shown to halt the progression of keratoconus, reducing the need for corneal grafts. Corneal cross-linking involves epithelial debridement, application of topical riboflavin drops, ultraviolet-A exposure at 370nm for approximately 30mins. 90% of KC patients are treated with contact lenses, eventually only the large scleral contact lenses are comfortable for them.

### **Learning points / take home message**

1. Keratoconus has a complex multifactorial aetiology, but there is likely an important emphasis on genetic causes;
2. The nomenclature of corneal dystrophies has been recently classified;
3. Family history and examination of the young children of sufferers of autosomal dominant corneal dystrophies is particularly important;
4. Co-existence of pathology should be considered with each new case, one cannot assume that if one disease is present a further will not be.

### **References**

1. Cremona FA, Ghosheh FR, Rapuano CJ, et al. Keratoconus associated with other corneal dystrophies. *Cornea* 2009;28(2):127-35.
2. Wollensak G, Green WR, Temprano J. Keratoconus associated with corneal granular dystrophy in a patient of Italian origin. *Cornea* 2002;21(1):121-2.
3. Mitsui M, Sakimoto T, Sawa M, et al. Familial case of keratoconus with corneal granular dystrophy. *Jpn J Ophthalmol* 1998;42(5):385-8.
4. Weiss JS, Møller HU, Lisch W, et al. The IC3D classification of the corneal dystrophies. *Cornea* 2008;27 Suppl 2:S1-83.

5. Wagner H, Barr JT, Zadnik K. Collaborative Longitudinal Evaluation of Keratoconus (CLEK) Study: methods and findings to date. *Cont Lens Anterior Eye* 2007;30(4):223-32.
6. Nielsen K, Hjortdal J, Pihlmann M, et al. Update on the keratoconus genetics. *Acta Ophthalmol* 2013;91(2):106-13.
7. Sugar J and Macsai MS. What causes keratoconus? *Cornea* 2012;31(6):716-9.
8. Coyle JT. Keratoconus and eye rubbing. *Am J Ophthalmol* 1984;97(4):527-8.
9. Kennedy RH, Bourne WM, Dyer JA. A 48-year clinical and epidemiologic study of keratoconus. 1986;101(3):267-3.