



**MEDICINA
UNIVERSITARIA**

www.elsevier.com.mx



CLINICAL CASE

Bleeding complications during percutaneous endoscopic gastrostomy treated with hemoclips

José Alberto González-González,¹ Eduardo Giasi-Gonzalez,¹ Francisco Javier Bosques-Padilla,¹ Juan Obed Gaytán-Torres,¹ Héctor Jesús Maldonado-Garza,¹ Iliana Aracely Hernández-Juárez²

¹Servicio de Gastroenterología

²Departamento de Pediatría

Dr. José Eleuterio González School of Medicine and University Hospital of UANL (Facultad de Medicina y Hospital Universitario Dr. José Eleuterio González de la UANL)

Received: november, 2009. Accepted: november, 2009.

KEY WORDS:

Endoscopic gastrostomy procedure;
Bleeding;
Hemoclips

Abstract

Percutaneous endoscopic gastrostomy (PEG) has become the primary procedure for the long-term nutrition of patients with swallowing disorders. It has been shown to be a safe method with a lower complication rate than surgical placement. Acute hemorrhage following PEG is rarely reported. We present a case report about the use of hemoclips to stop bleeding from gastric wall vessel injury during a PEG procedure.

PALABRAS CLAVE:

Gastrostomía endoscópica;
Sangrado;
Hemoclips.

Complicaciones de sangrado durante una gastrostomía endoscópica percutánea tratado con clips hemostáticos

Resumen

La gastrostomía endoscópica percutánea (GEP) es el procedimiento de elección para la nutrición a largo plazo de pacientes con trastornos de la deglución. Es un método seguro con un riesgo de complicaciones menor que el procedimiento quirúrgico. La hemorragia aguda después de la GEP es poco frecuente. Presentamos el reporte de un caso sobre el uso de hemoclips para detener el sangrado de una lesión vascular de la pared gástrica durante un procedimiento de GEP.

Corresponding author: Dr. José Alberto González González. Centro Regional para el Estudio de las Enfermedades Digestivas. Servicio de Gastroenterología. Facultad de Medicina y Hospital Universitario Dr. José Eleuterio González de la UANL. Edificio Dr. Rodrigo F. Barragán 2° Piso. Avenida Francisco I. Madero y Gonzalitos s/n Colonia Mitras Centro C. P. 64460 Monterrey, Nuevo León, México. Telephone: (+52 81) 8348 6068, 8333 3664. E-mail: joseagonz@yahoo.com

Background

Percutaneous endoscopic gastrostomy (PEG) is the procedure of choice for in-patients who need long-term tube-feeding support. Different complications have been described for this procedure. Bleeding is a rare but severe complication. It has been estimated to occur in 0.2 to 2.5 % of cases.^{1,2} In our previous experience with 223 consecutive PEG procedures performed using the Ponsky technique only one patient developed a gastric wall hematoma after a puncturing of the gastric cavity, requiring surgical treatment. Different endoscopic hemostasis methods exist. Thermal therapy, injection therapy, regional spray methods, and mechanical hemostatic methods have been described.³ This report describes the use of hemoclips in treating a spurting active bleeding from gastric wall vessel injury during a PEG procedure.

Case report

An 80-year-old man with dysphagia secondary to cerebrovascular ischemic disease was submitted to PEG procedure using the Ponsky technique. Complete upper GI endoscopic procedure was normal. After previous asepsis of the abdominal wall, the gastric cavity was fully distended. Transillumination and indentation point in the anterior gastric wall was localized and its correlation with the abdominal wall site was noted. A 1 cm skin incision was performed. Under endoscopic vision and using a 14 gauge needle, the stomach was easily punctured and a guide wire was passed to the stomach grasped and retrieved. With the guide wire in place and prior to passing the gastrostomy tube, bright red blood was noticed in the patient's mouth. The endoscope was passed again and arterial spurting bleeding was observed in the gastric puncture site (**Figure 1**).

The Teflon needle's sheath and the guide wire were retrieved. At this time, we decided to treat our patient with hemoclips. We used an Olympus HX-6UR-1 hemoclipping device and type MD-59 hemoclips. Five hemoclips were applied at the bleeding point. Water irrigation was done until complete hemostasis was observed (**Figure 2**). Ranitidine infusion was indicated and during the first 24 hours no rebleeding occurred. After 72 hours of the procedure a new endoscopy was performed showing the five hemoclips in place and no bleeding stigmata or gastric ulcer. One week later a PEG procedure using the Ponsky technique was performed without complication. After three months the patient is doing well without gastric bleeding or tube feeding problems.

Discussion

Different studies have proven the utility and safety of the PEG. Immediate complications such as bleeding and perforation are rare during PEG procedure, and surgery may be needed for most of these complications.⁴

Active gastrointestinal bleeding is an emergency and remains a common cause of morbidity and mortality. With

Figure 1. A: Active bleeding and the guide-wire. B: spurting arterial bleeding.

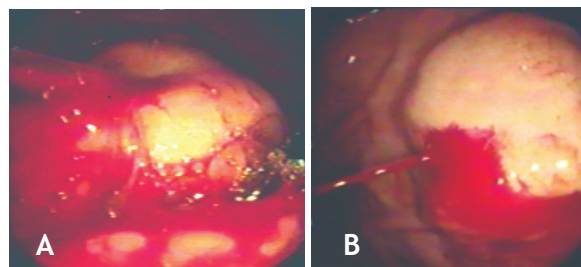
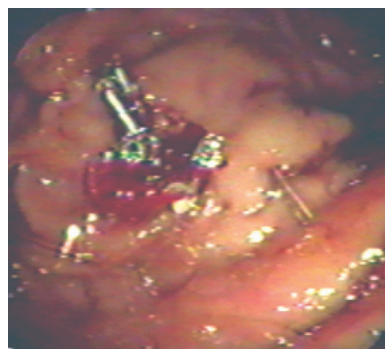


Figure 2. Hemostasis and five hemoclips in place.



the advance of new endoscopic hemostasis methods the necessity of surgery has been reduced.⁵ Different methods for endoscopic hemostasis have been described in bleeding lesions of the gastrointestinal tract. Hayashi in Japan, first described the mechanical method such as hemoclip, since 1988 it has been widely use in clinical practice.^{6,7}

The hemoclips function by grasping, compressing and ligating the bleeding vessels. An immediate hemostatic effect is noted and is expected to be permanent if the bleeding vessel is properly grasped. Several clips can be used without serious complication.⁸ In our case, we choose to use hemoclips because we had a good viewing position and considered the probability of a large gastric submucosal vessel injury (≥ 1 mm diameter). We are aware that hemostasis for vessels of this size is difficult in most cases.⁹

Other hemostasis methods may be considered for this kind of complication such as thermal therapy, in this regard, we were concerned about the risk of perforation of the gastric wall after the application of heat.

Given the suspicion of damage to a large gastric submucosal vessel, the banding procedure could have been a good option, but we were afraid of the risk of early dislodgment or late banding ulcer complication. At the third

and seventh days after clipping, five and three hemoclips were in place, respectively. No rebleeding or ulcer complication was noted in our patient after three months of follow up. Active bleeding due to gastric vessel puncture during PEG is a very rare complication but represents a high morbidity. Most of the time emergency surgery is considered. To our knowledge, this is the first case report about the use of hemoclips to stop bleeding from a gastric wall vessel injury during a PEG procedure.

References

1. Chung RS, Schertzer M. Pathogenesis of complications of percutaneous endoscopic gastrostomy. *Am Surg* 1990;56:134-7.
2. Larson DE, Burton DD, Schroeder KW, DiMagno EP. Percutaneous endoscopic gastrostomy. Indications, success, complications, and mortality in 314 consecutive patients. *Gastroenterology* 1987;93:48-52.
3. Chung IK, Kim EJ, Lee MS, Kim HS, Park SH, Lee MH, Kim SJ, Cho MS. Bleeding Dieulafoy's lesions and the choice of endoscopic method: comparing the hemostatic efficacy of mechanical and injection methods. *Gastrointest Endosc* 2000;52:721-4.
4. Stiegmann GV, Goff JS, Silas D, Pearlman N, Sun J, Norton L. Endoscopic versus operative gastrostomy: final results of a prospective randomized trial. *Gastrointest Endosc* 1990;36:1-5.
5. Rollhauser C, Fleischer DE. Nonvariceal upper gastrointestinal bleeding: an update. *Endoscopy*. 1997;29:91-105.
6. Hayashi I, Yonezawa TM, Kuwabara T, Kudoh I. The study on staunch clip for the treatment by endoscopy. *Gastroenterol Endosc* 1975;17:92-101.
7. Binmoeller KF, Grimm H, Soehendra N. Endoscopic closure of a perforation using metallic clips after snare excision of a gastric leiomyoma. *Gastrointest Endosc* 1993;39:172-4.
8. Devereaux CE, Binmoeller KF. Endoclip: closing the surgical gap. *Gastrointest Endosc* 1999;50:440-2.
9. Johnston JH, Jensen DM, Auth D. Experimental comparison of endoscopic yttrium-aluminum-garnet laser, electrosurgery, and heater probe for canine gut arterial coagulation. Importance of compression and avoidance of erosion. *Gastroenterology* 1987;92:1101-8.