

# Hemipenile prolapse and hemipenectomy in a leopard gecko (*Eublepharis macularius*)

## Prolapso de hemipene y hemipenectomía en un gecko leopardo (*Eublepharis macularius*)

Lescano J<sup>1\*</sup>, Quevedo M<sup>1</sup>

<sup>1</sup>Laboratorio de Anatomía Animal y Fauna Silvestre, Facultad de Medicina Veterinaria, Universidad Nacional Mayor de San Marcos, Lima, Perú.

\*Correo electrónico del autor: [xtianlescano@gmail.com](mailto:xtianlescano@gmail.com)

**Abstract:** Copulatory organ prolapse is a condition more frequently observed in chelonians and ophidians than in lizards. Most common causes are infections, forced separation during mating and inflammation associated to the use of probes for sex determination. Moreover, many other predisposing factors are described (hypocalcaemia, urolithiasis, etc.), but etiological diagnosis is rarely achieved. A four years old leopard gecko (*Eublepharis macularius*) was received presenting unilateral hemipenile prolapse. Medical therapy was performed using 50 % dextrose baths and prednisone (2 mg/kg) during 24 hours, but it was unsuccessful. Due to the fact that the prolapsed hemipenis showed signs of necrosis, surgical resection was performed. The patient was anesthetized using the combination ketamine (5 mg/kg), dexmedetomidine (0.1 mg/kg), and midazolam (1 mg/kg); also, lidocaine (4 mg/kg) was administered for local block, whereas atipamezole (0.5 mg/kg) was used for antagonizing dexmedetomidine. The used anesthetic protocol allowed an adequate surgical management. Hemipenectomy solved the problem without any observed complication.

**Key words:** Gekkonidae, lizard, paraphimosis, surgery

**Resumen:** El prolapso del órgano copulatorio es una afección más frecuentemente observada en quelonios y ofidios que en saurios. Las causas más comunes son infecciones, separación forzada durante la cópula e inflamación asociada al uso de sondas para determinación del sexo. Además, se han descrito muchas otros factores asociados (hipocalcemia, urolitiasis), pero rara vez se logra llegar al diagnóstico etiológico. Un gecko leopardo (*Eublepharis macularius*) de cuatro años de edad fue recibido presentando prolapso unilateral de hemipene. Se realizó tratamiento médico usando baños en dextrosa 50 % y prednisona (2 mg/kg) durante 24 horas, pero éste no fue exitoso. Debido a que el hemipene prolapsado presentó signos de necrosis, se realizó la resección quirúrgica. El paciente fue anestesiado empleando la combinación ketamina (5 mg/kg), dexmedetomidina (0,1 mg/kg) y midazolam (1 mg/kg). Además, se administró lidocaína (4 mg/kg) como bloqueo local y se usó atipamezol para antagonizar la dexmedetomidina. El protocolo anestésico empleado permitió el manejo quirúrgico adecuado. La hemipenectomía resolvió el problema sin observarse complicación alguna.

**Palabras clave:** Gekkonidae, saurio, paraquimosis, cirugía

## Introduction

Exotic reptiles are becoming into less uncommon pets (Rataj *et al.* 2011). Among them, the leopard gecko (*Eublepharis macularius*) is a species that, after decades of commercial spread, is currently well established in captivity. It is relatively popular and it can be found in pet stores, zoos, and breeding facilities (Bonke *et al.* 2011; Deming *et al.* 2008).

Lizards possess a pair of extraclacal copulatory organs named hemipenes, which are disposed inside a sac located at the base of the tail and caudally directed from the cloaca (Funk 2002; Girling 2003; Silva *et al.* 2013). These organs do not perform urinary function (as reptiles lack penile urethra) and only one hemipenis is used during mating at a time (Barten 2005). During copulation, hemipenis is filled with blood and a groove is formed on its dorsal surface; through such groove spermatic fluid and spermatozoa drain from the cloaca (Girling 2003).

Hemipenile prolapse occurs when the copulatory organ remains everted during a prolonged period. In those cases, hemipenis will tend to desiccation and necrosis if it is not rapidly relocated (Podhade and Harne 2014). If hemipenis presents normal coloration and necrosis is not evident, relocation is suggested. For that purpose, the organ must be rinsed using cold chlorhexidine 0.5 % or sodium chloride solution (Podhade and Harne 2014; Silva *et al.* 2013;) aiming to decrease contamination. Furthermore, as hemipenis is usually edematous due to exposure and friction to substrate, hypertonic solution (e.g. dextrose 50 %) or glicerine should be used to facilitate its relocation (Bennett and Mader 2005; Silva *et al.* 2013). If hemipenis cannot be relocated, incisions must be performed at each side of the sac in order to make its opening

wider, then the hemipenis is introduced and sutures are placed to close incisions avoiding it everts again (Bennett and Mader 2005; Nisbet *et al.* 2011). On the contrary, if hemipenis is severely damaged or shows signs of necrosis, amputation is the treatment of choice (Bennett and Mader 2005; Silva *et al.* 2013). It should be noted that such procedure will not affect urination or reproduction (as one functional hemipenis will remain within the animal) (Bennett and Mader 2005; Silva *et al.* 2013). The aim of this article was to describe the successful surgical management of hemipenile prolapse in a leopard gecko (*Eublepharis macularius*).

## Case report

A four years old male leopard gecko (*Eublepharis macularius*) was presented to the Wild and Exotic Animals Clinic, Facultad de Medicina Veterinaria, Universidad Nacional Mayor de San Marcos, Lima, Perú. The animal was kept in a vivarium with sand as substrate, and under humidity and temperature conditions according to recommended range (Kramer 2002; McBride and Hernández-Divers 2004). Three days before presentation, the animal had been placed in a terrarium with a female leopard gecko in order to breed. One day before presentation, the owner noticed the animal had a swelling near the cloaca. At physical examination the animal weighed 70 g, and showed good body condition (3/5). Moreover, left hemipenis was found everted and oedematous. Medical therapy using prednisone (2 mg/kg PO c/24 h) (prednisona, Laboratorios Portugal, Perú) (Carpenter *et al.* 2014) and rinsing using dextrose 50 % were performed. Next day, swelling had not decreased and hemipenis started showing signs of necrosis (Figure 1). Hence, surgical removal of affected hemipenis was suggested.

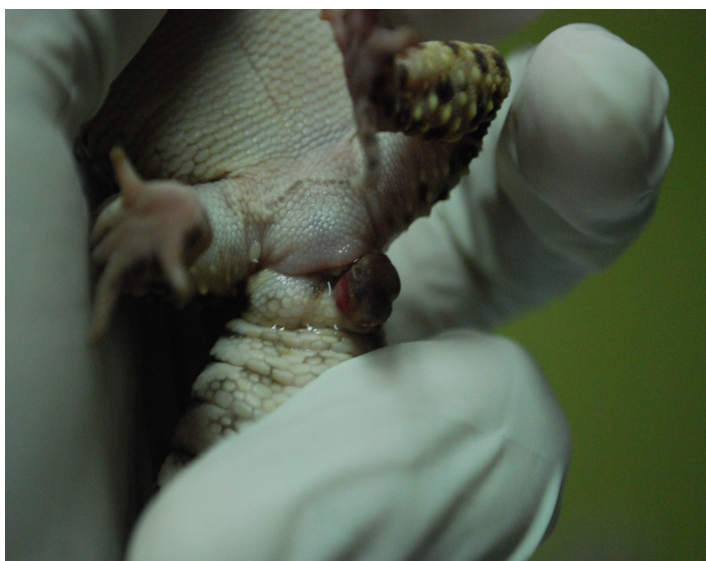

Figure 1. Leopard gecko (*Eublepharis macularius*) presenting eversion of left hemipenis showing evidence of necrosis.

The animal was anesthetized using the combination ketamine (5 mg/kg) (Imalgene®, Merial, France), dexmedetomidine (0.1 mg/kg) (Dexdomitor®, Orion Pharma, Finland), and midazolam (1 mg/kg) (Dormonid®, Roche, Switzerland), administered intracoelomically (Schumacher and Mans 2014). Recumbency (from drugs administration to sternal recumbency) (Figure 2a), sedation (from drugs administration to absence of resistance to dorsal recumbency), and surgery start (from drugs administration to the absence of response to stimuli) times respectively were 1, 5, and 10 minutes. Surgical antisepsis was performed using chlorhexidine 5 % (Bennett and Mader 2005). Lidocaine (4 mg/kg) (Otarvas Q, Perú) was administered at the base of affected hemipenis for local anaesthesia (Silva *et al.* 2013; Carpenter *et al.* 2014) (Figure 2b). Transfixion ligature was placed at the base of hemipenis using polyglactin acid 5/0 (Vicryl PGA, Ethicon, USA) aiming to avoid haemorrhage (Figure 2c) (Funk 2002). Then, hemipenis was resected and its containing sac was closed (Figure 2d). Surgery was performed during about 20 minutes; at the end the animal received 0.5 mg/kg of atipamezole (Antisedan®, Orion, Finland) and fluid therapy using Jarchow solution (20 ml/kg ICe) (Norton 2005). Five minutes after atipamezole administration, the animal recovered sternal position and remained resting during

about two hours in a warmed room (at 30 °C). Post-surgical therapy was composed by tramadol (10 mg/kg PO c/24 h) (Tramadol®, John Martin, Argentina) and enrofloxacin (5 mg/kg PO c/12 h) (Floxaviar®, Genfar, Colombia) (Carpenter *et al.* 2014) during one week. Moreover, wound was cleaned using 0.5 % chlorhexidine twice a day during two weeks. No complication was observed in wound healing and animal was found in good condition during a routine check three months after surgery.

## Discussion

To the authors' knowledge, this article reports a case of hemipenis prolapse and its surgical management in a leopard gecko for the first time in Perú, an even in South America. Moreover, the use of the anaesthetic combination ketamine-dexmedetomidine-midazolam is reported for the first time in a leopard gecko; its use has only been recorded in spiny-tailed lizard (*Uromastyx sp.*), bearded dragon (*Pogona vitticeps*), and blue iguana (*Cyclura lewis*) (Schumacher and Mans 2014). Descriptions of anesthetic combinations used in Leopard geckos are very scarce and poorly detailed; hence, comparisons among protocols are difficult. The induction and recovery times described in this article (10 and 120 minutes,




Figure 2. Hemipenectomy in a leopard gecko (*Eublepharis macularius*). (a) Transfixion suture is placed at the base of hemipenis (b) Hemipenis resection and closure of the corresponding sac.

respectively) were longer than those described by Hall and Lewbart (2006) using isoflurane (5 and 30 minutes, respectively). This is an expected finding, as inhalant drugs are known to produce recovery times shorter than injectable ones (Bouts and Gasthuys 2002). However, it should be noted that in these studies geckos underwent different kind of procedures (hemipenis resection and percutaneous oocentesis, respectively) involving different anesthetic depth and time; consequently, direct comparison must be carefully examined and might be questionable.

Copulatory organ prolapse is more commonly observed in chelonians than in snakes and lizards (Ramos *et al.* 2009; Silva *et al.* 2013). During the literature review performed for preparing this article, reports of hemipenis or penis prolapse were found only for snakes (*Bothrop sissularis*, *Daboia russelii*) and chelonians (*Geochelone carbonaria*, *Trachemys scriptaelegans*) (Nisbet *et al.* 2011; Podhade and Harné 2014; Ramos *et al.* 2009; Silva *et al.* 2013). The most common causes for this condition are infection, forced separation during mating, and inflammation due to trauma when using probes for sex determination (Bennett and Mader 2005). However, other associated causes are trauma of hemipenes retractor muscle of cloacal sphincter, intestinal parasites, urolithiasis, hypocalcemia, diarrhea, constipation, foreign body obstruction, prolonged sexual activity, neurological dysfunction, and general weakness (Nisbet *et al.* 2011; Podhade and Harné 2014; Silva *et al.* 2013). In most cases, etiologic diagnosis is not achieved (Nisbet *et al.* 2011). In the presented case, the most likely cause would be prolonged sexual activity as the patient remained during about 72 hours in a same enclosure with a sexually receptive female gecko. Despite scientific literature about reproductive management of reptiles is scarce and there is no standardized protocols. Ladage *et al.* (2008) used 10 minutes intervals during four hours in a research about mating and fertility in *E. macularius*. This hypothetic cause is supported by anamnesis and physical examination of patient, by which it was not possible to find any other predisposing factor. However, other factors (e.g. parasites, hypocalcemia) could not be specifically ruled out as they were not assessed.

Medical treatment was unsuccessful probably because prolapsed hemipenis was severely edematous. This might have occurred because the hemipenis was exposed to substrate (sand) during 24 to 72 hours. On the other hand, surgical approach was successful and the animal did not present any surgical or post-surgical complication. Funk (2002) described amputation as one of the most frequently surgical procedures performed in hemipenis. The same author mentions prolapse is the most common reason for hemipenile amputation, whereas trauma and infection

are less frequent. The anaesthetic combination used in this case provided adequate duration and quality of induction, anaesthesia, and recovery periods, allowing the performance of hemipenis resection.

## Conclusions

The successful surgical management of hemipenile prolapse in *Eublepharis macularius* is presented in detail. Also, the safe use of the anesthetic combination ketamine-dexmedetomidine-midazolam in *E. macularius* is described for the first time; however, further research is required in order to assess and standardize such protocol in this species.

## Acknowledgements

The authors acknowledge Gerson Silva for his help during the performance of surgery described in this article.

## Conflict of interests

The authors certify that they have no affiliations with or involvement in any organization or entity with any financial interest (such as honoraria; educational grants; participation in speakers' bureaus; membership, employment, consultancies, stock ownership, or other equity interest; and expert testimony or patent-licensing arrangements), or non-financial interest (such as personal or professional relationships, affiliations, knowledge or beliefs) in the subject matter or materials discussed in this manuscript.

## References

- Bennett RA, Mader DR. Cloacal prolapse. In: Mader DR, 2005. Reptile medicine and surgery. 2nd Ed. St. Louis, Missouri, USA; Saunders Elsevier, pp. 751-5.
- Bonke R, Böhme W, Opiela K, Rödder D. A remarkable case of cannibalism in juvenile Leopard Geckos, *Eublepharis macularius* (Blyth, 1854) (Squamata: Eublepharidae). Herpetol Notes. 2011;4:211-2.
- Bouts T, Gasthuys F. Anesthesia in reptiles: inhalation anesthesia. Vlaams Diergen Tijds 2002; 71:195-201.
- Carpenter JW, Klaphake E, Gibbons PM. Reptile formulary and laboratory normals. In: Mader DR, Divers SJ, 2014. Current therapy in reptile medicine and surgery. St. Louis, Missouri, USA; Elsevier Saunders, pp. 382-410.
- Deming C, Greiner E, Uhl EW. Prevalence of *Cryptosporidium* infection and characteristics of oocyst shedding in a breeding colony of leopard geckos (*Eublepharis macularius*). J Zoo Wild Med. 2008;39(4):600-7.
- Funk RS. Lizard reproductive medicine and surgery. Vet Clin Exot Anim. 2002;5(3):579-613.
- Girling S. Basic reptile and amphibian anatomy and physiology. In: Girling S, 2003. Veterinary nursing of exotic pets. Oxford, UK; Blackwell Publishing, pp. 105-26.

Hall AJ, Lewbart GA. Treatment of dystocia in a leopard gecko (*Eublepharis macularius*) by percutaneous ovariectomy. *Vet Rec.* 2006;158:737-9.

LaDage LD, Gutzke WHN, Simmons RA, Ferkin MH. Multiple mating increases fecundity, fertility and relative clutch mass in the female leopard gecko (*Eublepharis macularius*). *Ethol.* 2008;114:512-20.

Mc Bride M, Hernández-Divers SJ. Nursing care of lizards. *Vet Clin Exot Anim.* 2004;7(2):375-96.

Nisbet HO, Yardimci C, Özak A, Sirin YS. Penile prolapse in a red eared slider (*Trachemys scriptaelegans*). *Kafkas Univ Vet Fak Derg.* 2011;17(1):151-3.

Norton TM. Chelonian emergency and critical care. *Semin Avian Exot Pet.* 2005;14(2):106-30.

Podhade DN, Harne R. Surgical intervention in prolapsed rescued Russell Viper (*Daboia russelii*). *JWR.* 2014;2(2):9-10.

Ramos RM, Vale DF, Hanawo MEOC, Ferreira FS, Luz MJ, Oliveira ALA. Penectomia em caso de prolapso peniano em Jabuti-piranga (*Geochelone carbonaria*) – Relato de caso. *JBCA.* 2009;2(3):166-74.

Schumacher J, Mans C. Anesthesia. In: Mader DR, Divers SJ, 2014. *Current therapy in reptile medicine and surgery.* St. Luis, Missouri, USA; Elsevier Saunders, pp. 134-53.

Rataj AV, Lindtner-Knific R, Vlahović K, Mavri U, Dovč A. Parasites in pet reptiles. *Acta Vet Scand.* 2011;53:33.

Silva KB, Muñiz-da-Silva DF, Silva KMP, Garcia VC, Santos SMA. Hemipenicectomia em Jararaca-Ilhoa (*Bothrops insularis*) – Relato de caso. *Vet e Zootec.* 2013;20(3):9-14.