



2-1990


Infection and Twiddler Syndrome in a Dog With Addison's Disease, Complete Heart Block, and Wandering Artificial Pacemakers

James W. Buchanan

University of Pennsylvania, jwb@vet.upenn.edu

Richard C. Hill

Follow this and additional works at: https://repository.upenn.edu/vet_papers

 Part of the [Animal Diseases Commons](#), [Cardiovascular Diseases Commons](#), [Comparative and Laboratory Animal Medicine Commons](#), [Medical Biotechnology Commons](#), and the [Rehabilitation and Therapy Commons](#)

Recommended Citation

Buchanan, J. W., & Hill, R. C. (1990). Infection and Twiddler Syndrome in a Dog With Addison's Disease, Complete Heart Block, and Wandering Artificial Pacemakers. *Journal of the American Animal Hospital Association*, 26 (1), 25-32. Retrieved from https://repository.upenn.edu/vet_papers/130

This paper is posted at Scholarly Commons. https://repository.upenn.edu/vet_papers/130
For more information, please contact repository@pobox.upenn.edu.

Infection and Twiddler Syndrome in a Dog With Addison's Disease, Complete Heart Block, and Wandering Artificial Pacemakers

Abstract

Third-degree heart block developed in an obese seven-year-old dog with adrenal cortical failure. After three days of extensive medical therapy and use of a temporary transvenous pacemaker, a transthoracic permanent pacemaker was implanted in the usual paracostal location. After two years of normal function, the pulse generator suddenly migrated to a ventral location in the flank and became surrounded by an abscess. Intermittent pacing failure ensued. Medical therapy with antibiotics failed to eliminate infection until the infected pacemaker and site were excised surgically. A new pacemaker was placed on the opposite side and functioned well for two months. Subsequent migration and rotation of the new pacemaker led to spiral twisting of the lead and dislodgment of the corkscrew electrode from the myocardium in a syndrome analogous to Twiddler's syndrome in man. The dog presently is 10 years old and asymptomatic with a nonpaced ventricular rhythm of 60 beats per minute and an usual chest radiograph.

Disciplines

Animal Diseases | Cardiovascular Diseases | Comparative and Laboratory Animal Medicine | Medical Biotechnology | Rehabilitation and Therapy

Infection and Twiddler Syndrome in a Dog with Addison's Disease, Complete Heart Block, and Wandering Artificial Pacemakers

Richard C. Hill, BVSc, MRCVS
James W. Buchanan, DVM, MMedSc

Third-degree heart block developed in an obese seven-year-old dog with adrenal cortical failure. After three days of extensive medical therapy and use of a temporary transvenous pacemaker, a transthoracic permanent pacemaker was implanted in the usual paracostal location. After two years of normal function, the pulse generator suddenly migrated to a ventral location in the flank and became surrounded by an abscess. Intermittent pacing failure ensued. Medical therapy with antibiotics failed to eliminate infection until the infected pacemaker and site were excised surgically. A new pacemaker was placed on the opposite side and functioned well for two months. Subsequent migration and rotation of the new pacemaker led to spiral twisting of the lead and dislodgment of the corkscrew electrode from the myocardium in a syndrome analogous to Twiddler's syndrome in man. The dog presently is 10 years old and asymptomatic with a nonpaced ventricular rhythm of 60 beats per minute and an unusual chest radiograph.

Introduction

Artificial pacemakers have become an accepted therapy for third-degree heart block in veterinary medicine. Complications that have been reported include overlying skin ulceration, exit block, lead fracture or dislocation, battery failure, and infection.¹⁻⁴ This report describes successful treatment of pacemaker infection by excision and replacement. The second pacemaker subsequently migrated and rotated numerous times in a manner analogous to Twiddler's syndrome in man.⁵

Case Description

A seven-year-old extremely obese spayed female Labrador retriever mix-breed weighing 40 kg was presented with acute collapse, bradycardia (35 beats per minute [BPM]), dyspnea, and general edema. An electrocardiogram revealed third-degree heart block [Figure 1]. The dog had been receiving therapy for hypoadrenocorticism (florinef 0.0037 mg/kg body weight *q* 12 hrs, prednisolone 0.125 mg/kg body weight *q* 12 hrs) for two years prior to admission and had been asymptomatic until 24 hours prior to emergency admission. Tentative diagnosis of Addisonian crisis was substantiated by physical and laboratory findings. Initial hypovolemia, oliguria, mild hyperkalemia (6.1 mEq/L), mild hyponatremia (134 mEq/L), and metabolic acidosis responded to fluid and electrolyte therapy, dopamine infusion (4 μ g/kg per minute), prednisolone (0.25 mg/kg body weight SC *q* 12 hrs), and desoxycorticosterone acetate (0.075 mg/kg body weight SC *q* 24 hrs).

Routine blood profile showed leukocytosis with slight left shift, and urinary sediment contained numerous white blood cells. Therefore, the dog was given ampicillin (10 mg/kg body weight SC *q* 8 hrs) until results of urine culture (negative) were known on day 3. At that time antibiotic

From the Section of Medicine (Hill) and Section of Cardiology (Buchanan), Department of Clinical Studies, School of Veterinary Medicine, University of Pennsylvania, Philadelphia, Pennsylvania 19104-6010.

Supported in part by the Bernard and Muriel Freeman Heart Research Fund.

Address reprint requests to Dr. James W. Buchanan.

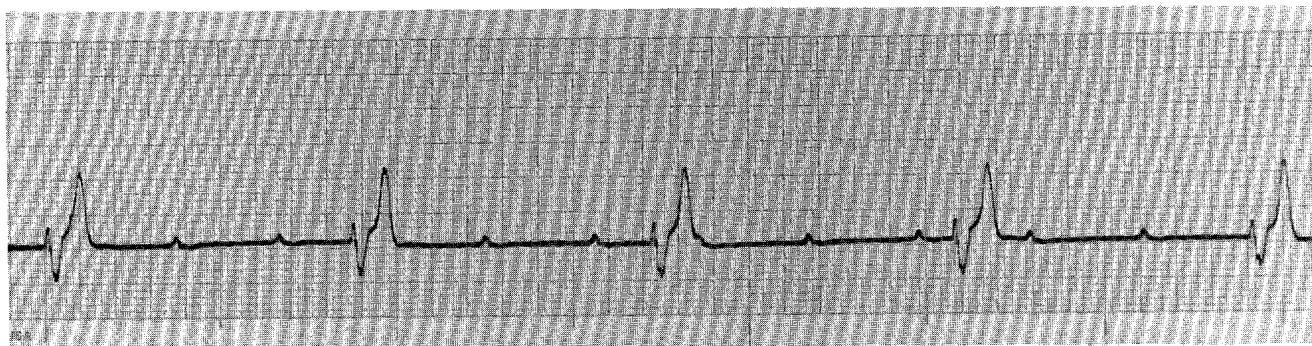


Figure 1—Electrocardiogram on admission demonstrating complete heart block. Atrial rate is 100 beats per minute (BPM). Idioventricular rate is 35 BPM. Lead II=1 cm/mv, 25 mm/sec.

therapy was changed to cephalothin (30 mg/kg body weight IV *q* 12 hrs) for two days because of transcutaneous pacemaker placement. Subsequently, the dog was given cephadrine (20 mg/kg body weight PO *q* 12 hrs) for 14 days as a prophylactic measure.

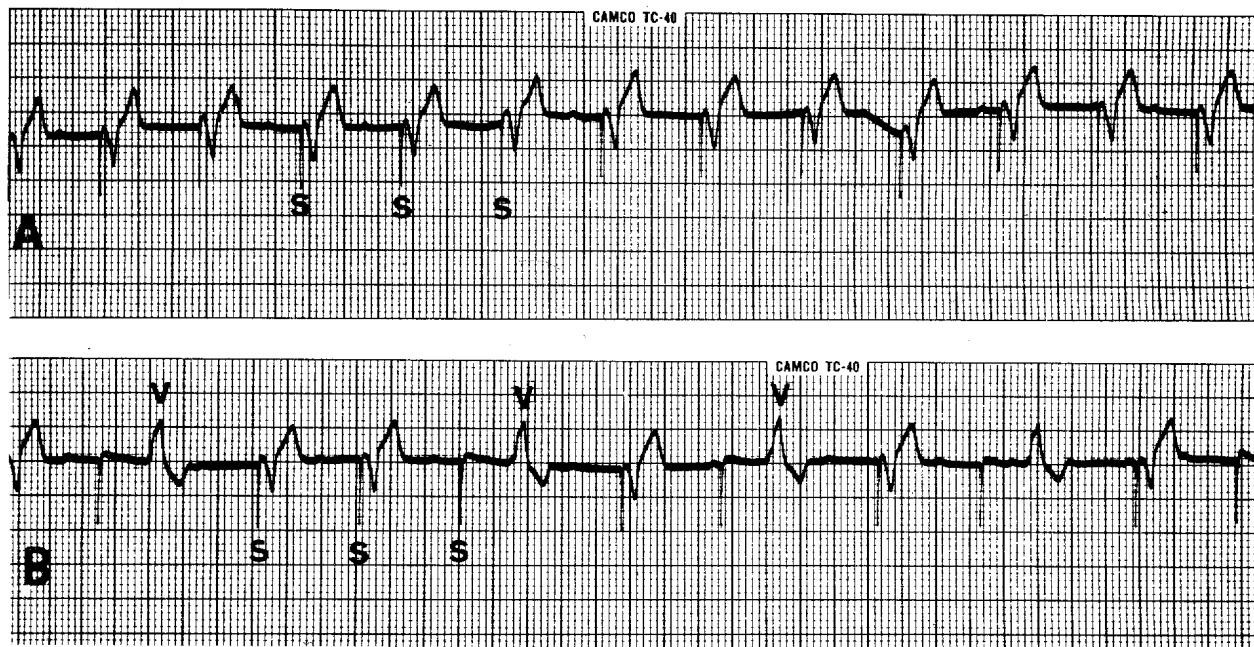
Third-degree heart block on admission was not improved by atropine (0.02 mg/kg body weight SC) so isoproterenol (3 mg in 250 ml 5% dextrose IV) was given at a variable rate to maintain heart rate at 60 to 80 BPM. A temporary transvenous pacemaker was inserted on the second day, and the dog improved sufficiently to be considered for a permanent pacemaker. On the fourth day a permanent epicardial corkscrew electrode was attached to the left ventricle, and a unipolar demand pacemaker set at 100 BPM was placed in the left paracostal region as described previously.^{6,7}

Postoperative recovery was uneventful, and the dog was managed successfully with monthly injections of desoxycorticosterone pivalate (1.25 mg/kg body weight) and daily prednisolone (0.25 mg/kg body weight). Regular cardiac examinations showed the pacemaker to be functioning normally with the pulse generator situated in the left paralumbar fossa.

After two years without complications, the dog was presented for migration of the pulse generator to a ventrolateral location. One week later overlying skin became inflamed. There was a small area of alopecia, but skin was intact, dry, and slightly pink. A fluctuant fluid-filled sac was palpable superficially and dorsally to the pulse generator. An aspirate specimen showed this to be an abscess from which

Pseudomonas aeruginosa was cultured that was sensitive only to gentamycin and carbenicillin. No other abnormalities were detectable on physical examination. A CBC count was within normal limits. The abscess was drained under local anesthesia and the dressing changed twice a week. Gentamycin (4 mg/kg body weight) was administered intramuscularly daily (twice the first day). Blood creatinine level increased to 1.2 mg/dl after 10 days, and the dose of gentamycin was reduced to 2.5 mg/kg body weight. After four weeks, discharge was much reduced, but culture still yielded the same organism. Muscle twitching developed over the pulse generator, and pacing failure occurred when the generator was not compressed by the bandage.

With the failure of conservative therapy, a two-stage surgical procedure was undertaken to insert a new pacemaker on the opposite side and then remove the infected one. The heart was exposed through a right fifth intercostal space thoracotomy. The original pacing wire attached to the left ventricle did not appear to be infected within the thorax. The wire was severed a few centimeters from its site of attachment to the heart, and a silicone lead cap was glued in place over the remaining segment. A new corkscrew electrode (Medtronics 6717) was inserted with 2.5 turns into the right ventricular wall near the apex in accordance with the manufacturer's recommendations. The new pulse generator was placed medially to the right latissimus dorsi muscle to keep it distant from the abscess. It was fixed in place with catgut sutures through fascia and muscle along the ventral edge of the latissimus dorsi muscle.



Figures 2A, 2B—Electrocardiogram made three weeks after pacemaker replacement (A) demonstrates regular pacing at 100 BPM when skin was compressed over the pulse generator. The pacemaker stimulus artifact (S) is followed immediately by ventricular depolarization. When no pressure was applied (B), the pacemaker occasionally failed to stimulate the heart, and a ventricular escape beat occurred (V).

After closure of the thorax, the dog was turned over and the infected pulse generator and surrounding tissue radically excised. The old generator was surrounded by purulent fluid within a thickened fibrous pocket. There appeared to be no extension of infection to adjacent tissues or along the lead. The pacing wire was withdrawn with the generator and the tunnel ligated. The entire thick-walled fibrous pocket was removed. Three Penrose drains were placed during closure of the infected side. A compression bandage was applied to minimize edema formation. Carbenicillin (22 mg/kg body weight IV *q* 8 hrs) was administered in combination with gentamycin (1 mg/kg body weight IV *q* 12 hrs) because sensitivity tests indicated they both still were effective. However, gentamycin was administered only twice because polyuric renal failure developed postoperatively, and creatinine level rose to 7.1 mg/dl. Carbenicillin was continued for five days postoperatively until discharge from the hospital when intravenous administration was no longer practicable. Renal failure resolved over 72 hours with intensive fluid therapy and dopamine infusion (3 μ g/kg body weight per minute). A postoperative leukocytosis (26,000/mm³) persisted for two weeks but returned to normal when Penrose drains were removed.

One week after surgery, edema developed around the new pulse generator. The generator then migrated to a more ventral location on the chest wall, slipping below the latissimus dorsi muscle into a dependent vulnerable subcutaneous position just laterally to the sternum. It was manipulated externally into its original surgical position and held in place for two weeks by an external chest bandage to permit development of a fibrous pocket which would maintain its position. This was partially successful, but the pulse generator still migrated occasionally to the sternum, and the owner learned to reposition it. Intermittent pacing failure sometimes occurred when the pulse generator dropped out of position. If the pulse generator was held firmly in place, it would pace the heart at a regular rate of 100 BPM [Figure 2A]. However, when it dropped into a loose parasternal position, intermittent pacing failure occurred, and ventricular escape beats were noted [Figure 2B]. Chest radiographs revealed a few twists in the lead wire [Figures 3A, 3B]. At four weeks after surgery the pulse generator was no longer dropping out of its pocket, and it was functioning normally.

At eight weeks the pulse generator was firmly in position and the dog bright and alert, but heart rate was slow. An electrocardiogram revealed pac-

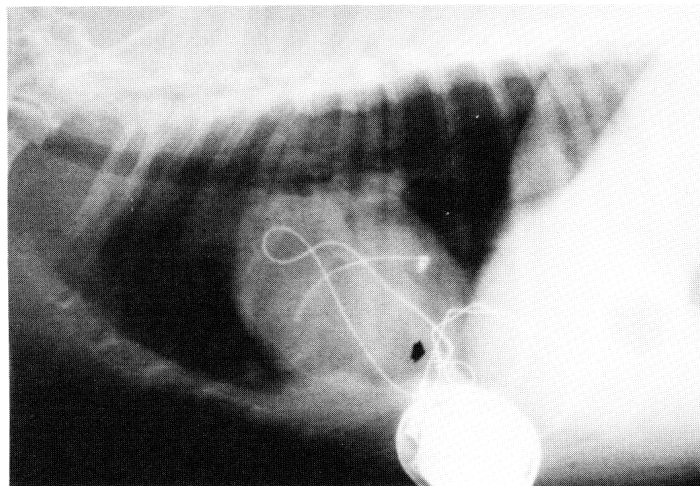


Figure 3A

Figures 3A, 3B—Lateral and dorsoventral radiographs two weeks after pacemaker replacement. The pulse generator is out of its pocket in a right parasternal location. The replacement corkscrew lead is at the apex of the right ventricle (arrow), and the lead wire has a few twists. The original corkscrew lead still is in place at the apex of the left ventricle.

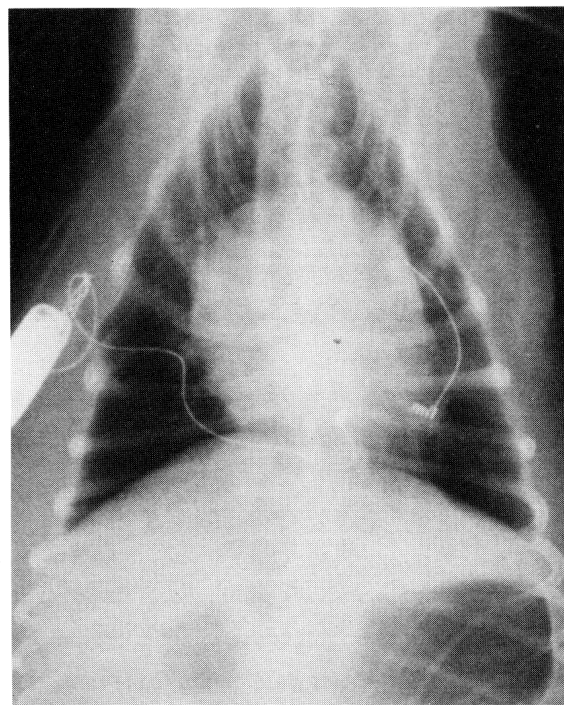


Figure 3B

ing failure with a regular idioventricular rhythm at 55 BPM and pacemaker stimulus artifacts 600 milliseconds after each ventricular beat at the programmed inhibition interval [Figure 4]. Radiographs showed the pacemaker lead to be severely twisted on itself causing tension on the electrode at its insertion. However, the site of attachment into the ventricle appeared to be unchanged [Figures 5A, 5B]. Therefore, it was presumed that fibrosis had occurred around the pacemaker lead and there was failure of conduction from the pacing electrode to the surrounding myocardium (exit block). At 12 weeks the pulse generator was no longer palpable, having migrated into the axilla. Radiographs showed more twisting of the wire, and fluoroscopy showed separation and

displacement of the electrode from the original site in the myocardium [Figures 6A, 6B]. Occasional twitching of the shoulder muscles on some days suggested continued rotation of the pulse generator and intermittent contact of the negative terminal with the muscle groups concerned.

To reduce the dog's weight, food intake was restricted, and the dose of maintenance prednisolone was halved to 0.12 mg/kg body weight daily to reduce excessive appetite. This achieved moderate success with a weight loss of 10 kg over two years. A TSH test to rule out hypothyroidism as the cause of obesity was normal. In the absence of any evidence of circulatory failure, further surgery was not attempted, and the dog was well at the age of 10.5 years.

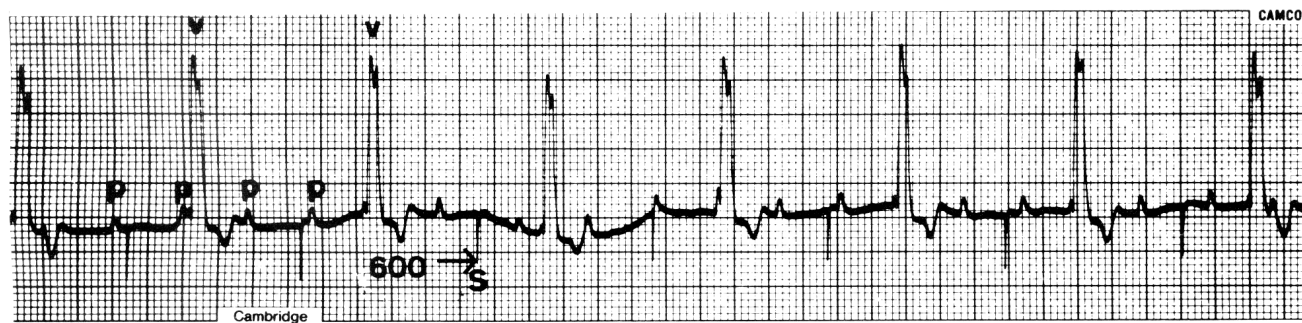

Figure 4—Electrocardiogram eight weeks after pacemaker replacement demonstrates loss of pacing capture. Recording shows the typical features of complete heart block with P waves (P) indicating an atrial rate of 160 BPM and wide QRST complexes indicating an idioventricular rhythm of 55 BPM. The pacemaker stimulus artifact (S) occurs 600 ms after each idioventricular beat (V) at the preset inhibition interval.

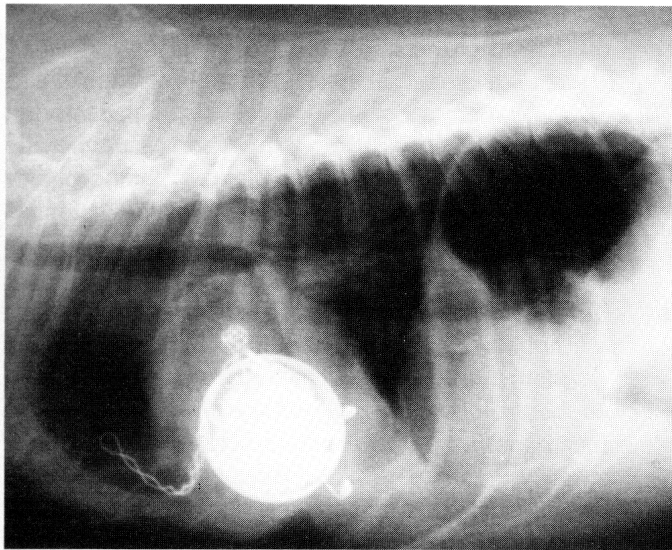


Figure 5A

Figures 5A, 5B—Lateral and dorsoventral radiographs eight weeks after pacemaker replacement. The pulse generator has moved to a midthoracic location, and the lead has twisted many more times creating tension on the corkscrew electrode. The twisted lead appears to be within the pleural cavity and to extend forward toward the thoracic inlet. Site of attachment of the electrode appears to be unchanged, although there is some displacement of heart shadow to the right when compared to previous radiographs [Figure 3].

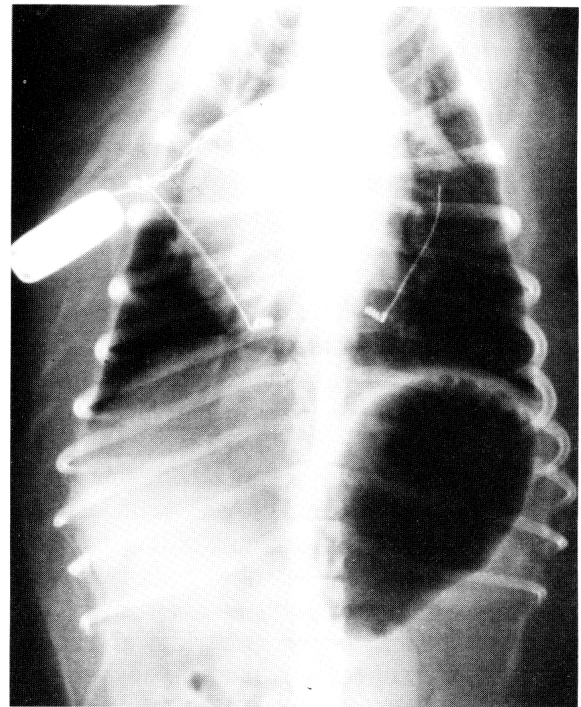


Figure 5B

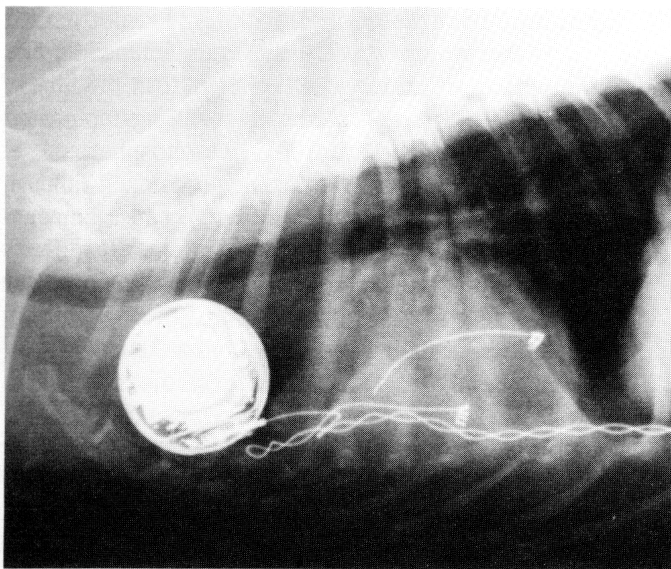


Figure 6A

Figures 6A, 6B—Lateral and dorsoventral radiographs 12 weeks after pacemaker replacement. The pulse generator is in the axilla, and there has been further twisting of the lead. The twisted lead is displaced toward the diaphragm, and the corkscrew has dislodged from the heart apex and is in a right lateral location.

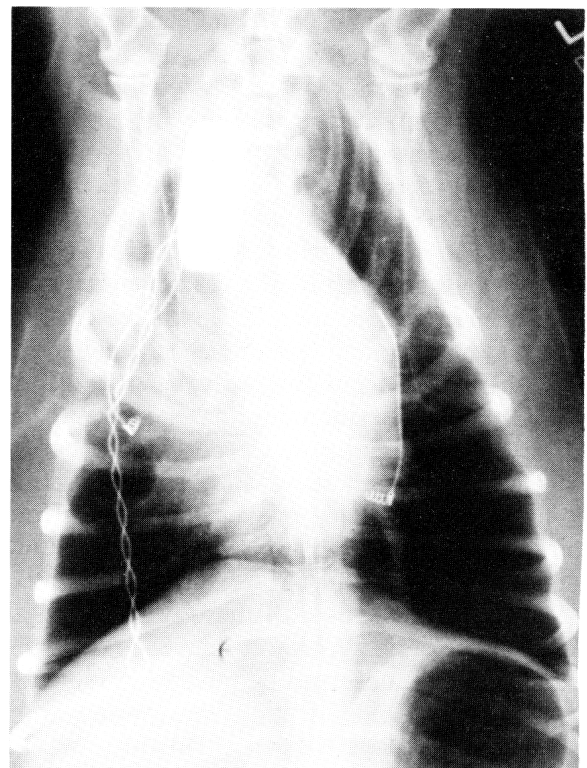


Figure 6B

Discussion

Third-degree (complete) atrioventricular (AV) block is uncommon in dogs.⁸ It has been recognized in association with a variety of cardiac diseases, but histological studies to identify specific site and nature of abnormality seldom are carried out because it is necessary to examine multiple sections along the AV conduction pathway. Various processes and causes of AV block that have been identified include endocarditis, hemorrhagic fibrosis, degeneration, neoplasia, arteriosclerosis, myocardial infarction, cardiac trauma, electrolyte abnormalities (hyper- and hypokalemia), and toxic substances including digitalis overdosage.⁹

The cause of AV block in the present case initially was thought to be hyperkalemia secondary to hypoadrenocorticism. However, hyperkalemia was not marked, and the block persisted after correction of electrolyte abnormalities which suggested the presence of an underlying pathological process. The dog had been under treatment for hypoadrenocorticism for two years prior to its emergency admission. Existence of conduction disturbances prior to admission is not known. Complete AV block created experimentally in normal dogs can cause congestive heart failure even without exercise stress.¹⁰ In clinical patients the usual presenting signs are those of congestive heart failure or fainting due to bradycardia.^{3,4,11,12} In the present case it is difficult to distinguish the relative contributions of the Addisonian crisis and complete heart block in the presenting episode of circulatory collapse and unresponsive state. Stabilization was not achieved without pacing, yet the dog has done well in the past year without the benefit of pacing. It appears that the current idioventricular heart rate of 55 to 60 BPM is sufficient to maintain adequate circulation under circumstances of restricted exercise and normal electrolyte balance.

Artificial pacemakers have been a well-established therapeutic modality in veterinary medicine since the first application reported 22 years ago.⁶ Incidence of complications appears to be higher than in man and include pacemaker migration, ulceration of overlying skin, exit block, lead fracture and dislocation, generator failure, and postoperative infection.^{1,4} One or more of these was seen in all 11 dogs in one series.⁴ A lower incidence of complications has been observed by others.^{11,12} Incidence of pacemaker-related infections has varied with the technique employed. Four of 44 dogs (9%) with pacemaker leads placed by lateral thoracotomies and the generator placed in the subcutaneous tissue developed pacemaker-associated infections.^{3,4,12} None of 27 implants done by an abdominal trans-

diaphragmatic approach with the generator placed in the abdomen became infected.^{11,12}

Incidence of pacemaker-related infection in man also has declined, but 1% to 4% of patients still develop an infection.¹³ Infections can be life threatening and difficult to eradicate without replacing the pacemaker. Because of the seriousness of infections related to prosthetic material, it generally is recommended to place patients on prophylactic antibiotics at time of surgery. In the present case, the animal had indwelling catheters at the time of initial permanent pacemaker implantation, so prophylactic cephalothin treatment was given. The source of *Pseudomonas aeruginosa* infection two years after surgery is unknown. An indolent infection related to initial pacemaker surgery may have been responsible or organisms may have entered through the skin in the area of dermatitis where the pacemaker migrated after two years, though there was no evidence of perforation. However, it seems more reasonable to suggest that infection was hematogenous from an unknown source and led to breakdown of the usual fibrous supporting capsule that normally develops around a pulse generator. This would explain the sudden ventral migration of the pacemaker with subsequent inflammation.

Underlying endocrine or metabolic diseases also may have been a factor contributing to infection and pacemaker migration. Dose of maintenance steroids was within recommended levels but, at the time of infection, excessive water and food consumption and a slightly elevated serum alkaline phosphatase level (250 U/L) suggested excessive dosing. Although steroids in high doses are known to cause immunosuppression, it is doubtful that maintenance levels given prior to infection were a predisposing factor in that regard. It is possible that fibrous tissue encapsulation of the pacemaker may have been less than usual because of the steroid administration. This might have allowed the original pacemaker to migrate to the ventral abdomen and the second pacemaker to migrate to the axilla. Steroid dose was reduced to half without untoward effects over the last 18 months. Obesity also could have contributed to infection or poor encapsulation and pacemaker migration. In man, increased postoperative infection rates have been reported in obese patients.¹⁴ Animals with the degree of obesity observed in this case have thick layers of fat between muscle layers. Such fat has a consistency approaching that of soft jello and offers little resistance to surgical dissection or compression around a pacemaker.

Treatment of pacemaker infections is the subject of some controversy.^{13,15} Some have reported

success with conservative measures including closed irrigation, local debridement, and systemic antibiotics, while others advocate complete surgical removal and replacement of pacemaker and wire. Risks associated with the first course relate to spread of infection along the electrode into adjacent tissues and systemically. In view of difficulties associated with open wound management, risk of pacemaker dislodgment, and cost of hospitalization, surgical removal of the infected pacemaker would seem to be advisable in the dog. Irrigation was not pursued aggressively in the present case because the owner insisted upon outpatient management. However, medical treatment did contain the infection over the Christmas holiday period until a replacement pacemaker could be obtained and surgery arranged. Other difficulties in this case concerned insensitivity of the organism to antibiotics and development of nephrotoxicity. Although gentamycin is known to be nephrotoxic, this complication usually is mild and reversible if detected before extensive damage is done. Long-term use is possible with careful monitoring of renal function.¹⁶ Carbenicillin was administered as soon as the dog was hospitalized and intravenous administration became practicable. Penicillins are known to have a synergistic action with gentamycin, and additionally it was hoped that combination therapy would slow development of antibiotic resistance.¹⁶ Carbenicillin became the only appropriate antibiotic when elevation of serum creatinine levels precluded further administration of gentamycin.

Rotation of the pacemaker has not been described in the dog. A similar occurrence called "Twiddler's syndrome" has been reported in man⁵ where rotation of the pacemaker either spontaneously or as a result of idle flipping of the pacemaker in its subcutaneous pocket by the patient causes spiral shortening of the lead which may dislodge the electrode from the myocardium or cause fracture of the pacing wire. The electrode will continue to pace only if it remains in contact with the myocardium. In the present case, it is likely that some of the initial lead twisting was caused by repeated repositioning of the second pacemaker under the latissimus dorsi muscle by the owner and clinicians involved in the case. This manipulation was discontinued after the pacemaker seemed to be stabilized in position. Additional spiraling which subsequently caused migration of the pacemaker into the axilla probably stemmed from movement of the leg during normal locomotion.

Encasement of pacemakers in a Dacron pouch has been recommended to promote encapsulation and stabilization and to reduce frequency of skin erosion,

particularly in older patients with thin skin.¹⁷ Use of a Dacron pouch in this patient would have made stabilization of the second pacemaker under the latissimus dorsi muscle more secure and probably would have prevented pacemaker rotation and migration. Placement of the second pulse generator inside the abdomen in the present case also may have avoided Twiddler's syndrome. However, because of the infected first pacemaker there was concern about risk of infectious peritonitis, so the abdomen was not entered.

Addendum

Two years after placement of the second pacemaker the dog was presented for a progressive lethargy, anorexia, vomiting, and mild dyspnea over a three-day period. Electrocardiography revealed regular idioventricular rhythm at 60 BPM. The pacemaker stimulus artifact was present but only inhibited by every other idioventricular beat. Thoracic radiographs and aspiration revealed pyothorax. There was equivocal evidence that the pulse generator might be inside the thorax. At exploratory surgery to locate and remove the implant, the generator and leads all were found inside the right pleural cavity covered by a thick fibrinous capsule which was extensively adherent to the pleura and adjacent lung lobes necessitating a lobectomy to remove the adherent mass. Extensive pleural thickening was present on the other lung lobes. Hypoventilation and cardiac arrest occurred 18 hours after surgery. Necropsy examination revealed chronic proliferative pleuritis with fibrous encasement of all lung lobes. Multifocal chronic nonsuppurative myocarditis also was present. There was a 3 mm thick fibrous sac surrounding the pacemaker and twisted leads. The pulse generator and inside of the sac were coated with a brownish mucoid exudate similar to that found in the sac around the infected pulse generator two years earlier. Culture yielded *Pseudomonas* sensitive to piperacillin, ticarcillin, and ceftazidime and resistant to gentamycin, carbenicillin, and all other agents tested.

References

1. Klement P, Del-Nido P, Wilson GJ. The use of cardiac pacemakers in veterinary practice. *Comp Cont Ed* 1984;6:893-903.
2. Yoshioka MM, Tilley LP, Harvey HJ, et al. Permanent pacemaker implantation in the dog. *J Am Anim Hosp Assoc* 1981;17:746-50.
3. Lombard CW, Tilley LP, Yoshioka MM. Pacemaker implantation in the dog: survey and literature review. *J Am Anim Hosp Assoc* 1981;17:751-8.

(Continued on next page)

References (cont'd)

4. Bonagura JD, Helprey ML, Muir WW. Complications associated with permanent pacemaker implantation in the dog. *J Am Vet Med Assoc* 1983;182:149-55.
 5. Bayliss CE, Beanlands DS, Baird RJ. The pacemaker Twiddler syndrome: a new complication of implantable transvenous pacemakers. *Can Med Assoc J* 1968;99:371-3.
 6. Buchanan JW, Dear MG, Pyle RL, Berg P. Medical and pacemaker therapy of complete heart block and congestive heart failure in a dog. *J Am Vet Med Assoc* 1968;152:1099-1109.
 7. Eyster GE, Probst M. Basic cardiac procedures. In: Slatter DH, ed. *Textbook of small animal surgery*. Philadelphia: WB Saunders, 1985:1107-31.
 8. Patterson DF, Detweiler DK, Hubben K, Botts RP. Spontaneous abnormal cardiac arrhythmias and conduction disturbances in the dog (a clinical pathologic study of 3000 dogs). *Am J Vet Res* 1961;22:355-69.
 9. Tilley LP. *Essentials of canine and feline electrocardiography*. Philadelphia: Lea & Febiger, 1985:172-3.
 10. Starzl TW, Geaertner RA. Chronic heart block in dogs: a method for producing experimental heart failure. *Circulation* 1955;12:259-70.
 11. Fox PR, Matthiesen DT, Purse D, Brown NO. Ventral abdominal transdiaphragmatic approach for implantation of cardiac pacemakers in the dog. *J Am Vet Med Assoc* 1986;189:1303-8.
 12. Fingerroth JM, Birchard SJ. Transdiaphragmatic approach for permanent cardiac pacemaker implantation in dogs. *Vet Surg* 1986;15:329-33.
 13. Stryker DW, Palmer DL. Infections associated with pacemakers. In: Sugarman B, Young EJ, eds. *Infections associated with prosthetic devices*. Boca Raton: CRC Press, 1984:113-22.
 14. Pasulka PS, Bistran BR, Benotti PN, *et al*. The risk of surgery in obese patients. *Ann Intern Med* 1986;104:540-6.
 15. Choo MH, Holmes DR, Gersh BJ, *et al*. Permanent pacemaker infections: characterization and management. *Am J Cardiol* 1981;48:559-64.
 16. Lietman PS. Aminoglycosides and spectinomycin. Aminocyclitols. In: Mandell EL, Douglas G, Bennett JE, eds. *Anti-infective therapy*. New York: Wiley Press, 1985:109-45.
 17. Parsonnet V. A stretch fabric pouch for implanted pacemakers. *Arch Surg* 1972;105:654.
-