



Spring 4-22-2017

Comparison Between Genetic and Morphological Sex of the Cranium

Elizabeth V. Pierce

University of Pennsylvania, pieli@sas.upenn.edu

Follow this and additional works at: http://repository.upenn.edu/anthro_seniortheses

 Part of the [Biological and Physical Anthropology Commons](#)

Recommended Citation

Pierce, Elizabeth V., "Comparison Between Genetic and Morphological Sex of the Cranium" (2017). *Anthropology Senior Theses*. Paper 179.

Comparison Between Genetic and Morphological Sex of the Cranium

Abstract

Morphological methods are relied upon to determine the sex of skeletal remains of both archaeological and forensic significance. The characteristics commonly examined in these morphological methods have a large margin of error, especially when it comes to partial or fragmentary cranial remains. The case could be made from this morphological study that sex attributed to fragmented remains where not more than one commonly scored trait is available for examination should not be considered as being fully reliable. In this study, I examined 20 crania from a collection from Tepe Hissar to compare morphological sex and genetic sex. Overall, the mastoid process should be considered a better indicator of sex than the supraorbital margins, nuchal crest, supraorbital ridges, and mental eminence. It is safe to assume that if the genetic sex and the morphological sex are the same, that sex is definitive. Conversely, it is difficult to determine which is correct when the morphological sex does not align with the DNA-determined sex. Through this research I have concluded that DNA analysis and morphological methods have the most significant advantages, especially over their alternatives, analysis of tooth size and wear and measurements plugged into discriminant functions, but have significant drawbacks.

Keywords

morphological sex, genetic sex, DNA, crania, mental eminence, mastoid process, supraorbital margin, supraorbital ridge, nuchal crest, skull

Disciplines

Anthropology | Biological and Physical Anthropology

COMPARISON BETWEEN GENETIC AND MORPHOLOGICAL SEX OF THE CRANIUM

By

Elizabeth V. Pierce

In

Anthropology

Submitted to the
Department of Anthropology
University of Pennsylvania

Thesis Advisor: Janet Monge

2017

Abstract

Morphological methods are relied upon to determine the sex of skeletal remains of both archaeological and forensic significance. The characteristics commonly examined in these morphological methods have a large margin of error, especially when it comes to partial or fragmentary cranial remains. The case could be made from this morphological study that sex attributed to fragmented remains where not more than one commonly scored trait is available for examination should not be considered as being fully reliable. In this study, I examined 20 crania from a collection from Tepe Hissar to compare morphological sex and genetic sex. Overall, the mastoid process should be considered a better indicator of sex than the supraorbital margins, nuchal crest, supraorbital ridges, and mental eminence. It is safe to assume that if the genetic sex and the morphological sex are the same, that sex is definitive. Conversely, it is difficult to determine which is correct when the morphological sex does not align with the DNA-determined sex. Through this research I have concluded that DNA analysis and morphological methods have the most significant advantages, especially over their alternatives, analysis of tooth size and wear and measurements plugged into discriminant functions, but have significant drawbacks.

Introduction

The ability to estimate the sex of uncovered remains is an important aspect of a physical anthropologist's job. Determining sex for archaeological remains contributes to the demographic profile for that archaeological site (Balm & Patterson, 2013). A demographic profile is used to make conclusions about mortality rates at various points in the life cycle for each sex (Balm & Patterson, 2013). Understanding the demographic of the burial can yield information about the demographic of the site in general (Mays, 2010). Insight into the particular funerary practices as well as the social structure of the society, including gender roles, can also be ascertained (Mays, 2010). Another reason to determine sex of skeletal remains from archaeological sites is that if there is a change in the way the different sexes are treated in death by the people that once inhabited the site, it can be noted (Afshar, 2014). From a forensic standpoint, the assignment of sex is key to the identification of the individual and thus key to the investigation into his or her death (Pickering & Bachman 2009). Clearly, determining sex is important, even for long dead individuals (Mays, 2010).

One approach to determining sex is through morphological identification. Morphological methods are relied upon to determine the sex of skeletal remains of both archaeological and forensic significance. The characteristics commonly examined in these morphological methods have a large margin of error, especially when it comes to partial or fragmentary cranial remains. Morphological methods are based on the sexual dimorphism of the human skeleton. Sexual dimorphism mainly results from testosterone differentiating males, initiating growth that females do not undergo (Mays, 2010). When male hormones are not present, the skeletal elements appear female as proven in a study where sex hormones were removed from mice (Mays, 2010). Female

could thus be considered the base sex from which males diverge (Mays, 2010). There is, however, the exception of the pelvis, which is altered by each of the respective sex hormones (Mays, 2010).

The skull and the pelvis display the greatest levels of sexual dimorphism (Mays, 2010); thus, these skeletal elements are the most useful for the assignment of sex. The pelvic bone is the most reliable for morphological sex (Duric, et al, 2005), as it can yield an accuracy rate of 90% on its own (Pickering & Bachman 2009). After the pelvis, the skull is the most accurate skeletal element to use for assignment of sex to human remains (Pickering & Bachman 2009). When relying just on the skull, however, accurate determination of sex dips from 100 percent (based on the use of the pelvis and the skull together) to 70.56 percent (Duric, et al, 2005), though Mays claims the skull alone can allow for an accuracy rate as high as 92 percent (2010). It is said that without the mandible in reasonable condition, sexing a human skull remains accurately occurs 80 percent of the time, whereas if the mandible is present, sexing with just the skull occurs with 90 percent accuracy (Kozerska et al, 2015).

Perhaps the presence of an intact mandible is the cause of such variation in the frequencies of accuracy presented by Duric et al and Mays. Shape of the mandible is so reliable, Rogers claims, because it changes as an individual ages, thus becoming increasingly sexually dimorphic (2005). Features that develop during childhood are not yet sexually dimorphic because they develop prior to sexual maturity and thus prior to when sexual differentiation in the skeleton becomes apparent. Rogers is making the statement that the mandible changes shape after the skeleton has begun the process of specializing to the sex of the individual, so it becomes indicative of the sex of the individual.

It is very often the case that the pelvis is either not present or not preserved well enough to make an anthropologist certain enough to assign sex. It is then that the skull alone is used to determine sex. As stated above, making accurate determinations of sex for skeletal remains of archaeological and forensic cases is very important. The entire interpretation of a site and maybe of an entire culture can be wrong if the sexes of the individuals excavated are incorrect. Likewise, if sex is assigned incorrectly in a forensic case, the individual or individuals may not be identified and the investigation becomes stagnated. Anything less than 100 percent accuracy in determination of sex leaves a margin of error too large for comfort.

Background to the Research Problem

Sierp and Henneberg write that it is helpful to understand the gender roles of the population from which the archaeological skeletal remains originate as these roles will be reflected in the development of the muscles used in their daily routine activities and therefore will be shown on their bones (2015). There is a problem with this, however, because typically gender roles are uncovered once sex has been determined, not before. After assignment of sex, the buried objects associated with that individual are interpreted, so it could very well be the case that no knowledge of gender roles exists yet. There are methods for estimating sex that are much more reasonable, including tooth examination, metric methods, and DNA analysis in addition to morphological methods. It seems that tooth size is an unreliable tool with which to estimate the sex of an individual (Rogers, 2005). This is most likely due to the fact that the guideline for this method is simply that male teeth are larger than female teeth. This kind of relative sexing can be wildly inaccurate.

There are definite problems with using discriminant functions through programs like FORDISC to determine the sex for a set of remains metrically (Rogers, 2005). For instance, there is an overlap of males and females in measurements of sexed individuals, making sexing based on measurements unreliable (Balm & Patterson, 2013). It is true that fragmented bones are nearly impossible to sex using metric methods, as the functions require measurements from particular features on each bone (Rogers, 2005). It is also the case that populations differ in size of each bone, which can easily lead to an incorrect estimation of sex unless the particular measurements for that population are known (Rogers, 2005). Using metric methods to determine sex can lead to misinterpretation if the measurements are plugged into the wrong function (Sierp & Henneberg, 2015). Examining the remains of a person of unknown origins makes it difficult to choose the correct function in which to enter the metric information (Sierp & Henneberg, 2015); thus, metric methods are severely limiting for both archaeological and forensic cases alike.

Using DNA analysis for sex has been deemed the most accurate method for determining sex when a viable sample is taken (Rosing et al, 2007). The Polymerase Chain Reaction allows the small amounts of DNA that survive in ancient skeletons to be amplified and potentially yield viable information (Mays, 2010). Testing DNA, however, is an expensive process (Rosing et al, 2007). Because DNA testing is so expensive, it is only used when sex cannot be determined morphologically and the information is somehow significant (Mays, 2010). Also, between one and two thirds of DNA tests yield inconclusive results (Rosing et al, 2007). Moreover, DNA can become contaminated, whether it is from the laboratory technician, from other commingled remains, or even from elements in the surrounding soil (Rosing et al, 2007). The way the test is carried out, it looks for either the effects of a single chromosome (X) or the effect two

chromosomes (XY) (Mays, 2010). If a male handled a female specimen, his DNA could contaminate the sample because the Y chromosome would be present on the sample (Mays, 2010). Despite these drawbacks, DNA is still regarded as the definitive method of sexing any set of human skeletal remains, supposedly yielding the most accurate results.

“Morphological methods [of sexing human skeletal remains] rely on features which arise from an interaction between genetically controlled sex-linked patterns of growth and development, with environmental influences that may differ according to gender (Sierp & Henneberg, 2015).” Rogers claims that experienced physical anthropologists should have an accuracy of 90% with just the skull (2005), most likely including the mandible. To make the best determination of sex should be made based on as many skeletal elements as possible (Pickering & Bachman 2009), even if that means just looking at several features of just the skull. Several features should be used in conjunction, as their accuracy rate is much higher together (Rogers, 2005). More often than would be preferable, a skull has features that are neither overtly male nor overtly female, making determining sex a difficult job. Using several traits in conjunction with each other allows the anthropologist to compensate for average features that could be male or female (Salisbury, 2012).

Duric et al’s study concluded that the features of the skull used to determine sex vary too widely from population to population to expect 100% accuracy without the pelvis (2005). Expectations of high accuracy with only the skull are debunked further by the results of Sierp and Henneberg’s study, which showed that there was not one individual in the 20 they observed that was consistently deemed the same sex through their 15 tests, seven of which were metric and eight of which were morphological (2015). Only 45 percent of the individuals used in this

study were determined to be of one sex by each of the eight morphological methods (Sierp & Henneberg, 2015), meaning that just nine sets of remains out of the 20 had all morphological features indicative of a single sex. Of the 20, 17 did have one sex that was more often attributed to them than the other (Sierp & Henneberg, 2015), however, proving that the more morphological features that are considered in tandem, the better.

Determining sex morphologically using just the skull can lead to more female classifications than male, as the dimorphic features rely on the continued growth of the male to be determined as such. The skull continues to add bone as an individual ages (Rogers, 2005). This is how younger males are mistakenly determined to be female and older females are misinterpreted as male (Rogers, 2005). The more gracile nature of the younger male skull suggests femaleness, just as the thicker, more robust nature of the older female skull is suggestive of maleness. Thus, age at time of death may hinder determination of sex morphologically (Rogers, 2005). On the other side of this, though, if age at time of death is known, morphological methods of sexing skeletal remains might be easier. In the case of Wenu-hotep, an Egyptian mummy, the coffin marked it as that of a women, but features of the skull suggested it actually contained a male individual (Pickering & Bachman 2009). A CAT scan was performed, revealing a distinctly female pelvis and reconstructing the tissue of desiccated breasts (Pickering & Bachman 2009). The mummy was indeed female as the hieroglyphics on the coffin claimed (Pickering & Bachman 2009). Relying on the skull alone would have been erroneous (Pickering & Bachman 2009).

Using the same morphological methods of determining sex with every set of skeletal remains means that we believe that sexual dimorphism displays itself in the same way over all

time and space (Balm & Patterson, 2013). This can be a critical mistake because humans grow in different ways depending on the environment in which they live. Population-specific growth is important particularly when dealing with the skull (Rosing et al, 2007) because the shape of the skull is determined by a combination of genetic and environmental factors (Mays, 2010). This makes knowledge of the expected population rather important, but seemingly impossible. An anthropologist can hardly be expected to be readily equipped with knowledge of any given population before being asked to analyze skeletal material, especially in forensic cases when ancestry is unknown. Even in archaeological excavations, the ancient people may not be similar enough to the existing population of the region, rendering it impossible to be aware of the norms for the archaeological population.

If Kozerska's statistics are correct, that 80 percent of the time sex can be correctly assigned with crania without the mandible and 90 percent of the time with the mandible (2015), then 10 to 20 percent of crania are not sexed correctly. That is too many individuals missing their correct identity. The high frequency of inconclusive DNA testing, between one and two thirds of all tests, is also cause for concern (Rosing et al, 2007). DNA testing technology will most likely be improved in the future and hopefully become less expensive. In the meantime, morphological methods are widely accepted as the best means of determining sex without hemorrhaging money on DNA analysis, but the less than desirable statistics that accompany morphological sexing should be causing more concern than they seem to be.

It is my belief that the morphological methods so heavily relied upon in archaeological and forensic cases are not as reliable as we in these fields would like. Though of course no one trait is so reliable that it can be used over the others, is there one that should be perhaps regarded

as just a bit more highly reliable in comparison to the others to use when the skull is either scored average in most traits or so fragmented that not all the desired characteristics are present to examine? In the case of fragmented skulls, is it possible to simply use the features that are present to accurately assign sex? As already stated, it is the case that one feature would not be considered definitive when there are multiple traits, but when that one trait is the only available to use in determining sex, that single trait suddenly carries much more weight than it should. More attention should be brought to these issues in an effort to increase the accuracy of assigning sex correctly through morphological methods, which are more cost effective relative to genetic testing and reliable in comparison to both metric discriminant functions and tooth examination.

Methodology

Tepe Hissar is an archaeological site on the northeast section of the Central Plateau in Iran (Afshar, 2014). This site was occupied from the late 5th millennium to the early 1st BC (Afshar, 2014). The University of Pennsylvania has been periodically excavating the site since 1931 (Afshar, 2014). Nearly 1,637 burials were excavated during Penn's sojourns to this site, though not all of them are detailed in the records (Afshar, 2014). The research I conducted was with the University of Pennsylvania's skeletal collection from Tepe Hissar. I examined 50 complete crania and 50 fragmented crania and to determine the sex of each. The morphological traits I scored came from the guidelines put forth in *Human Osteology* (White, 2012), in which a chart is given showing five characteristics with values from one to five ranging from small and undeveloped to large and robust. Lower values generally correspond to female skeletal remains while higher values are typically attributed to males. The five traits White presents are those that

are most commonly used to determine the sex of an individual. These are the mastoid processes, supraorbital margins, supraorbital ridge, nuchal crest, and mental eminence. I also took into consideration the slant of the forehead and the squareness of the mandible when sexing these crania.

As this is the first experience I have had with sexing skeletal material, I examined more crania than the university determined genetic sex for, so that I could get a better feel for the practical application of the morphological techniques I learned through my undergraduate courses. Because testing is so expensive, it is not fiscally pertinent to test each and every set of skeletal remains from an archaeological site, especially one that yielded the remains of so many individuals. Sierp and Henneberg showed in their study that inexperience can be an advantage. The anthropologists involved in sexing the individuals in Sierp and Henneberg's project had no significant prior experience determining sex for skeletal material, so there was no biases incorporated into judging these remains (Sierp & Henneberg, 2015). Since these anthropologists had no extended experience working with one particular population, there is no bias working against the skeletal collection in front of him or her (Sierp & Henneberg, 2015). In this way, inexperience is an advantage. Likewise, I brought no preexisting knowledge of a particular population into my examination; thus, there were no biases preventing the assignments of sex that I made. In this way, inexperience is beneficial.

The point of this research is to evaluate and discuss the efficacy of morphological methods of assigning sex to human remains through a comparison with sex determined through DNA analysis prior to my research project. To do this, I first used morphological traits to sex 100 complete or fragmented crania without knowing which crania. I then compared the sexes I

determined to the genetic sexes previously determined through DNA analysis. Because of the high expense of DNA analysis, there is only a small sample of the 100 crania I examined that had a genetic sex to use in this comparison.

Results

For the purposes of this examination, I accepted the genetic sex as absolute, though as stated previously, the DNA tested could have been contaminated. With the exception of one skull, the DNA analysis seems to be accurate. For those crania I assigned a different sex to than determined through genetic tests, I could see where my own determination was incorrect. It was only object number 33-16-143 that the genetic sex was nearly inconceivable.

Of the 100 complete and fragmented crania I examined, genetic sex was available for 20 of them. Of these twenty, I was able to correctly assign sex to nine of them. This accuracy lines up well with the research conducted by Duric et al, which concludes that an inexperienced anthropologist is able to accurately determined sex using only the skull in 54.44 percent of the cases (2005). Their study also claimed that experienced anthropologists were able to assign correct sex for 70.56 percent of the remains in comparison (Duric, et al, 2005). Every study seems to have a different statistic for the accuracy for morphological sexing by experienced anthropologists, but they are all within about ten percent of each other. The results of my study suggest correct sexing for an inexperienced anthropologist can occur for 45 percent of the skeletal material.

Of the 20 crania I examined that also had genetic sex previously tested for and assigned, there were a total of 11 males and nine females. I had estimated six to be female and 14 to be

male. This means that, of the 11 males, I determined the correct sex of seven and of the nine females I sexed two accurately. Figure 1 displays the scores I attributed to each of the five cranial features as well as the sex I assigned and the genetic sex I compared those to afterward.

Different researchers find different traits to be of higher accuracy. Rogers claims that among the traits most helpful for her was the supraorbital margin (Rogers, 2005). She also claims that the mandibular shape should be of secondary considerations and the shape of the forehead should be considered next to last (Rogers, 2005). The most accurate feature on the skull in determining sex is the mandible, while the supraorbital margins are the least reliable (Duric, et al, 2005). For me, The most accurate feature was the mastoid processes by far. Coming in second were the supraorbital margins. The nuchal crest, supraorbital ridge, and mental eminence were all equally accurate, but less so than both the mastoid processes and supraorbital margins. Of the features that were given the average score of three, I was able to correctly assign sex almost exactly 50 percent of the time based on the other scored features as well as the shape of the eye orbits, slant of the forehead, shape of the mandible, and overall weight and robusticity of the crania.

Discussion

The most useful feature to determine sex morphologically is the mastoid process. This serves as the attachment site for the sternocleidomastoid muscle, one of the largest muscles in the neck. The mastoid process is almost invariably larger in any male and any female. Figure 2 is representative of a female with rather small attachment sites for the sternocleidomastoid while the mastoid process of the male cranium in Figure 3 are so large they are raised off the surface of

the temporal bone. The sexual dimorphism exerted on the human skeleton is evidently particularly strong when it comes to the mastoid processes. I would suggest that the mastoid process be relied upon more heavily than the other scored features when the other features are not present, too fragmented for a conclusive evaluation, or fall directly in the average range.

After the mastoid process, the most reliable feature is the supraorbital margins, which are blunt for males and sharp for females. The supraorbital margins are scored by feeling the top of the eye orbit for relative sharpness or bluntness. Some anthropologists do not find this feature of particular use, but the research I conducted proves otherwise. Several of the skulls I examined scored average in several features, but the supraorbital margin could be relied upon if that feature itself was not considered average.

The supraorbital ridge, nuchal crest, and mental eminence are all of equal weight when determining morphological sex. The supraorbital ridge is the attachment site for muscles of mastication and tends to be thicker and protrude further off the frontal bone in males than in females. Figure 4 shows the stereotypical supraorbital ridge size for a female while Figure 5 displays another female, but one that has a highly developed brow like a male would have. Other than the ridge, however, the cranium shown in Figure 5 has female features. The supraorbital ridge, then, is reliable enough to help confirm sex, but should not be considered definitive above other traits. When examining the skulls myself, I wrongly believed that the supraorbital ridge could in fact be considered more highly than the other features. I believed the skull pictured in Figure 5 to be male, when in fact it was female. More traits suggested female than male. Going against the more commonly suggested sex in favor of the sex suggested by the supraorbital ridge is a mistake, as is true for most of the features discussed here.

The nuchal crest, the area toward the base of the occipital that serves as the attachment site for several muscles, is stereotypically flat or nearly flat on female crania. On the crania I examined, however, the nuchal area could be highly developed on females. Figure 6 shows the nuchal area of a female skull, that appears far too developed to belong to a female. The other features of that cranium, however, easily identify it as that of a female. Compared to the nuchal area shown in Figure 7, which is a very stereotypical male skull, the nuchal area of the skull in Figure 6 is larger. The case could be made, then, that the nuchal area is not a clear indication of sex on its own, considering that the skull in Figure 3 would be considered male if only the occipital bone was left to indicate sex. Of the 13 skulls that were either complete or were fragmented but had the nuchal area intact, two of them had nuchal crests indicative of the opposite sex than their true sex. Both of these were female with heavy ridges in the nuchal area. It is thus possible that females are misinterpreted as males due to having a nuchal area scored at or above a three.

The mental eminence is located at the midline of the mandibular body, where the right and left sides come together. This triangular protuberance of the mandible is, once again, more pronounced in males than females. With many of the fragmented skulls, there was not much left but the mental eminence with which to make an estimation of sex. In several of those cases, I wrongly went against the sex suggested by the mental eminence, yet, in other cases, I chose to go with sex foretold by the mental eminence over the other factors I was considering, but again was wrong. Three of the mandibles (fig.8) were missing teeth and the alveolar hole in which the missing teeth originally rested in the jaw were healed over. This lead me to believe they were older individuals and could therefore appear masculine when they were actually remains of a

female because as a human ages, bone is added to the skull, resulting in a more masculine appearance. This is an example of the age at time of death interfering with the determination of sex.

Assigning sex based on one feature alone leaves a wide margin of error, so in many cases, I examined other features that are not scored, but can be used in tandem with features that are scored. These include the shape of the eye orbits, slant of the forehead, shape of the mandible, and overall weight and robusticity of the skull. The eye orbits, in females, are more rounded and in males are square. This was of use when looking at the eye orbits of the cranium depicted in Figure 9. Another helpful trait is whether the forehead is slanted, indicating male, or long and flat, suggestive of a female. Figure 10 shows what this slope looks like and Figure 9 shows the flat forehead of a female as well. The shape of the mandible is somewhat reliable, as the mandibular ramus would be angled further back than a male's shorter ramus would be. Males also have very square mandible. The front of the mandible, where the mental eminence lies, is generally wider in males than females, but this is certainly not a rule. Several females had wide mandibular bodies that appeared male, like Figure 11. Using a measure like the overall robusticity of a skull can be misleading, as a skull can become rather rugged if the female exercised or performed the same actions as a male in the same population would. An example of this is discussed in the next paragraph.

The single most baffling DNA sex result was for the skull pictured in Figure 12, Figure 13, Figure 14, and Figure 15. The scores, three of which were fives and two of which were fours, suggested that it was a male cranium and mandible without a doubt. It was also one of the heaviest, most robust skulls I handled. The DNA result, however, concluded that it was, in fact,

female. It seems impossible that a DNA sample could be contaminated, making it come out as female rather than male because the way the analysis takes place usually contaminations occur in female skeletal remains, adding a Y chromosome where one was not present originally. This skull could be an anomalous result for the morphological method, but it goes to show that the problems of the morphological method are very real. If this was a forensic case, the investigative team would have immediately removed all the missing persons alerts for any female because this skull appears so masculine. The person would never be identified and the investigation of her death would go cold. This radical anomaly has the potential to occur in 1/20 cases, as it has in my research. Archaeologically speaking, that is a lot of females that are not represented as they should be at a given site; therefore affecting the interpretation of that place's history. Forensically, that indicates many lives that were cut short are never put to rest. As this is the sole purpose of forensic anthropology, it is devastating to the field if the statistic of my research is true for all collections.

Conclusion

Morphological methods are relied upon to determine the sex of skeletal remains of both archaeological and forensic significance. The characteristics commonly examined in these morphological methods have a large margin of error, especially when it comes to partial or fragmentary cranial remains. The case could be made from this morphological study that sex attributed to fragmented remains where not more than one commonly scored trait is available for examination should not be considered as being reliably sexed. Overall, the mastoid process should be considered a better indicator of sex than the supraorbital margins, nuchal crest,

supraorbital ridges, and mental eminence. After the mastoids, the supraorbital ridges are of the most use. It seems to me that it is safe to assume that if the genetic sex and the morphological sex are the same, that sex is correct. Conversely, it is difficult to determine which is correct when the morphological sex does not align with the DNA-determined sex, especially in cases similar to the skull represented in Figures 12-15.

Through this research I have concluded that DNA analysis and morphological methods have the most significant advantages, especially over their alternatives including analysis of dental size and wear and measurements plugged into discriminant functions. DNA analysis has the drawback of being wildly expensive and frequently inconclusive. Morphological methods are the most relied upon, but can be misleading. Revision of the features used in the morphological method of assigning sex to human remains should be made. In the fields of anthropology and archaeology, a 70-80 percent accuracy is favorable in comparison to the frequencies of the many theories and tests available, not just for determining sex for sets of human remains. The examination of human remains dictates much of the interpretation of archaeological sites and serves as the basis for forensic identification of skeletonized remains. Both humans of the past as well as humans in modern time deserve to be identified correctly, so that their stories can be understood, shared, and learned from. Thus, we should recognize the problems associated with assignment of sex morphologically and focus on realigning the associations we make about male and female skeletal elements.

References Cited

- Afshar, Z. (2014). Mobility and economic transition in the 5th to the 2nd millennium B.C. in the populations of the central Iranian Plateau, Tepe Hissar (Unpublished doctoral dissertation). Durham University.
- Balme, J., & Paterson, A. (Eds.). (2013). *Archaeology in Practice : A Student Guide to Archaeological Analysis* (2). Somerset, US. Wiley-Blackwell. Retrieved from <http://www.ebrary.com>
- Duric, M, Rakocevic, Z & Donic D. (2005). The reliability of sex determination of skeletons from forensic context in the Balkans. *Forensic Science International*, 147, 159-164.
- Kozerska, M., Skrzat, J., & Szczepanek, A. (2015). Application of the temporal bone for sex determination from skeletal remains. *Folia Medica Cracoviensia*, 55, 33-39.
- Mays, S. (2010). *The Archaeology of Human Bones* (2). New York, NY. Routledge
- Pickering, R. & Bachman, D. (2009). *The use of forensic anthropology* (2). Boca Raton, FL. Taylor & Francis Group
- Rogers, T. (May 2005). Determining the sex of human remains through cranial morphology. *Journal of Forensic Science*. 50.
- Rosing, F.W., Graw, M., Marre, B., Ritz-Timme, S., Rothschils, M.A., Rotzcher, K., Schmeling, A., Schroder, I., & Geserick, G. (2007). Recommendations for the forensic diagnosis of sex and age from skeletons. *Journal of Comparative Human Biology*. 58, 75-89.
- Salisbury, Elizabeth. "Sex Estimation Using Morphological Traits of the Skull." Poster presented at the Academic Excellence Showcase, Western Oregon University, May 31, 2012.
- Sierp, I. & Henneberg, M. (2015). The difficulty of sexing skeletons from unknown populations. *Journal of Anthropology*.
- White, T., Black, M., & Folkens P. (2012). *Human Osteology* (3). Burlington, MA. Elsevier Inc.

Figures:

Object Number	Nuchal Crest	Mastoid Process	Supra-orbital Margin	Supra-orbital Ridge	Mental Eminence	Sex (my guess)	Genetic Sex
33-16-050	3	2	3	2	2	F	F
33-16-110	5	2	1	1	1	F	F
33-16-118	4	5	3	5	np	M	M
33-16-128	3	3	2	3	5	M	F
33-16-136	3	3	3	4	2	M	F
33-16-143	5	5	5	4	4	M	F
33-16-209	3	3	3	3	np	M	M
33-16-196	2	3	2	4	2	F	M
33-16-012	np	np	np	np	1	M	F
33-16-013	np	np	np	np	2	M	F
33-16-023	3	5	5	5	4	M	M
33-16-044	np	np	np	np	1	F	M
33-16-051	4	3	np	np	3	M	M
33-16-093	np	2	3	5	2	M	F

33-16-2 31	np	np	np	np	2	M	M
33-23-0 05	np	np	2	3	2	M	F
33-23-0 67	4	3	3	3	2	M	M
33-23-0 72	3	3	3	2	np	F	M
33-23-0 74	np	np	np	np	3	F	M
22-23-1 24	3	5	5	5	4	M	M

Figure 1: Table of the score (1-5) given to each feature of every cranial element I assigned sex tho that also had genetic sex to which to compare them.

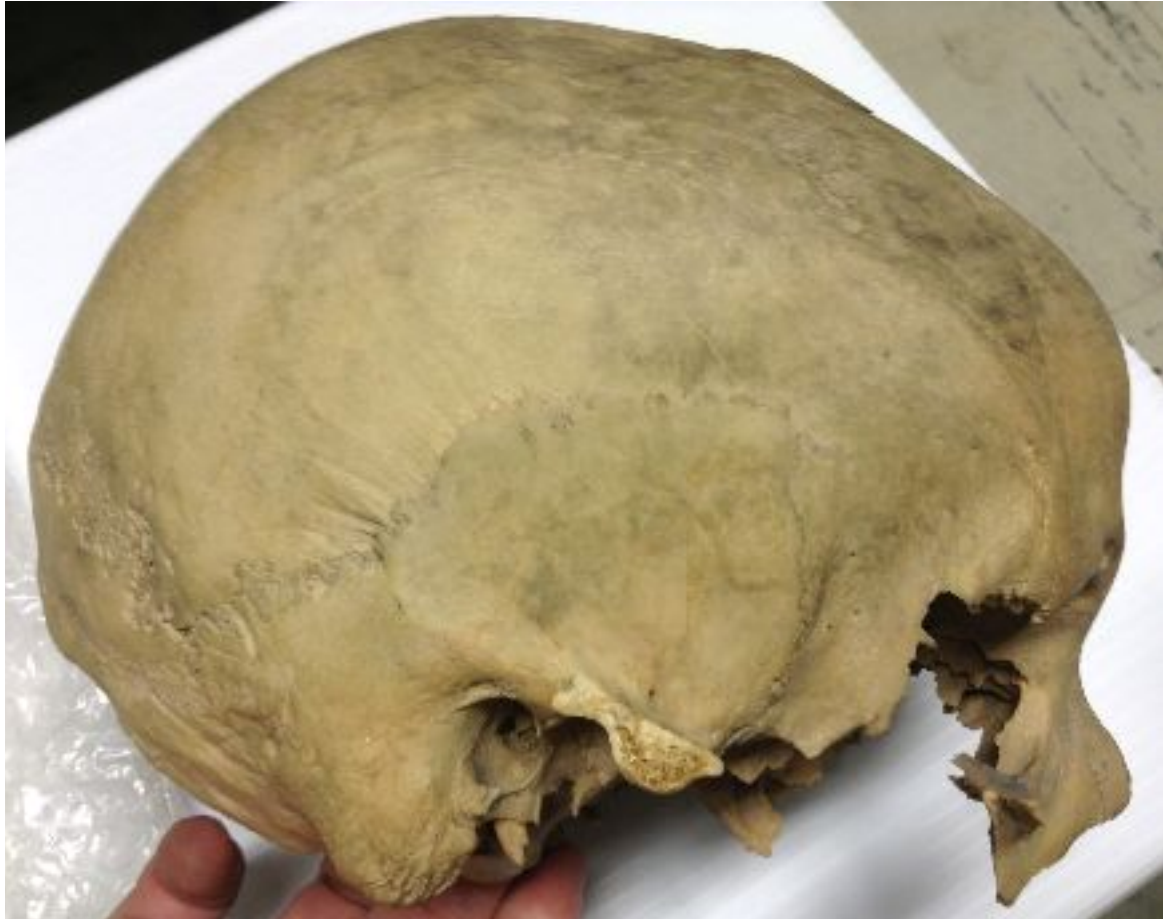

Figure 2: Small mastoid process of female, 33-16-050

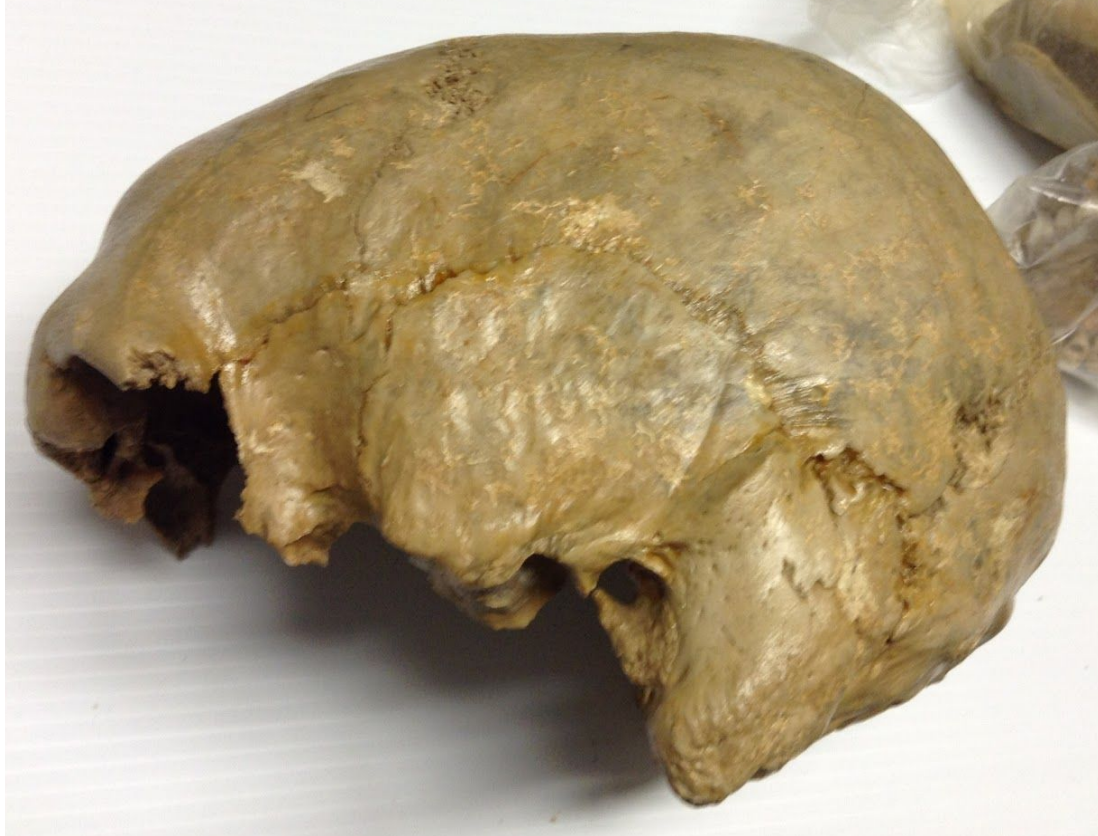

Figure 3: Large mastoid process of object number 33-16-023, a male

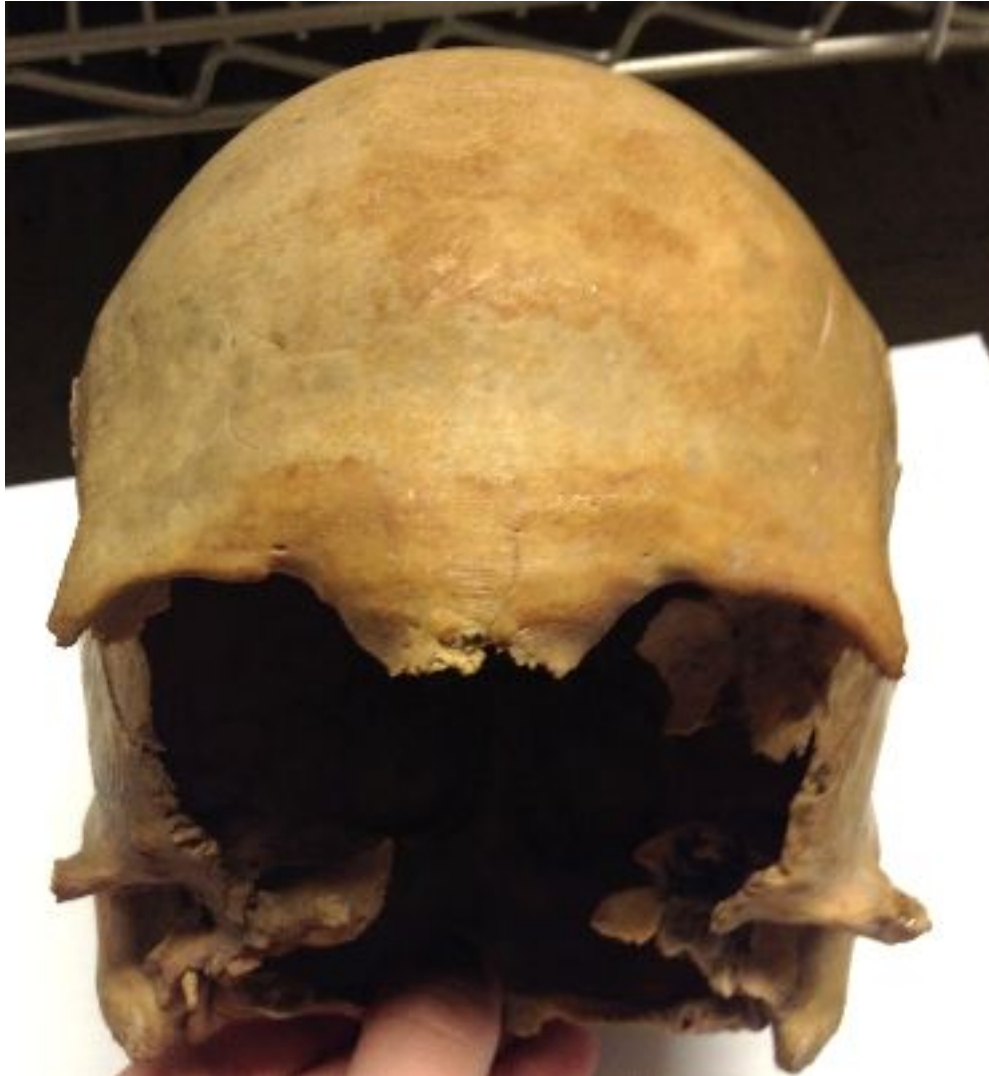

Figure 4: Object number 33-16-110, a female skull with the normal supraorbital ridge expected for a female.

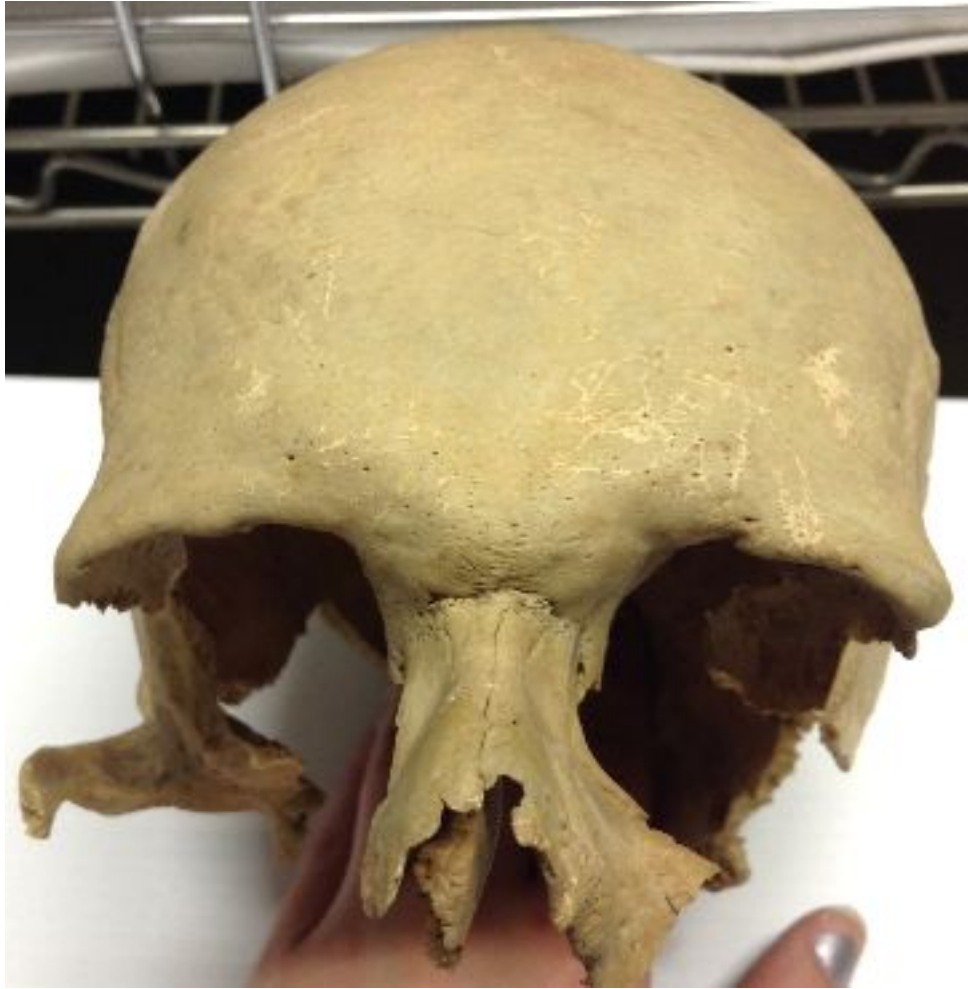

Figure 5: Object number 33-16-093, also a female skull with rather large supraorbital margins.

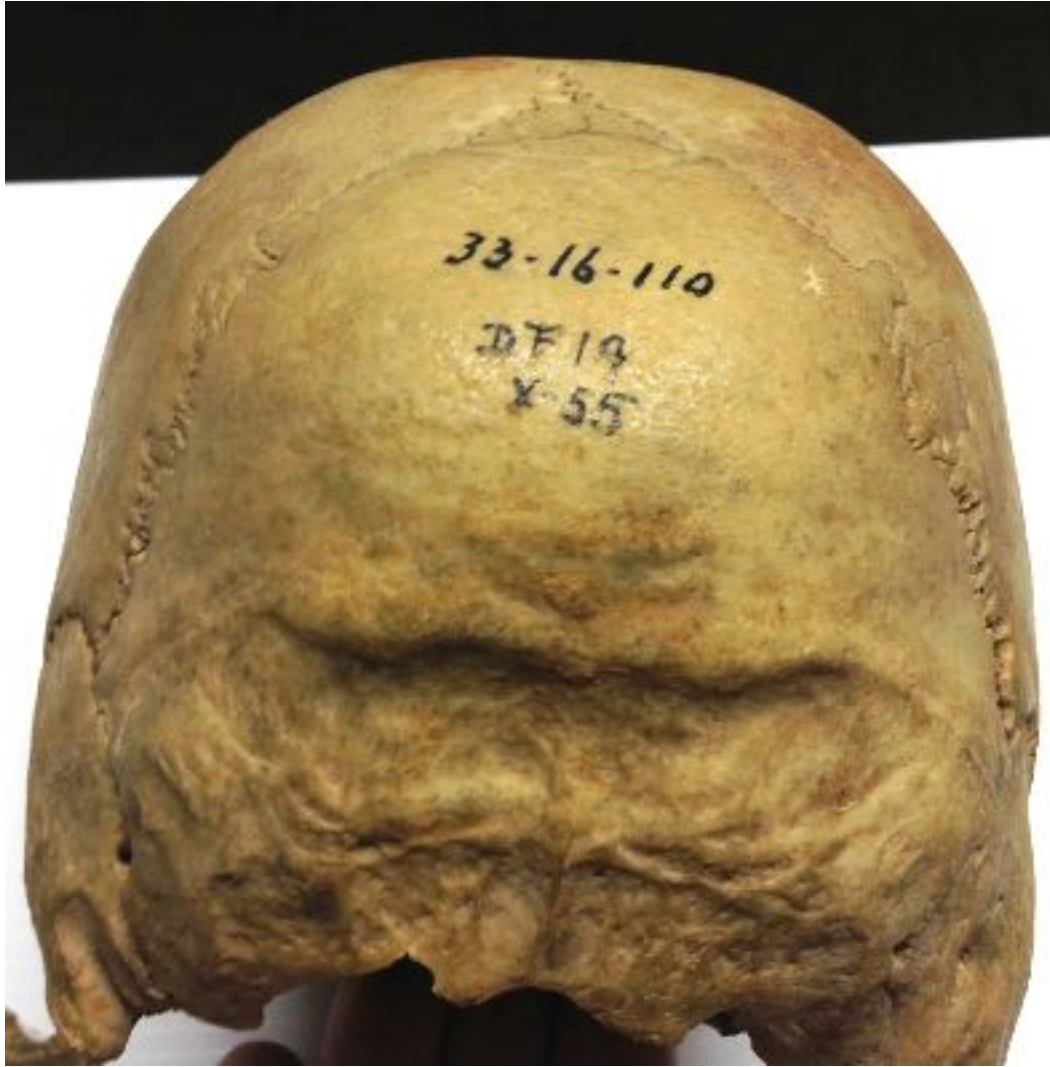


Figure 6: Nuchal area of 33-16-110, a female skull.

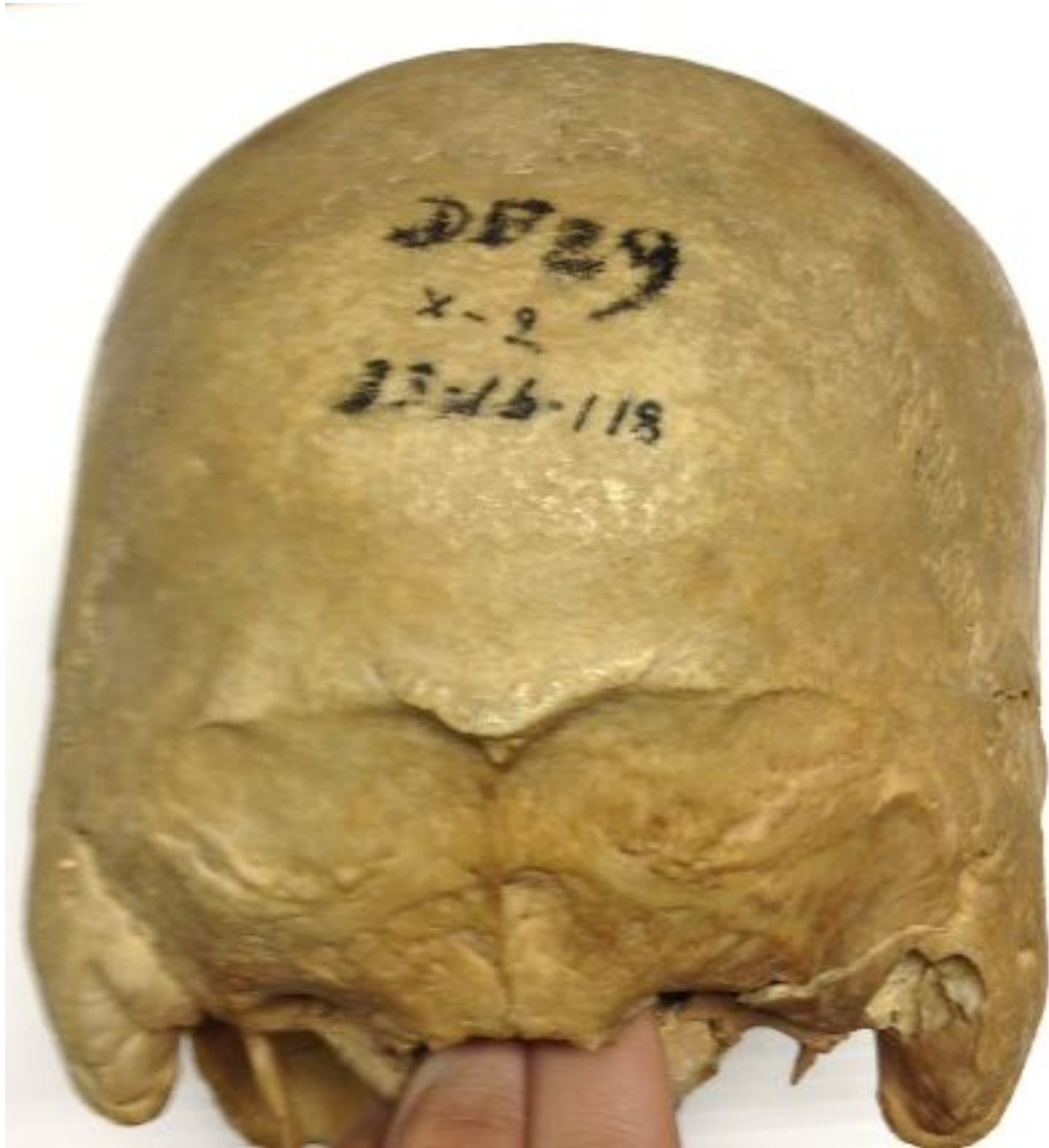

Figure 7: Object number 33-16-118, a male with a less developed nuchal area than in Figure 6.

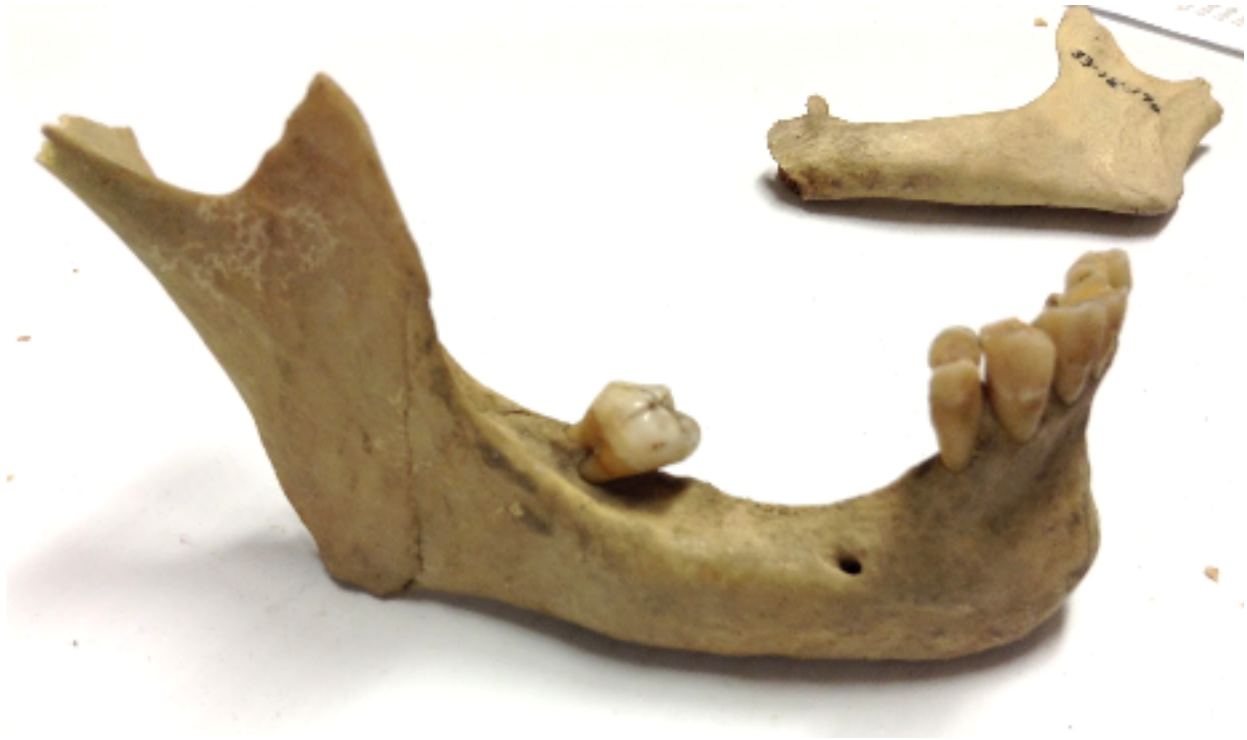

Figure 8: Missing teeth of object 33-16-196 lead me to believe it could belong to an older female.

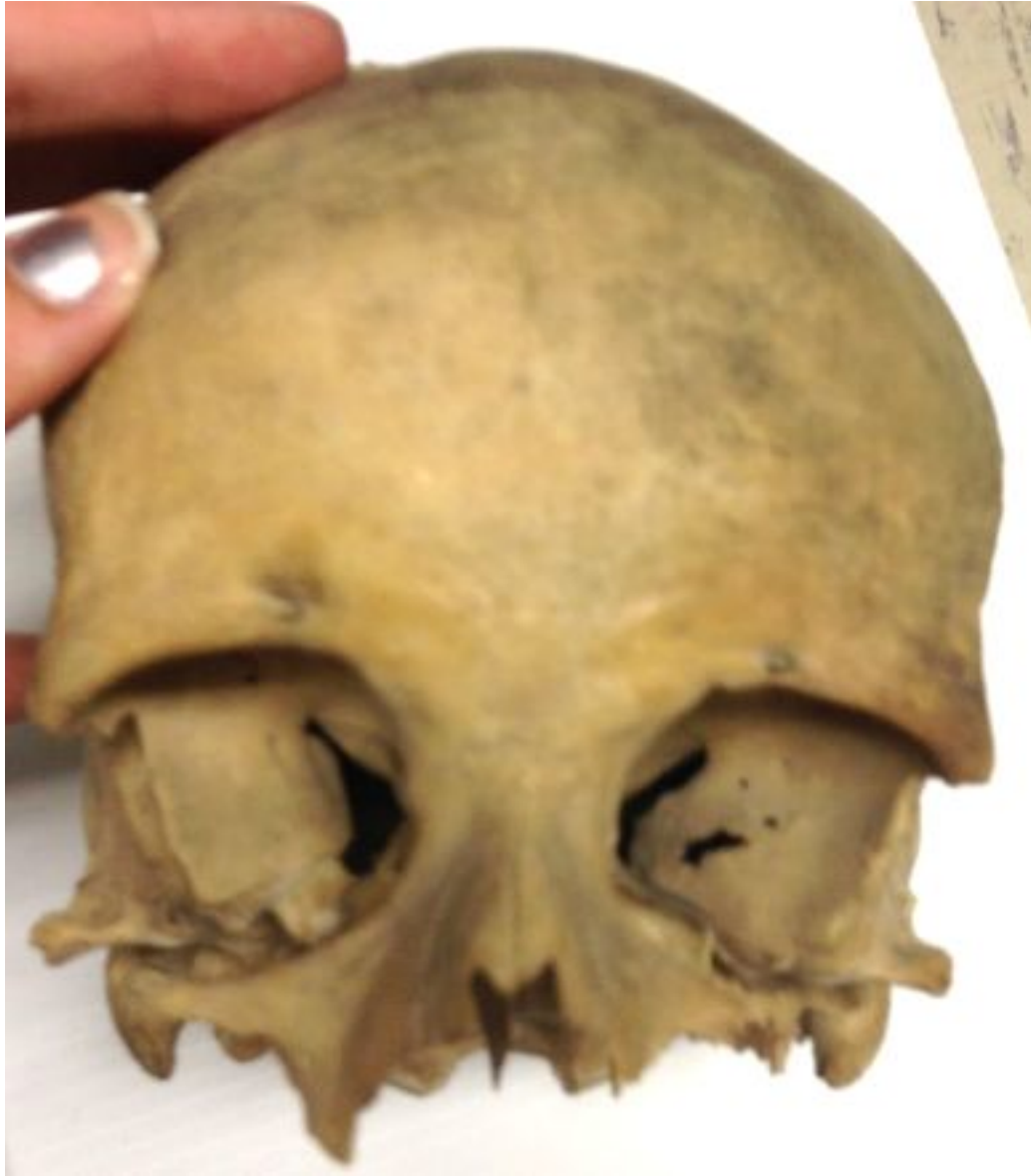

Figure 9: Object number 33-16-050, showing the rounded eye orbits of the typical female skull.

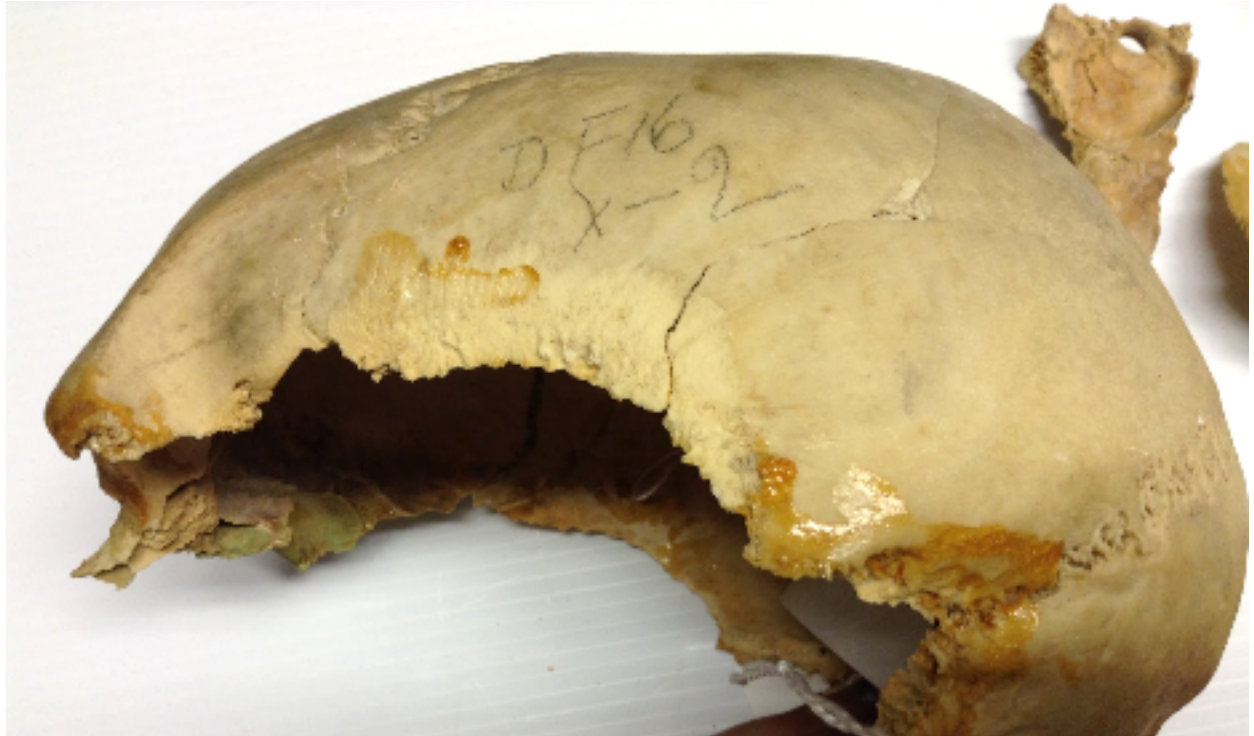

Figure 10: Object number 33-23-124, an excellent example of the sloping forehead of a male

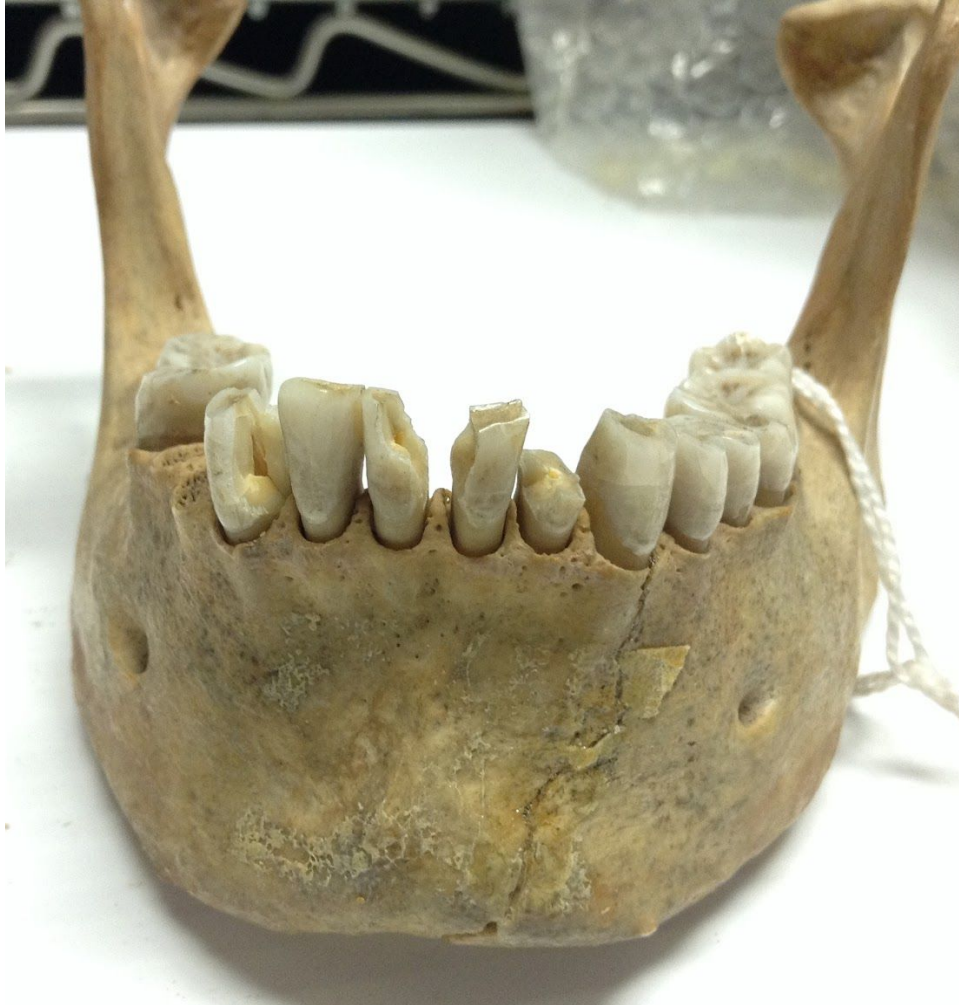

Figure 11: Wide mandibular body of object number 33-16-093, a female.

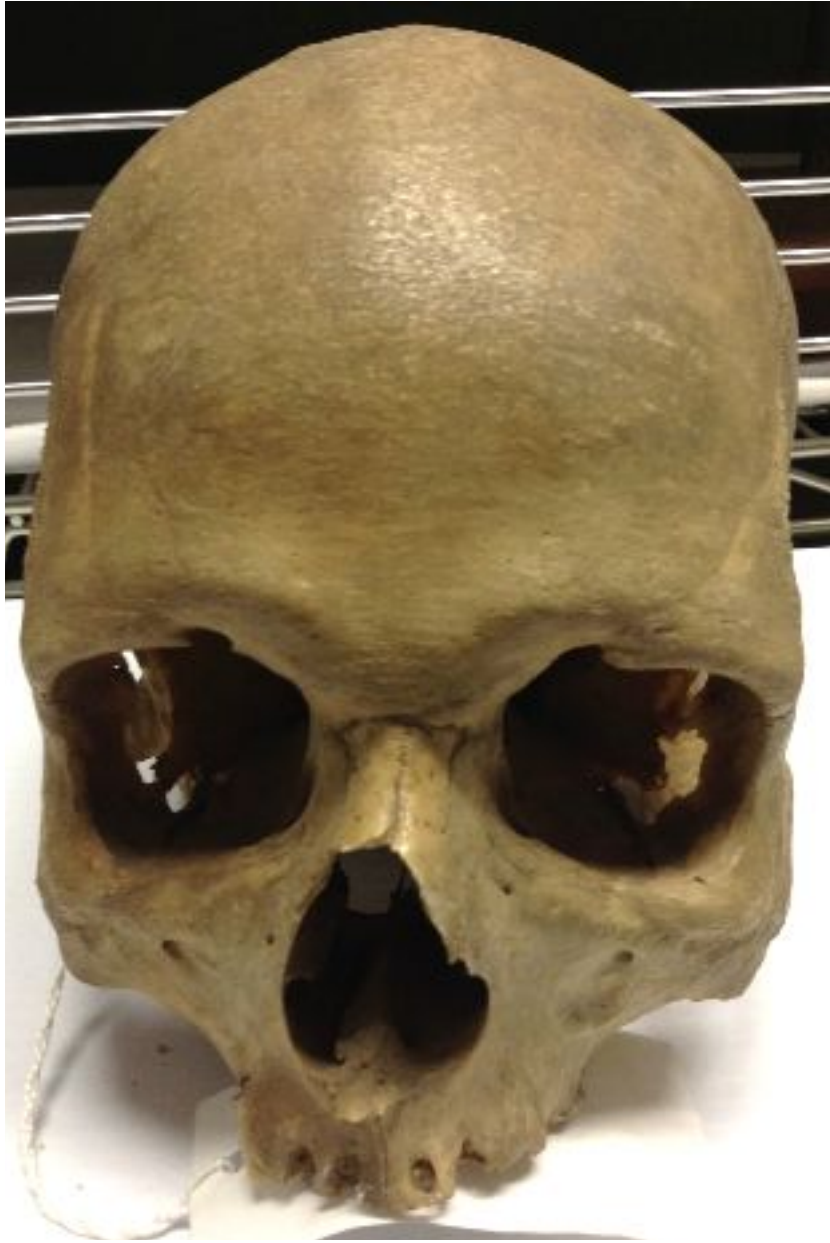

Figure 12: Object number 33-16-143, appears very obviously male, but is actually female, facial view. Notice the prominent supraorbital margin, very square eye orbits, and clearly blunt supraorbital margins.

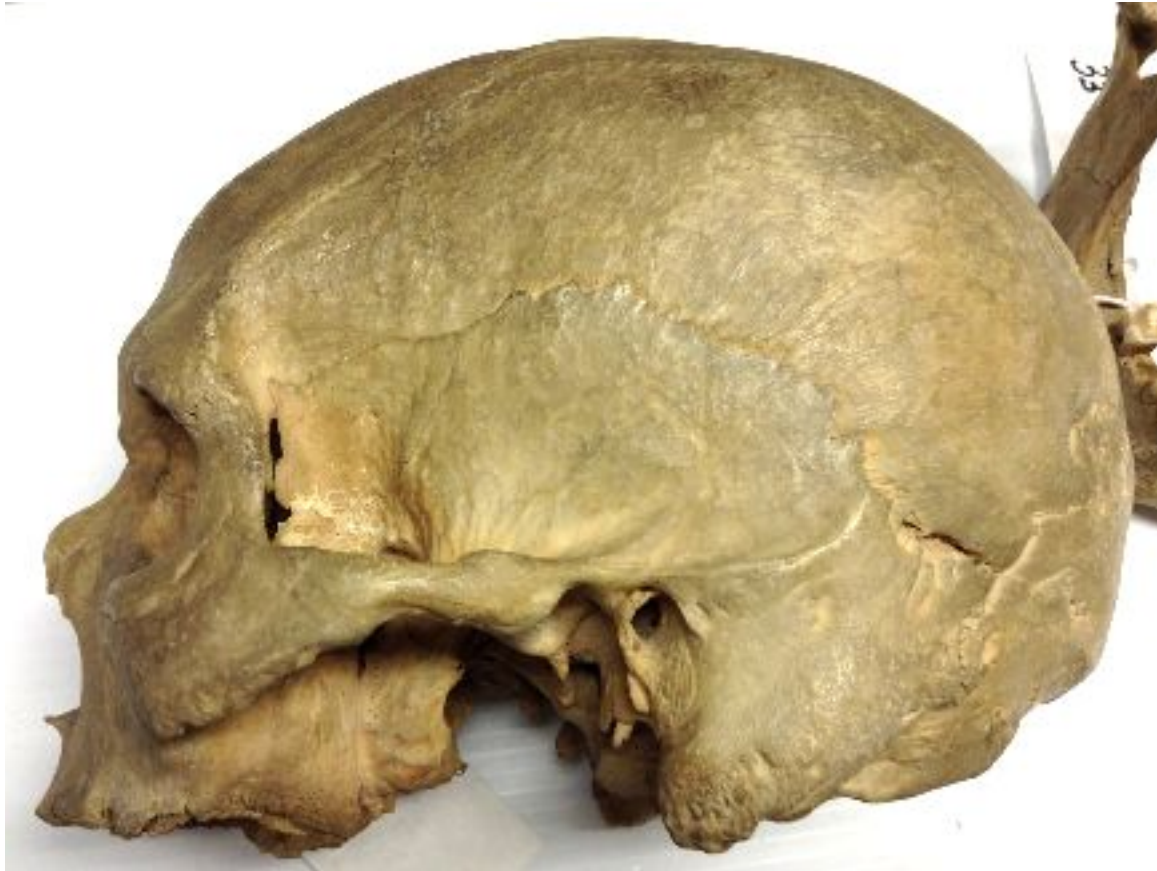

Figure 13: Object number 33-16-143, appears very obviously male, but is actually female, left side view. Observe the protruding mastoid processes, the very slanted forehead, and overall robusticity.

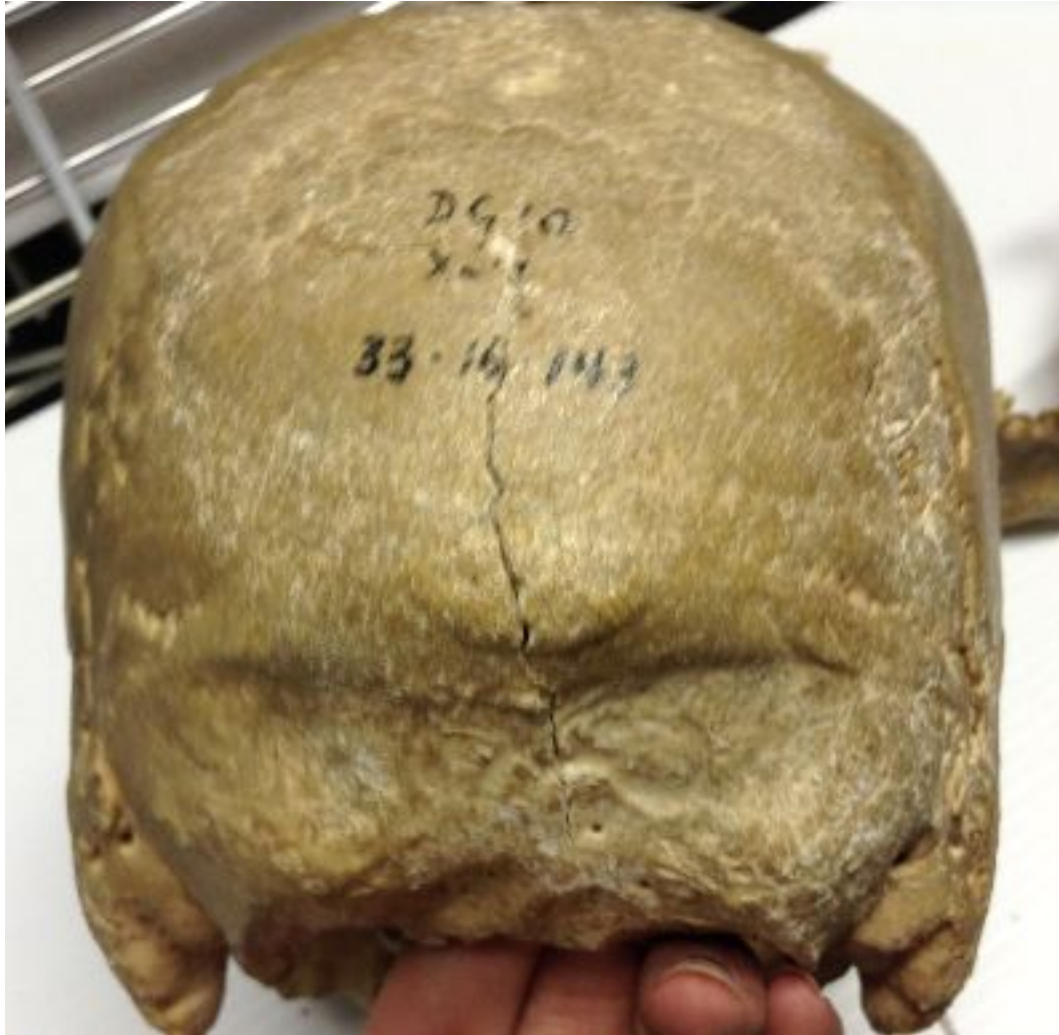

Figure 14: Object number 33-16-143, appears very obviously male, but is actually female. Notice the insanely large nuchal crest and again the prominence of the mastoid processes of this occipital view.

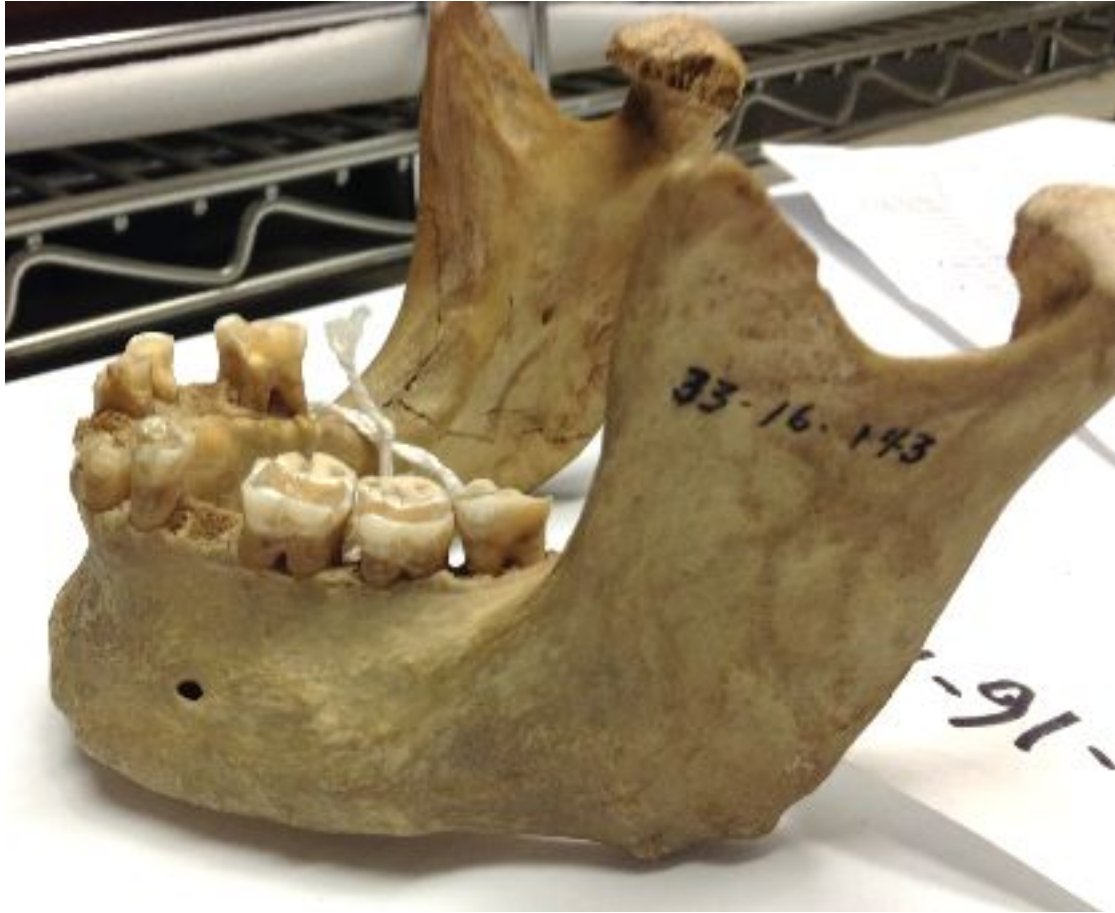

Figure 15: Object number 33-16-143, appears very obviously male, but is actually female. This view of the mandible shows the protubing mental eminence and its overall robusticity.