



University of Pennsylvania
ScholarlyCommons

Departmental Papers (BE)

Department of Bioengineering

5-2007

Cascaded Segmentation of Brain Tumors Using Multi-Modality MR Profiles

Yangming Ou

University of Pennsylvania, ouya@seas.upenn.edu

Hongmin Cai

University of Pennsylvania

Seung-Koo Lee

University of Pennsylvania

Elias R. Melhem

University of Pennsylvania

Christos Davatzikos

University of Pennsylvania

See next page for additional authors

Follow this and additional works at: http://repository.upenn.edu/be_papers

 Part of the [Bioimaging and Biomedical Optics Commons](#)

Recommended Citation

Ou, Y., Cai, H., Lee, S., Melhem, E. R., Davatzikos, C., & Verma, R. (2007). Cascaded Segmentation of Brain Tumors Using Multi-Modality MR Profiles. Retrieved from http://repository.upenn.edu/be_papers/137

Yangming Ou, Hongmin Cai, Seung-koo Lee, Elias R. Melhem, Christos Davatzikos, Ragini Verma. "Cascaded Segmentation of Brain Tumors Using Multi-Modality MR Profiles". International Society for Magnetic Resonance in Medicine (ISMRM), 2007. Berlin, Germany.

This paper is posted at ScholarlyCommons. http://repository.upenn.edu/be_papers/137

For more information, please contact libraryrepository@pobox.upenn.edu.

Cascaded Segmentation of Brain Tumors Using Multi-Modality MR Profiles

Abstract

The accurate identification of the brain tumor boundary and its components is crucial for their effective treatment, but is rendered challenging due to the large variations in tumor size, shape and location, and the inherent inhomogeneity, presence of edema, and infiltration into surrounding tissue. Most of the existing tumor segmentation methods use supervised or unsupervised tissue classification based on the conventional T1 and/or T2 enhanced images and show promising results in differentiating tumor and normal tissues [1-3]. However, perhaps due to the lack of enough MR modalities that could provide a more distinctive appearance signature of each tissue type, these methods have difficulty in differentiating tumor components (enhancing or non-enhancing) and edema. These issues are alleviated by the framework proposed in this paper, that incorporates multi-modal MR images, including the conventional structural MR images and the diffusion tensor imaging (DTI) related maps to create tumor tissue profiles that provide better differentiation between tumor components, edema, and normal tissue types. Tissue profiles are created using pattern classification techniques that learn the multimodal appearance signature of each tissue type by training on expert identified training samples from several patients. The novel use of DTI in the multi-modality framework, helps incorporate the information that tumors grow along white matter tracts [4]. In addition to distinguishing between enhancing and non-enhancing tumors, our framework is also able to identify edema as a separate class, contributing to the solution of tumor boundary detection problem. Tumor segmentation and probabilistic tissue maps generated as a result of applying the classifiers on a new patient reflect the subtle characterizations of tumors and surrounding tissues, and thus could be used to aid tumor diagnosis, tumor boundary identification and tumor surgery planning.

Keywords

Multi-parametric MRI, brain tumor, tumor segmentation, classification

Disciplines

Bioimaging and Biomedical Optics

Comments

Yangming Ou, Hongmin Cai, Seung-koo Lee, Elias R. Melhem, Christos Davatzikos, Ragini Verma. "Cascaded Segmentation of Brain Tumors Using Multi-Modality MR Profiles". International Society for Magnetic Resonance in Medicine (ISMRM), 2007. Berlin, Germany.

Author(s)

Yangming Ou, Hongmin Cai, Seung-Koo Lee, Elias R. Melhem, Christos Davatzikos, and Ragini Verma

Cascaded segmentation of brain tumors using multi-modality MR profiles

Y. Ou¹, H. Cai², S-K. Lee², E. R. Melhem², C. Davatzikos², and R. Verma³

¹Upenn, philadelphia, PA, United States, ²UPenn, PA, ³UPenn, PA, United States

INTRODUCTION. The accurate identification of the brain tumor boundary and its components is crucial for their effective treatment, but is rendered challenging due to the large variations in tumor size, shape and location, and the inherent inhomogeneity, presence of edema, and infiltration into surrounding tissue. Most of the existing tumor segmentation methods use supervised or unsupervised tissue classification based on the conventional T1 and/or T2 enhanced images and show promising results in differentiating tumor and normal tissues [1-3]. However, perhaps due to the lack of enough MR modalities that could provide a more distinctive appearance signature of each tissue type, these methods have difficulty in differentiating tumor components (enhancing or non-enhancing) and edema. These issues are alleviated by the framework proposed in this paper, that incorporates multi-modal MR images, including the conventional structural MR images and the diffusion tensor imaging (DTI) related maps to create tumor tissue profiles that provide better differentiation between tumor components, edema, and normal tissue types. Tissue profiles are created using pattern classification techniques that learn the multimodal appearance signature of each tissue type by training on expert identified training samples from several patients. The novel use of DTI in the multi-modality framework, helps incorporate the information that tumors grow along white matter tracts [4]. In addition to distinguishing between enhancing and non-enhancing tumors, our framework is also able to identify edema as a separate class, contributing to the solution of tumor boundary detection problem. Tumor segmentation and probabilistic tissue maps generated as a result of applying the classifiers on a new patient reflect the subtle characterizations of tumors and surrounding tissues, and thus could be used to aid tumor diagnosis, tumor boundary identification and tumor surgery planning.

METHODS. For each patient, the tissue profile is composed of seven MR modalities, including five structural images, namely, B0, Diffusion Weighted Images (DWI), Fluid-Attenuated Inversion Recovery (FLAIR), T1-weighted, and gadolinium-enhanced T1-weighted (GAD), and two scalar maps computed from the DTI, namely, Fractional Anisotropy (FA) and Apparent Diffusion Coefficient (ADC). These images are skull-stripped, smoothed and registered to the space of the T1 image. In our tissue classification scheme, abnormal tissue samples (enhancing tumor, non-enhancing tumor and edema) were labeled by a neuro-radiologist (see Fig 2) in a very conservative manner, i.e. only those voxels with high confidence are selected. On the other hand, normal samples are selected via the segmentation results (gray matter, white matter and CSF) of the remaining normal brain. For each voxel, intensity values from each of the modalities are combined into a feature vector that serves as this voxel's appearance signature. Following that, a two-phase cascade classifier is designed. In the first phase, training samples from the patients used for training are categorized into two groups: normal (including GM, WM, CSF) and abnormal (including enhancing tumor, non-enhancing tumor, edema), and a Gaussian-kernel SVM is employed to classify the whole brain of a new incoming patient into normal or abnormal regions, with spatial smoothness and morphological constraints. In the second phase, the identified abnormal regions are further classified into one of enhancing tumor, non-enhancing tumor or edema tissue types, by using multivariate discriminant (Bayesian) classifiers trained only on the tumor regions of the training datasets. This two-phase classifier helps eliminate false positives. The classifiers create probability maps that provide additional information about the tissue composition at each voxel, which is extremely useful in tumor surgery planning. Classification accuracy is determined by studying the performance of this classifier of the tumor samples identified by the expert in the test dataset.

RESULTS. In this study, there are 22 brain tumor patients of varying tumor grades. After preprocessing, 7 modalities, five structural images and two DTI scalar map images, are integrated into a uniform multimodality tissue profile, as shown in Fig. 1 for a typical patient. Typical slices from the GAD, FLAIR and FA images are shown in the three columns of Fig. 2 (left to right), overlaid with examples of the expert defined tissue samples (in red color in Fig. 2) for edema, enhancing and non-enhancing tumor. It may be noted that only a very small portion of the tumor has been sampled by the expert. Each of the rows represent samples from different patients. These samples are combined to form a two-class SVM classifier for abnormal and healthy tissue. Fig. 3(a) shows the final across-patient segmentation results. In Fig. 3(a), red, blue and yellow regions correspond to edema, enhancing tumor and non-enhancing tumor, respectively. Fig. 3(b) depicts the probability map that is generated in the first phase of the cascade classification scheme. Fig. 3(c) shows the classified tumor region as light blue, which is obtained from thresholding Fig. 3(b) with some morphological constraints. The advantage of this first phase is to eliminate false positives in the normal region. Using training samples in all tumor images we define multivariate discriminant for the enhancing, non-enhancing tumor, edema and normal tissue. These classifiers are adaptively updated using voxels in the training patients that have been identified to be of a particular tumor tissue type. These adaptive discriminants are then applied to the region identified as abnormal in phase 1. Fig 3(d-g) show the probability map of edema, enhancing tumor, non-enhancing tumor, and normal tissue. The performance of the classifier on expert defined samples in this brain shows that our cascade classification achieves the detection accuracy of 46.64% in edema, 99.2% in enhancing tumor, 59.56% in non-enhancing tumor and 95.06% in normal tissue. These results are superior to the classification results of these regions, when information was not combined across patients.

DISCUSSION. We have been able to achieve good classification of the tumor components by combining MRI information across several patients. into a uniform multimodality profile that provides a distinctive appearance signature for each tissue type, and paves the way to the differentiation of tumor components, edema and their surrounding normal tissues. The probability maps provide information of tissue change and have a predictive value that could potentially aid tumor diagnosis and tumor surgery planning. The results of across-patient classification shown in Fig. 2, demonstrates the generalization ability of our classification scheme, which is extremely useful in tumor diagnosis of new incoming patients. This framework is general and applicable to any multimodality dataset, specifically to any patient for whom acquisition from these 7 modalities is available.

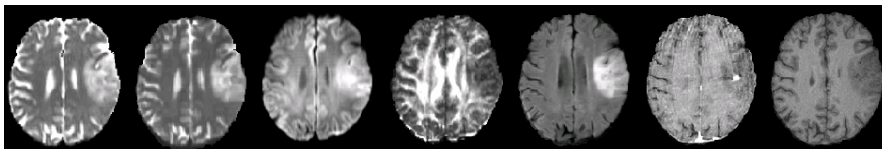


Fig. 1. Representative slices from each of the MR modalities

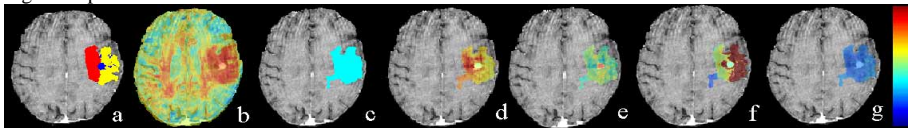


Fig. 3. Across-patient classification results. (a) Final segmentation results. (b) Probability map of normal versus tumor classification; (c) Tumor area as light blue; (d-g) Probability map for edema, enhancing tumor, non-enhancing tumor and normal tissues, respectively.

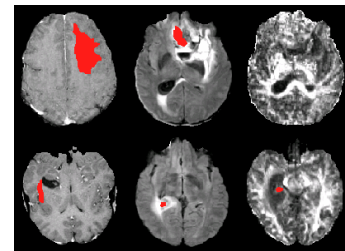


Fig. 2. Abnormal tissue samples (non-enhancing tumor, enhancing tumor and edema) outlined by expert, with different rows pertaining to different patients.

References.

- [1] M. Clark, et al. *IEEE Transactions on Medical Imaging*, vol. 17, pp. 187-201, 1998.
- [2] Kaus MR, et al. *Radiology*, vol. 218, pp. 586-591, 2001.
- [3] Prastawa M, et al. *Medical Image Analysis*, vol. 8, pp. 275-283, 2004.
- [4] Mori S, et al. *Annals of Neurology*, vol. 51, pp. 377-380, 2002.
- [5] Duda RO, Hart PE, and Stork DG, *Pattern Classification*: John Wiley and Sons, Inc., 2001.