



University of Pennsylvania
ScholarlyCommons

Departmental Papers (Dental)

Penn Dental Medicine

8-22-2013

Household Laundry Detergent as a Possible Cause of Oral Lichenoid Lesions


Eric T. Stoopler

University of Pennsylvania, ets@dental.upenn.edu

Christine Nadeau

University of Pennsylvania

Follow this and additional works at: https://repository.upenn.edu/dental_papers

 Part of the [Allergy and Immunology Commons](#), [Oral Biology and Oral Pathology Commons](#), and the [Pathological Conditions, Signs and Symptoms Commons](#)

Recommended Citation

Stoopler, E. T., & Nadeau, C. (2013). Household Laundry Detergent as a Possible Cause of Oral Lichenoid Lesions. *Quintessence International*, 44 (9), 699-701. <http://dx.doi.org/10.3290/j.qi.a30180>

This paper is posted at ScholarlyCommons. https://repository.upenn.edu/dental_papers/42
For more information, please contact repository@pobox.upenn.edu.

Household Laundry Detergent as a Possible Cause of Oral Lichenoid Lesions

Abstract

Oral lichenoid lesions (OLLs) are a diverse group of disorders that may be attributed to an autoimmune etiology, underlying systemic disease, or in association with an identifiable causative agent, such as a medication, food product, or dental material. OLLs commonly present with striae, erythema, and/or ulceration on affected oral mucosa and can be symptomatic. The aim of this report is to describe a case of OLLs that were believed to be attributed to use of household laundry detergent to clean an oral occlusal appliance.

Keywords

laundry detergent, oral lichenoid lesion

Disciplines

Allergy and Immunology | Dentistry | Oral Biology and Oral Pathology | Pathological Conditions, Signs and Symptoms



Household laundry detergent as a possible cause of oral lichenoid lesions

Eric T. Stoopler, DMD, FDS RCSEd¹/Christine Nadeau, DMD²

Oral lichenoid lesions (OLLs) are a diverse group of disorders that may be attributed to an autoimmune etiology, underlying systemic disease, or in association with an identifiable causative agent, such as a medication, food product, or dental material. OLLs commonly present with striae, erythema, and/or ulceration on affected oral mucosa and can be symptomatic. The aim of this report is to describe a case of OLLs that were believed to be attributed to use of household laundry detergent to clean an oral occlusal appliance. (*Quintessence Int* 2013;44:699–701; doi: 10.3290/j.qi.a30180)

Key words: laundry detergent, oral lichenoid lesion

Oral lichenoid lesions (OLLs) can represent a variety of clinical conditions including: oral lichen planus (OLP), an immune-mediated disorder; mucosal reactions that develop in direct relationship with a dental restorative material or food product; lesions that may be associated with other systemic diseases, such as hepatitis C; and drug reactions that arise in temporal relationship with ingestion of certain medications.¹ Clinically, OLLs present as areas of radiating striae often accompanied by ulceration and erythema, which are often symptomatic.¹ Histologically, OLLs demonstrate degeneration of the basal cell layer with a lymphocytic infiltrate in the submucosal layers.² OLLs secondary to an exogenous source will resolve in the majority of cases when the offending agent is eliminated.² The aim of this report is to describe a case of OLLs that were believed to be attributed to use of household laundry detergent to clean an oral occlusal appliance.

CASE REPORT

A 71-year-old woman presented for evaluation of asymptomatic white lesions of the palate of 2 years duration that were discovered as an incidental finding on routine dental examination. A previous biopsy of the lesions demonstrated histopathology consistent with lichenoid mucositis. She denied use of mint, cinnamon, spices, new medications, or new oral hygiene products with the onset of the lesions. She reported a history of bruxism and used an acrylic maxillary occlusal appliance (OA) nightly for 3 years without evidence of oral mucosal lesions as per routine dental examination every 6 months. The patient did not report use of any cleaning agents for this OA. Subsequently, the patient had an identical OA fabricated and cleaned it with perfume- and dye-free household laundry detergent daily of her own accord with subsequent development of the palatal lesions. The patient denied any other mucosal or cutaneous lesions. Her past medical history was significant for hypercholesterolemia, angina, previous myocardial infarction, and previous uterine malignancy. Medications included aspirin, simvastatin, loratadine/pseudoephedrine, and multivitamins. She reported true drug allergies to penicillin, meperidine, and codeine. Her family and social histories were unremarkable and her review of systems was significant for intermittent bilateral knee pain.

¹Associate Professor of Oral Medicine; Director, Oral Medicine Residency Program, Department of Oral Medicine, University of Pennsylvania School of Dental Medicine, Philadelphia, Pennsylvania, USA.

²Resident, Department of Oral Medicine, University of Pennsylvania School of Dental Medicine, Philadelphia, Pennsylvania, USA.

Correspondence: Dr Eric T. Stoopler, University of Pennsylvania School of Dental Medicine, 240 South 40th Street, Philadelphia, PA 19104, USA. Email: ets@dental.upenn.edu

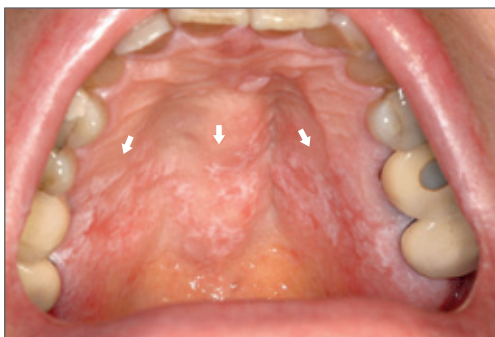

Fig 1 Diffuse area of striae and erythema affecting the central and vertical portions of the palate (arrows).

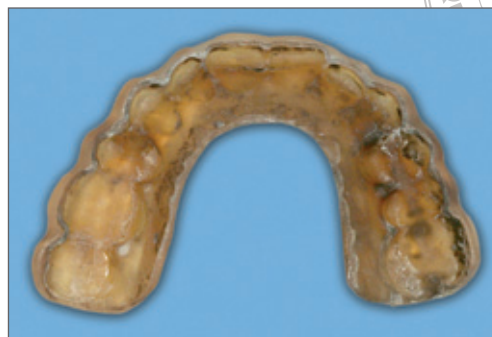

Fig 2 Heavily stained acrylic maxillary occlusal appliance.

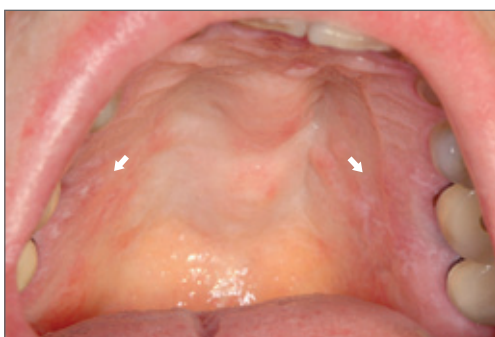

Fig 3 Significant resolution of central palatal lesions 1 month after cessation of OA use. Striae with mild erythema can be observed on the vertical portions of the palate only (arrows).

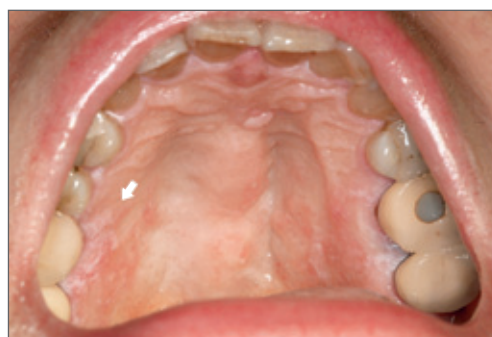

Fig 4 Continued resolution of palatal lesions on 6 week reevaluation. The only remaining area of striae and mild erythema is noted on the vertical portion of the right palate (arrow).

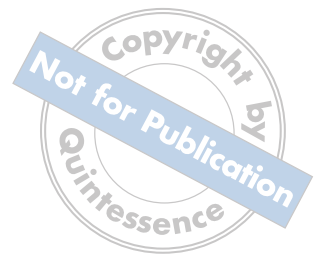Physical examination revealed a well-nourished woman in no apparent distress. Extraoral examination did not reveal lymphadenopathy, thyromegaly, salivary gland enlargement, or cutaneous lesions. Intraoral examination revealed a diffuse area of striae with erythema primarily on the palate (Fig 1).

Examination of the OA revealed a heavily stained prosthesis retained by the maxillary dentition (Fig 2). Differential diagnosis consisted of OLLs believed to be caused by household laundry detergent and OLP, given the clinical and histopathologic features of the lesions. Treatment recommendations included cessation of OA use, completing oral hygiene with baking soda and water only, and avoiding mint, cinnamon, and spices. She returned 1 month later and upon examination, the palatal lesions had significantly resolved and the patient remained asymptomatic (Fig 3).

Fabrication of a new OA was recommended due to the likelihood that her current OA was saturated with household laundry detergent and the lichenoid lesions may re-occur if she continues to wear the device. The patient was reevaluated 6 weeks later and demonstrated continuing resolution of the palatal lesions (Fig 4).

DISCUSSION

Cutaneous reactions secondary to household laundry detergent have rarely been reported. A multicenter study conducted by Belsito et al³ in 2002 concluded that allergic contact dermatitis caused by laundry detergents may occur at a rate of < 0.7% in dermatitic patients. In a study conducted by Magnano et al,⁴ several potential irritants were identified in 63 laundry detergent products available in Italy, including preser-



vatives methylchloroisothiazolinone (MCI), methylisothiazolinone (MI), 1,2-benzisothiazolin-3-one, and fragrances such as butylphenyl methylpropional, hexyl cinnamal, and propylene glycol. In a prospective study conducted by Austoria et al,⁵ skin erythema and dryness were observed in subjects who were exposed to various laundry detergents commonly used in India. Although acrylic resin and its components have been associated with lichenoid mucositis,² in the present case, the authors believe that the patient's OLLs were attributed to the household laundry detergent since no oral mucosal lesions were identified on routine dental examination with an identical OA worn previously that was not cleaned with this substance. Dental professionals should provide specific recommendations to patients regarding hygiene products for removable prostheses or devices (ie, dentures or OAs) to potentially avoid adverse oral reactions such as those described in this report.

REFERENCES

1. Al-Hashimi I, Schifter M, Lockhart PB, et al. Oral lichen planus and oral lichenoid lesions: diagnostic and therapeutic considerations. *Oral Surg Oral Med Oral Pathol Oral Radiol Endod* 2007;103(Suppl S25):e1–12.
2. DeRossi SS, Ciarrocca KN. Lichen planus, lichenoid drug reactions and lichenoid mucositis. *Dent Clin North Am* 2005;49:77–89.
3. Belsito DV, Fransway DF, Fowler JF Jr, et al. Allergic contact dermatitis to laundry detergents: a multi-center study to assess prevalence. *J Am Acad Dermatol* 2002;46:200–206.
4. Magnano M, Silvani S, Vincenzi C, Nino M, Tosti A. Contact allergens and irritants in household washing and cleaning products. *Contact Dermatitis* 2009;61:337–341.
5. Austoria AJ, Lakshmi C, Srinivas CR, Anand CV, Mathew AC. Irritancy potential of 17 detergents used commonly by the Indian household. *Indian J Dermatol Venereol Leprol* 2010;76:249–253.

Copyright of Quintessence International is the property of Quintessence Publishing Company Inc. and its content may not be copied or emailed to multiple sites or posted to a listserv without the copyright holder's express written permission. However, users may print, download, or email articles for individual use.