



10-2013

## Pemphigus

Frank A. Santoro


Eric T. Stoopler

*University of Pennsylvania*, ets@dental.upenn.edu

Victoria P. Werth

*University of Pennsylvania*, werth@mail.med.upenn.edu

Follow this and additional works at: [https://repository.upenn.edu/dental\\_papers](https://repository.upenn.edu/dental_papers)

 Part of the [Allergy and Immunology Commons](#), [Dentistry Commons](#), [Diagnosis Commons](#), [Skin and Connective Tissue Diseases Commons](#), and the [Stomatognathic Diseases Commons](#)

---

### Recommended Citation

Santoro, F. A., Stoopler, E. T., & Werth, V. P. (2013). Pemphigus. *Dental Clinics of North America*, 57 (4), 597-610. <http://dx.doi.org/10.1016/j.cden.2013.06.002>

This paper is posted at ScholarlyCommons. [https://repository.upenn.edu/dental\\_papers/33](https://repository.upenn.edu/dental_papers/33)  
For more information, please contact [repository@pobox.upenn.edu](mailto:repository@pobox.upenn.edu).

---

## Pemphigus

### Abstract

Pemphigus vulgaris and paraneoplastic pemphigus are two subtypes of pemphigus that involve the oral mucosa. These autoimmune blistering disorders have antibodies targeted against proteins of keratinocyte adhesion, thereby causing acantholysis. Clinical findings include oral erosions and flaccid cutaneous bullae and erosions. In addition to the clinical exam, diagnostic tests including tissue biopsy, direct and indirect immunofluorescence, and enzyme-linked immunosorbent assays (ELISA) help to establish a diagnosis. Further malignancy workup in patients with suspected paraneoplastic pemphigus is warranted. Retrospective uncontrolled studies suggest that immunosuppressive agents reduce mortality in pemphigus vulgaris and cohort uncontrolled studies of rituximab, a monoclonal antibody against CD20, suggest it is an effective treatment for refractory patients. Ongoing studies will define its role in early disease.

### Keywords

pemphigus, paraneoplastic pemphigus, oral erosions, stomatitis, blistering disorder, acantholysis, rituximab

### Disciplines

Allergy and Immunology | Dentistry | Diagnosis | Skin and Connective Tissue Diseases | Stomatognathic Diseases

Published in final edited form as:

*Dent Clin North Am.* 2013 October ; 57(4): . doi:10.1016/j.cden.2013.06.002.

## Pemphigus

Frank A. Santoro, M.D.<sup>1,2,3</sup>, Eric T. Stoopler, D.M.D.<sup>4</sup>, and Victoria P. Werth, M.D.<sup>2,3</sup>

<sup>1</sup>Henry Ford Hospital, Department of Dermatology, Detroit, MI

<sup>2</sup>Philadelphia VA Medical Center, Philadelphia, PA

<sup>3</sup>University of Pennsylvania, Department of Dermatology, Philadelphia, PA

<sup>4</sup>University of Pennsylvania School of Dental Medicine, Department of Oral Medicine, Philadelphia, PA

### Abstract

Pemphigus vulgaris and paraneoplastic pemphigus are two subtypes of pemphigus that involve the oral mucosa. These autoimmune blistering disorders have antibodies targeted against proteins of keratinocyte adhesion, thereby causing acantholysis. Clinical findings include oral erosions and flaccid cutaneous bullae and erosions. In addition to the clinical exam, diagnostic tests including tissue biopsy, direct and indirect immunofluorescence, and enzyme-linked immunosorbent assays (ELISA) help to establish a diagnosis. Further malignancy workup in patients with suspected paraneoplastic pemphigus is warranted. Retrospective uncontrolled studies suggest that immunosuppressive agents reduce mortality in pemphigus vulgaris and cohort uncontrolled studies of rituximab, a monoclonal antibody against CD20, suggest it is an effective treatment for refractory patients. Ongoing studies will define its role in early disease.

### Keywords

Pemphigus; paraneoplastic pemphigus; oral erosions; stomatitis; blistering disorder; acantholysis; rituximab

## I. Introduction and epidemiology

### Introduction

**Nature of the Problem**—Pemphigus is a group of chronic blistering disorders of the skin and mucosal membranes. Autoantibodies are directed against cell-cell adhesion molecules of

---

Correspondence to: Victoria P. Werth.

Frank A. Santoro, M.D., Henry Ford Hospital, Department of Dermatology, 3031 West Grand Boulevard, Suite 800, Detroit, MI 48202, Phone: 313-916-2171, Fax: 313-916-2156, franksantoro@gmail.com

Eric T. Stoopler, D.M.D., Department of Oral Medicine, University of Pennsylvania School of Dental Medicine, 240 South 40<sup>th</sup> Street, Philadelphia, PA 19104, Tel. 215-898-6627, Fax: 215-573-7853, ets@dental.upenn.edu

Victoria P. Werth, M.D., Department of Dermatology, University of Pennsylvania, Perelman Center for Advanced Medicine Suite 1-330A, 3400 Civic Center Boulevard, Philadelphia, PA 19104, Tel. 215-823-4208, Fax 866-755-0625, werth@mail.med.upenn.edu

**Publisher's Disclaimer:** This is a PDF file of an unedited manuscript that has been accepted for publication. As a service to our customers we are providing this early version of the manuscript. The manuscript will undergo copyediting, typesetting, and review of the resulting proof before it is published in its final citable form. Please note that during the production process errors may be discovered which could affect the content, and all legal disclaimers that apply to the journal pertain.

Disclosures for authors:

Frank A. Santoro: No disclosures

Eric T. Stoopler: No disclosures

Victoria P. Werth: No disclosures

keratinocytes, thereby causing loss of adhesion or acantholysis. While there are five major categories of pemphigus (pemphigus vulgaris, pemphigus foliaceus, paraneoplastic pemphigus (PNP), drug-induced pemphigus, and IgA pemphigus), only pemphigus vulgaris and paraneoplastic pemphigus (PNP) typically have oral involvement.

**Definition**—The word pemphigus originates from the Greek word *pemphix*, which translates into blister or bubble. The blisters result from acantholysis. PNP was recognized as a distinct entity in 1990<sup>1</sup> after various reports<sup>2–6</sup> associated pemphigus and malignancy, usually of lymphoid tissue.

**Symptom Criteria**—Symptom criteria for pemphigus vulgaris

- Painful erosions in the mouth; +/- oropharyngeal and/or esophageal involvement. 50% of patients with pemphigus vulgaris have isolated oral lesions.
- Flaccid bullae and erosions on the body can accompany oral disease.

Symptom criteria for PNP<sup>7</sup>

- Painful, progressive stomatitis
- Acantholysis or lichenoid/interface inflammation on histopathology
- Presence of anti-plakin antibodies
- Presence of an underlying lymphoproliferative disorder

**Pathogenesis**—In pemphigus vulgaris, IgG autoantibodies against desmogleins, one of the prominent cell adhesion molecules of the desmosome, cause a loss of cell adhesion<sup>8</sup>. This loss of adhesion results in acantholysis. Desmoglein-1 (Dsg-1) is expressed in all layers of the epidermis with a higher concentration in the more superficial layers whereas desmoglein-3 (Dsg-3) is expressed in the parabasal and basal layers. In the mucosa, Dsg-1 and Dsg-3 are expressed throughout all layers of the epidermis, however, the mucosa has lower concentrations of Dsg-1. Patients with mucocutaneous pemphigus vulgaris have detectable autoantibodies directed against Dsg-1 and Dsg-3 whereas patients with only mucosal disease have antibodies targeted against only Dsg-3<sup>9,10</sup>. The triggering event leading to antibody formation is unknown.

Patients with paraneoplastic pemphigus also have autoantibodies against Dsg-1 and Dsg-3. In addition, PNP has antibodies targeted against proteins in the plakin family (plectin, desmoplakin I, desmoplakin II, bullous pemphigoid antigen I, envoplakin, and periplakin). These plakin proteins are also involved in cell-cell adhesion of keratinocytes.

### Prevalence/Incidence & Worldwide/Regional Incidence

The overall incidence of pemphigus is estimated at 0.076 to 5 100,000 person years<sup>11</sup>. The incidence of pemphigus vulgaris is higher in women (male:female; 1:1.1–2.25) and the Ashkenazi Jewish population. Since there is regional and ethnic clustering of pemphigus, there is likely a genetic component, and recently ST18, a gene regulating apoptosis and inflammation, has been identified in predisposing individuals to pemphigus vulgaris in a population-specific manner<sup>12</sup>.

## II. Clinical Parameter

### Clinical Findings

**Physical Exam**—Pemphigus vulgaris

On exam, patients with pemphigus vulgaris usually have oral erosions, particularly on the labial and buccal mucosa, which often appear as delicate, superficial ulcers<sup>13</sup> (Figure 1). Any mucosal surface, including the oropharynx and esophagus can be involved. Half of these patients will have cutaneous involvement with findings of flaccid blisters and erosions with a predilection for the trunk, groin, axillae, scalp and face. Initially, there can be erythematous macules and patches that evolve into flaccid bullae. Desquamative gingivitis (DG) may be present and is often associated with this disease<sup>14</sup>. Gingival involvement can cause significant pain and hemorrhage. Pemphigus-related DG is similar to DG seen in other mucocutaneous disorders, such as oral lichen planus and mucous membrane pemphigoid<sup>15</sup>. Nikolsky's sign is a common exam finding. The direct Nikolsky sign (Figure 2) refers to direct application of pressure on a blister, causing the extension of the blister. The indirect Nikolsky sign is when the application of friction on clinically normal skin induces a blister. Other clinical findings include nail dystrophy, paronychia, and subungual hematomas<sup>16,17</sup>.

#### Paraneoplastic pemphigus

Paraneoplastic pemphigus (PNP) can have similar exam findings to pemphigus vulgaris. In addition, lichenoid, targetoid and tense blisters can be seen. The oral findings can be similar to pemphigus vulgaris, however, PNP often has painful, progressive stomatitis preferentially involving the tongue<sup>18</sup>. In addition, the presence of blisters and targetoid lesions on the palms and soles can help differentiate PNP from pemphigus vulgaris. A biopsy with direct immunofluorescence (DIF) and a complete physical exam can further help differentiate PNP from pemphigus vulgaris (see section below on diagnostic modalities).

**Rating Scales**—In a Cochrane review of clinical trials studying pemphigus, a total of 116 different outcomes measures were used<sup>19</sup>. Without a standardization of outcome measures, it is difficult to compare the efficacy of therapies. In an effort to standardize outcome measures, Rosenbach et al.<sup>20</sup> evaluated two instruments, the Autoimmune Bullous Skin Disorder Intensity Score (ABSIS) and Pemphigus Disease Area Index (PDAI) for their reliability and convergent validity. The PDAI correlates better with the physician's assessment of disease severity<sup>20</sup>, and is more sensitive to measuring patients with milder disease. Table 1 summarizes the details of the outcome measures and their strengths and weaknesses.

**Diagnostic modalities**—Clinical examination and diagnostic modalities aid in the diagnosis of pemphigus. Direct and indirect immunofluorescence (Figure 3) and enzyme-linked immunosorbent assays (ELISA) are helpful in distinguishing the different subtypes of pemphigus.

#### Light microscopy

A tissue biopsy is an important modality in the diagnosis of the pemphigus. A 4mm punch biopsy preferably taken at the transitional edge of the blister and inflamed skin is submitted for in 10% formalin. The specimen is stained with hematoxylin and eosin (H&E) and visualized under light microscopy. By including the edge of the blister, the site of blister formation can be better visualized. In an absence of blisters, a biopsy including an erosion and adjacent skin might be helpful, however, it often shows only non-specific inflammation.

#### Direct immunofluorescence (DIF)

- Size and type of biopsy: 4 mm
- Technique: A biopsy specimen is exposed to antibodies (IgG, C3, IgM and IgA) with a fluorescent tag (fluorophore). Pemphigus will have autoantibodies attached

to the cells. The fluorescent antibodies will bind to the autoantibodies and fluoresce under microscopy.

- Transport media: Michel's media
- Site of biopsy: Within 2 centimeters of the blister on clinically normal skin.

### **Pathology of pemphigus vulgaris and paraneoplastic pemphigus**

Under light microscopy, pemphigus vulgaris is characterized by an intraepithelial blister with acantholysis. Acantholytic cells are round with eosinophilic cytoplasm and pyknotic nuclei. The basal layer will have a single layer of intact cells, often referred to as "tombstoning" (Figure 4). Acantholysis might track down the hair follicles and this finding serves as a distinguishing feature from other acantholytic diseases. There are often a few inflammatory cells in the blister cavity with notable eosinophils and a moderate perivascular chronic inflammation. Direct immunofluorescence (Figure 5) demonstrates an intercellular deposition of IgG and C3 in a "chicken-wire" lattice pattern.

Paraneoplastic pemphigus has a highly variable presentation under light microscopy with features similar to pemphigus vulgaris, lichen planus, and erythema multiforme. It can show a combination of intraepithelial blister with suprabasal acantholysis, interface dermatitis, dyskeratotic keratinocytes, and lymphocyte exocytosis. Spongiosis, chronic perivascular and lichenoid infiltrates and pigment incontinence can also be seen. DIF shows IgG deposition in all layers of the epidermis and C3 in the lower epidermis and basement membrane. In contrast to pemphigus vulgaris, intercellular staining is often focal and faint.

#### Indirect immunofluorescence (IIF)

- Technique:
  1. The patient's serum is diluted and incubated on a substrate (see below) and human salt-split skin.
  2. A fluorescein-conjugated IgG anti-serum is applied.
  3. If autoantibodies from the patient's serum are present and bound, the fluorescein conjugated IgG anti-serum will fluorescence under microscopy. The test will be reported as a titer.
- Substrates and sites of antibody binding
  - Pemphigus vulgaris
    - Substrate: Rhesus monkey esophagus
    - Site of antibody binding: intraepithelial
  - Paraneoplastic pemphigus
    - Substrate: Rodent bladder
      - ◆ PNP antibodies bind the desmosomes of simple and transitional epithelia in addition to stratified squamous epithelia. In contrast, other pemphigus subtypes only bind stratified squamous epithelia.
    - Site of antibody binding: Intraepithelial and basement membrane zone

- Sensitivity: 75%; specificity: 83%<sup>22</sup>.
- Interpretation
  - This test should be used in conjunction with clinical, histological and DIF findings.
  - IIF will test for the presence and titer of corresponding antibodies.
- Importance of the test:
  - High positive predictive value (~90% in active pemphigus vulgaris patients) and low negative predictive value<sup>23</sup>.
  - In addition to its diagnostic value, IIF titers may correlate with disease activity, but further studies are now ongoing.
  - Directly correlate with clinical disease activity and might be useful to follow disease progression and response to therapy<sup>24</sup>.

#### ELISA (Enzyme-Linked Immunosorbent Assay)

- Interpretation of results for pemphigus vulgaris
  - ELISA is comparable to IIF for sensitivity, but inferior for specificity<sup>25</sup>.
  - If there is a strong clinical suspicion for pemphigus with a negative ELISA, IIF is recommended.
  - The titers of anti-desmoglein antibodies correlate with disease activity and are proportional to the severity of the disease<sup>24</sup>.
  - It should be noted that there is a subset of patients with persistently elevated anti-desmoglein 3 antibodies, despite low disease activity. These antibodies are unlikely pathogenic<sup>26,27</sup>.

## Imaging

There is no specific imaging required for pemphigus vulgaris. If the patient has dysphagia, an esophagogastroduodenoscopy can assess the extent of esophageal involvement. If there is concern for airway obstruction, then an airway evaluation might be indicated.

Paraneoplastic pemphigus can also involve the oropharynx and gastrointestinal tract. There is normally an underlying malignancy, including non-Hodgkin's lymphoma, chronic lymphocytic leukemia and Castleman's disease<sup>28</sup>. Other non-hematologic malignancies include adenocarcinomas and sarcomas<sup>29</sup>. A computed tomography (CT) scan of the chest, abdomen and pelvis to detect such malignancies is recommended. In cases of hematologic malignancy, a patient will need to undergo evaluation with oncologist and a bone marrow biopsy. Lastly, PNP can involve the respiratory mucosa and 30–40% of patients will develop bronchiolitis obliterans. Bronchiolitis obliterans is a non-reversible, inflammatory obstructive pulmonary disease which presents with severe shortness of breath, wheezing and dry cough. Patient with suspected bronchiolitis obliterans will need a high resolution CT scan, pulmonary function tests including a diffusion capacity of carbon monoxide (DLCO) and referral to a pulmonologist.

## Diagnostic Dilemmas

**Differential Diagnosis**—The clinical and histopathologic differential diagnoses for pemphigus vulgaris and paraneoplastic pemphigus are included in Tables 2 and 3, respectively.

**Comorbidities**—Complications from the disease include malnutrition, dehydration and sepsis. However, corticosteroid use has decreased mortality from pemphigus vulgaris and the side effects from immunosuppressive agents are the most common cause of morbidity and mortality.

Dental complications include inadequate maintenance of oral hygiene for patients with active PV lesions due to pain and / or hemorrhage when performing such activities. This may lead to increased dental plaque, which may contribute to development and / or progression of periodontal disease in this patient population<sup>30,31</sup>.

In addition to underlying malignancies discussed under the imaging section, PNP affects respiratory mucous membranes causing bronchiolitis obliterans, a disease which evolves into progressive respiratory failure<sup>29</sup>. These comorbidities confer a high mortality rate. In a cohort of 84 patients with PNP the mortality rate was 90% with major causes of death due to sepsis, respiratory failure or an underlying neoplasm<sup>32</sup>.

### III. Management strategy

#### Management Goals

Goals of therapy include minimizing disease burden and improving quality of life. In most patients, this clinically translates into the absence of blistering or occasional blistering.

#### Pharmacologic Strategies

Pharmacologic treatments for pemphigus vulgaris and paraneoplastic pemphigus are reviewed (Tables 4 and 5). Topical agents may be useful for palliative treatment of symptomatic oral lesions<sup>18</sup>. Topical anesthetic rinses, such as viscous lidocaine, are often effective for temporary relief while high-potency topical corticosteroids can be prescribed in various forms (rinses, pastes, gels) and may be used as monotherapy or in conjunction with systemic treatment<sup>33</sup>. Topical tacrolimus has also demonstrated some benefit in treating recalcitrant lesions<sup>33,34</sup>. Intralesional corticosteroid injections may be used to treat oral PV lesions, but this type of therapy has been associated with scarring and / or mucosal atrophy<sup>33</sup>. Systemic corticosteroids (1mg/kg) are the first-line treatment for pemphigus. Over months, the corticosteroids are tapered to 2.5 mg. Prior to the patient tapering less than 2.5 mg daily, an AM cortisol prior to the daily dose of prednisone is checked to evaluate for adrenal insufficiency. As the corticosteroids are tapered, steroid-sparing therapies including Rituximab are initiated.

Rituximab, a monoclonal antibody to CD20, has become a first line treatment of pemphigus and a safer alternative to steroids in recent years. Since pemphigus vulgaris is mainly an antibody-mediated disease, targeting B lymphocytes with a monoclonal antibody causes less antibody production and therefore, less clinical disease. A meta-analysis of 153 patients with pemphigus demonstrated a complete remission in 65% of patients treated with rituximab<sup>35</sup>. The role of Rituximab use in early disease and its safety profile need to be evaluated in larger prospective studies<sup>35</sup>.

Since patients with pemphigus usually require a prolonged course of corticosteroids (>3 months), the prevention of glucocorticoid-induced osteoporosis must be considered. Fractures occur in 30–50% of patients chronically using glucocorticoids<sup>36</sup>. The fracture risk rapidly accelerates in the first 3–6 months, thereby making early initiation crucial. Oral bisphosphonates, along with 1200 mg calcium and 800 international units of vitamin D, are the mainstays of prevention. Bisphosphonates should be initiated in postmenopausal women, males >50 years old with a high fracture risk, and patients who will need a dose of prednisone >7.5 mg daily for three months. Benefits of osteoporosis prevention outweigh



the risks of side effects of bisphosphonates such as osteonecrosis of the jaw and atypical fractures.

Patients with on chronic glucocorticoid treatment should also be monitored for symptoms of adrenal insufficiency, infections, hypertension, diabetes mellitus, gastrointestinal ulcers, steroid myopathy, and mood instability. Patients with any signs of side effects should be evaluated further and attempts should be undertaken to taper the dose of glucocorticoids and/or add steroid-sparing therapies.

### **Nonpharmacologic strategies**

Recommended treatment of cutaneous erosions includes cleansing with antibacterial soap twice a day, followed by bandaging with non-stick gauzes, such as petrolatum gauzes. Patients should avoid aggressive oral hygiene practices, including flossing, when symptomatic lesions are present, due to increased risk of pain and / or bleeding. Gentle oral hygiene measures may consist of saline rinses and should be discussed with the oral health care provider in the overall context of an individual's oral hygiene program.

In 75% of patients, complete resection of a tumor will lead to improvement in mucocutaneous disease in PNP. However, treatment of an unresectable tumor does not normally improve disease<sup>29</sup>. Bronchiolitis obliterans does not improve with resection<sup>29</sup>.

### **Evaluation, adjustment, recurrence**

If the patient does not improve on 1 mg/kg /day of prednisone, the dose of prednisone can be increased to 1.5 to 2 mg/kg or start IV methylprednisolone. In addition, corticosteroids can be combined with or substituted for with immunosuppressive drugs (Table 4).

Patients receiving one cycle of rituximab will frequently need re-treatment<sup>40</sup>. The ideal timing and dose for treatment is undetermined.

## **IV. Summary/Discussion**

Pemphigus vulgaris and paraneoplastic pemphigus are the two categories of pemphigus that manifest as oral disease. While the clinical exam findings can be similar in both diseases, other diagnostic modalities, such as routine biopsy, direct and indirect immunofluorescence, and ELISA help to differentiate the two diseases. Rituximab has become an excellent option for treatment for pemphigus vulgaris, but studies examining the role of its use early in disease, as well as the optimal dose regimen and maintenance treatment doses, are undetermined. Long-term studies of safety are needed.

## **Acknowledgments**

This material is supported by the National Institutes of Health, including NIH K24-AR 18 02207 (Werth) and by the Department of Veterans Affairs, Veteran Health Administration, Office of Research and Development, Biomedical Laboratory Research and Development. A mentorship award from the Medical Dermatology Society supported Dr. Santoro.

## **References**

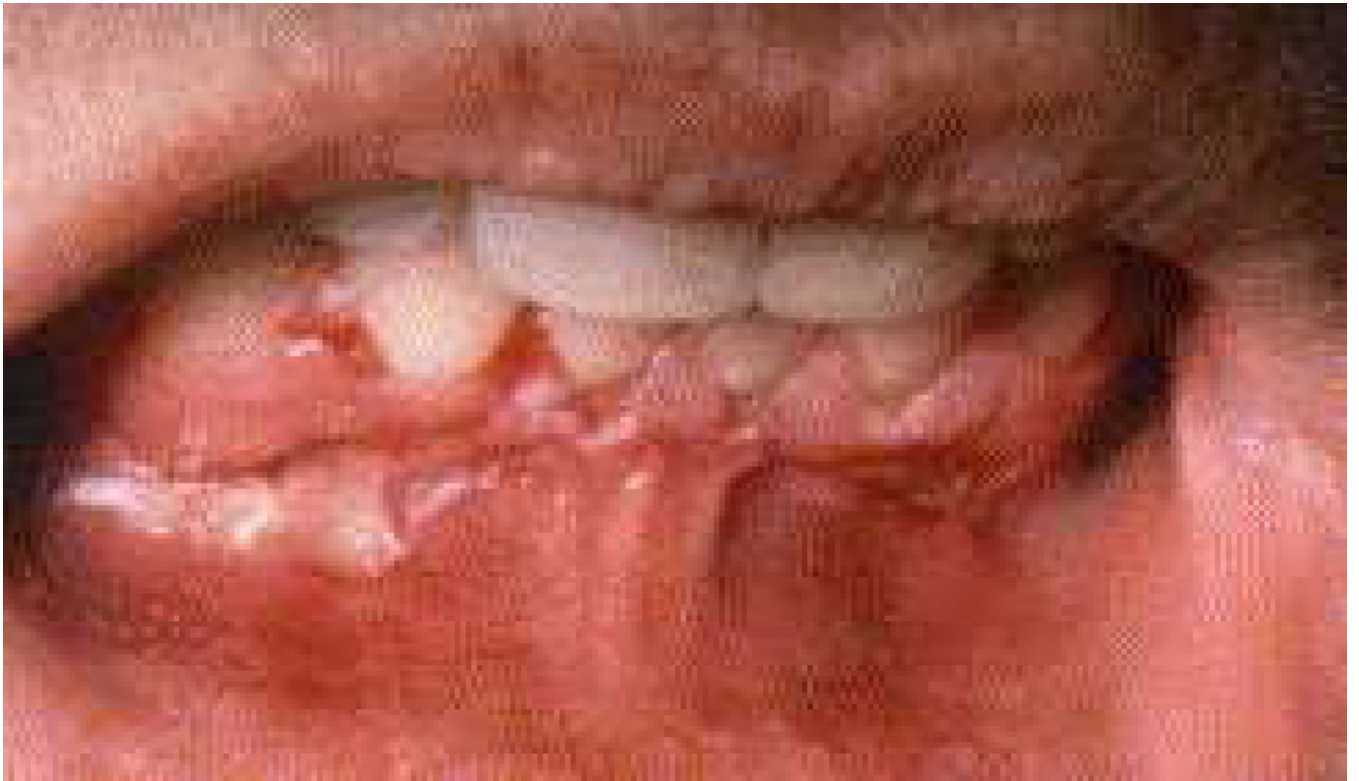1. Anhalt GJ, Kim SC, Stanley JR. et al. Paraneoplastic pemphigus. An autoimmune mucocutaneous disease associated with neoplasia. *N Engl J Med.* 1990; 323:1729–1735. [PubMed: 2247105]
2. Krain LS, Bierman SM. Pemphigus vulgaris and internal malignancy. *Cancer.* 1974; 33:1091–1099. [PubMed: 4362104]
3. Laskaris GC, Papavasiliou SS, Bovopoulou OD, et al. Association of oral pemphigus with chronic lymphocytic leukemia. *Oral Surg Oral Med Oral Pathol.* 1980; 50:244–249. [PubMed: 6931999]

4. Redon J, Sorni G, Gonzalez-Molina A, et al. Pemphigus associated with giant lymph node hyperplasia. *Br Med J (Clin Res Ed)*. 1983; 287:1761–1762. [PubMed: 6416581]
5. Matsuoka LY, Wortsman J, Stanley JR. Epidermal autoantibodies in erythema multiforme. *J Am Acad Dermatol*. 1989; 21:677–680. [PubMed: 2808784]
6. Tagami H, Sagawa K, Imamura S, et al. Severe erosive stomatitis and giant cell lymph node hyperplasia of retroperitoneum (Castleman's tumor). *Dermatologica*. 1978; 157:138–145. [PubMed: 680299]
7. Anhalt GJ. Paraneoplastic pemphigus. *J Invest Dermatol Symp Proc*. 2004; 9:29–33.
8. Karpati S, Amagai M, Prussick R, et al. Pemphigus vulgaris antigen, a desmoglein type of cadherin, is located within keratinocyte desmosomes. *J Cell Biol*. 1993; 122:409–415. [PubMed: 8320263]
9. Amagai M, Tsunoda K, Zillikens D, et al. The clinical phenotype of pemphigus is defined by the anti-desmoglein autoantibody profile. *J Am Acad Dermatol*. 1999; 40:167–170. [PubMed: 10025740]
10. Shirakata Y, Amagai M, Hanakawa Y, et al. Lack of mucosal involvement in pemphigus foliaceus may be due to low expression of desmoglein 1. *J Invest Dermatol*. 1998; 110:76–78. [PubMed: 9424092]
11. Gupta VK, Kelbel TE, Nguyen D. A globally available internet-based patient survey of pemphigus vulgaris: epidemiology and disease characteristics. *Dermatol Clin*. 2011; 29:393–404. [PubMed: 21605804]
12. Sarig O, Bercovici S, Zoller L, et al. Population-specific association between a polymorphic variant in ST18, encoding a pro-apoptotic molecule, and pemphigus vulgaris. *J Invest Dermatol*. 2012; 132:1798–1805. [PubMed: 22437316]
13. Edgin WA, Pratt TC, Grimwood RE. Pemphigus vulgaris and paraneoplastic pemphigus. *Oral Maxillofacial Surg Clin N Am*. 2008; 20:577–584.
14. Scully C, Mignogna M. Oral mucosal disease: Pemphigus. *Br J Oral Maxillofacial Surg*. 2008; 46:272–277.
15. Toscano NJ, Holtzclaw DJ, Shumaker ND, et al. Surgical considerations and management of patients with mucocutaneous disorders. *Compend Contin Educ Dent*. 2010; 31:344–350. [PubMed: 20583504]
16. Berker DD, Dalziel K, Dawber RP. Pemphigus associated with nail dystrophy. *Br J Dermatol*. 1993; 129:461–464. [PubMed: 8217764]
17. Kolivras A, Gheeraert P, André J. Nail destruction in pemphigus vulgaris *Dermatology*. 2003; 206:351–352.
18. Ettlin DA. Pemphigus. *Dent Clin North Am*. 2005; 49:107–125. [PubMed: 15567364]
19. Martin L, Murrell DF. Measuring the immeasurable: a systematic review of outcome measures in pemphigus. *Paper Australas J Dermatol*. 2006; 47(Supp 11):A32–A33.
20. Rosenbach M, Murrell DF, Bystryn JC, et al. Reliability and convergent validity of two outcome instruments for pemphigus. *J Invest Dermatol*. 2009; 129:2404–2410. [PubMed: 19357707]
21. Murrell DF, Dick S, Ahmed AR, et al. Consensus statement on definitions of disease, end points, and therapeutic response for pemphigus. *J Am Acad Dermatol*. 2008; 58:1043–1046. [PubMed: 18339444]
22. Helou J, Allbritton J, Anhalt G. Accuracy of indirect immunofluorescence testing in the diagnosis of paraneoplastic pemphigus. *J Am Acad Dermatol*. 1995; 32:441–447. [PubMed: 7868713]
23. Mutasim DF, Adams BB. Immunofluorescence in dermatology. *J Am Acad Dermatol*. 2001; 45:803–822. [PubMed: 11712024]
24. Avgerinou G, Papafragkaki DK, Nasiopoulou A, et al. Correlation of antibodies against desmogleins 1 and 3 with indirect immunofluorescence and disease status in a Greek population with pemphigus vulgaris [published online Jan 5, 2012]. *J Eur Acad Dermatol Venereol*.
25. Zagorodniuk I, Weltfriend S, Shtruminger L, et al. A comparison of anti-desmoglein antibodies and indirect immunofluorescence in the serodiagnosis of pemphigus vulgaris. *Int J Dermatol*. 2005; 44:541–544. [PubMed: 15985020]

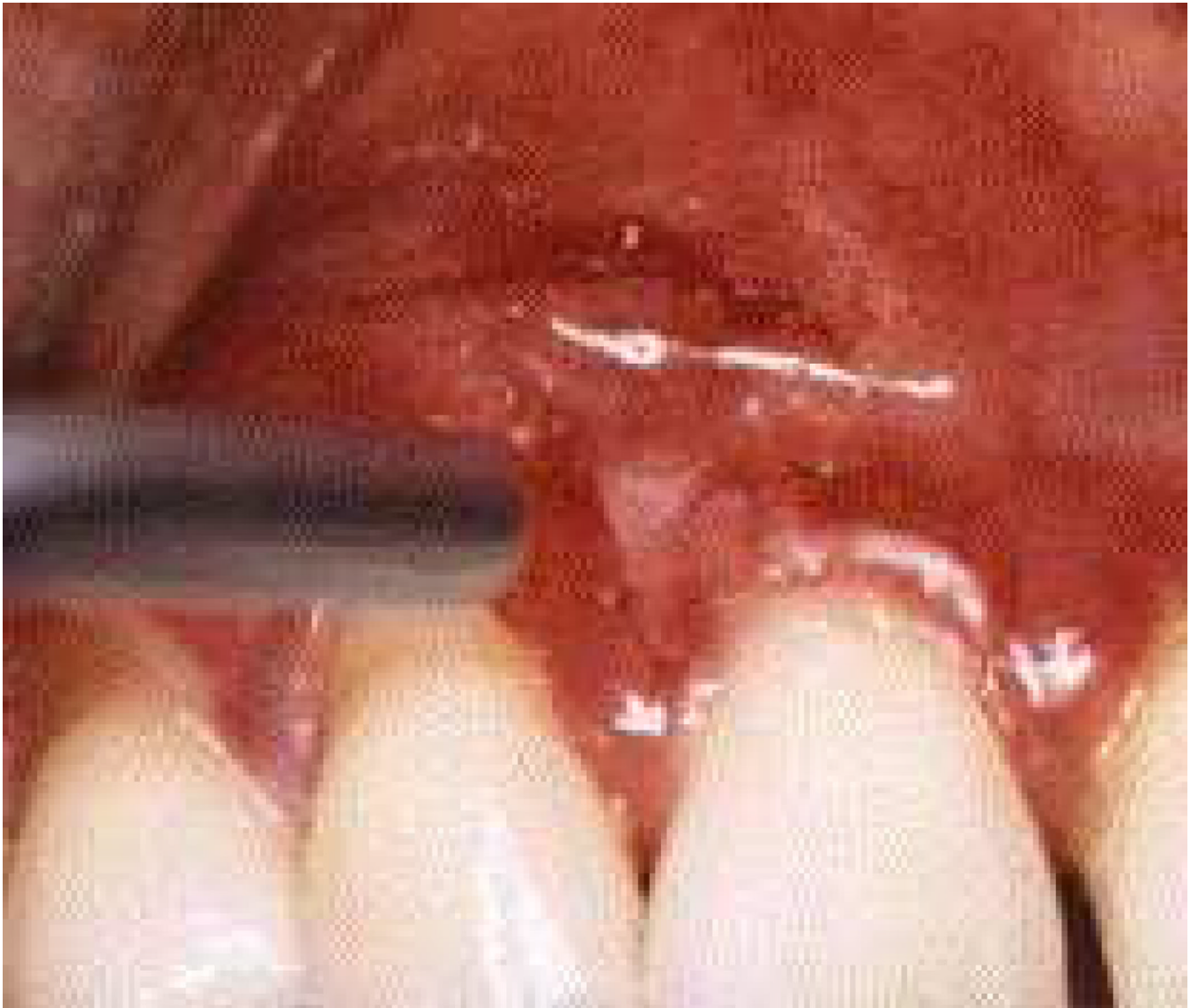26. Kwon EJ, Yamagami J, Nishikawa T, et al. Anti-desmoglein IgG autoantibodies in patients with pemphigus in remission. *J Eur Acad Dermatol Venereol.* 2008; 22:1070–1075. [PubMed: 18410336]
27. Harman KE, Seed PT, Gratian MJ, et al. The severity of cutaneous and oral pemphigus is related to desmoglein 1 and 3 antibody levels. *Br J Dermatol.* 2001; 144:775–780. [PubMed: 11298536]
28. Anhalt GJ. Paraneoplastic pemphigus: the role of tumours and drugs. *Br J Dermatol.* 2001; 144:1102–1104. [PubMed: 11422027]
29. Czernik A, Camilleri M, Pittelkow MR, et al. Paraneoplastic autoimmune multiorgan syndrome: 20 years after. *Int J Dermatol.* 2011; 50:905–914. [PubMed: 21781058]
30. Akman A, Kacaroglu H, Yilmaz E, et al. Periodontal status in patients with pemphigus vulgaris. *Oral Dis.* 2008; 14:640–643. [PubMed: 18627505]
31. Thorat MS, Raju A, Pradeep AR. Pemphigus vulgaris: effects on periodontal health. *J Oral Sci.* 2010; 52:449–454. [PubMed: 20881339]
32. Nousari HC, Anhalt GJ. Pemphigus and bullous pemphigoid. *Lancet.* 1999; 354:667–672. [PubMed: 10466686]
33. Ben Lagha N, Poulesquen V, Roujeau JC, et al. Pemphigus vulgaris: A case-based study. *J Can Dent Assoc.* 2005; 71:667–672. [PubMed: 16271165]
34. Hodgson TA, Malik F, Hegarty AM, et al. Topical tacrolimus: a novel therapeutic intervention for recalcitrant labial pemphigus vulgaris. *Eur J Dermatol.* 2003; 13:142–144. [PubMed: 12695129]
35. Lunardon L, Tsai KJ, Propert KJ, et al. Adjuvant rituximab therapy of pemphigus: a single center experience with 31 patients. *Arch Dermatol.* 2012; 148:1031–1036. [PubMed: 22710375]
36. Canalis E, Mazziotti G, Giustina A, et al. Glucocorticoid-induced osteoporosis: pathophysiology and therapy. *Osteoporos Int.* 2007; 18:1319–1328. [PubMed: 17566815]
37. Vojáková N, Fialová J, Vaňousová D, et al. Pemphigus vulgaris treated with adalimumab: case study. *Dermatol Ther.* 2012; 25:95–97. [PubMed: 22591504]
38. Behzad M, Mobs C, Kneisel A, et al. Combined treatment with immunoadsorption and rituximab leads to fast and prolonged clinical remission in difficult-to-treat pemphigus vulgaris. *Br J Dermatol.* 2012; 166:844–852. [PubMed: 22092243]
39. Lee FC. Longterm clinical remission of oral and cutaneous pemphigus with thalidomide. *Int J Dermatol.* 2011; 50:1120–1123. [PubMed: 22126875]
40. Feldman RJ, Ahmed AR. Relevance of rituximab therapy in pemphigus vulgaris: analysis of current data and the immunologic basis for its observed responses. *Exp Rev Clin Immunol.* 2011; 7:529–541.

### Key points

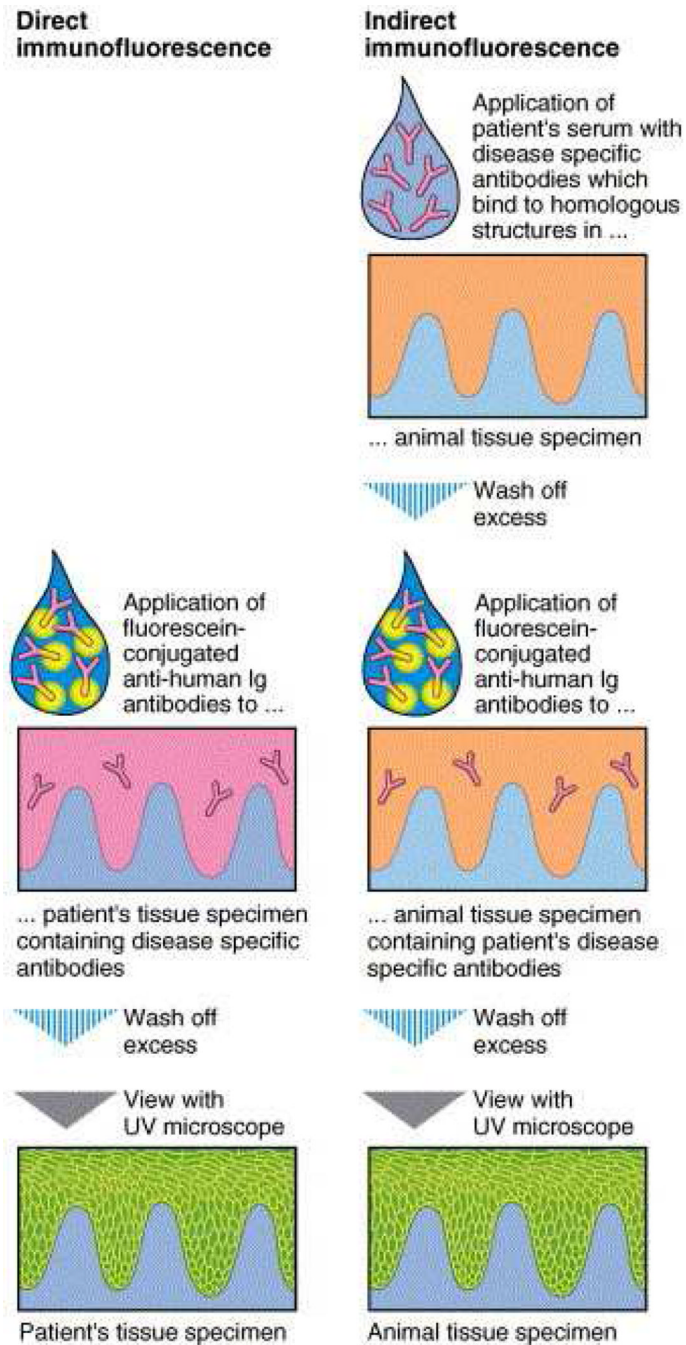
- Pemphigus vulgaris and paraneoplastic pemphigus manifest as flaccid mucosal bullae leading to erosions.
- Mucosal biopsy and direct immunofluorescence are necessary to differentiate pemphigus vulgaris and paraneoplastic pemphigus from other mucosal diseases. Indirect immunofluorescence and enzyme linked immunosorbent assays (ELISA) can aid in the diagnosis and be may be useful to monitor disease activity.
- Paraneoplastic pemphigus is normally associated with an underlying malignancy, usually of lymphoid origin. A complete blood count, CT scan of the chest, abdomen and pelvis, and a bone marrow biopsy may be indicated.
- Immunosuppressive agents can be used as steroid-sparing agents.
- Rituximab, an anti-CD20 monoclonal antibody, helps in treatment-refractory pemphigus vulgaris. Defining the role of Rituximab in earlier disease, and well as its safety profile, will require larger prospective studies.



**Figure 1.**  
Erosions of the gingival margin secondary to tissue fragility from brushing teeth.

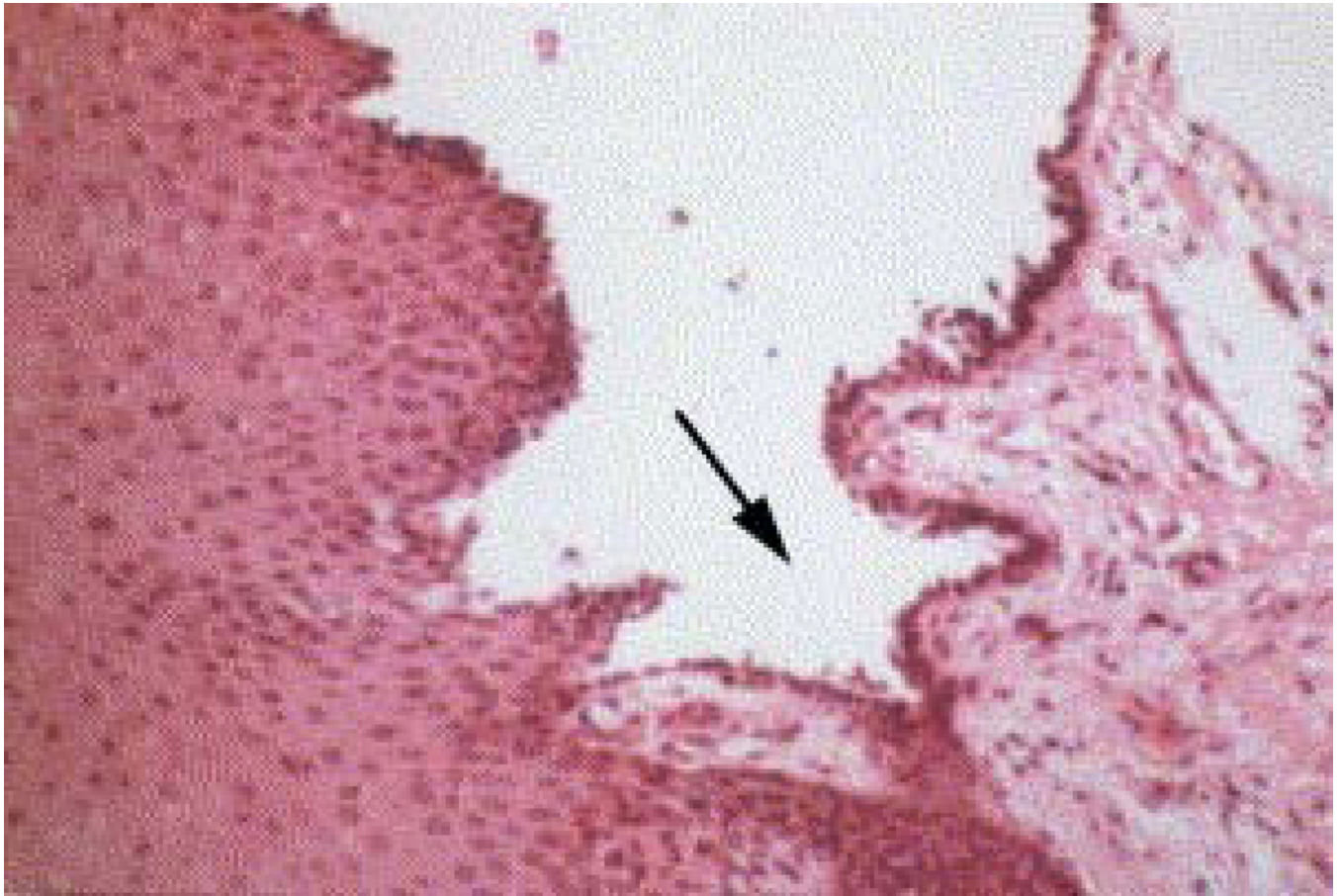

**Figure 2.**  
Light pressure causing a direct Nikolsky's sign.



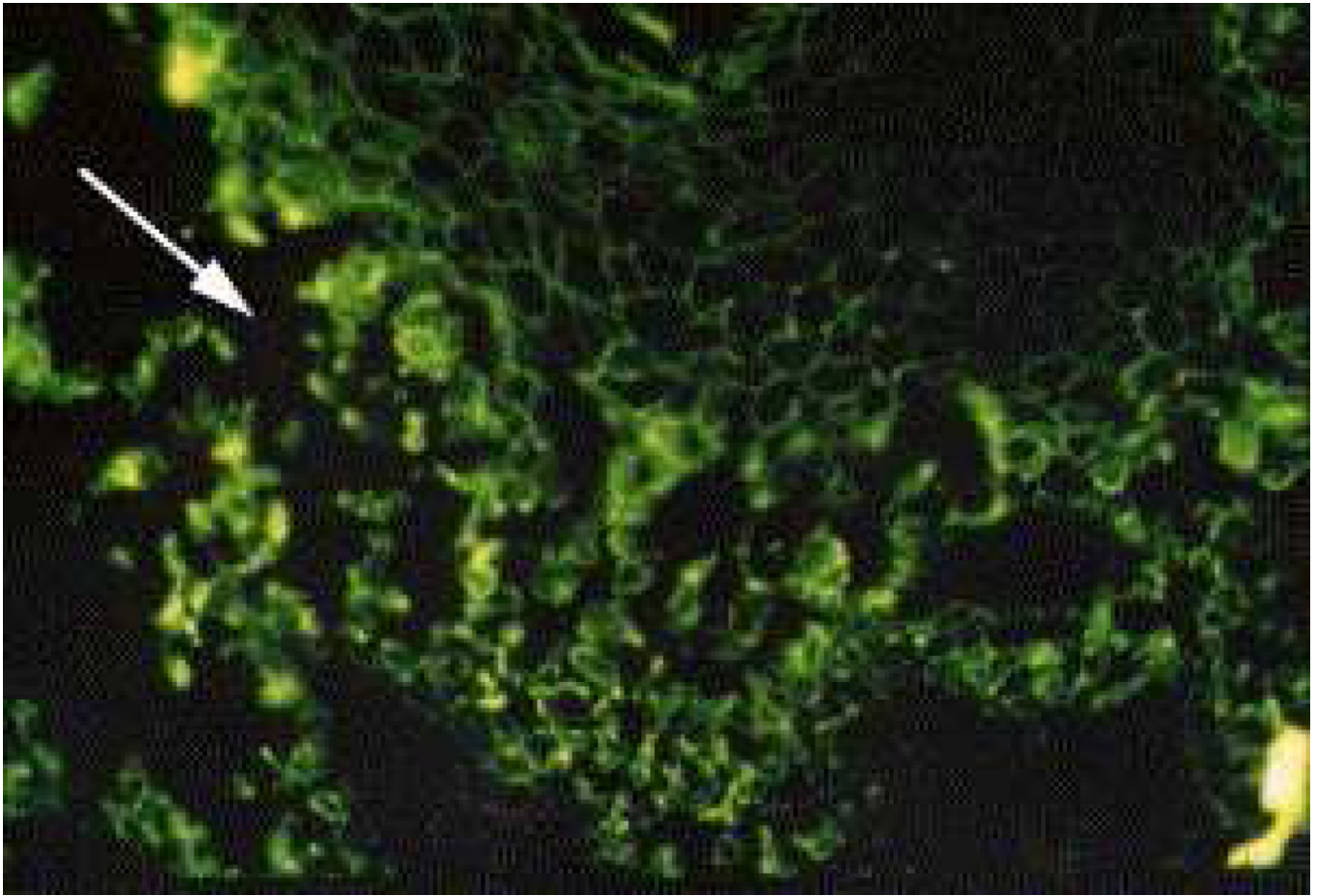
**Figure 3.**

Direct and indirect immunofluorescence techniques. On the left side of the figure, direct immunofluorescence visualizes autoantibodies deposited on the patient's skin specimen. On the right side of the figure, indirect immunofluorescence involves applying the patient's serum to animal tissue and then visualizing it with fluorescein-tagged antibodies.



**Figure 4.** Hematoxylin and eosin staining of pemphigus vulgaris demonstrating a suprabasilar blister (arrow) with acantholysis.





**Figure 5.**

Direct immunofluorescence of pemphigus vulgaris showing IgG deposition on epithelial surface. The area shows the suprabasilar blister cavity.

\*These figures have been previously published in:

Reference 18: Ettlín DA. Pemphigus. *Dent Clin North Am* 2005;49:107–25. Figure 1: pg 111; Figure 2: pg 112; Figure 3: 115 Figure 4: pg 113; Figure 5: pg 113

**Table 1**

Comparison of the Autoimmune Bullous Skin Disorder Intensity Score (ABSIS) and the Pemphigus Disease Area Index (PDAI)

<i>Rating scale</i>	<b>Autoimmune Bullous Skin Disorder Intensity Score (ABSIS)</b>	<b>Pemphigus Disease Area Index (PDAI)</b>
<i>Overview</i>	<p>Combines quantitative and qualitative components</p> <p><b>Quantitative:</b> Assigns weights to involved body surface area and types of lesions on the skin and oral mucosa/oropharynx</p> <p><b>Qualitative:</b> Subjective severity scale based ability to eat and drink</p>	<p>A quantitative measurement of the size and number of lesions on the body, scalp and mucous membranes. It incorporates both disease activity and disease damage.</p>
<i>Strength(s)</i>	<p>Easier to score than PDAI</p>	<p>Developed from the consensus of leading academic dermatologists<sup>21</sup></p> <p>Better inter- and intra-rater reliability compared to ABSIS</p> <p>Compared to ABSIS, might better detect changes in mild-moderate disease</p>
<i>Weaknesses</i>	<p>The majority of its inter-rater reliability comes from its subjective component</p> <p>Might not be able to detect clinically significant disease, since it depends on having at least 1% involvement in any of the body areas measured, which is frequently not the case.</p> <p>Difficult to incorporate into daily practice</p>	<p>Difficult to incorporate into daily practice</p>

**Table 2**

## Clinical and histopathologic differential diagnoses for pemphigus vulgaris

---

•	Mucosal involvement
–	Acute herpetic stomatitis
–	Aphthous stomatitis
–	Erythema multiforme
–	Stevens-Johnson syndrome
–	Lichen planus
–	Systemic lupus erythematosus
–	Mucous membrane pemphigoid
–	Paraneoplastic pemphigus
•	Cutaneous involvement
–	Pemphigus foliaceus
–	Linear IgA bullous dermatosis
–	Hailey-Hailey disease
–	Grover's disease
•	Histological
–	Other subtypes of pemphigus (paraneoplastic pemphigus, pemphigus foliaceus)
–	Hailey-Hailey disease
–	Darier's disease
–	Grover's disease

---

**Table 3**

## Clinical and histopathologic differential diagnoses for paraneoplastic pemphigus

---

•	Clinical
–	Pemphigus vulgaris
–	Cicatricial pemphigoid
–	Erythema multiforme
–	Stevens-Johnson syndrome
–	Lichen planus
–	Graft-versus-host disease
–	Persistent herpetic stomatitis
–	Stomatitis due to chemotherapy
•	Histological
–	Other subtypes of pemphigus
–	Drug eruption
–	Lichen planus
–	Erythema multiforme
–	Graft-versus-host disease

---

**Table 4****Pharmacologic treatments for pemphigus vulgaris**

---

Topical therapies<sup>33,34</sup>

High-potency corticosteroids (rinses, gels, pastes)

Tacrolimus ointment 0.1%

## First line treatments

- Corticosteroids 1 mg/kg/day with clinical remission in 4–12 weeks<sup>37</sup>
- Rituximab: 4 weekly infusions at 375 mg/m<sup>2</sup> of BSA (oncology dosing) or 1000 mg × 2 separated by 2 weeks (rheumatology dosing)

Other treatments<sup>37–39</sup>

- Intravenous immunoglobulin (sometimes combined with rituximab)
  - Azathioprine
  - Mycophenolate mofetil
  - Cyclophosphamide
  - Methotrexate
  - Others: gold, cyclosporine, plasmapheresis, extracorporeal photochemotherapy, tumor necrosis alpha inhibitors, thalidomide
-

**Table 5**

## Pharmacologic treatments for paraneoplastic pemphigus

---

- Prednisone (0.5–1 mg/kg)
- Cyclosporine (5 mg/kg), sometimes combined with prednisone
- Cyclophosphamide (2mg/kg), sometimes combined with prednisone and cyclosporine

Other treatments for PNP

- Immunoablative cyclophosphamide without stem cell rescue
- Immunoapheresis
- Intravenous immunoglobulin
- Rituximab
- Alemtuzumab

---