



University of Pennsylvania
ScholarlyCommons

Botswana-UPenn Scholarly Publications

Botswana-UPenn Partnership

6-2011

Use of Mobile Telemedicine for Cervical Cancer Screening

Kelly E. Quinley
University of Pennsylvania

Rachel H. Gormley
University of Pennsylvania, Rachel.Gormley@uphs.upenn.edu


Sarah Ratcliffe
University of Pennsylvania, sratclif@mail.med.upenn.edu

Ting Shih

Zsofia Szep
University of Pennsylvania

See next page for additional authors

Follow this and additional works at: http://repository.upenn.edu/botswana_schol

 Part of the [Female Urogenital Diseases and Pregnancy Complications Commons](#)

Recommended Citation

Quinley, Kelly E.; Gormley, Rachel H.; Ratcliffe, Sarah; Shih, Ting; Szep, Zsofia; Steiner, Ann; Ramogola-Masire, Doreen; and Kovarik, Carrie, "Use of Mobile Telemedicine for Cervical Cancer Screening" (2011). *Botswana-UPenn Scholarly Publications*. 20.
http://repository.upenn.edu/botswana_schol/20

This paper is posted at ScholarlyCommons. http://repository.upenn.edu/botswana_schol/20
For more information, please contact libraryrepository@pobox.upenn.edu.

Use of Mobile Telemedicine for Cervical Cancer Screening

Abstract

Visual inspection of the cervix with application of 4% acetic acid (VIA) is an inexpensive alternative to cytology-based screening in areas where resources are limited, such as in many developing countries. We have examined the diagnostic agreement between off-site (remote) expert diagnosis using photographs of the cervix (photographic inspection with acetic acid, PIA) and in-person VIA. The images for remote evaluation were taken with a mobile phone and transmitted by MMS. The study population consisted of 95 HIV-positive women in Gaborone, Botswana. An expert gynaecologist made a definitive positive or negative reading on the PIA results of 64 out of the 95 women whose PIA images were also read by the nurse midwives. The remaining 31 PIA images were deemed insufficient in quality for a reading by the expert gynaecologist. The positive nurse PIA readings were concordant with the positive expert PIA readings in 82% of cases, and the negative PIA readings between the two groups were fully concordant in 89% of cases. These results suggest that mobile telemedicine may be useful to improve access of women in remote areas to cervical cancer screening utilizing the VIA 'see-and-treat' method.

Keywords

cervix, acetic acid, VIA, vagina, Cervical cancer, HIV Positive

Disciplines

Diseases | Female Urogenital Diseases and Pregnancy Complications | Medicine and Health Sciences

Author(s)

Kelly E. Quinley, Rachel H. Gormley, Sarah Ratcliffe, Ting Shih, Zsofia Szep, Ann Steiner, Doreen Ramogola-Masire, and Carrie Kovarik

Use of mobile telemedicine for cervical cancer screening

Kelly E Quinley^{*}, Rachel H Gormley[†], Sarah J Ratcliffe[‡], Ting Shih[§], Zsafia Szep^{**}, Ann Steiner^{††}, Doreen Ramogola-Masire^{‡‡}, and Carrie L Kovarik[†]

^{*}University of Pennsylvania School of Medicine, Philadelphia, USA

[†]Department of Dermatology, University of Pennsylvania Medical Center, Philadelphia, USA

[‡]Department of Biostatistics and Epidemiology, CFAR Biostatistics Core, University of Pennsylvania School of Medicine, USA

[§]Click Diagnostics, Boston, Massachusetts, USA

^{**}Department of Medicine, Division of Infectious Diseases, University of Pennsylvania Medical Center, Philadelphia, USA

^{††}Department of Obstetrics and Gynecology, University of Pennsylvania Medical Center, Philadelphia, USA

^{‡‡}Botswana-UPenn Partnership, Women's Health Initiative, Gaborone, Botswana

Summary

Visual inspection of the cervix with application of 4% acetic acid (VIA) is an inexpensive alternative to cytology-based screening in areas where resources are limited, such as in many developing countries. We have examined the diagnostic agreement between off-site (remote) expert diagnosis using photographs of the cervix (photographic inspection with acetic acid, PIA) and in-person VIA. The images for remote evaluation were taken with a mobile phone and transmitted by MMS. The study population consisted of 95 HIV-positive women in Gaborone, Botswana. An expert gynaecologist made a definitive positive or negative reading on the PIA results of 64 out of the 95 women whose PIA images were also read by the nurse midwives. The remaining 31 PIA images were deemed insufficient in quality for a reading by the expert gynaecologist. The positive nurse PIA readings were concordant with the positive expert PIA readings in 82% of cases, and the negative PIA readings between the two groups were fully concordant in 89% of cases. These results suggest that mobile telemedicine may be useful to improve access of women in remote areas to cervical cancer screening utilizing the VIA 'see-and-treat' method.

Introduction

Cervical cancer is the leading cause of cancer mortality among women in the developing world.¹ The prevention of cervical cancer depends on widespread screening and accurate diagnosis of precursor lesions, followed by appropriate triaging and implementation of therapy.² Women in sub-Saharan Africa often present with advanced stages of cervical cancer despite the fact that precancerous lesions are detectable via cervical screening. This is the result of a lack of screening, lack of appropriate referral of women with cervical disease, and HIV-HPV (human papillomavirus) co-infection. While screening based on Papanicolaou (Pap) smears and conventional cytology has dramatically reduced mortality

from cervical cancer in industrialised countries (by 74% in the USA, for example³), such programmes are not feasible in low-resource settings because of their relatively high cost, the prolonged time between when testing occurs and when results are available, and the need for substantial infrastructure and trained personnel.⁴ Screening approaches that require few resources, and which can be performed by providers at various levels of training, are more appropriate in these areas.

One such approach is visual inspection of the cervix with the application of acetic acid (VIA). The VIA screening method is a simple, inexpensive, practical alternative to cytology-based Pap smear screening. A single VIA screening procedure has been estimated to reduce the lifetime risk of cervical cancer by 25%.⁵ Application of 4–5% acetic acid to the cervix causes dysplastic, neoplastic and certain types of normal epithelium to transiently appear white (Figures 1a and 1b), with normal cervical squamous epithelium appearing pink.⁶ Abnormal white areas, or acetowhite lesions, can then be treated with cryotherapy, or excised with a loop electrosurgical excision procedure (LEEP) or cold knife cone biopsy. VIA is appealing because it is affordable, requires few resources, and can be performed by a wide range of health-care workers (physicians, nurse midwives, local health-care workers). As the results of this test are immediate, such screening allows for a single appointment, 'see-and-treat' approach, where the patient can be treated during the screening visit. However, VIA as a screening tool relies on acetowhitening of the cervix, and while the sensitivity for detecting precancerous lesions is significant, the specificity remains low.⁷

The major disadvantage of VIA is that it is a subjective test and interpretation can vary from provider to provider. Estimates of the accuracy of this method vary widely, with significantly higher sensitivity and specificity for detecting disease achieved by physicians than by nurses.⁸ Because experience and training determine the effectiveness of VIA as a screening tool, a strategy is required for distant preceptorship and supervision of novice health-care staff.² Mobile phone telemedicine has the potential to assist non-physician health-care workers in interpreting VIA results, thereby extending current resources to reach more women.

Our primary aim was to determine whether mobile telemedicine is safe and effective for cervical cancer screening when employed as an adjunct to VIA. We assessed the agreement between (1) diagnoses based on visualization of the cervix after VIA application of 4% acetic acid (control) during a live patient clinical encounter and (2) diagnoses for the same patient encounter based on photographic evaluation using mobile phone telemedicine (photographic inspection with acetic acid, PIA).

Methods

The study was conducted in August 2009 in Gaborone, the capital city of Botswana. All enrolled subjects were women recruited as they presented to the Antiretroviral Therapy (ART)/HIV Bontleng Clinic, following counselling on increased risk for cervical cancer due to their HIV-positive status. Subjects were screened at Bontleng Clinic according to the clinic's routine protocol, and were counselled in Setswana by the four participating nurse midwives. All patient histories were self-reported. Subjects were deemed eligible for enrolment in the study if they were over 18 years old and able to provide informed consent. Since potential study candidates were drawn from women visiting HIV treatment clinics, all of the study subjects were HIV-positive. The exclusion criteria consisted of conditions that could interfere with visualization of the cervix, therefore women who had previously been diagnosed with and/or treated for cervical precancer and cancer with surgical removal of part of the cervix were excluded. Pregnant women were also excluded from the study. The study was approved by the appropriate ethics committee, as well as the Ministry of Health in

Botswana. All subjects were counselled and provided written informed consent for participation in the study.

Procedure

Each woman underwent an initial speculum examination and visual cervical inspection without acetic acid by a nurse midwife. Next, each subject had an endocervical swab performed with a CytoSmear cervical cytology brush to obtain cells for HPV testing, which were stored in ThinPrep medium. After obtaining the endocervical sample, the nurse midwife examining the patient used forceps to soak a cotton ball in 4% acetic acid and gently press it against the cervix and vaginal fornices for three minutes. After removing the cotton ball, the cervix was inspected for acetowhite lesions using standard VIA criteria, which included the presence of sharply-demarcated acetowhite areas as well as ulcerations or growths. Digital images of the cervix were obtained using a mobile phone (SGH-U900, Samsung, Seoul) equipped with a 5 megapixel camera and zoom function. The photographs were taken by two medical students with one day's training in taking cervical pictures with the mobile phone camera. These images were transmitted by MMS and stored in a database to be evaluated by the same nurse midwife who performed the face-to-face examination three months after the initial visit, and who would be blinded to her original evaluation of the patient's cervix. HPV genotyping of the patient's ThinPrep endocervical sample was performed using Gold Taq with modified MY09/11 PCR to evaluate the presence of 32 different genotypic HPV strains, namely HPV 5, 8, 16, 18, 30, 31, 33, 34, 35, 39, 45, 51, 52, 53, 54, 56, 58, 59, 61, 62, 66, 67, 68, 70, 71, 72, 73, 81, 82, 83, 84 and 85. PCR products from positive samples were typed by dot-blot hybridization using type-specific probes, with masked intra-batch and inter-batch repeats to verify the reproducibility of the HPV DNA assays.

Subjects deemed to be VIA positive, indicating an increased risk for precancer or cancerous lesions, were treated at the same visit with cryotherapy, i.e. in a see-and-treat model of care. Cryotherapy is a liquid nitrogen-based epithelial freezing therapy used to remove epithelial lesions on the cervix. In cases where the lesions occupied over 75% of the cervix, extended into the cervical os, could not be fully visualized, or were extremely thick or suggestive of invasive carcinoma, referral was made to a tertiary medical centre for treatment by loop electrosurgical excision procedure (LEEP) or cervical cone biopsy. The cone biopsy specimens were sent to the Botswana National Laboratory for routine processing and histopathological diagnosis.

Diagnostic reliability

Four nurse midwives trained in face-to-face VIA screening with the expert gynaecologist for four months prior to the beginning of the study. In order to evaluate the diagnostic reliability of PIA compared to conventional VIA, the concordance was calculated between the diagnosis made by the on-site nurse midwife using VIA and the diagnosis made by an expert off-site gynaecologist at a tertiary care centre using PIA.

After a period of three months following the completion of the study, the nurses were shown PIA images from patients whom they had screened with VIA, and asked to determine whether the subject was positive, negative, or insufficient for acetowhite cervical changes based on looking at the photograph alone (PIA). Concordance was determined for the diagnosis made by the on-site nurse midwife using VIA and the diagnosis made by the same nurse midwife (blinded to the initial patient encounter) from PIA images. The digital PIA images were 1 megabyte in size when acquired and were not compressed when sent from the mobile phone to the web server.

While reviewing the PIA images on various laptop computers with 36–38 cm LCD computer screens using the basic viewer provided with Microsoft Windows, and while zooming in at will, the on-site nurse midwives determined whether the VIA and PIA results were positive or negative for acetowhite changes suggestive of precancerous or cancerous epithelial changes, or if the photos were of insufficient quality for the detection of such acetowhite changes. The expert off-site gynaecologist was also instructed to label PIA images as either positive, negative or insufficient for the presence of precancerous or cancerous-appearing acetowhite lesions.

Although the nurses were not tested to ensure the attainment of a set level of expected performance, they participated in continuous weekly quality assurance training in which they reviewed all VIA cervical photographs taken that week to check whether their VIA diagnoses had been similar to the expert's diagnoses.

Statistical analysis

Agreement between VIA and PIA results was defined as concordance in diagnosis as either positive, negative or insufficient. Kappa statistics were used to examine whether the concordance exceeded that expected by chance.

Results

The four nurses (labelled Nurse 1 through Nurse 4) had 10, 20, 14 and 10 years of experience, respectively, as nurse midwives prior to the commencement of the study. In the first month of training, the nurses each took 100 VIA images with a hand-held digital camera and completed 100 VIA readings, as well as 35 cryotherapy procedures. Their assessments were checked against those of the expert gynaecologist, who already had five years of experience in VIA and colposcopy treatment. By the end of the first three months of training, completed prior to the commencement of this study, the nurses' VIA assessments agreed with those of the expert in over 90% of cases.

A total of 99 women were invited to enroll in the study and received HPV testing from endocervical swabs. All of these women were HIV-positive and 71% were also HPV-positive. Condom use practices of these women are summarized in Table 1. The women were often co-infected with multiple HPV types: 47% were infected with two or more different HPV types (the mean number of strains in the HPV-positive subjects was 2.2 per patient). The most common types detected were HPV 35 (13%), 16 (9%), 33 (9%), 53 (9%), 30 (8%), 52 (8%), 58 (8%), 51 (6%) and 71 (6%), which is illustrated in Table 2. A total of 79% of the HPV-positive subjects had at least one strain of high-risk type HPV genotypes, which in the study cohort included HPV types 16, 18, 31, 33, 34, 35, 39, 45, 51, 52, 53, 56, 58, 59, 68 and 82.^{7,9} The prevalence of these high-risk HPV strains in our study cohort was as follows: HPV 16 (9%), 18 (2%), 31 (3%), 33 (9%), 34 (0%), 35 (13%), 39 (3%), 45 (4%), 51 (6%), 52 (8%), 53 (9%), 56 (3%), 58 (8%), 59 (1%), 68 (5%) and 82 (3%).

Although 99 women were invited to enroll in the study, four of them were ultimately excluded based on cervical bleeding or treatment for sexually transmitted infections, which did not allow VIA screening to be performed. The sociodemographic and sexual history characteristics of the 95 women who received VIA are summarized in Table 3. Their median age was 34 years. Twenty-seven (28%) were found to have positive VIA results with acetowhite lesions suspicious for cervical precancer or cancer found during their in-person VIA interpretation by a clinic nurse. A total of 10 women were referred for further management at a LEEP clinic located nearby at a tertiary hospital centre.

VIA results

Of the 95 women seen for VIA assessment, two did not receive a definitive VIA reading owing to the presence of blood obscuring the cervix. The results of the remaining 93 study subjects who received VIA screening results and their HPV status are shown in Table 4. All 26 subjects who were VIA positive were also HPV-positive. Approximately 92% of the women with positive VIA results were infected with at least one strain of high-risk HPV. However, only 47% of the subjects who had been infected with high-risk HPV subtypes tested positive with VIA. A total of 5% of women who were infected with only non-high-risk HPV strains received positive VIA screening results. All subjects who were HPV-negative had a negative VIA determination, indicating that VIA had 100% specificity for detecting HPV-induced cervical epithelial changes in these women.

The expert gynaecologist made a definitive positive or negative reading on the PIA results of 64 out of the 95 women whose PIA images were also read by the nurse midwives. The remaining 31 PIA images were deemed insufficient in quality for a reading by the expert gynaecologist.

Nurse PIA

The nurses' individual PIA determinations are summarized in Table 5. PIA photographs were considered insufficient by the expert for 31 of the 95 subjects, and were excluded from the analysis. Two more were excluded as one nurse did not submit PIA diagnoses for these patients. Therefore the results of the remaining 62 of these subjects' PIA readings are included. Collectively, the nurses decided that 66% of the PIA results were negative, 29% were positive and 5% were insufficient for the diagnosis of acetowhite changes.

Agreement between nurse PIA versus expert PIA

A cross-tabulation of nurse PIA and expert PIA results for all 62 subjects whose PIA photos were sufficient for a reading by the expert gynaecologist and who received PIA readings by the nurse midwives is shown in Table 6. Of all the PIA results determined to be negative by the expert, 89% were also considered negative by the nurses. In addition, 82% of the positive expert PIA readings were also determined to be positive by nurse PIA. Based on the kappa statistic (0.71), the nurses and expert agreed more often than would be expected by chance ($P < 0.001$). The diagnostic concordance between nurse PIA and expert PIA results varied between nurses. The PIA results of Nurse 1 agreed with those of the expert in 69% of cases, and those of Nurse 2 agreed with the expert in 77% of cases. Both Nurse 3 and Nurse 4 agreed with the expert in every PIA diagnosis, yielding a diagnostic concordance of 100%.

Nurse VIA versus Nurse PIA

When including PIA results from all 93 study subjects who received VIA readings, counting those deemed by the expert as insufficient, the individual nurse VIA and PIA diagnoses agreed in 70% of cases. Based on the kappa statistic (0.38), the nurse VIA and PIA agreed more than expected by chance ($P < 0.001$). Because nurses did not classify VIA as insufficient as frequently as did the expert, cases of PIA categorization as insufficient by the expert were automatically counted statistically as non-concordance. However, when excluding the 31 insufficient PIA cases, the nurse VIA and PIA showed an overall 81% diagnostic concordance, which is greater than would be expected by chance according to the kappa statistic ($P < 0.001$).

Discussion

Previous research has demonstrated that transmitted images of the cervix can allow the accurate diagnosis of cervical lesions.² These studies used images taken by high-quality

digital cameras in colposcopy clinics. The aim of the present study was to determine whether mobile phone photographs could be of sufficient quality for accurate remote VIA diagnosis. The benefit would be the facilitation of remote cervical cancer screening, as photographs could be transmitted from mobile phones to a website via MMS without the need for an Internet connection at the clinical site where the cervical photos were taken. The limitation of mobile phone photographs lies in their lower picture quality compared to that of conventional digital cameras. In colposcopy, where the cervix is visualized through the vagina, a zoom function must be available and of sufficient power to enlarge the cervix in order to use VIA to visualize cervical acetowhite lesions. Our results indicate that in 70% of cases, remote diagnosis using mobile phone photographs was fully concordant with in-person VIA results. When photographs deemed by an expert gynaecologist to be grossly insufficient for visualizing cervical lesions were excluded, teleradiology was concordant with in-person VIA examination in approximately 81% of cases.

In the present study, two pragmatic reference standards were used to assess the nurses' results. The first was the in-person VIA conducted by a nurse midwife at Bontleng Clinic. The second was the expert gynaecologist's reading of the PIA results. Judging the nurse PIA results by the first reference standard allows the determination of whether the image quality of the mobile phone photos is high enough to allow for concordant diagnosis of cervical lesions in person versus with photographs.

The concordance of teleradiology between the nurse PIA and expert PIA increased when 31 photographs deemed insufficient by the expert for a PIA reading were excluded from the analysis. It is important to look at the two groups of results, both including and excluding these insufficient photographs, for several reasons. First, in a clinical setting, training of nurses and other health providers could focus on ensuring that photograph quality was sufficient for making a PIA diagnosis remotely. Considerations in taking adequate photographs of the cervix with the Samsung Soul U900 mobile phone include using adequate and appropriate lighting, minimizing glare from the metal speculum (Figure 2), successfully using the camera focus to bring the cervix into view and understanding the appropriate distance to place the camera for a clear photograph. Another consideration is the placement of the speculum used to visualize the cervix for the VIA procedure. Poor visualization of the cervix and the intrusion of sections of vaginal wall (Figure 3) or hair (Figure 4) into the line of sight between the camera lens and the cervix led to poorer quality images. The use of a mobile phone camera with an automatic zoom did not allow for manual determination of the cervical section in focus, and therefore the camera would frequently focus automatically on vaginal wall or hair, and the cervix would not be visualized clearly. Poor speculum placement can also cause the clinician to overlook positive acetowhite lesions if the vaginal fornices are obscured. In a non-study setting, women whose PIA photographs were insufficient would be referred to a clinic for in-person VIA and colposcopy with a trained professional. These constitute lessons learned about obtaining photographs of sufficient quality for accurate PIA, and will be valuable in the training of future health workers taking cervical photographs for remote diagnosis.

Excluding the 31 insufficient photographs gave a diagnostic concordance of 81% between nurse PIA and nurse VIA results. This illustrates that when photographs are taken with sufficient quality, mobile phone technology can be an effective method of transmitting high-quality images, allowing clinicians to make a diagnosis from a PIA photo remotely that is similar to the diagnosis they would make with VIA in person. However, even when these 31 insufficient photographs are included in the analysis, a 70% diagnostic concordance between nurse VIA and nurse PIA results confirms that PIA with mobile phone photographs has great potential for increasing the access of women to cervical cancer screening using the VIA 'see-and-treat' approach.

Another factor that could have decreased diagnostic concordance between nurse VIA and nurse PIA results concerns the training of the nurses. At the commencement of the study, each nurse had received only four months of in-person VIA training. Once the study cervical photographs were taken, a three-month period passed before the nurses were shown the cervical photographs for PIA diagnosis. This was done to blind nurses to their initial VIA diagnosis. However, the nurses continued to participate in VIA quality assurance training during that three-month period. This might have changed the agreement between nurse VIA and nurse PIA diagnoses in our study.

The second reference standard was the expert gynaecologist's reading of the PIA results. Again, the subjective nature of VIA is a limiting factor. Excluding the expert's insufficient PIA photographs, the positive nurse PIA readings were concordant with the positive expert PIA readings in 82% of cases, and the negative PIA readings between the two groups were fully concordant in 89% of cases. In both series, the nurses and expert agreed more than expected by chance.

Based on this diagnostic agreement, we conclude that mobile telemedicine technology is a reliable method for diagnosing cervical lesions compared to in-person gynaecological evaluation. The use of this technique has the potential to connect resource-poor cancer screening centres to remotely located gynaecologists in order to provide screening for women throughout rural Africa with otherwise limited access to care. In addition, these results are encouraging as they demonstrate that health providers with little prior experience in VIA can be trained quickly to conduct VIA screening, and to read PIA results remotely. This bodes well for implementing a PIA training programme in resource-poor areas where cervical cancer screening services are needed.

A limitation of the present study was the subjective nature of VIA as a visually-based screening tool. Even if a particular nurse has full concordance between her VIA and PIA diagnoses, that nurse may be more or less adept at recognizing true positive acetowhite lesions using the VIA approach, leading to discordance when compared with expert PIA interpretation.

Some studies have shown VIA to be less sensitive and specific than HPV testing. For example, one study in India illustrated that HPV testing had a higher sensitivity (100%) and specificity (91%) for detecting advanced stage cervical carcinoma in situ compared to Pap cytology (sensitivity 78%; specificity 86%) and VIA (sensitivity 32%; specificity 88%).¹⁰ However, resource-poor settings where screening clinics lack access to HPV testing materials must provide cervical cancer screening with the resources that they are able to obtain. VIA represents the least expensive of these three methods of screening in circumstances where resources are lacking, and therefore remains an important screening modality for the prevention of cervical cancer-related deaths.

All 26 study subjects who had positive VIA results were also HPV-positive. Approximately 92% of these women with positive VIA results were infected with at least one strain of high-risk HPV. This highlights the cervical cancer risk for these HIV-positive patients, as by the time of screening, there was enough cervical epithelial dysplasia to be detected by VIA. Although the size of the study was small, these findings may have implications for the utility of currently available HPV vaccines, such as Gardasil, in Botswana and other areas of Southern Africa, as the vaccine covers only oncogenic HPV strains 16 and 18. Larger studies are needed to further investigate the distribution of HPV types in Botswana and surrounding areas of sub-Saharan Africa.

Conclusions

Previous studies have demonstrated that digital cameras are capable of producing good quality, high resolution images, which can be used to perform magnified examination of the cervix and vagina. There is mounting evidence to suggest that digital camera-based assessment provides consistent and accurate assessment of lesions of the reproductive tract.¹¹ Digital cameras have the advantages of portability, ease of use and low cost, compared to colposcopy. However, in areas without computer access or reliable Internet connectivity, it becomes cumbersome or impossible to transmit digital images for consultation. Telemedicine performed with an appropriate mobile camera phone has the advantage of not requiring Internet connections or an electricity supply, and allows images to be transmitted immediately. This provides the opportunity for evaluation by a remote expert while the patient is still in the clinic.

We believe that mobile telemedicine technology allows for safe and efficacious remote diagnosis by expert gynaecologists. If remote diagnoses can be made effectively and safely using mobile telemedicine, women can be triaged, with reduced referral delays and decreased need for travel from remote sites.² Increasing cervical cancer screening services by using mobile telemedicine PIA could substantially reduce the prevalence of cervical cancer, especially in areas where a high HIV infection rate and limited access to gynaecological services and cervical cancer screening increase the burden of cervical cancer morbidity and mortality.

Acknowledgments

We are grateful to Ting Shih of ClickDiagnostics; Dr Robert D Burk for HPV PCR testing of all samples; Dr Danielle Burkland for help in testing the Samsung camera's feasibility for use with VIA; Zsofia Szep for advice about the study design; and to nurse midwives Gracious Dithabang, Elizabeth Chibaya, Bakgaki Ratshaa and Metlha Chunga for their help with study enrolment and language translation. The work was funded by a Penn Center for Aids Research grant.

References

1. Parkin DM, Bray F, Ferlay J, Pisani P. Estimating the world cancer burden: Globocan 2000. *Int J Cancer*. 2001; 94:153–6. [PubMed: 11668491]
2. Ferris DG, Macfee MS, Miller JA, Litaker MS, Crawley D, Watson D. The efficacy of telecolposcopy compared with traditional colposcopy. *Obstet Gynecol*. 2002; 99:248–54. [PubMed: 11814505]
3. Saslow D, Runowicz CD, Solomon D, et al. American Cancer Society Guideline for the Early Detection of Cervical Neoplasia and Cancer. *J Low Genit Tract Dis*. 2003; 7:67–86. [PubMed: 17051049]
4. Roblyer D, Richards-Kortum R, Park SY, Adewole I, Follen M. Objective screening for cervical cancer in developing nations: lessons from Nigeria. *Gynecol Oncol*. 2007; 107:S94–7. [PubMed: 17825396]
5. Goldie SJ, Gaffikin L, Goldhaber-Fiebert JD, et al. Cost-effectiveness of cervical-cancer screening in five developing countries. *N Engl J Med*. 2005; 353:2158–68. [PubMed: 16291985]
6. Ferris DG. Cervicography – an adjunct to Papanicolaou screening. *Am Fam Physician*. 1994; 50:363–70. [PubMed: 8042572]
7. Schiffman M, Wentzensen N. From human papillomavirus to cervical cancer. *Obstet Gynecol*. 2010; 116:177–85. [PubMed: 20567185]
8. Sangwa-Lugoma G, Mahmud S, Nasr SH, et al. Visual inspection as a cervical cancer screening method in a primary health-care setting in Africa. *Int J Cancer*. 2006; 119:1389–95. [PubMed: 16619217]
9. de Villiers EM, Fauquet C, Broker TR, Bernard HU, zur Hausen H. Classification of papillomaviruses. *Virology*. 2004; 324:17–27. [PubMed: 15183049]

10. Gravitt PE, Paul P, Katki HA, et al. Effectiveness of VIA, Pap, and HPV DNA testing in a cervical cancer screening program in a peri-urban community in Andhra Pradesh, India. *PLoS One*. 2010; 5:e13711. [PubMed: 21060889]
11. Jamshidi R, Blumenthal P. Digital assessment of the reproductive tract (DART). *J Acquir Immune Defic Syndr*. 2004; 37:S171–3. [PubMed: 16419268]

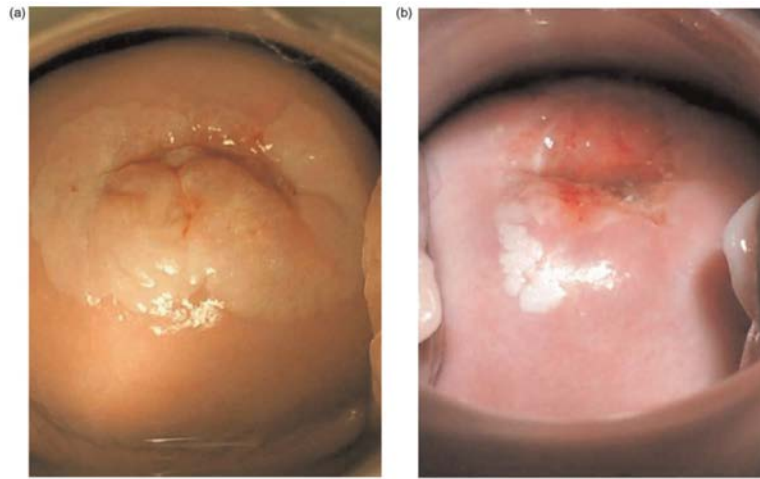


Figure 1a and Figure 1b.
Positive acetowhite lesions after VIA with the application of 4% acetic acid to the cervix for 3 min

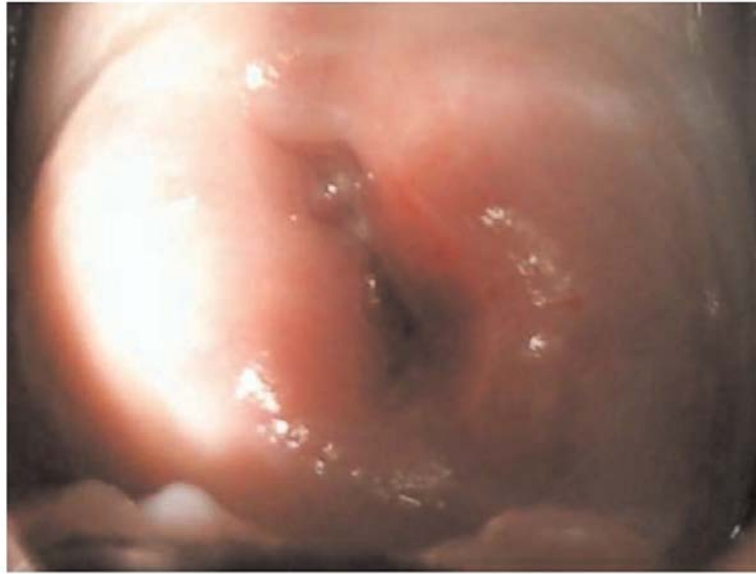

Figure 2. Glare during image capture, causing the camera's focus to fall on the brightest area, and resulting in the cervix falling out of focus

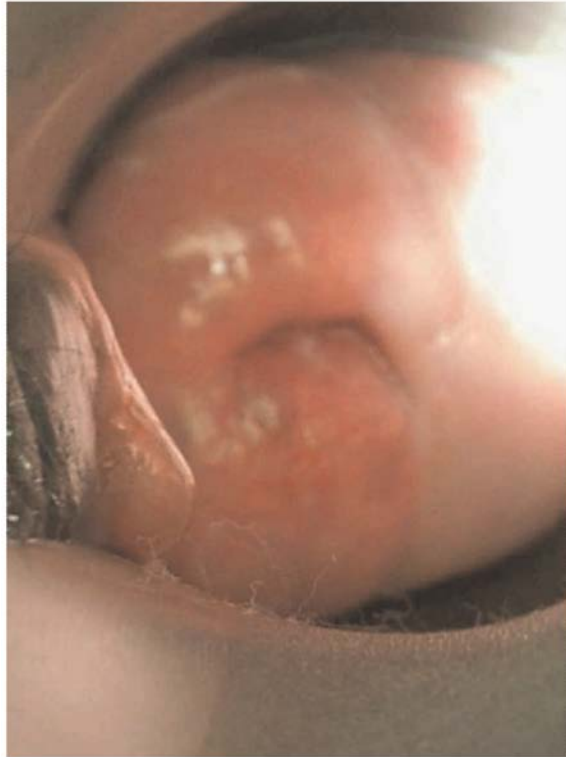

Figure 3. Sections of vaginal wall protruding into the view between camera and cervix redirected the camera's focus away from the cervix

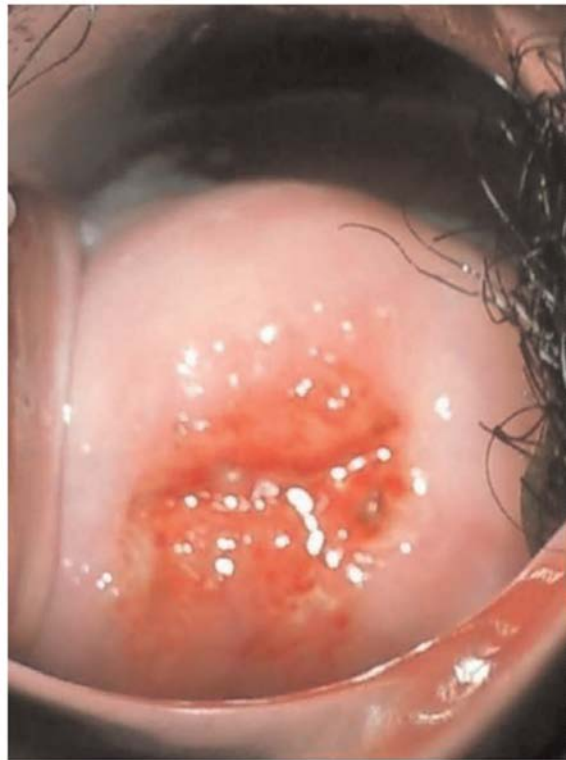

Figure 4.
Hair protruding into the field of view between camera and cervix redirected the camera's focus away from the cervix

Table 1

Condom use of the 99 enrolled study subjects

<i>Barrier contraceptive use</i>	<i>n</i>	<i>%</i>
Doesn't use barrier contraception	17	17
Uses condoms	74	78
<i>Frequency of condom use with regular partners</i>	<i>n</i>	<i>%</i>
Sometimes uses condoms	5	7
Almost always uses condoms	12	16
Always uses condoms	57	77

Table 2Most common HPV subtypes in the study subjects ($n = 99$)

HPV type	Prevalence (%)	High-risk type
16	9	Yes
30	8	No
33	9	Yes
35	13	Yes
51	6	Yes
52	8	Yes
53	9	Yes
58	8	Yes

Table 3

Sociodemographic and sexual history characteristics of the 95 study subjects who received VIA screening

Age range (years)	21–65		
Average age (years)	36		
Average age at first intercourse (years)	18		
Average number of lifetime partners	6		
Lifetime sexual partners	<i>n</i>	%	
1	7	7	
2–5	49	52	
6–10	29	31	
11–20	8	8	
21–40	2	2	

Table 4

Results of in-person VIA screening tests and HPV status for the 93 study subjects who received VIA results

<i>HPV positive</i>	<i>VIA</i>			<i>Total</i>
	<i>Negative</i>	<i>Positive</i>	<i>Insufficient image</i>	
No	27	0	0	27
Yes	38	26	2	66
				93
<i>High-risk HPV type</i>				
No	39	2	1	42
Yes	26	24	1	51
				93

Table 5

Individual nurse PIA results

Nurse	Negative	Positive	Insufficient image	Total
1	8	5	3	16
2	7	6	0	13
3	13	6	0	19
4	13	1	0	14

Table 6

Nurse PIA versus Expert PIA results for the 64 subjects whose PIA photographs were sufficient for interpretation by an expert gynaecologist

<i>Nurse PIA</i>	<i>Expert PIA</i>	
	Negative	Positive
Negative	40	1
Positive	4	14
Insufficient image	1	2
<i>Nurse PIA versus Expert PIA</i>	<i>n</i>	<i>%</i>
Complete concordance of positive diagnoses	40	88.9
Complete concordance of negative diagnoses	14	82.4