



University of Pennsylvania
ScholarlyCommons

Botswana-UPenn Scholarly Publications

Botswana-UPenn Partnership

2-1-2009

Tenofovir-Associated Nephrotoxicity in Two HIV-Infected Adolescent Males

Sarah M. Wood

Samir S. Shah

University of Pennsylvania, Samir.Shah@uphs.upenn.edu

Andrew P. Steenhoff

University of Pennsylvania, steenhoff@email.chop.edu

Kevin E. C Meyers

Bernard S. Kaplan

See next page for additional authors

Follow this and additional works at: http://repository.upenn.edu/botswana_schol

 Part of the [Medical Genetics Commons](#), and the [Medical Immunology Commons](#)

Recommended Citation

Wood, Sarah M.; Shah, Samir S.; Steenhoff, Andrew P.; Meyers, Kevin E. C; Kaplan, Bernard S.; and Rutstein, Richard M., "Tenofovir-Associated Nephrotoxicity in Two HIV-Infected Adolescent Males" (2009). *Botswana-UPenn Scholarly Publications*. 47.
http://repository.upenn.edu/botswana_schol/47

This paper is posted at ScholarlyCommons. http://repository.upenn.edu/botswana_schol/47
For more information, please contact libraryrepository@pobox.upenn.edu.

Tenofovir-Associated Nephrotoxicity in Two HIV-Infected Adolescent Males

Abstract

We report two cases of tenofovir (TDF)-associated nephrotoxicity in perinatally HIV-infected adolescents. The first case, a 16-year-old African American male with an absolute CD4⁺ cell count of 314 cells/mm³, presented with an abrupt rise in serum creatinine leading to irreversible renal failure while on TDF-containing highly active antiretroviral therapy (HAART). While the patient had evidence of underlying kidney disease, the timing of his renal failure indicates that TDF played a central role. The second case, a 16-year-old African-American male with an absolute CD4⁺ cell count of 895 cells/mm³, presented with rickets and hypophosphatemia while receiving TDF-based HAART. To our knowledge, these cases represent the first reports of TDF-associated irreversible renal failure and rickets in pediatric patients. We believe these cases highlight important and potentially irreversible side effects of this agent and emphasize the need for further studies of the renal safety of TDF in pediatric patients.

Keywords

tenofovir (TDF), HIV-infected adolescents, highly active antiretroviral therapy (HAART), kidney disease

Disciplines

Medical Genetics | Medical Immunology | Medicine and Health Sciences

Author(s)

Sarah M. Wood, Samir S. Shah, Andrew P. Steenhoff, Kevin E. C Meyers, Bernard S. Kaplan, and Richard M. Rutstein

Case Report

Tenofovir-Associated Nephrotoxicity in Two HIV-Infected Adolescent Males

Sarah M. Wood, M.D.,¹ Samir S. Shah, M.D., MSCE,^{2,3,5} Andrew P. Steenhoff, M.B., B.Ch.,^{3,5,6}
Kevin E.C. Meyers, M.D.,⁴ Bernard S. Kaplan, M.B., B.Ch.,⁴ and Richard M. Rutstein, M.D.^{1,2}

Abstract

We report two cases of tenofovir (TDF)-associated nephrotoxicity in perinatally HIV-infected adolescents. The first case, a 16-year-old African American male with an absolute CD4⁺ cell count of 314 cells/mm³, presented with an abrupt rise in serum creatinine leading to irreversible renal failure while on TDF-containing highly active antiretroviral therapy (HAART). While the patient had evidence of underlying kidney disease, the timing of his renal failure indicates that TDF played a central role. The second case, a 16-year-old African-American male with an absolute CD4⁺ cell count of 895 cells/mm³, presented with rickets and hypophosphatemia while receiving TDF-based HAART. To our knowledge, these cases represent the first reports of TDF-associated irreversible renal failure and rickets in pediatric patients. We believe these cases highlight important and potentially irreversible side effects of this agent and emphasize the need for further studies of the renal safety of TDF in pediatric patients.

Introduction

TENOFOVIR DISOPROXIL FUMARATE (TDF), a nucleotide reverse transcriptase inhibitor, received Federal Drug Administration (FDA) approval for use in adult patients in October 2001. TDF is often used to treat older children and adolescents, particularly those receiving salvage regimens, although it is not FDA approved for use in patients under the age of 18. However, data from 2005 for a multisite pediatric study group revealed that 13% of patients younger than 18 years of age were on a TDF-containing regimen (R.M. Rutstein, personal communication, 2006). TDF is a structural analogue of cidofovir and adefovir, both of which have been associated with significant renal dysfunction.^{1,2} Initial adult clinical trials of TDF yielded no episodes of renal failure or significant (grade 3 or 4) increases in serum creatinine concentration,^{3,4} and a recent review of adult expanded access and postmarketing data indicated an overall low rate (0.5%) of renal serious adverse events.⁵ However, recent cohort studies have demonstrated decreases in creatinine clearance

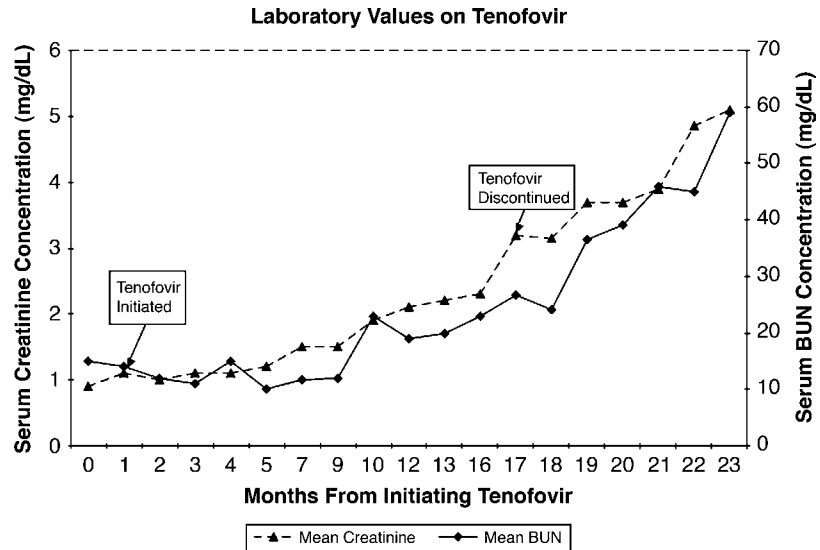
(CrCl) and glomerular filtration rate (GFR) for adult patients on TDF-containing regimens.^{6,7} Several reports have also described TDF-associated renal failure in adults, most often presenting as proximal tubular dysfunction with or without a Fanconi-like syndrome.⁸⁻¹⁰

TDF-associated nephrotoxicity may occur as a consequence of multiple drug interactions. The drug is primarily cleared through renal excretion, entering the basal membrane of the tubule cell via the human organic anion transporter 1 (hOAT1) and exiting the apical cellular membrane through the multi-drug-resistance transporter 4 (MRP 4).¹¹ Drug interactions at the cellular level may be responsible for the nephrotoxic potential of TDF. Most reported cases of TDF-associated renal failure have occurred in patients receiving concomitant treatment with the protease inhibitor ritonavir (RTV).¹⁰ TDF clearance is slower in subjects receiving lopinavir/ritonavir (LPV/RTV), which may lead to accumulation of toxic drug levels within tubular cells.¹² Didanosine (ddI), a nucleoside reverse transcriptase inhibitor (NRTI), has also been associated with an increased risk of nephrotoxicity with TDF due

Divisions of ¹Special Immunology, ²General Pediatrics, ³Infectious Diseases, and ⁴Nephrology, The Children's Hospital of Philadelphia, Philadelphia, Pennsylvania.

⁵Centers for Clinical Epidemiology and Biostatistics, and ⁶AIDS Research University of Pennsylvania School of Medicine, Philadelphia, Pennsylvania.

FIG. 1. Laboratory values for tenofovir.



both to its renal excretion as well as possible competition for hOAT1.⁹

We report two presentations of clinically significant TDF-associated nephrotoxicity in adolescent patients receiving TDF along with LPV/RTV.

Patient 1

A 16-year-old African American male with perinatally acquired HIV and a history of tetralogy of Fallot presented with an abrupt rise in serum creatinine concentration while receiving a TDF-containing HAART regimen. The patient's Center of Disease (CDC) classification was C-3 secondary to an AIDS diagnosis at age 5 for recurrent bacterial infections. However, he had been clinically stable on HAART for many years. The change to a TDF-based regimen was prompted by the patient's significant emotional distress secondary to severe facial lipodystrophy. At the time of the regimen change, to tenofovir/emtricitabine (Truvada, Gilead Sciences, Foster City, CA) 300 mg/200 mg once daily and lopinavir/ritonavir (Kaletra, Abbott Laboratories, Abbott Park, IL) 133.3 mg/33.3 mg three tablets twice daily, the patient's plasma viral RNA level had been undetectable (<75 copies per milliliter by HIV RNA polymerase chain reacton [PCR]) for more than 1 year. His absolute CD4⁺ cell count and percentage were 314 cells/mm³ and 21%. The patient had been adopted in infancy and family history was unknown. He smoked one half-pack of cigarettes daily and denied other illicit substance use. At initiation of TDF, the patient was normotensive and not anemic.

His baseline serum creatinine concentration at initiation of TDF was 0.9 mg/dL, with an estimated CrCl of 121 mL/min. Five months after initiating TDF, the patient's serum creatinine concentration began to slowly rise (Fig. 1), reaching a level of 2.0 mg/dL (estimated CrCl: 56.5 mL/min) 1 year after initiation of TDF. While discontinuing the regimen was discussed at the time, TDF-based therapy was continued due to the limited treatment options available to this patient with multi-drug-resistant HIV and the achievement of virologic suppression on TDF.

Seventeen months after initiation of TDF, the patient's serum creatinine concentration abruptly rose to 3.2 mg/dL

(CrCl: 35.9) from a level of 2.3 mg/dL the previous month. His blood pressure was 116/70 mm Hg. At this time all antiretroviral medications were discontinued. A urinalysis revealed greater than 3000 mg/dL proteinuria. A renal ultrasound revealed markedly echogenic kidneys with a lack of cortico-medullary differentiation. The overall appearance was not consistent with HIV nephropathy because the kidneys were not enlarged. A renal biopsy was not obtained, as the results would not have altered the treatment plan. On the basis of clinical presentation, laboratory values, and ultrasound results, the patient was diagnosed with chronic kidney disease stage 4 secondary to nephrotoxic medications and/or HIV nephropathy.

After discontinuation of TDF, the patient's renal function failed to improve. He developed hypertension and anemia 3 months later. His serum creatinine concentration has continued to rise, prompting initiation of hemodialysis. He is currently undergoing evaluation for renal transplantation.

Patient 2

A 16-year-old African American male with perinatally acquired HIV presented with chronic knee pain and limp. He was found to have rickets with hypophosphatemia while on a TDF-based HAART regimen. The patient was started on tenofovir/emtricitabine (Truvada) 300 mg/200 mg once daily and lopinavir/ritonavir (Kaletra) 133.3 mg/33.3 mg three tablets twice daily after poor adherence to his previous regimen. His CDC classification was B-2 secondary to lymphocytic interstitial pneumonitis at age 3. His family history was unknown. The patient was a nonsmoker, and denied other illicit substance use. At the time of the regimen change, the patient's plasma viral RNA level was 170 copies per milliliter. His absolute CD4⁺ cell count and percentage were 895 cells/mm³ and 55%. The patient was not anemic. His blood pressure was 120/54 mmHg. Shortly after initiating TDF-based HAART, the patient transferred care to another provider due to transportation issues.

The patient developed knee pain and difficulty walking 2 years after starting TDF, and returned to our clinic for a second opinion. On physical examination, he had bilateral genu

valgum, with no swelling or decrease in range of motion. A dual-energy x-ray absorptiometry (DEXA) scan revealed severely reduced lumbar bone mineral density (BMD), with a z score of -3.4 standard deviation (SD). Plain film radiographs of the knees showed rickets with abnormal physes and metaphyses. Serum laboratory values were notable for hypophosphatemia (2.3 mg/dL), hypouricemia (1.8 mg/dL), normal creatinine concentration (1.0 mg/dL, estimated GFR: 104 mL/min), and increased alkaline phosphatase (1438 mg/dL). Serum parathyroid hormone, calcium, bicarbonate, 25-hydroxy vitamin D, and 1,25-vitamin D were within normal limits. Urine studies revealed a slightly increased to creatinine ratio of 0.9. The β_2 -microglobulin (B2MG) concentration (49,244 μ g/dL) and B2MG/creatinine ratio (96,557 μ g/g) were markedly elevated, fractional tubular reabsorption of phosphate was decreased (76%), and he had glucosuria, indicating tubular damage. Blood pressures and hemoglobin were normal. The patient was diagnosed with rickets caused by phosphate wasting with evidence of renal and tubular injury, most likely secondary to TDF-associated nephrotoxicity. Three months later his serum creatinine had increased to 1.3 mg/dL, serum phosphorus remained low at 2.1 mg/dL, and serum alkaline phosphatase had increased to 1988 U/L. He admitted that he was not adhering to the phosphate and calcitriol treatment.

Discussion

While numerous cases of TDF-associated renal dysfunction have been described in adults, few pediatric cases have been reported, all of which have been reversible acute renal failure.^{13,14} Our cases differ significantly from the previous cases in presentation and course of illness.

Our first patient represents a probable case of TDF-associated nephrotoxicity, presenting as a proximal tubular protein-wasting nephropathy. The structural damage evident on ultrasound raises the possibility of preexisting renal disease. However, the normal urinalysis 3 months after beginning TDF therapy suggests that the patient's proteinuria developed in the context of TDF use.

The differential diagnosis of renal failure in HIV-infected patients includes HIV-associated nephropathy (HIVAN), membranoproliferative glomerulonephritis and other immune complex glomerulonephritides, drug-induced renal disease secondary to direct nephrotoxicity or acute interstitial nephritis, as well as the myriad of other causes affecting the general population.¹⁵ HIVAN is the most common cause of renal insufficiency in patients with HIV, disproportionately affecting patients of African descent. The typical presentation for HIVAN involves rapidly rising creatinine levels accompanied by nephrotic-range proteinuria.^{15,16}

While our patient's history suggests some degree of underlying renal disease, his presentation is atypical for HIVAN. Most notably, HIV nephropathy generally occurs at CD4 cell counts less than 200 cells/mm³, and high viral loads.¹⁷ With the exception of one value of 184 cells/mm³ 3 months after initiating this regimen, our patient's CD4 cell count has remained above 300 cells/mm³ and greater than 20% for the past 10 years. Similarly his level of viremia has remained largely undetectable for 7 years. In a setting of near-normal CD4 counts, suppressed viral load, normal kidney size, and normal urinalysis until initiation of TDF, we believe that HI-

VAN is unlikely as the sole etiology for his irreversible renal failure.

A point of particular importance is the apparent irreversibility of the renal damage. In adult reports, 81%–94% of patients returned to baseline creatinine values upon discontinuation of TDF.^{6,8,9} All previously reported pediatric cases returned to baseline renal function.^{13,14} In our patient, the nephropathy has failed to resolve over the 2-year period since discontinuation of TDF, necessitating dialysis and possible kidney transplantation.

TDF remains an off-label medication for pediatric patients. However, it is a vital component of salvage regimens for heavily treatment-experienced children and adolescents.¹⁸ In this particular patient, the choice to use TDF was based on genotypic assay of his multi-drug-resistant virus, as well as the lipodystrophic adverse effects of his prior regimen. Early safety and efficacy trials found TDF to be associated both with less lipodystrophy than other NRTI-based regimens and with an increased genetic barrier to resistance.³ These qualities make it an excellent choice for salvage therapy in patients with complicated HAART treatment histories.

Our second patient's presentation of rickets with hypophosphatemia has not been previously reported in the literature. Although clinically significant changes in bone mineral density (BMD) in pediatric patients have been associated with TDF use, this is the first report of TDF-associated rickets.^{18,19} The severity of our patient's loss of BMD underscore the need for regular monitoring of BMD in pediatric patients receiving TDF.

Adult and pediatric trials have reported a significant association between hypophosphatemia and TDF-based HAART.^{20,21} Renal reabsorption of phosphate occurs at the proximal tubule, the segment of the nephron most commonly affected in TDF-associated nephrotoxicity. Our patient's presentation of rickets with proximal renal tubular dysfunction as evidenced by hypophosphatemia, hypouricemia, phosphate wasting, glucosuria, and high urinary concentrations of B2MG but normal PTH, and vitamin D levels suggest that a drug-induced proximal tubulopathy is the likely etiology. The patient's high urinary levels of B2MG also implicate TDF as the likely causative agent. Previous studies have found an association between high B2MG levels and TDF usage in HIV-infected adults and children, suggesting that B2MG may be a sensitive marker of TDF-associated renal dysfunction.^{21,22}

These two cases emphasize the need for safe and effective antiretroviral agents for use in pediatric salvage therapy. While TDF is a preferred agent for initial therapy for HIV-infected adults, it has not been approved for use in patients less than 18 years of age. Safety and pharmacokinetic data are limited for the younger age group with a paucity of information about the incidence of TDF-associated nephrotoxicity in this population. For patients on a TDF-based regimen in combination with RTV or ddI, particular attention must be paid to ongoing renal function, and drug doses should be tailored to minimize risk of toxicity while still achieving optimal virologic control. Finally, baseline and ongoing monitoring of bone mineral density with DEXA scanning may help identify children at risk for TDF-associated rickets or osteopenia. Further studies are warranted to better characterize the renal safety profile of TDF in children, and to guide ongoing management of children on TDF-based salvage therapy.

Author Disclosure Statement

No competing financial interests exist.

References

- Vandercam B, Moreau M, Goffin E, Marot JC, Cosyns JP, Jadoul M. Cidofovir-induced end-stage renal failure. *Clin Infect Dis* 1999;29:948–949.
- Fisher EJ, Chaloner K, Cohn DL, et al. The safety and efficacy of adefovir dipivoxil in patients with advanced HIV disease: A randomized, placebo-controlled trial. *AIDS* 2001;15:1695–1700.
- Gallant JE, Staszewski S, Pozniak AL, et al. Efficacy and safety of tenofovir DF vs stavudine in combination therapy in antiretroviral-naïve patients: A 3-year randomized trial. *JAMA* 2004;292:191–201.
- Antoniou T, Raboud J, Chirhin S, et al. Incidence of and risk factors for tenofovir-induced nephrotoxicity: A retrospective cohort study. *HIV Med* 2005;6(4):284–90.
- Nelson MR, Katlama C, Montaner JS, et al. The safety of tenofovir disoproxil fumarate for the treatment of HIV infection in adults: The first 4 years. *AIDS* 2007;21:1273–1281.
- Winston A, Amin J, Mallon P, et al. Minor changes in calculated creatinine clearance and anion-gap are associated with tenofovir disoproxil fumarate-containing highly active antiretroviral therapy. *HIV Med* 2006;7:105–111.
- Fux CA, Simcock M, Wolbers M, et al. Tenofovir use is associated with a reduction in calculated glomerular filtration rates in the Swiss HIV Cohort Study. *Antivir Ther* 2007;12:1165–1173.
- Malik A, Abraham P, Malik N. Acute renal failure and Fanconi syndrome in an AIDS patient on tenofovir treatment—Case report and review of literature. *J Infect* 2005;51:E61–65.
- Zimmermann AE, Pizzoferrato T, Bedford J, Morris A, Hoffman R, Braden G. Tenofovir-associated acute and chronic kidney disease: A case of multiple drug interactions. *Clin Infect Dis* 2006;42:283–290.
- Gupta SK. Tenofovir-associated Fanconi syndrome: Review of the FDA adverse event reporting system. *AIDS Patient Care STDs* 2008;22:99–103.
- Imaoka T, Kusuhara H, Adachi M, Schuetz JD, Takeuchi K, Sugiyama Y. Functional involvement of multidrug resistance-associated protein 4 (MRP4/ABCC4) in the renal elimination of the antiviral drugs adefovir and tenofovir. *Mol Pharmacol* 2007;71:619–627.
- Kiser JJ, Carten ML, Aquilante CL, et al. The effect of lopinavir/ritonavir on the renal clearance of tenofovir in HIV-infected patients. *Clin Pharmacol Ther* 2008;83:265–272.
- Hussain S, Khayat A, Tolaymat A, Rathore MH. Nephrotoxicity in a child with perinatal HIV on tenofovir, didanosine and lopinavir/ritonavir. *Pediatr Nephrol* 2006;21:1034–1036.
- Hawkins S, Ball C. Adverse events experienced by three children taking tenofovir and didanosine in combination. *HIV Med* 2007;8:411.
- Fine DM, Atta MG. Kidney disease in the HIV-infected patient. *AIDS Patient Care STDs* 2007;21:813–824.
- Gupta SK, Eustace JA, Winston JA, et al. Guidelines for the management of chronic kidney disease in HIV-infected patients: Recommendations of the HIV Medicine Association of the Infectious Diseases Society of America. *Clin Infect Dis* 2005;40:1559–1585.
- Roling J, Schmid H, Fischeder M, Draenert R, Goebel FD. HIV-associated renal diseases and highly active antiretroviral therapy-induced nephropathy. *Clin Infect Dis* 2006;42:1488–1495.
- Gafni RI, Hazra R, Reynolds JC, et al. Tenofovir disoproxil fumarate and an optimized background regimen of antiretroviral agents as salvage therapy: Impact on bone mineral density in HIV-infected children. *Pediatrics* 2006;118:e711–718.
- Purdy JB, Gafni RI, Reynolds JC, Zeichner S, Hazra R. Decreased bone mineral density with off-label use of tenofovir in children and adolescents infected with human immunodeficiency virus. *J Pediatr* 2008;152:582–584.
- Fux CA, Christen A, Zraggen S, Mohaupt MG, Furrer H. Effect of tenofovir on renal glomerular and tubular function. *AIDS* 2007;21:1483–1485.
- Papaleo A, Warszawski J, Salomon R, et al. Increased beta-2 microglobulinuria in human immunodeficiency virus-1-infected children and adolescents treated with tenofovir. *Pediatr Infect Dis J* 2007;26:949–951.
- Gatanaga H, Tachikawa N, Kikuchi Y, et al. Urinary beta2-microglobulin as a possible sensitive marker for renal injury caused by tenofovir disoproxil fumarate. *AIDS Res Hum Retroviruses* 2006;22:744–748.

Address reprint requests to:

Richard M. Rutstein, M.D.

Division of General Pediatrics

Children's Hospital of Philadelphia

34th and Civic Center Boulevard, Room 2419

Philadelphia, PA 19104

E-mail: RUTSTEIN@email.chop.edu