



5-1-2008

# Operating in the Dark: A Night-Vision System for Surgery in Retinas Susceptible to Light Damage

András M. Komáromy


*University of Pennsylvania*, komaromy@vet.upenn.edu

Gregory M. Acland

Gustavo D. Aguirre

*University of Pennsylvania*, gda@vet.upenn.edu

Follow this and additional works at: [https://repository.upenn.edu/vet\\_papers](https://repository.upenn.edu/vet_papers)

 Part of the [Eye Diseases Commons](#), [Ophthalmology Commons](#), [Optometry Commons](#), and the [Veterinary Medicine Commons](#)

---

## Recommended Citation

Komáromy, A. M., Acland, G. M., & Aguirre, G. D. (2008). Operating in the Dark: A Night-Vision System for Surgery in Retinas Susceptible to Light Damage. *Archives of Ophthalmology*, 126 (5), 714-717. <http://dx.doi.org/10.1001/archophth.126.5.714>

*Archives of Ophthalmology* is now called *JAMA Ophthalmology*.

This paper is posted at Scholarly Commons. [https://repository.upenn.edu/vet\\_papers/106](https://repository.upenn.edu/vet_papers/106)

For more information, please contact [repository@pobox.upenn.edu](mailto:repository@pobox.upenn.edu).

---

# Operating in the Dark: A Night-Vision System for Surgery in Retinas Susceptible to Light Damage

## Abstract

A standard operating microscope was modified with a bandpass infrared filter in the light path and infrared image intensifiers for each of the 2 eyepieces. We evaluated this system for subretinal injections in normal control dogs and those with a mutation in the rhodopsin gene. Rhodopsin-mutant dogs are a model for human autosomal dominant retinitis pigmentosa, and their retinas degenerate faster when exposed to modest light levels as used in routine clinical examinations. We showed that the mutant retinas developed severe generalized degeneration when exposed to the standard operating microscope light but not the infrared light. The modified operating microscope provided an excellent view of the ocular fundus under infrared illumination and allowed us to perform subretinal injections in the retinas of the rhodopsin-mutant dogs without any subsequent light-induced retinal degeneration.

The first description of light-induced retinal damage showed that exposure of albino rats to visible light intensities ordinarily encountered in the laboratory led to irreversible retinal damage.<sup>1</sup> This finding soon was extended to other species, including rabbits<sup>2</sup> and monkeys.<sup>3</sup> Studies in animal models of retinal degeneration (eg, Royal College of Surgeons rats, *ABCA4*-mutant mice, or rhodopsin-mutant mice and dogs) have emphasized the interplay between the gene mutation and environmental light and demonstrated acceleration of the disease process by light.<sup>4-10</sup> The effect of environmental light on disease severity in humans with retinitis pigmentosa has been suggested by case reports,<sup>11</sup> although definitive proof is lacking. However, patients with class B1 rhodopsin mutations may be at risk of accelerated vision loss with increased light exposures because they have defects in dark (bleaching) adaptation similar to those found in rhodopsin-mutant dogs that demonstrate a high susceptibility to retinal light damage.<sup>8,12,13</sup>

Many of the emerging therapies for retinal degeneration require the intraocular placement of a reagent or device with the use of an operating microscope.<sup>14,15</sup> The damaging effect of the microscope light on the normal retina, even with the appropriate filtering of UV light, has been described previously,<sup>16,17</sup> and there is increased emphasis on reducing the intensity and duration of the exposures. Herein, we describe a modification of an operating microscope with an infrared bandpass filter and a night-vision system to perform surgical interventions in the posterior segment of the eyes of rhodopsin-mutant dogs without the risk of photochemical retinal damage. This modification prevents acceleration of the photoreceptor degeneration that occurs with exposure to modest light levels as used in routine clinical practice.<sup>8</sup> If humans with retinitis pigmentosa are shown to have similar light damage susceptibility, this microscope modification could be considered for surgical procedures such as the subretinal application of gene therapy vectors.

## Disciplines

Eye Diseases | Ophthalmology | Optometry | Veterinary Medicine

## Comments

*Archives of Ophthalmology* is now called *JAMA Ophthalmology*.

Published in final edited form as:

*Arch Ophthalmol.* 2008 May ; 126(5): 714–717. doi:10.1001/archophth.126.5.714.

## Operating in the Dark: A Night Vision System for Surgery in Retinas Susceptible to Light Damage

András M. Komáromy, DrMedVet, PhD, Gregory M. Acland, BVSc, and Gustavo D. Aguirre, VMD, PhD

Author Affiliations: School of Veterinary Medicine, University of Pennsylvania, Philadelphia, PA (Drs. Komáromy and Aguirre), and Baker Institute, Cornell University, Ithaca, NY (Dr. Acland).

### Abstract

A standard Zeiss OPMI 6 operating microscope was modified with a bandpass infrared filter in the light path, and infrared image intensifiers for each of the two eye pieces. The aim of the study was to evaluate this system for subretinal injections in normal control and *rhodopsin* mutant dogs. These dogs are a model for human autosomal dominant retinitis pigmentosa (adRP), and their retinas degenerate faster when exposed to modest light levels as used in routine clinical examinations. We showed that the mutant retinas developed severe generalized degeneration when exposed to the standard operating microscope light, but not the infrared light. The modified operating microscope provided excellent view of the ocular fundus under infrared illumination, and allowed us to perform subretinal injections in the *rhodopsin* mutant dog retinas without any subsequent light-induced retinal degeneration.

### INTRODUCTION

The first description of light-induced retinal damage showed that exposure of albino rats to visible light intensities ordinarily encountered in the laboratory led to irreversible retinal damage.<sup>1</sup> This finding soon was extended to other species including rabbits<sup>2</sup> and monkeys.<sup>3</sup> Studies in animal models of retinal degeneration, e.g. RCS rats, *ABCA4* mutant mice, or *rhodopsin* mutant mice and dogs, have emphasized the interplay between the gene mutation and environmental light, and demonstrated acceleration of the disease process by light.<sup>4–10</sup> The effect of environmental light on disease severity in human patients with retinitis pigmentosa (RP) has been suggested by case reports,<sup>11</sup> although definitive proof is lacking. However, patients with Class B1 *rhodopsin* mutations may be at risk for accelerated vision loss with increased light exposures as they have similar defects in dark (bleaching) adaptation as *rhodopsin* mutant dogs that demonstrate a high susceptibility to retinal light damage.<sup>8,12,13</sup>

Many of the emerging therapies for retinal degenerations require the intraocular placement of a reagent or device using an operating microscope.<sup>14,15</sup> The damaging effect of the microscope light on the normal retina, even with the appropriate filtering of ultraviolet light, has been described,<sup>16,17</sup> and there is increased emphasis in reducing both the intensity and duration of the exposures. Herein, we describe a modification of an operating microscope with an infrared bandpass filter and a night vision system to carry out surgical interventions in the posterior segment of the eyes of *rhodopsin* mutant dogs without the risk of photochemical

---

Correspondence: András M. Komáromy, DrMedVet, PhD, Department of Clinical Studies, School of Veterinary Medicine, University of Pennsylvania, 3900 Delancey Street, Philadelphia, PA 19104, 215.573.2695 [Office], 215.573.2162 [Fax], komaromy@vet.upenn.edu.

Financial Disclosure: None

retinal damage. This modification prevents acceleration of the photoreceptor degeneration that occurs with exposure to modest light levels as used in routine clinical practice.<sup>8</sup> If human patients are shown to have similar light damage susceptibility, this microscope modification could be considered for surgical procedures such as the subretinal application of gene therapy vectors.

## METHODS

A Zeiss OPMI 6 operating microscope equipped with a standard, manufacturer-provided 100-W tungsten halogen low voltage lamp (HLX 64627; Osram Sylvania, Danvers, MA) and 475-nm long pass filter (GG475; Schott, Mainz, Germany) was used for the subretinal injection studies. For the surgeries under dark conditions, an infrared bandpass filter (RT-830; Hoya Corporation USA, San Jose, CA) with a central wavelength of 830 nm and a full width at half maximum of 260 nm was placed in the microscope's light path using an already existing slider on the OPMI 6 (Figure 1). Monocular infrared image intensifiers were attached to each of the two eyepieces with custom-built adapters for the Zeiss OPMI 6 microscope (Owl Nitemare 3<sup>rd</sup> Generation; B.E. Meyers & Co, Inc., Redmond, WA); the infrared image intensifiers had a resolution of 56 line pairs per millimeter (Figure 1).

Bilateral subretinal injections of saline were performed in normal control and *rhodopsin* mutant dogs. We recently identified this naturally occurring canine model of autosomal dominant RP (adRP), and determined the cause to be a T4R missense mutation in the *rhodopsin* gene.<sup>8,13</sup> For this study, the dogs were kept under the same standard light conditions that they were exposed to since birth, i.e. 12 hours on / 12 hours off light/dark cycles with an irradiance during the light phase between 0.003 and 0.015 mW/cm<sup>2</sup>; the irradiance range depended on the dog's location in the kennel. These environmental light conditions were used because they do not cause retinal degeneration within the first year of life in this model provided no ophthalmic examination procedures are performed.<sup>8</sup> All procedures were done in accordance with the ARVO Statement for the Use of Animals in Ophthalmic and Vision Research.

One eye of each dog was injected under standard light conditions while the contralateral eye was injected under dark conditions with the infrared bandpass filter and infrared image intensifiers. While one eye was operated, the fellow eye was covered with a black, non-transparent plastic occluder. Our protocol for subretinal injections in dogs has previously been described.<sup>18</sup> The induction of general anesthesia and the preparation of the eyes were done under regular ambient room lights (irradiance = 0.14 mW/cm<sup>2</sup>).<sup>a</sup> As soon as the operating microscope with its light source was brought into position, the overhead room lights were turned off, and only a red darkroom safelight (Kodak 1A filter) was kept on in a distant corner of the room. As a reference, the irradiance measured at the plane of the cornea was 36 mW/cm<sup>2</sup> with the standard microscope light, and 6.1 mW/cm<sup>2</sup> when the infrared bandpass filter was used (in both cases brightness setting #5 on the OPMI 6). In terms of illuminance, these irradiances represent 6,670 lux without filter, and 0.18 lux with the infrared bandpass filter.

For the subretinal injections, a Chalam Direct Flat SSV® surgical lens (Volk; Mentor, OH) was placed on the cornea for visualization of the ocular fundus. The globe was penetrated with the 25-G needle of a RetinaJect™ subretinal injection device (SurModics, Inc., Eden Prairie, MN<sup>18</sup>) 6 mm posterior to the limbus, and the tip of the needle was brought into proximity of the retinal surface. Next, a 39-G cannula was extended from the tip of the 25-G needle and brought tangentially into contact with the retina, followed by the rapid injection of 150 µl of saline. Successful injection was recognized by the formation of a subretinal bleb in the area

---

<sup>a</sup>The ambient light intensities in this report were slightly higher than ambient light measured in a vitreoretinal surgery suite in a human medical center (0.07 mW/cm<sup>2</sup>).

centralis region of the fundus which is comparable to the human macular region. The total time period during which the eyes were exposed to the microscope light was between 8–10 minutes, and was comparable for both standard and infrared illumination surgical procedures.

In order to demonstrate the effect of a range of light intensities, that may be used for surgical procedures other than subretinal injections, the anterior and posterior ocular segments of anesthetized *rhodopsin* mutant dogs were visualized for 10 minutes with the OPMI6 using irradiances between 0.74 and 17.6 mW/cm<sup>2</sup> (brightness settings between #3.5 and #4.5 on the OPMI 6) without performing surgery.

Following surgery or light exposure procedures, the dogs were kept for 15 days under the same light conditions as prior to surgery. No additional ophthalmic procedures were used to monitor the *rhodopsin* mutant dogs in order to prevent retinal damage unrelated to the surgery. After 15 days, the dogs were euthanatized and the eyes were fixed in Bouin's solution for routine processing and embedding in paraffin. Globes were oriented so that sections were made through the center of the subretinal injection sites. The tissue sections were stained with hematoxylin and eosin (H&E).

## RESULTS

The combination of the infrared bandpass filter and the infrared image intensifiers provided good illumination and sufficient resolution to perform subretinal injections. The estimated maximal resolution decreased from ~10 µm with the standard light condition to ~20 µm with the use of the infrared image intensifiers; this small loss in resolution did not affect the surgical performance. The main difference to the standard illumination was that the image provided by the night vision system appeared in shades of green rather than in colors. This did not create a challenge as the available illumination and resolution allowed the visualization of important anatomic structures and landmarks.

Morphologic assessment of the normal control retinas showed that the injected and non-injected areas were normal for both the standard and infrared light conditions (data not shown). In contrast, the *rhodopsin* mutant retinas operated under standard light conditions were severely and uniformly degenerate in both injected and non-injected areas. There was complete loss of photoreceptors, almost unrecognizable outer nuclear layers, and loss of many retinal pigment epithelial (RPE) cells (Figures 2A – 2D). There were no obvious differences in the degree of retinal degeneration between the tapetal (RPE not pigmented, Figures 2A & 2B) and the non-tapetal regions (RPE pigmented, Figures 2C & 2D). The retinas that were injected using the infrared night vision system and infrared light were normal both inside (Figures 2E & 2F) and outside (data not shown) the subretinal injection sites.

All the light settings that were evaluated on the OPMI6 (#3.5 – 5) lead to the same severe degeneration of the *rhodopsin* mutant retinas. The same damage was found with and without the use of a surgical lens. Differences between the brightness settings were seen in the size of the estimated areas of photoreceptor loss (~37% for setting #3.5, ~51% for setting #4, and 100% for settings #4.5 and #5) with the central retinas always being most severely affected. We compared these brightness settings with a more current operating microscope model, the Zeiss VISU160, that uses the same tungsten halogen low voltage lamp (Figure 3). The irradiance values for the VISU160 brightness settings commonly used by cataract surgeons (settings #0.3 – 0.6) are within the irradiances evaluated in this study which caused light induced retinal degeneration.

## COMMENT

The potential contribution of environmental light to the modification of inherited retinal degenerations in humans has been suggested,<sup>11</sup> and supported by more recent experimental studies in several animal models of retinal degeneration.<sup>4–10</sup> We now show that even a short ophthalmic surgical procedure lasting less than 10 minutes and using the standard 475-nm long pass filter (GG 475) provided by the manufacturer with the Zeiss OPMI 6 results in severe degeneration of the *rhodopsin* mutant canine retina.

These results confirm our previous work showing a very rapid retinal degeneration in the *rhodopsin* mutant dog retinas following clinical light exposures such as used in routine fundus photography.<sup>8</sup> In contrast to the rather localized damage found with fundus photography, however, the standard lights of the operating microscope caused wide-field degeneration extending beyond the subretinal injection site. This could result from the wider distribution of the incident light on the retina by the surgical lens and/or the longer exposure times (minutes vs. microseconds). A similar susceptibility to light damage during ophthalmic procedures has been identified in the T17M *rhodopsin* transgenic mouse.<sup>10</sup> The T4R and T17M mutations in dogs and mice, respectively, alter the first and second opsin consensus glycosylation sites,<sup>19</sup> and possibly render the mutant protein-chromophore combination exquisitely susceptible to damage from low levels of light exposure.

Previous reports, and the manufacturer's specifications, state that the infrared output represents a significant portion of the total irradiation produced by the tungsten halogen lamp.<sup>20</sup> We took advantage of this infrared irradiation by placing an infrared bandpass filter in the operating microscope light path; this reduced the irradiance by a factor of ~6, and the illuminance by a factor of ~37,000, and prevented the light-associated degeneration of the *rhodopsin* mutant retina. By almost completely eliminating light within and below the visual pigment absorption spectrum, we prevented the risk of photochemical retinal damage.<sup>21</sup>

The use of a night vision system allowed the proper visualization of the surgical field, including the fundus, to successfully perform subretinal injections. Although the minimal loss of resolution did not affect the surgical performance, infrared image intensifiers with higher resolution of up to 72 line pairs per millimeter (instead of the 56 line pairs per millimeter used in this study) are currently available and could be considered for use. Recently, a similarly modified near-infrared Zeiss operating microscope with head-mounted displays was presented for lightless cataract surgery.<sup>22</sup> The author's purpose was to prevent light-associated complications of cataract surgery, i.e. photochemical retinal damage.<sup>22</sup> That system could be equally applicable for surgical manipulations in patients with retinal diseases that would render them susceptible to light damage.

Many of the newly emerging treatment options for retinal degenerations require surgical interventions that utilize an operating microscope. In experimental animals with increased susceptibility to retinal light damage,<sup>8,10</sup> and possibly in human patients with homologous disorders,<sup>12</sup> minimizing light exposures during retinal or other ophthalmic surgical procedures may be necessary. The modification of a standard operating microscope with infrared bandpass filters and infrared night vision system provides an approach to make such surgical procedures safer in those human patients where the disease phenotype may be modified by light exposures used in routine clinical practice.

## ACKNOWLEDGMENTS

Funding/Support: This study was supported by the NIH Grants EY013132, EY017549, K12 EY015398, EY006855, P30 EY001583, the Foundation Fighting Blindness, and the ONCE International Prize for R&D in Biomedicine and New Technologies for the Blind. The authors thank Amanda Nickle, Gerri Antonini, Alice Eidsen, Tracy Greiner,


Michael Suplick (machine shop), and Mary Leonard (illustrations) for technical support. The authors appreciate the assistance, helpful comments and suggestions of Dr. Artur Cideciyan (Scheie Eye Institute, University of Pennsylvania). Special thanks go to Howard Schwartz (Opto-Systems, Inc., Newtown, PA) for his advice and guidance. The authors have full access to all the data in the study and take responsibility for the integrity of the data and the accuracy of the data analysis.

## REFERENCES

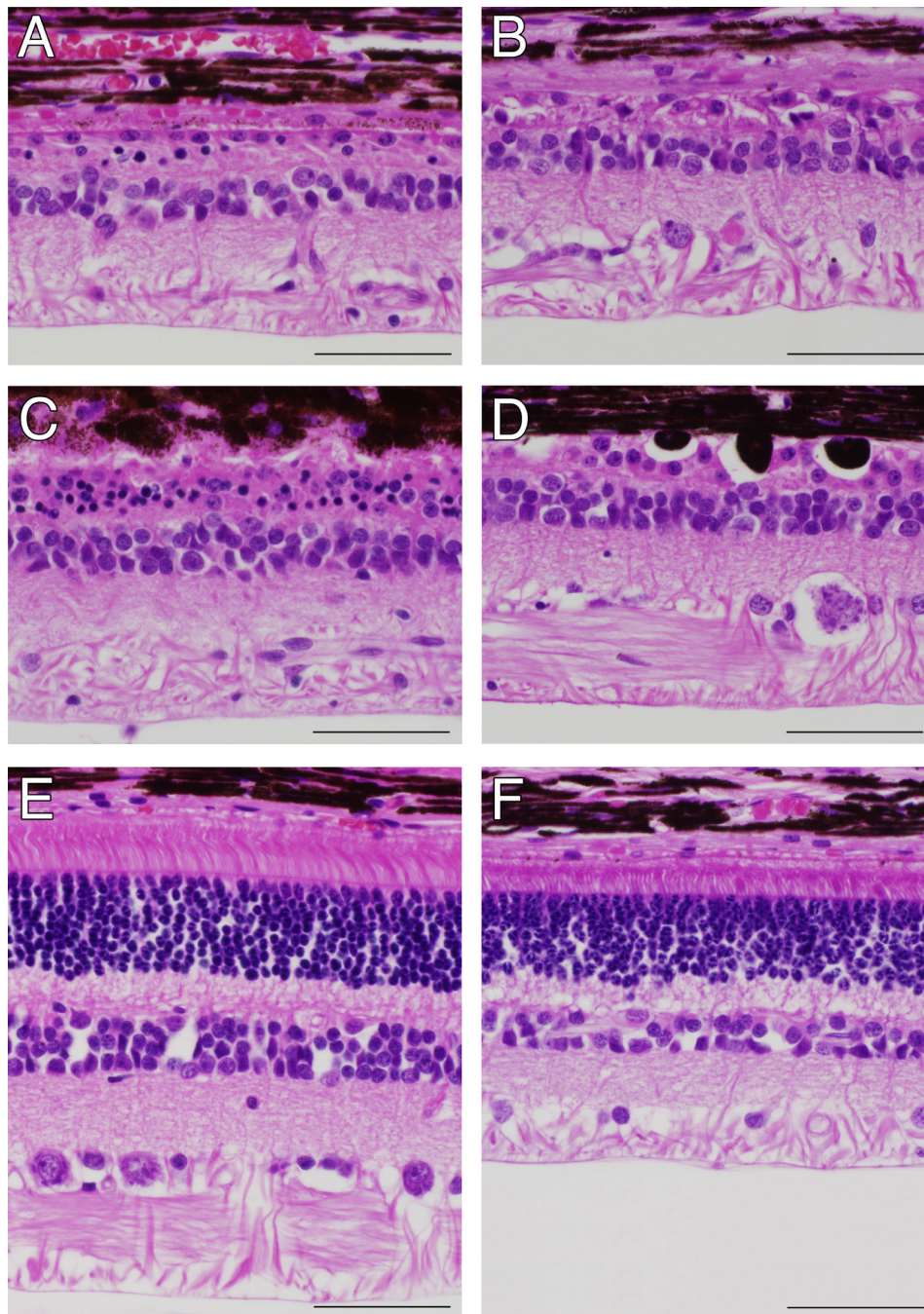
1. Noell WK, Walker VS, Kang BS, Berman S. Retinal damage by light in rats. *Invest Ophthalmol Vis Sci* 1966;5:450–473.
2. Lawwill T. Effects of prolonged exposure of rabbit retina to low-intensity light. *Invest Ophthalmol* 1973;12:45–51. [PubMed: 4691946]
3. Sykes SM, Robison WG, Waxler M, et al. Damage to the monkey retina by broad-spectrum fluorescent light. *Invest Ophthalmol Vis Sci* 1981;20:425–434. [PubMed: 7216664]
4. Organisciak DT, Darrow RM, Barsalou L, et al. Susceptibility to retinal light damage in transgenic rats with rhodopsin mutations. *Invest Ophthalmol Vis Sci* 2003;44:486–492. [PubMed: 12556372]
5. Organisciak DT, Li M, Darrow RM, Farber DB. Photoreceptor cell damage by light in young Royal College of Surgeons rats. *Curr Eye Res* 1999;19:188–196. [PubMed: 10420189]
6. Naash ML, Peachey NS, Li ZY, et al. Light-induced acceleration of photoreceptor degeneration in transgenic mice expressing mutant rhodopsin. *Invest Ophthalmol Vis Sci* 1996;37:775–782. [PubMed: 8603862]
7. Wang M, Lam TT, Tso MOM, et al. Expression of a mutant opsin gene increases the susceptibility of the retina to light damage. *Vis Neurosci* 1997;14:55–62. [PubMed: 9057268]
8. Cideciyan AV, Jacobson SG, Aleman TS, et al. *In vivo* dynamics of retinal injury and repair in the *rhodopsin* mutant dog model of human retinitis pigmentosa. *Proc Natl Acad Sci U S A* 2005;102:5233–5238. [PubMed: 15784735]
9. Cremers FP, Maugeri A, den Hollander AI, Hoyng CB. The expanding roles of *ABCA4* and *CRB1* in inherited blindness. *Novartis Found Symp* 2004;255:68–79. [PubMed: 14750597]
10. White DA, Hauswirth WW, Kaushal S, Lewin AS. Increased sensitivity to light damage in a mouse model of autosomal dominant retinal disease. *Invest Ophthalmol Vis Sci*. 2007accepted for publication
11. Heckenlively JR, Rodriguez JA, Daiger SP. Autosomal dominant sectoral retinitis pigmentosa. Two families with transversion mutation in codon 23 of rhodopsin. *Arch Ophthalmol* 1991;84–91. [PubMed: 1987955]
12. Cideciyan AV, Hood DC, Huang Y, et al. Disease sequence from mutant rhodopsin allele to rod and cone photoreceptor degeneration in man. *Proc Natl Acad Sci U S A* 1998;95:7103–7108. [PubMed: 9618546]
13. Kijas JW, Cideciyan AV, Aleman TS, et al. Naturally occurring *rhodopsin* mutation in the dog causes retinal dysfunction and degeneration mimicking human dominant retinitis pigmentosa. *Proc Natl Acad Sci U S A* 2002;99:6328–6333. [PubMed: 11972042]
14. Acland GM, Aguirre GD, Ray J, et al. Gene therapy restores vision in a canine model of childhood blindness. *Nat Genet* 2001;28:92–95. [PubMed: 11326284]
15. Sieving PA, Caruso RC, Tao W, et al. Ciliary neurotrophic factor (CNTF) for human retinal degeneration: phase I trial of CNTF delivered by encapsulated cell intraocular implants. *Proc Natl Acad Sci U S A* 2006;103:3896–3901. [PubMed: 16505355]
16. Michael R, Wegener A. Estimation of safe exposure time from an ophthalmic operating microscope with regard to ultraviolet radiation and blue-light hazards to the eye. *J Opt Soc Am A* 2004;21:1388–1392.
17. Robertson DM, McLaren JW. Photic retinopathy from the operating room microscope. Study with filters. *Arch Ophthalmol* 1989;107:373–375. [PubMed: 2923559]
18. Komáromy AM, Varner SE, de Juan E, et al. Application of a new subretinal injection device in the dog. *Cell Transplant* 2006;15:511–519. [PubMed: 17121162]
19. Zhu L, Jang GF, Jastrzebska B, et al. A naturally occurring mutation of the opsin gene (T4R) in dogs affects glycosylation and stability of the G protein-coupled receptor. *J Biol Chem* 2004;279:53828–53839. [PubMed: 15459196]

20. Michels M, Dawson WW, Feldman RB, et al. Infrared. An unseen and unnecessary hazard in ophthalmic devices. *Ophthalmology* 1987;94:143–148. [PubMed: 3574879]
21. Kremers JJM, van Norren D. Two classes of photochemical damage of the retina. *Lasers Light Ophthalmol* 1988;2:41–52.
22. Kim B-H. Lightless cataract surgery using a near-infrared operating microscope. *J Cataract Refract Surg* 2006;32:1683–1690. [PubMed: 17010868]



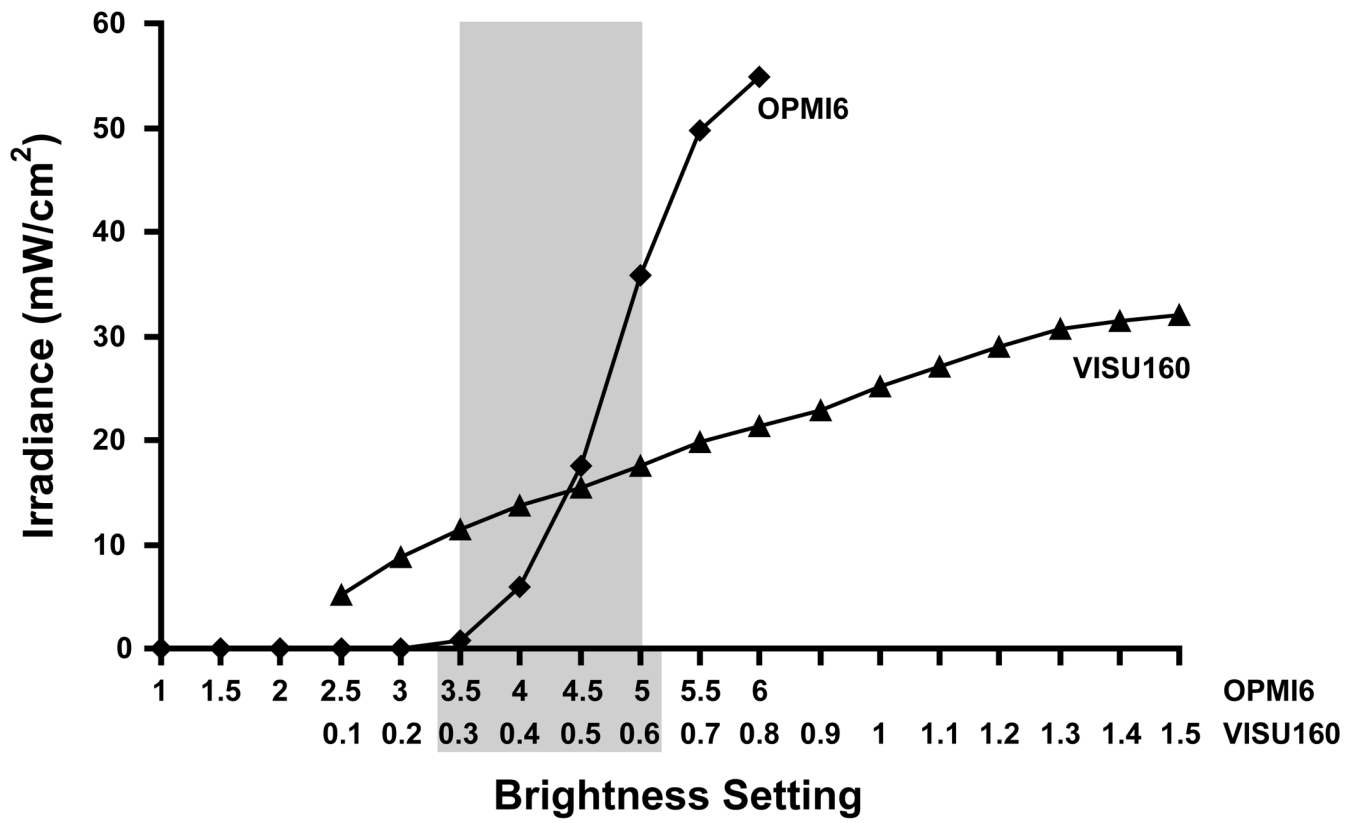


**Figure 1.**  
The Zeiss OPMI 6 operating microscope modified with the monocular Owl Nitemare night vision systems. The arrow points to the location of the slider housing the infrared bandpass filter.



**Figure 2.**

Photomicrographs showing *rhodopsin* mutant canine retinas 15 days after subretinal injection of saline. With the use of the standard operating microscope light, the retinas showed extensive outer retinal and RPE degeneration in both the injected (**A, B**) and non-injected areas (**C, D**) of different dogs. With the use of the night vision system and infrared light in the fellow eyes, the retinal morphology remained normal in the injected areas (**E, F**). Hematoxylin and eosin stain; calibration marker=50  $\mu$ m.



**Figure 3.** Comparison of brightness settings between the Zeiss OPMI6 and VISU160 operating microscopes. The gray area shows the range of commonly used VISU160 settings (0.3 – 0.6) that were overlapped with the OPMI6 settings evaluated in this study (3.5 – 5).