



11-1-2008

Cardiac Disorder in a Cat

Caryn A. Reynolds
University of Pennsylvania

Mark A. Oyama
University of Pennsylvania, maoyama@vet.upenn.edu

Sonya G. Gordon

Follow this and additional works at: https://repository.upenn.edu/vet_papers

 Part of the [Small or Companion Animal Medicine Commons](#)

Recommended Citation

Reynolds, C. A., Oyama, M. A., & Gordon, S. G. (2008). Cardiac Disorder in a Cat. *NAVC Clinician's Brief*, 6 57-58. Retrieved from https://repository.upenn.edu/vet_papers/4

This paper is posted at ScholarlyCommons. https://repository.upenn.edu/vet_papers/4
For more information, please contact repository@pobox.upenn.edu.

Cardiac Disorder in a Cat

Keywords

make your diagnosis, cardiology

Disciplines

Small or Companion Animal Medicine | Veterinary Medicine

Visit cliniciansbrief.com/subscribe to get your OWN FREE digital subscription to *Clinician's Brief*.

Caryn A. Reynolds, DVM, and Mark A. Oyama, DVM, Diplomate ACVIM (Cardiology), University of Pennsylvania
Sonya G. Gordon, DVM, DVSc, Diplomate ACVIM (Cardiology), Texas A&M University

Cardiac Disorder in a Cat

An 8-year-old castrated male domestic shorthair was presented for an annual wellness examination and vaccines.

History. A slight decrease in activity level of 2 months in duration was reported. No heart murmur had been detected on previous physical examinations.

Physical Examination. The cat was bright and alert, with a heart rate of 230 bpm and a respiratory rate of 32 breaths/min. A grade 3/6 left parasternal systolic heart murmur was detected. Respiratory sounds were normal. No other abnormalities were found.

Diagnostics. CBC, blood chemistry panel, total T_4 , and systemic blood pressure were within normal limits. To further evaluate the heart murmur, the cardiac biomarker NT-proBNP was measured and was 330 pmol/L (reference range, < 50 pmol/L).

continues



ASK YOURSELF ...

- What is NT-proBNP?
- What does an elevated NT-proBNP concentration mean?
- What does a normal NT-proBNP concentration mean?
- Does this cat have significant underlying heart disease?
- What further diagnostics should be performed?

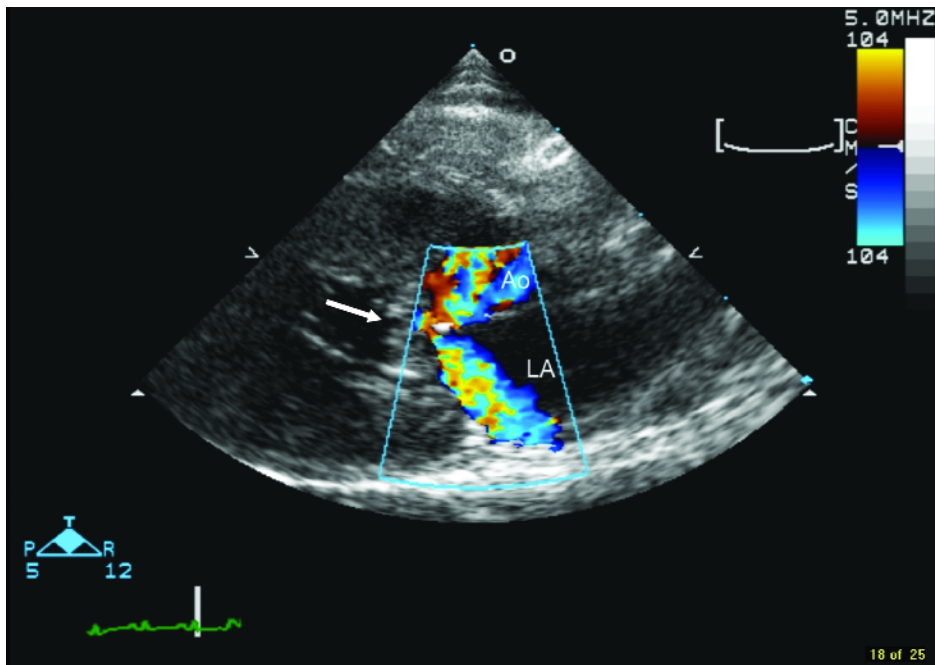
bpm = beats per minute; CBC = complete blood count;
NT-proBNP = N-terminal pro-B-type natriuretic peptide;
 T_4 = thyroxine

Diagnosis: Hypertrophic obstructive cardiomyopathy

Further Diagnostics. The cat was referred to a specialty hospital for cardiac evaluation. Echocardiography revealed a thickened interventricular septum and left ventricular free wall of 7.7 mm and 5.9 mm, respectively. The ratio of atrial diameter to aortic root diameter was mildly increased at 1.5. Systolic anterior motion of the mitral valve was documented (**Figure 1**) and the left ventricular outflow tract velocity was 4.5 m/s (values up to 2 m/s are normal).

Treatment. Tachycardia and left ventricular outflow obstruction are indications for beta-blockade. Atenolol 6.25 mg Q 24 H was initiated.

Follow-Up. The cat returned 1 month later for reevaluation. He was doing well at home and had a normal appetite and activity level. Heart rate was 174 bpm and echocardiographic examination indicated that the left ventricular outflow obstruction was partially attenuated, indicating effective beta-blockade. The treatment plan included continued atenolol therapy and a recheck visit in 3 to 6 months. ■



Right parasternal long-axis view of a cat with hypertrophic obstructive cardiomyopathy and elevated NT-proBNP. Note the presence of systolic anterior motion of the mitral valve (*arrow*), causing both mitral regurgitation and left ventricular outflow tract obstruction. Note the turbulent blood flow in the left atrium (LA) and aorta (Ao) during systole.

See Aids & Resources, back page, for references, contacts, and appendices.
Article archived on www.cliniciansbrief.com

Dr. Oyama discloses that he consults for IDEXX Laboratories, Westbrook, Maine.

DID YOU ANSWER...

- NT-proBNP is a natriuretic hormone produced by cardiac muscle in response to increased wall stress.
- Elevated levels of NT-proBNP are consistent with underlying heart disease.
- Normal levels of NT-proBNP rule out clinically significant heart disease.
- Diagnosis of heart disease in cats without overt clinical signs can be challenging. When heart murmurs or a gallop rhythm is present, the sound is often soft and intermittent. In addition, some cats with a murmur have little to no sig-

nificant underlying heart disease. Chest radiographs are relatively insensitive to changes in heart size before the onset of advanced disease.

- Echocardiography is considered the gold standard for diagnosis; however, it is not always available and is relatively expensive. In a study of cats with clinical signs, with and without a murmur or gallop, NT-proBNP levels greater than 49 pmol/L differentiated cats with cardiomyopathy from normal controls with 100% sensitivity and 89% specificity.¹ While further research will be needed to determine

the positive predictive value of any individual NT-proBNP test result, based on these results it may be possible to use NT-proBNP as an initial screening test for significant heart disease in cats with a murmur or gallop. If a cat has an NT-proBNP level greater than 50 pmol/L, it probably has underlying heart disease and further tests, such as echocardiography with or without thoracic radiography and electrocardiography, are warranted and necessary for a definitive diagnosis.

bpm = beats per minute; CBC = complete blood count; m/s = meters per second; NT-proBNP = N-terminal pro-B-type natriuretic peptide; T₄ = thyroxine