




7-1-1973

# Posterior Lenticonus in the Dog

Gustavo D. Aguirre  
*University of Pennsylvania*

Stephen I. Bistner

Follow this and additional works at: [https://repository.upenn.edu/vet\\_papers](https://repository.upenn.edu/vet_papers)

 Part of the [Congenital, Hereditary, and Neonatal Diseases and Abnormalities Commons](#),  
[Ophthalmology Commons](#), and the [Veterinary Medicine Commons](#)

---

## Recommended Citation

Aguirre, G. D., & Bistner, S. I. (1973). Posterior Lenticonus in the Dog. *Cornell Veterinarian*, 63 (3), 455-461. Retrieved from [https://repository.upenn.edu/vet\\_papers/30](https://repository.upenn.edu/vet_papers/30)

At the time of publication, author Gustavo Aguirre was affiliated with Cornell University. Currently, he is a faculty member at Penn Vet at the University of Pennsylvania.

PMID: 4782563

This paper is posted at Scholarly Commons. [https://repository.upenn.edu/vet\\_papers/30](https://repository.upenn.edu/vet_papers/30)  
For more information, please contact [repository@pobox.upenn.edu](mailto:repository@pobox.upenn.edu).

---

# Posterior Lenticonus in the Dog

## **Abstract**

Posterior lenticonus is a congenital defect of the posterior lenticular surface. The posterior cortical and capsular regions of the lens have a circumscribed conelike or globular protrusion of variable size. Opacities may be present in the region of the conus. The defect has been reported in man, rabbits, calves and mice. This report documents 2 cases in unrelated dogs. The possible mechanism for the formation of this defect is discussed.

## **Keywords**

eye, congenital, lens, cataract, dog

## **Disciplines**

Congenital, Hereditary, and Neonatal Diseases and Abnormalities | Medicine and Health Sciences |  
Ophthalmology | Veterinary Medicine

## **Comments**

At the time of publication, author Gustavo Aguirre was affiliated with Cornell University. Currently, he is a faculty member at Penn Vet at the University of Pennsylvania.

PMID: 4782563

## POSTERIOR LENTICONUS IN THE DOG

GUSTAVO AGUIRRE<sup>1</sup> and STEPHEN I. BISTNER<sup>2</sup>

<sup>1</sup>*Section of Ophthalmology,  
Research Laboratory for Diseases of Dogs,  
New York State Veterinary College,  
Cornell University, Ithaca, New York 14850*  
and <sup>2</sup>*Department of Small Animal Medicine and Surgery,  
New York State Veterinary College,  
Cornell University, Ithaca, New York 14850*

Received June 12, 1972

**ABSTRACT** Posterior lenticonus is a congenital defect of the posterior lenticular surface. The posterior cortical and capsular regions of the lens have a circumscribed conelike or globular protrusion of variable size. Opacities may be present in the region of the conus. The defect has been reported in man, rabbits, calves and mice. This report documents 2 cases in unrelated dogs. The possible mechanism for the formation of this defect is discussed.

**KEY WORDS:** EYE, CONGENITAL, LENS, CATARACT, DOG

*(Cornell Vet., 1973, 63:455-461)*

**P**OSTERIOR lenticonus is a congenital defect of the posterior lenticular surface. Instead of having a smoothly convex surface, the posterior cortical and capsular regions have a circumscribed conelike (lenticonus) or globular (lenti-globus) protrusion of variable size. Opacities may be present in the region of the conus. The defect has been reported in man (2), rabbits (6), calves (6), mice (3) and the lesion reported in pigs has been recently reviewed (6). In mice, a hereditary spontaneous rupture of the posterior lens capsule has been described. This condition is transmitted as a simple recessive trait. The lenticular changes become evident about the third week of life and are characterized by the formation

of a posterior lenticonus and lens capsule rupture. A cataract then forms and the nucleus and cortical material are expelled into the vitreous chamber (3).

To our knowledge, there are no reports of this condition in dogs. The purpose of this article is to present two cases of posterior lenticonus in the dog and to discuss the possible mechanism for the formation of this defect.

#### CASE 1.

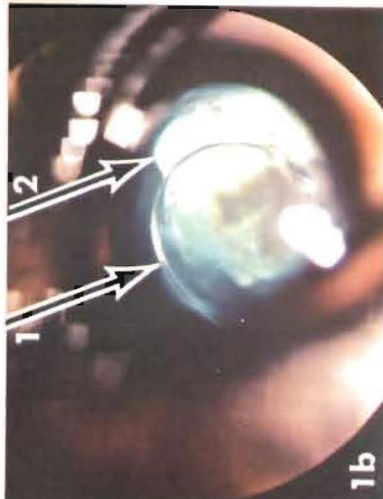
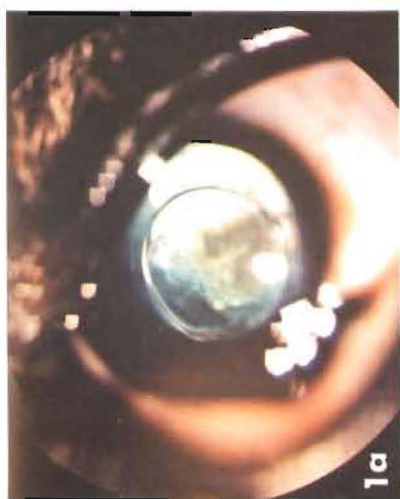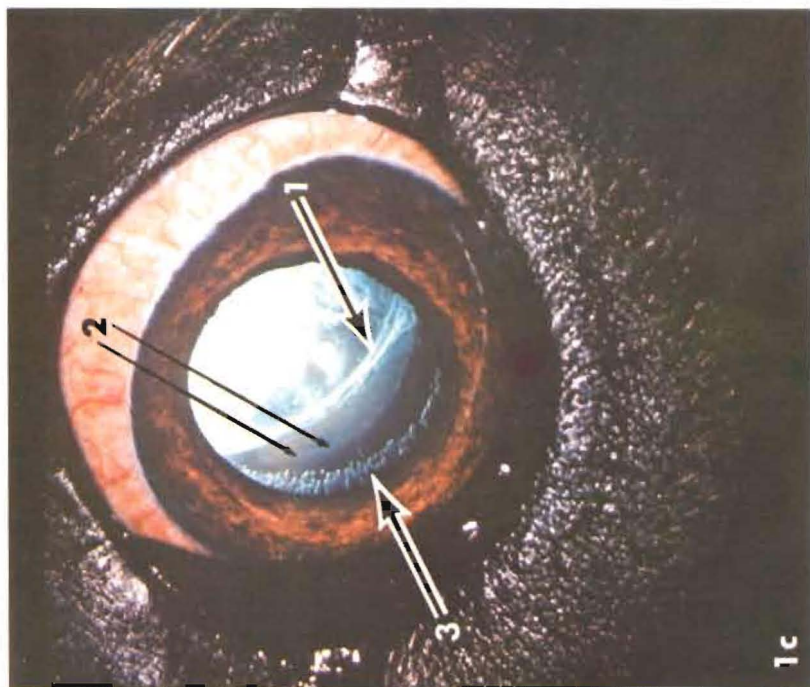
A 1½ year old female miniature Schnauzer was examined for the presence of congenital hereditary cataracts. The left eye had a small nuclear cataract and a circumscribed defect of the posterior lens capsule (Fig. 1a). This eccentrically placed defect (displaced infero-nasally) occupied 2/5 of the posterior lens surface, and cortical fibers as well as parts of the nuclear cataract projected through the ectatic lesion deep into the vitreous (Fig. 1b). Biomicroscopic examination indicated that the posteriorly displaced lenticular material was surrounded by a thin but intact lens capsule. Ophthalmoscopy revealed the posterior limits of this lesion to be +5 to +6 diopters away from the optic nerve head (Fig. 2).

The remaining cortical and equatorial regions of the lens were clear and no other abnormalities were present in the left eye. Only a small nuclear opacity was present in the right eye. A diagnosis of bilateral nuclear cataracts and posterior lenticonus (left eye) was made.

---

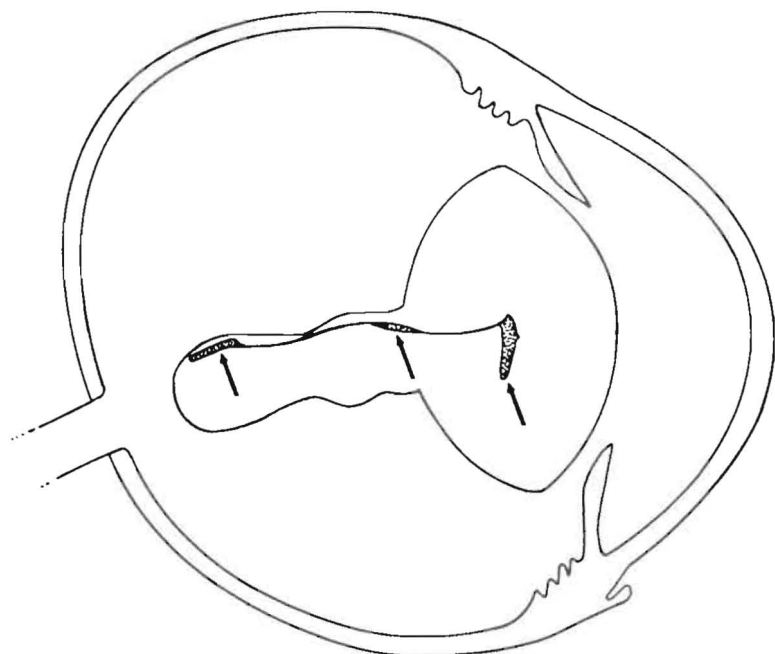
*Fig. 1.* Clinical photographs of the lenticular defects present in cases 1 (1a and 1b) and 2 (1c). In 1a, the camera was focused on the posterior lens capsule and demonstrates the well circumscribed border of the posterior lenticonus. The V-shaped nuclear opacity is slightly out of focus. In 1b, the camera was focused in the mid-vitreous and shows the circumscribed posterior lens capsule defect (arrow 1) and the posterior limit of the lenticonus (arrow 2).

Figure 1c (case 2) shows the infero-nasal aspect of the posterior capsule defect (arrow 1), the posterior border of the lenticonus which is located in the anterior vitreous (arrow 2) and the extensive vacuolation of the lenticular equator (arrow 3).



## CASE 2.

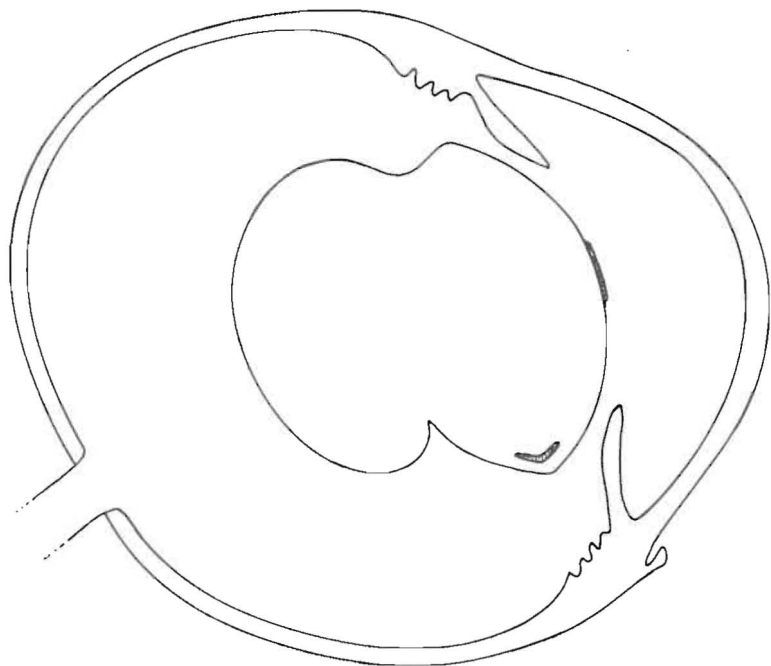
A 10 month old female brindle Mastiff-cross was examined for lenticular subluxation because an "aphakic" crescent was seen by the referring veterinarian. In the left eye a



*Fig. 2.* Diagrammatic view of the globe and the lenticular defect in case 1. The posterior lenticonus extends deep into the vitreous body, close to the optic nerve head. A nuclear cataract (arrow) projects through the lenticular defect into the posterior limits of the lenticonus.

large circular defect occupied nearly  $2/3$  of the posterior lens capsule surface. On biomicroscopic examination, cortical fibers, covered by an intact lens capsule, were seen to project through the ectatic area into the anterior vitreous. In addition, a small anterior capsular opacity and extensive vacuolation of the inferior lenticular equator were present in the left eye (Fig. 1c and 3). The impression of an "aphakic" crescent was created by the inferior border of the lenticonus located in the path of the tapetal reflection.

The right eye was normal. A diagnosis of unilateral anterior capsular cataract and posterior lentiglobus was made.



*Fig. 3.* Diagrammatic view of the globe and the lenticular defect in case 2. The posterior lenticonus is globular in shape and projects into the anterior vitreous. Inferior equatorial vacuolation and an anterior capsular opacity are also present.

#### DISCUSSION

Ectodermal defects can produce alterations in the size, shape, position and transparency of the lens (6). During fetal life, the developing optic vesicle induces formation of the lens placode which differentiates into the lens sphere or vesicle and detaches from the surface ectoderm. The cells in the posterior surface of the lens sphere elongate and form the primary lens fibers, the primordia of the adult fetal nucleus. The posterior lens capsule is fully formed by 35 days of gesta-

tion, and the fetal nucleus becomes surrounded by the secondary or cortical fibers by 40 days of gestation. Once the cortical fibers are present, posterior lens capsule material is no longer formed (1). The presence of an intact lens capsule surrounding the posterior lenticonus in these two cases suggests that the defect occurred prior to the formation of the lens capsule. In fact, the presence of a nuclear opacity extending into the posterior border of lenticonus would indicate that, in at least one case, the posterior lenticonus occurred at the time the primary lens fibers began to elongate, i.e., by 25 days of gestation (1).

Several theories have been proposed to explain the processes involved in the formation of posterior lenticonus in man. These theories range from those suggesting the presence of a localized lenticular hernia due to a posterior capsule defect to the more recent ones which indicate that the abnormality is the result of an overgrowth of lens fibers (see reference 2 for review). Histological sections obtained from several cases of posterior lenticonus in man have demonstrated a very thin but intact lens capsule, with the aberrant growth of sub-capsular epithelium overlying the lenticonus (2).

In both of our cases, biomicroscopic examination revealed the presence of an intact lens capsule around the very extensive posterior lenticular defects. In the absence of substantiating histopathologic material, we feel that in our two cases the lenticular defect probably occurred at the time of elongation of the primary lens fibers.

#### ACKNOWLEDGMENT

The authors express appreciation to Mr. George Batik, M.S., for the diagrammatic sketches.

#### REFERENCES

1. Aguirre, G. D., L. F. Rubin and S. I. Bistner. 1972. The development of the canine eye. *Am. J. Vet. Res.* 33:2399-2414.
2. Duke-Elder, S. 1964. *System of Ophthalmology*. Vol. 3. Congenital Deformities. London, Henry Kimpton. 700-704.
3. Fraser, F. C. and M. L. Herer. 1950. The inheritance and expression of the "lens rupture" gene in the house mouse. *J. Hered.* 41:3-7.
4. Makley, T. A. Jr. 1955. Posterior lenticonus. *Am. J. Ophth.* 39:308-312.



5. Mann, I. 1957. Developmental abnormalities of the eye. Philadelphia, Lippincott.
6. Saunders, L. Z. 1968. Pathology of the eye of domestic animals. Special issue of "Ernst Joests Handbuch der speziellen pathologischen Anatomie der Haustiere". Vol. 3. Berlin, Paul Parey. 530-532.
7. Smelser, G. K. and L. von Sallman. 1949. Correlation of microscopic and slit-lamp examinations of developing hereditary cataracts in mice. *Am. J. Ophth.* 32:1703-1713.