



University of Pennsylvania  
ScholarlyCommons

---

Departmental Papers (Vet)

School of Veterinary Medicine

---

2-1-2011

# Intraocular Nematodiasis in a Llama (*Lama glama*)

Bettina Dunkel

Raymond W. Sweeney

University of Pennsylvania, [rsweeney@vet.upenn.edu](mailto:rsweeney@vet.upenn.edu)


Perry L. Habecker

University of Pennsylvania, [habecker@vet.upenn.edu](mailto:habecker@vet.upenn.edu)

András M. Komáromy

University of Pennsylvania, [komaromy@vet.upenn.edu](mailto:komaromy@vet.upenn.edu)

Follow this and additional works at: [https://repository.upenn.edu/vet\\_papers](https://repository.upenn.edu/vet_papers)

 Part of the [Ophthalmology Commons](#), [Pathology Commons](#), and the [Veterinary Medicine Commons](#)

---

## Recommended Citation

Dunkel, B., Sweeney, R. W., Habecker, P. L., & Komáromy, A. M. (2011). Intraocular Nematodiasis in a Llama (*Lama glama*). *Canadian Veterinary Journal (La Revue Vétérinaire Canadienne)*, 52 (2), 181-183. Retrieved from [https://repository.upenn.edu/vet\\_papers/47](https://repository.upenn.edu/vet_papers/47)

PMCID: PMC3022461

This paper is posted at ScholarlyCommons. [https://repository.upenn.edu/vet\\_papers/47](https://repository.upenn.edu/vet_papers/47)

For more information, please contact [repository@pobox.upenn.edu](mailto:repository@pobox.upenn.edu).

---

# Intraocular Nematodiasis in a Llama (*Lama glama*)

## Abstract

This report describes a unique case of presumed migration of *Parelaphastrongylus tenuis* through the spinal cord into the eye of a llama where it survived and matured within the ocular environment. Blindness of the eye was most likely attributable to migration of the parasite through the central nervous tissue.

## Résumé

**Infestation par les nématodes intraoculaire chez un lama (*Lama glama*).** Ce rapport décrit un cas unique de migration présumée de *Parelaphastrongylus tenuis* dans la colonne vertébrale jusque dans l'œil d'un lama où il a survécu et est parvenu à maturité dans l'environnement oculaire. La cécité de l'œil a été le plus probablement attribuable à la migration du parasite dans les tissus du système nerveux central.

(Traduit par Isabelle Vallières)

## Disciplines

Medicine and Health Sciences | Ophthalmology | Pathology | Veterinary Medicine

## Comments

PMCID: PMC3022461

## Intraocular nematodiasis in a llama (*Lama glama*)

Bettina Dunkel, Raymond W. Sweeney, Perry L. Habecker, Andras M. Komaromy

**Abstract** – This report describes a unique case of presumed migration of *Parelaphastrongylus tenuis* through the spinal cord into the eye of a llama where it survived and matured within the ocular environment. Blindness of the eye was most likely attributable to migration of the parasite through the central nervous tissue.

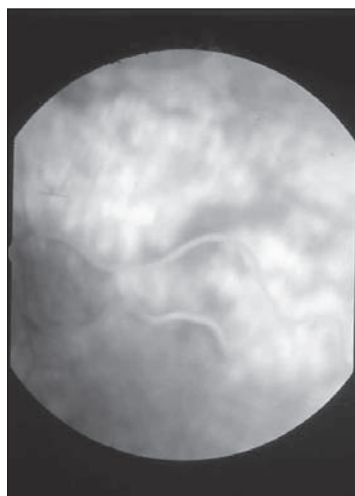
**Résumé** – Infestation par les nématodes intraoculaire chez un lama (*Lama glama*). Ce rapport décrit un cas unique de migration présumée de *Parelaphastrongylus tenuis* dans la colonne vertébrale jusque dans l'œil d'un lama où il a survécu et est parvenu à maturité dans l'environnement oculaire. La cécité de l'œil a été le plus probablement attribuable à la migration du parasite dans les tissus du système nerveux central.

(Traduit par Isabelle Vallières)

Can Vet J 2011;52:181–183

**A** 12-year-old female llama was presented with a history of acute onset of recumbency. The llama was kept in a field that had another llama and 1 alpaca and was frequently visited by the local deer population. The field was kept under loose observation. The camelids had been last dewormed with ivermectin (Merial, Athens, Georgia, USA) 0.2 mg/kg body weight (BW), SQ, 5 mo before presentation. On the day of presentation, the llama was found down on her left side, apparently unable to stand and was referred to the Widener Hospital for Large Animals at New Bolton Center, University of Pennsylvania. Upon presentation, the llama was bright and alert, and vital parameters were within normal limits. Several abrasions were present over the left side of the face; the left eye showed marked blepharospasm. Neuro-ophthalmic evaluation revealed an absent menace and dazzle response in the right eye. Direct and indirect pupillary light responses (PLR) were intact, but the eye was deemed non-visual.

Ophthalmologic examination of the right eye using direct and indirect ophthalmoscopy before and after pharmacologic dilation of the pupil yielded an actively moving, approximately



**Figure 1.** Fundoscopic picture of parasite within the posterior segment of the right eye.

2-cm long helminth within the vitreous, close to the retinal surface (Figure 1). The left eye had an intact menace response, the pupil was miotic, but direct and indirect PLR could be elicited. Fluorescein staining identified a central superficial corneal ulcer approximately 0.5 cm in diameter and a small amount of fibrin within the anterior chamber; no abnormalities of the posterior segment or fundus were observed. Ocular changes in the left eye were attributed to trauma sustained during recumbency leading to corneal ulceration and anterior uveitis. Intraocular pressure measurements and Schirmer tear tests were not performed as an increased intraocular pressure or decreased tear production were considered unlikely. The remainder of the neuro-ophthalmic examination was unremarkable. No further cranial nerve deficits were detected. Spinal reflexes were intact, but muscular tone in all 4 limbs was decreased. The llama was able to rise without assistance and stood for short periods. Based on the neurological

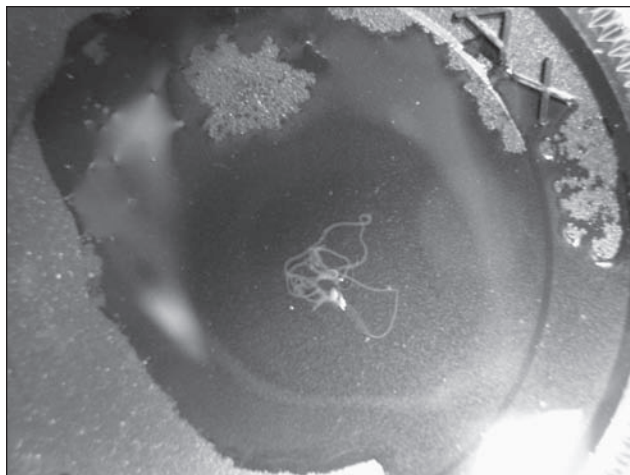
---

Departments of Clinical Studies (Dunkel, Sweeney, Komaromy) and Pathobiology (Habecker), School of Veterinary Medicine, New Bolton Center, University of Pennsylvania, 382 West Street Road, Kennett Square, Philadelphia, Pennsylvania 19348, USA. Address all correspondence to Dr. Bettina Dunkel; e-mail: bdunkel@rvc.ac.uk

Dr. Dunkel's current address is The Royal Veterinary College, Hawkshead Lane, North Mymms, Herts AL9 7TA, United Kingdom.

Reprints will not be available from the authors.

Use of this article is limited to a single copy for personal study. Anyone interested in obtaining reprints should contact the CVMA office (hbroughton@cvma-acmv.org) for additional copies or permission to use this material elsewhere.



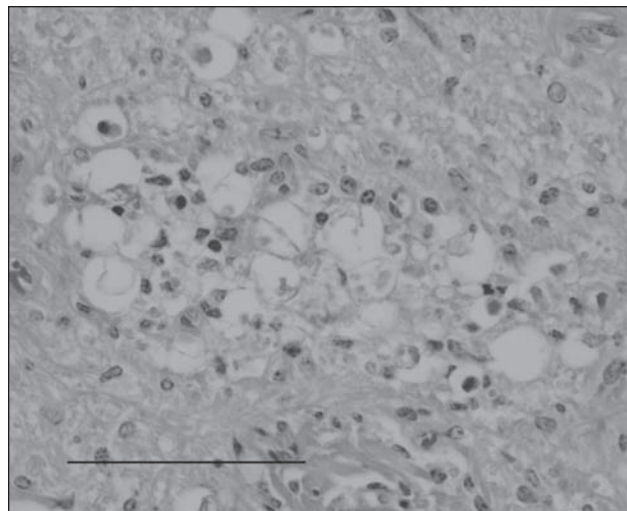
**Figure 2.** Photograph of the parasite on a camera lens after removal from the eye during postmortem examination.

examination, multifocal or diffuse disease of the spinal cord and brain was suspected.

A complete blood (cell) count and serum chemistry yielded no significant abnormal findings; therefore, cerebrospinal fluid (CSF) was obtained from the lumbosacral space. Analysis of the CSF showed an increased nucleated cell count ( $26 \times 10^6$  cells/L) and increased total protein concentration (0.94 g/L) (1). The red blood cell count was  $20 \times 10^6$  cells/L. The nucleated cell population was comprised predominantly of eosinophils with few mononuclear cells. Based on these findings, the presumptive diagnosis of intraocular and meningeal nematodiasis, most likely due to *Parelaphostrongylus tenuis* was established. Further diagnostic tests, including a Baerman flotation and CSF analysis for *P. tenuis* antigen were considered but not pursued in light of the low diagnostic yield of the flotation and limited availability of the antigen test.

Treatment consisted of 1 dose of ivermectin (Merial) 0.2 mg/kg BW, SQ, fenbendazole (Hoechst Roussel Vet, Somerville, New Jersey, USA), 15 mg/kg PO, q24h, dexamethasone (Hoechst Roussel Vet), 0.05 mg/kg, IV, q24h, and flunixin meglumine (Fort Dodge Animal Health, Overland Park, Kansas, USA), 0.5 mg/kg, IV, q12h. The left eye was treated with atropine (Bausch & Lomb Pharmaceuticals, Tampa, Florida, USA) once and triple antibiotic ointment (Pfizer Animal Health, New York, New York, USA) 3 times a day. The corneal ulcer healed rapidly, based on the absence of fluorescein uptake, and signs of anterior uveitis subsided based on the increased comfort and absence of further signs within the eye. The right eye remained unchanged during the course of treatment; the parasite was observed to move freely within the posterior segment, mainly close to the retina, but occasionally just posterior to the lens. When located close to the lens, the parasite was visible with the bare eye. The llama's neurologic condition gradually deteriorated, she became progressively weaker and was unable to rise. She was euthanized after 7 d of treatment.

Postmortem examination revealed an obese animal with no significant lesions in any organ system with the exception of the central nervous system (CNS) and the right eye. The vitreous of the right eye contained a 2.5 cm long, viable filamentous



**Figure 3.** Transverse section of the right optic nerve demonstrating a recent nematode path. The photo depicts inflammatory cell infiltrates, swollen and disrupted axon sheaths, axonophagia, and nearby spheroids. Bar = 0.1 mm.

nematode (Figure 2). The gross appearance of the parasite was consistent with *P. tenuis*, but a definitive identification could not be obtained as the specimen was lost during shipment to the parasitology service. No macroscopic lesions were identified within the CNS. Histopathologic examination demonstrated 2 distinct pathways, which were thought to be the result of parasite migration, advancing cranially from approximately the level of the 8th thoracic vertebra. Evidence of larval migration was also present within the brainstem, the optic chiasm, and along the right optic nerve. The lesions were characterized by inflammatory cell infiltrates, swollen and disrupted axon sheaths, axonophagia, and nearby spheroids (Figure 3). No histological changes were detected in the right retina or choroid. Based on the histopathological evidence of parasite migration along the spinal cord and optic nerve and the presence of a viable nematode within the posterior segment, the presumptive diagnosis of ocular parelaphostrongylosis and verminous myeloencephalitis was made. We suspect that the migrating larva entered the posterior segment via the optic nerve, remained viable and even matured within the eye. Blindness in this case was most likely central in origin, as the pupillary light reflex remained intact; however, blindness due to partial optic nerve damage remained a possibility.

The term larvae migrans refers to migration of parasitic larvae within organs and tissue of animals and humans. Depending on the path of migration, visceral, ocular, neural, or cutaneous larvae migrans can be distinguished (2). Migration of *P. tenuis* through the central nervous tissue has been long recognized as a cause of neurological deficits in South American camelids and several other species. The life cycle of the parasite, treatment and prevention of the disease have been extensively described in the veterinary literature (3,4). Unfortunately, the parasite present in this case could not be definitively identified. Although *P. tenuis* is the best described parasite causing verminous myeloencephalitis in camelids (5–8), other migrating larvae cannot be ruled out. Clinical signs depend on the path of the larvae and may

include ataxia, weakness, paralysis, blindness, or cranial nerve deficits (3). A tentative diagnosis is based on history, clinical presentation, and eosinophilia in the cerebrospinal fluid; however, definitive diagnosis requires postmortem examination. Intraocular aberrant parasite migration is much less commonly reported in veterinary patients (9). Recently, a case of intraocular nematodiasis caused by a *P. tenuis* larva was described in an eland antelope, causing progressive unilateral uveitis, blindness, and subsequent neurological deficits (8).

Parasitic larvae can migrate within the retina or invade the eye via the systemic circulation (6), direct penetration of the sclera (10), or via ciliary or optic nerves (8,11,12). In an experimental model of ocular toxocariasis, migrating larvae were found in the optic chiasm and optic nerve prior to entering the retina (12), taking a similar route as histopathologically evident in this case and as suspected in an antelope suffering from parelaphostrongylosis (8). Multiple parasitic species can cause ocular lesions, including *Toxoplasma* spp., *Toxocara* spp., *Dirofilaria* spp., *Onchocerca* spp., fly larvae (ophthalmomyiasis) and cestodes (10–12). The anterior chamber is most frequently invaded, but larvae and adult parasites have been described within the posterior segment (13–15). Due to the size of the observed adult parasites, intraocular maturation of larvae has been postulated (13). Ocular lesions range from minimal apparent damage to uveitis, corneal edema, glaucoma, endophthalmitis, and retinal changes including chorioretinitis, neuroretinitis, and retinal hemorrhage (9,12) and are thought to originate through direct damage caused by migration, release of toxic factors by the parasite or immunologic reactions of the host (16).

In this case, little ocular changes were observed despite the presence of a large, actively moving helminth. Death and decay of intraocular parasites has been associated with more severe ocular damage compared to presence of viable organisms (16), which could explain the lack of significant uveitis and retinitis antemortem in this case. Host species, localization within the eye, and the migration route are other factors influencing the varying clinical manifestations (10,16). The right-sided blindness with intact PLR but absent dazzle and menace reflex was thought to originate either from multifocal central lesions or damage to the optic nerve. Incomplete damage to the retinal ganglion cell fibers impairing vision and dazzle response, but not the PLR, was also considered, although it could not be confirmed histologically. Despite the relatively frequent occurrence

of ocular lesions in South American camelids (17), intraocular nematodiasis has not been previously reported to the authors' knowledge. The described case emphasizes the importance of a thorough ophthalmological evaluation during examination of a camelid patient and ocular nematodiasis should be considered in cases of unexplained ocular lesions.

CVJ

## References

1. Welles EG, Pugh DG, Wenzel JG, Sorjonen DC. Composition of cerebrospinal fluid in healthy adult llamas. *Am J Vet Res* 1994;55:1075–1079.
2. Kavzacos KR. Larva migrans from pets and wildlife. *Comp Cont Educ Pract Vet* 2002;24:41–46.
3. Pugh DG, Causey MK, Blagburn BL, Wolfe DF. Clinical Parelaphostrongylosis in llamas. *Comp Cont Educ Pract Vet* 1995;17:600–605.
4. Gandolf AR, Atkinson MW, Gemensky AJ, Hayes J, Grimes S, Blumer ES. Intraocular nematodiasis caused by *Parelaphostrongylus tenuis* in an eland antelope (*Taurotragus oryx*). *J Zoo Wildl Med* 2003;32:194–199.
5. Baum KH. Neurologic diseases of llamas. *Vet Clin North Am Food Anim Pract* 1994;10:383–390.
6. Baumgartner W, Zajac A, Hull BL, Andrews F, Garry F. Parelaphostrongylosis in llamas. *J Am Vet Med Assoc* 1985;187:1243–1245.
7. Brown TT, Jordan HE, Demorest CN. Cerebrospinal parelaphostrongylosis in llamas. *J Wildl Dis* 1978;14:441–444.
8. Krogdahl DW, Thilsted JP, Olsen SK. Ataxia and hypermetria caused by *Parelaphostrongylus tenuis* infection in llamas. *J Am Vet Med Assoc* 1987;190:191–193.
9. Carastro SM, Dugan SJ, Paul AJ. Intraocular dirofilariasis in dogs. *Comp Cont Educ Pract Vet* 1992;14:209–217.
10. Harris BP, Miller PE, Bloss JR, Pellitteri PJ. Ophthalmomyiasis interna anterior associated with *Cuterebra* spp. in a cat. *J Am Vet Med Assoc* 2000;216:352–355.
11. Sabrosa NA, Zajdenweber M. Nematode infections of the eye: Toxocariasis, onchocerciasis, diffuse subacute neuroretinitis, and cysticercosis. *Ophthalmol Clin North Am* 2002;15:351–356.
12. Hayashi E, Akao N, Fujita K. Evidence of involvement of the optic nerve as a migration route for larvae in ocular toxocariasis in Mongolian gerbils. *J Helminthol* 2003;77:311–315.
13. Blanchard GL, Thayer G. Intravitreal *Dirofilaria immitis* in a dog. *J Am Anim Hosp Assoc* 1978;14:33–35.
14. Gaunt PS, Confer AW, Carter JD, Trucksa RC, Neafie RC, Lichtenfels JR. Intraocular Strongylidiasis in a dog. *J Am Anim Hosp Assoc* 1982;18:120–122.
15. Gwin RM, Merideth R, Martin CL, Kaswan RL. Ophthalmomyiasis interna posterior in two cats and a dog. *J Am Anim Hosp Assoc* 1984;20:481–486.
16. Takayanagi TH, Akao N, Suzuki R, Tomoda M, Tsukidate S, Fujita K. New animal model for human ocular toxocariasis: Ophthalmoscopic observation. *Br J Ophthalmol* 1999;83:967–972.
17. Gelatt KN, Martinic GBOM, Flaneig JL, et al. Results of ophthalmologic examinations in 29 alpacas. *J Am Vet Med Assoc* 1995;206:1204–1207.