



7-1976

# Diseases of the Guttural Pouch

Charles W. Raker

Follow this and additional works at: [https://repository.upenn.edu/vet\\_papers](https://repository.upenn.edu/vet_papers)

 Part of the [Large or Food Animal and Equine Medicine Commons](#)

---

## Recommended Citation

Raker, C. W. (1976). Diseases of the Guttural Pouch. *Modern Veterinary Practice*, 57 (7), 549-552. Retrieved from [https://repository.upenn.edu/vet\\_papers/65](https://repository.upenn.edu/vet_papers/65)

This paper is posted at Scholarly Commons. [https://repository.upenn.edu/vet\\_papers/65](https://repository.upenn.edu/vet_papers/65)  
For more information, please contact [repository@pobox.upenn.edu](mailto:repository@pobox.upenn.edu).

---

# Diseases of the Guttural Pouch

## **Disciplines**

Large or Food Animal and Equine Medicine | Medicine and Health Sciences | Veterinary Medicine

# The Equine Practitioner



## DISEASES OF THE GUTTURAL POUCH

C. W. Raker, VMD  
University of Pennsylvania  
New Bolton Center  
Kennett Square, Pennsylvania 19348

The paired guttural pouches (GP) in the horse represent ventral diverticula of the eustachian tubes, although their true function is unknown. They may function as a relief valve mechanism since they fill with air during expiration and empty during inspiration, at which time the contained air might assist in warming inspired air. Their capacity is approximately 300 ml, and each connects with the pharynx through a slit-like opening.

These openings can be seen with an endoscope, but they are normally collapsed (except during forceful expiration and swallowing) and the inside of the pouch is not visible unless the endoscope is introduced directly into the GP. The medial side of the opening consists of a fold of fibrocartilage covered with mucous membrane.

The GP may be involved in all infections of the respiratory tract, but the incidence of primary GP disease is low.

### *Tympanites*

Tympanites (emphysema) of the GP is seen occasionally in sucklings and weanlings. Some reports suggest that this is a congenital defect which may not be manifested until the horse is 1 year of age.<sup>1</sup> The pertinent clinical signs are distention of one or both GP in the region of Viborg's triangle. Percussion reveals an air-filled cavity, and firm digital pressure may result in expulsion of air with collapse of the GP. Should this procedure fail, decompression can be achieved by inserting a needle into the distended GP.

Signs of upper airway obstruction vary in intensity with the degree of distention of the GP. The anomaly is said to be unilateral,<sup>2</sup> but I have seen 2 cases with bilateral involvement. The nature of the defect is not known, but it appears to involve the pharyngeal orifice of the eustachian tube, allowing air to enter the GP, where it is trapped. Nursing foals are susceptible to aspiration (milk) pneumonia—a serious complication; regurgitated milk may be observed at the external nares.

Several surgical methods to repair the defect are available, and in the absence of pneumonia the prognosis is favorable. Before surgery, decompression should be performed to determine whether the defect is unilateral or bilateral. Unilateral tympanites may cause distention on both sides of the neck, but the signs should disappear on unilateral decompression. If bilateral, signs would still be evident following unilateral decompression.

The foal is placed under general anesthesia in lateral recumbency with the affected GP up. The skin over Viborg's triangle is prepared for surgery, and a 3-4" skin incision is made in the triangle. The wall of the distended GP lies directly under the skin and is exposed by careful blunt dissection. It is carefully incised, causing it to collapse. If the defect is unilateral, a 1-cm<sup>2</sup> or larger window is made through the median walls of the left and right GP. This communication between the 2 GPs allows trapped air to escape through the opposite normal pharyngeal orifice.

If the defect is bilateral, in addition to establishing a communicating window, a 9" Allis tissue or sponge forceps is passed crani-

ally through the eustachian tube to the level of its pharyngeal orifice. Using the index finger as a guide, the free cartilaginous margin of the pharyngeal orifice is securely grasped in the forceps. A section of tissue is cut from the orifice with a pair of long Metzenbaum scissors. This procedure prevents the trapping of air and corrects the defect. The latter procedure can be used along with unilateral involvement.<sup>1</sup>

In a recently described technic a specially developed electrocautery is introduced into the GP, and with endoscopic visualization a window is cut between the right and left GP. The GP can also be approached by the more classical route in the region of the wing of the atlas.<sup>3</sup>

After completion of the corrective surgery, the wall of the GP and the skin may be sutured, or the wound may be left open to heal by granulation. Except for foreign body pneumonia, complications are rare and prognosis is favorable. Prophylactic tetanus antitoxin and antibiotics for 5 days are given.

#### *Diphtheria (Mycosis)*

Fatal epistaxis has been attributed to a condition termed diphtheria of the guttural pouch<sup>4</sup>. A diphtheritic lesion was found involving most frequently the dorsal wall of the medial compartment of the GP in the region of the petrous temporal bone, the cervical sympathetic nerve, and the glossopharyngeal and vagus nerves. Erosion of the wall of the internal carotid artery resulted in intermittent or fatal epistaxis. Signs included epistaxis, dysphagia, parotid pain, abnormal head posture, nasal catarrh, head shyness, abnormal respiratory noise, sweating and shivering, Horner's syndrome and ocular defects, colic, and facial paralysis. The causative agent was not determined, although *Aspergillus nidulans* was recovered. Concurrent bacterial infection, usually of mixed positive cocci and gram-negative bacilli, was common.

Postmortem studies in an abattoir revealed chronic, apparently healed lesions in the region of the petrous temporal bone, and it was speculated that these horses were at one time infected but had recovered. Most of the clinical signs result from involvement of one or more of the cranial nerves as they travel through the wall of the GP, or of the cervical sympathetic nerve

(Horner's syndrome). Involvement of vessels in the wall and infection of the GP leads to epistaxis, airway obstruction, intermittent nasal exudate, and pain.

Endoscopy of the GP is somewhat difficult. Special angled tips for standard straight endoscopes are available, and a long curved catheter (Guenther or Neilson) or a Chambers' uterine catheter is suitable for introduction into the GP. If difficulty is encountered passing a catheter, viewing the entrance to the GP through the endoscope may help. Cultures of the GP may be obtained in a similar manner, using sterile nasopharyngeal swabs. Similarly, irrigation and washing of the pouch, with collection of the fluid for cytology and culture, can be performed.

If daily irrigation and medication of the GP is desirable, a self-retaining plastic intrauterine catheter is inserted. The portion of the tube protruding from the external nares is securely sutured inside the nostril to prevent the horse from tearing it out by rubbing. This procedure obviates daily passage of tubes for irrigation and medication. Surgical drainage and local medication with various drugs has failed to alter the mycotic infection.<sup>4</sup> Surgical removal of the mycotic lesion may result in fatal epistaxis.

Mycosis/epistaxis has been effectively treated by instillation of a 1:4 dilution of povidone iodine (Betadine) solution.<sup>5</sup> The GP was irrigated daily for 7-10 days or until there was endoscopic evidence of a marked diffuse inflammatory reaction upon chemical debridement of the mucous membrane. A later case of chronic empyema of the GP treated in a similar manner failed to respond. Consideration is being given to infusing the GP with agents such as trichloroacetic acid or formalin; 2 horses with GP diphtheria were recently reported to respond satisfactorily to infusion.

Some veterinarians believe that every horse with epistaxis has a GP infection, or that every horse that shows epistaxis when the head is lowered is bleeding from the GP. This is an inaccurate observation since epistaxis may originate from other points. Pulmonary hemorrhage may not be evident until the head is lowered, permitting a free flow of blood from the lung and trachea to the throat.

Mycosis of the GP represents a serious



Fig 1. The most characteristic feature of tympanitis of the guttural pouch is the air-filled distention in the region of the throat latch posterior to the ramus of the mandible.

problem, calling for a guarded prognosis, and the possibility of fatal epistaxis should be reported to the owner. No truly effective treatment is available at this time, but the disease is undergoing extensive study.

### *Empyema*

Empyema of the GP usually represents a secondary chronic infection following a more generalized upper respiratory infection. Radiographs may demonstrate a fluid-filled GP, or the purulent exudate may become inspissated and form radiopaque masses. A relatively voluminous discharge

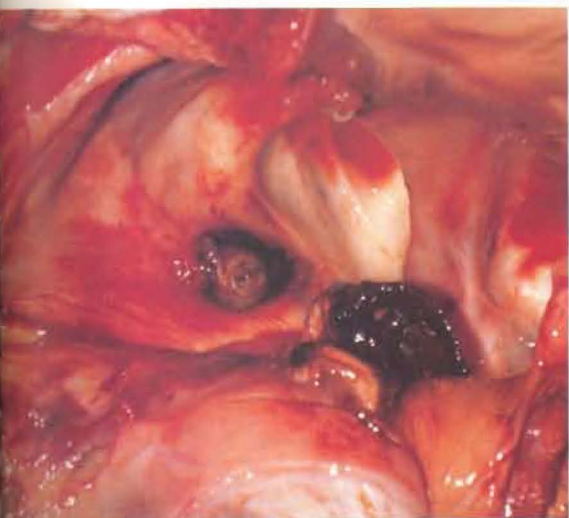


Fig 2. Diphtheritic lesions in the guttural pouch usually arise from the dorsal wall of the medial compartment. Erosion of the wall of the internal carotid artery may result in fatal epistaxis.

of accumulated exudate may be observed periodically when the horse lowers his head to the ground. With unilateral infection most of the exudate may flow from the nostril on the affected side. The exudate is usually nonodorous, somewhat mucoid, slightly milky, and opaque.

Exudate from the lungs may appear similar to that from the GP and may also be discharged intermittently; therefore, this sign is not pathognomonic. The affected GP may be distended, the head may be held stiff, and pressure over the area of the GP may elicit pain. The diagnosis can be confirmed by endoscopic examination of the GP.

Treatment consists of daily irrigation through a Neilson or Guenther catheter or

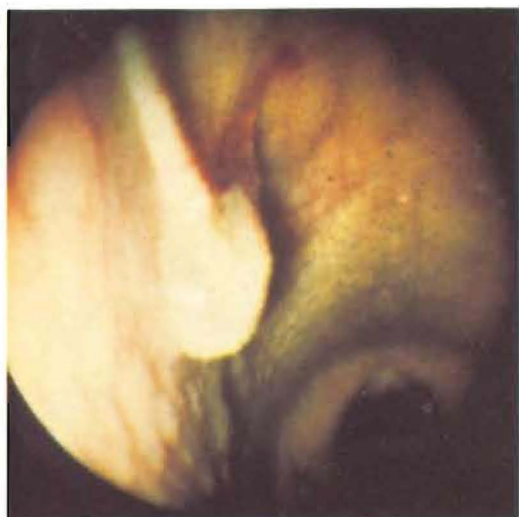

Fig 3. Diagnosis of empyema of the guttural pouch can frequently be confirmed by endoscopic evidence of drainage from the pharyngeal orifice. The pouch distended with pus protrudes into pharynx.

a self-retaining plastic uterine catheter. Should this approach fail, surgical drainage of the affected GP is indicated. The GP may be opened through Viborg's triangle, but due to the presence of the jugular and external maxillary veins, internal carotid artery, and other vital structures, this approach is not recommended unless marked distention makes it clearly outlined.

A more classical and safe approach (Charbert's) is described in standard surgical texts.<sup>3</sup> Basically, the operation is as follows: The horse is placed in lateral recumbency under general anesthesia. The area over the affected side of the head in the region of

This advertisement has been removed.

Viborg's triangle and the parotid gland up to the base of the ear is prepared for surgery. A 4" skin incision is made approximately 1" in front of and parallel to the anterior border of the wing of the atlas. The heavy fascia is carefully incised, bringing the parotid salivary gland in view.

Careful dissection is begun at the posterior border of the parotid gland and continued until the gland is completely freed from its tissue bed sufficiently to allow it to be retracted anteriorly. The auricular nerve should be isolated and retracted caudally. The plane of dissection is continued bluntly with the fingers to the posterior border of the occipito-mandibularis muscle, at which point the carotid artery will come into view. Careful exploration of the area will identify the thin wall of the GP. If the horse has not been intubated but has been given an intravenous anesthetic, the GP will distend with air during expiration.

The GP is grasped with a pair of rat-tooth forceps or Allis tissue forceps and incised with scissors. After the opening is enlarged with the fingers to admit the hand, the GP is inspected and palpated, and any inspissated material is removed. Following copious irrigation, a suitable drain is inserted, if indicated, with the distal end brought out through Viborg's triangle and sutured to the skin.

If more efficient drainage is deemed advisable, a curved metal probe is placed through the incision into the GP and directed distad so that its tip lies in Viborg's triangle. With the application of pressure the tip is palpable. The skin, underlying tissues and GP are carefully incised over the point of the catheter to establish effective ventral drainage. To prevent the opening from closing, a seton or suitable drain may be inserted. The incision along the wing of the atlas may be partially closed, leaving room for further irrigation and medication.

The prognosis following surgical drainage is favorable. Tetanus antitoxin and a course of antibiotics are indicated. □

#### References

1. *JAVMA* 140:453-454, 1962.
2. *Vet Rec* 79:1-7, 1966.
3. Frank: *Veterinary Surgery*, Burgess, Minneapolis, 1964.
4. *Vet Rec* 83:336-345; 422-428, 1968.
5. Hammel, Raker & Boles: Unpublished data.

Based on a presentation at the Annual Conference for Veterinarians, Cornell University, January 1976.