



1-1-2000

# Hyphema. Part II. Diagnosis and Treatment

András M. Komáromy

David T. Ramsey


Dennis E. Brooks

Cynthia C. Ramsey

Maria E. Kallberg

*See next page for additional authors*

Follow this and additional works at: [https://repository.upenn.edu/vet\\_papers](https://repository.upenn.edu/vet_papers)

 Part of the [Eye Diseases Commons](#), [Ophthalmology Commons](#), and the [Veterinary Medicine Commons](#)

---

## Recommended Citation

Komáromy, A. M., Ramsey, D. T., Brooks, D. E., Ramsey, C. C., Kallberg, M. E., & Andrew, S. E. (2000). Hyphema. Part II. Diagnosis and Treatment. *Compendium on Continuing Education for the Practicing Veterinarian*, 22 (1), 74-79, 96-. Retrieved from [https://repository.upenn.edu/vet\\_papers/52](https://repository.upenn.edu/vet_papers/52)

Dr. Komáromy was affiliated with the University of Pennsylvania from 2003-2012.  
Part I can be found at [http://repository.upenn.edu/vet\\_papers/51/](http://repository.upenn.edu/vet_papers/51/)

This paper is posted at Scholarly Commons. [https://repository.upenn.edu/vet\\_papers/52](https://repository.upenn.edu/vet_papers/52)  
For more information, please contact [repository@pobox.upenn.edu](mailto:repository@pobox.upenn.edu).

---

# Hyphema. Part II. Diagnosis and Treatment

## **Abstract**

The clinical appearance of hyphema is variable and is influenced by the volume of blood and the amount of time erythrocytes are present in the anterior chamber. When hyphema is evident, a complete history should be obtained and a thorough physical examination performed to direct the initial selection of diagnostic tests. Secondary complications of hyphema include glaucoma, synechiae, cataract formation, blood-staining of the cornea, and blindness. Frequent measurement of intraocular pressure is recommended. The two primary management issues in animals with hyphema are prevention of secondary hemorrhage (by treating the underlying disease) and control of secondary glaucoma.

## **Disciplines**

Eye Diseases | Medicine and Health Sciences | Ophthalmology | Veterinary Medicine

## **Comments**

Dr. Komáromy was affiliated with the University of Pennsylvania from 2003-2012.

Part I can be found at [http://repository.upenn.edu/vet\\_papers/51/](http://repository.upenn.edu/vet_papers/51/)

## **Author(s)**

András M. Komáromy, David T. Ramsey, Dennis E. Brooks, Cynthia C. Ramsey, Maria E. Kallberg, and Stacy E. Andrew



CE

Article #4 (1.5 contact hours)

Refereed Peer Review

## FOCAL POINT

- ★ Hyphema is frequently associated with iridocyclitis and generally implies severe intraocular or systemic disease.

## KEY FACTS

- The prognosis for animals with hyphema depends in large part on the identification of underlying diseases; institution of proper treatment; and careful, long-term follow-up, p. 74.
- A thorough ophthalmic and systemic diagnostic evaluation should be performed when hyphema is present, p. 75.
- The two primary management issues in animals with hyphema are preventing secondary hemorrhage (i.e., rebleeding) and controlling secondary glaucoma, 77.
- Frequent measurement of intraocular pressure is required in patients with hyphema, p. 78.

# Hyphema. Part II. Diagnosis and Treatment\*

University of Florida

Andras M. Komaromy, Dr.med.vet.

Dennis E. Brooks, DVM, PhD

Maria E. Kallberg, DVM

Stacy E. Andrew, DVM

Michigan State University

David T. Ramsey, DVM

Cynthia C. Ramsey, DVM, MS

**ABSTRACT:** The clinical appearance of hyphema is variable and is influenced by the volume of blood and the amount of time erythrocytes are present in the anterior chamber. When hyphema is evident, a complete history should be obtained and a thorough physical examination performed to direct the initial selection of diagnostic tests. Secondary complications of hyphema include glaucoma, synechiae, cataract formation, blood-staining of the cornea, and blindness. Frequent measurement of intraocular pressure is recommended. The two primary management issues in animals with hyphema are prevention of secondary hemorrhage (by treating the underlying disease) and control of secondary glaucoma.

**P**art I of this two-part presentation reviewed the pathophysiologic mechanisms that most frequently result in hyphema in animals; this article covers diagnostic and treatment considerations. The prognosis for animals with hyphema depends on identifying the underlying cause; initiating proper treatment; and careful, long-term follow-up.

## HISTORY

When hyphema is evident, a complete history should be obtained and a thorough physical examination performed to direct the initial selection of appropriate diagnostic tests. Recent health and vaccination status should also be ascertained. Trauma or ingestion of toxins (e.g., anticoagulant rodenticide) should be considered if an animal has access to the outdoors regardless of whether a traumatic incident or rodenticide ingestion was witnessed by the owner. Living in or travel to regions in which enzootic infectious disease (e.g., ehrlichiosis, Rocky Mountain spotted fever) is common should alert clinicians to consider infectious agents as a potential cause of hyphema. Recent drug administration or past illness may be important factors in determining the cause of hyphema. A recent history of abnormal vision or behavior before the onset of hyphema may signify preexisting or underlying ocular (e.g., iridocyclitis, glaucoma, retinal detachment) or central nervous system (e.g., hemorrhage, retrobulbar optic neuritis) disease. History of

\*Part I of this two-part presentation appeared in the November 1999 (Vol. 21, No. 11) issue of *Compendium*.

recurrent hyphema is suggestive of a persistent ocular or systemic disease.

The time at which hyphema is first observed may also assist clinicians in developing a list of differential considerations. For example, hyphema from anti-coagulant rodenticide toxicity takes 5 to 7 days to develop, whereas hemorrhage occurs immediately in patients with ocular trauma. Ocular neoplasia may also cause an acute onset of hyphema.

### PHYSICAL EXAMINATION

The physical examination of an animal with hyphema should not be limited only to the affected eye. When trauma has been eliminated as a likely cause, the prudent approach is to assume that a serious sight-threatening ocular disease or life-threatening systemic disease is present until proven otherwise. A thorough and detailed physical examination is indicated to detect any underlying evidence of systemic disease. Petechial hemorrhages of the mucous membranes (i.e., conjunctiva, oral mucosa, preputial/vulvar mucosa) or skin are frequently present along with thrombocytopenia or thrombocytopeny. Intraocular hemorrhage of the iris may also be present before hyphema occurs (Figure 1). Abdominal and thoracic palpation and auscultation may reveal physical signs suggestive of a third-compartment hemorrhage or vital organ involvement. Unless trauma is definitively identified as the cause of intraocular hemorrhage, every cat with hyphema should have its arterial blood pressure measured to identify systemic hypertension.<sup>1</sup>

### OPHTHALMIC EXAMINATION

The physical examination should always include a

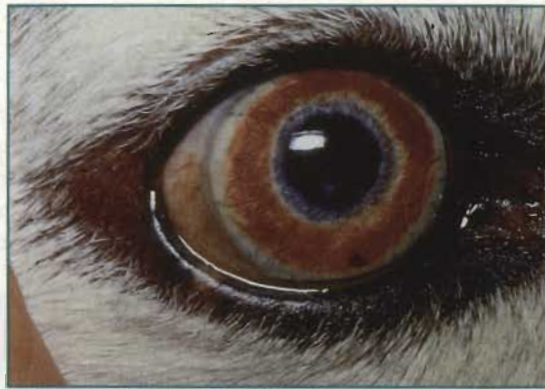

Figure 1A

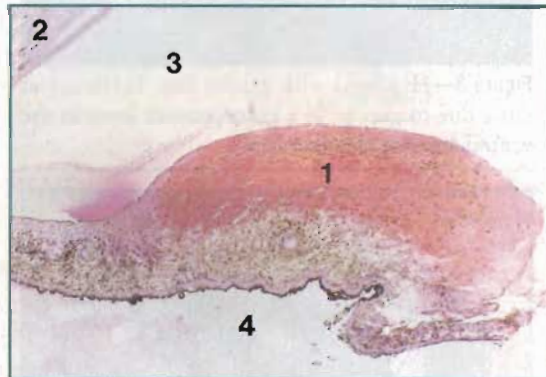


Figure 1B

Figure 1—Photograph (A) and photomicrograph (B) showing intraocular hemorrhage of the iris (1) in a dog (cornea [2], anterior chamber [3], posterior chamber [4]). (Hematoxylin & eosin stain; original magnification,  $\times 40$ )

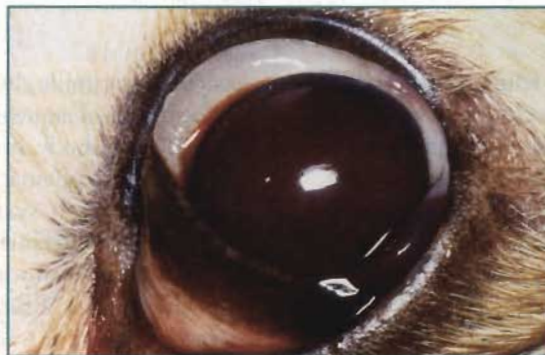

Figure 2—Complete (total) hyphema in a dog.

detailed ophthalmic examination of both the anterior and posterior segments of the affected and contralateral eye. Indirect pupillary light response allows the evaluation of retinal function, even with a blood-filled anterior chamber, as long as the contralateral pupil is visible. Iridocyclitis manifests as conjunctivitis, corneal edema, miosis, and hypotony. Glaucoma and retinal detachment are generally associated with a mydriatic pupil. When hyphema is attributable to a systemic disease process, the contralateral eye may also have clinical signs suggestive of the disease. Funduscopic examination allows direct visualization of delicate vascular structures (retinal and choroidal vasculature) and central nervous tissue (optic nerve head, retina). Ocular signs suggestive of systemic vasculitis are frequently detected during examination of the fundus.

Depending on the cause and severity of blood-ocular barrier breakdown and the presence of iridocyclitis, aqueous flare (predominantly proteins), hypopyon, or hyphema may appear in the anterior chamber. The clinical appearance of hyphema is influenced by the volume of erythrocytes in the anterior chamber and by how long they have been present and may differ substantially from case to case. The term *complete* or *total hyphema* is used to describe hemorrhage filling the entire anterior chamber and is usually a result of acute fulminant or recurrent hemorrhage (Figure 2).

Complete hyphema obstructs the examiner's ability to visualize intraocular structures.

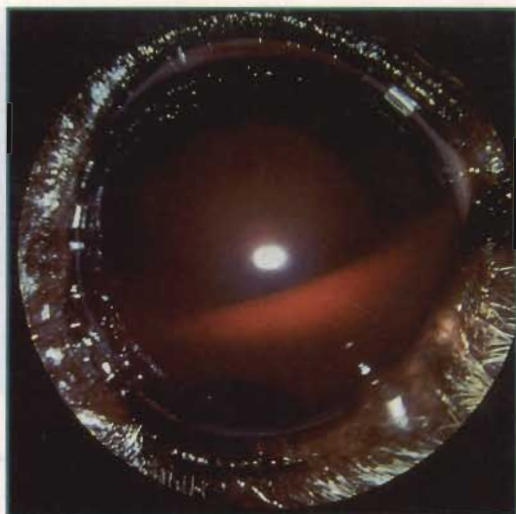
The blood in a complete hyphema may change color from red to black as a result of altered aqueous dynamics, indicating the cessation of aqueous circulation.<sup>2</sup> If hemorrhage was initially minimal and transitory, hy-

phema is light red in appearance. This type of hyphema may develop a shallow line of demarcation (i.e., gravity line) when erythrocytes settle due to gravity in a homogeneous layer in the ventral anterior chamber (Figure 3). Extensive or persistent hemorrhage into the anterior chamber appears bright red in color and may occlude both the pupil and iris. Complete hyphema attributable to transient hemorrhage that has been present for at least 5 to 7 days appears dark red or bluish-black and is referred to as *eight-ball hyphema* (Figure 4).<sup>3</sup> Decreased oxygenation of erythrocytes in the anterior chamber is reflected by the dark color.<sup>2</sup> Chronic active hyphema may appear light or dark red or bluish-black, depending on when the last active hemorrhage occurred. Occlusion of the pupil by hyphema may cause a relative pupillary block that inhibits aqueous circulation to the anterior chamber, resulting in subsequent elevated intraocular pressure (IOP).

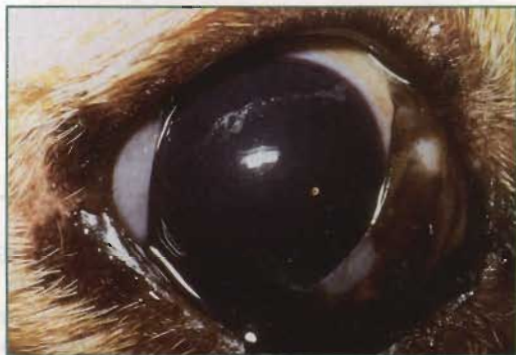There are definitive circumstances that determine when blood in the anterior chamber may or may not clot. Hyphema caused by trauma, vasculitis (e.g., feline infectious peritonitis [FIP]), or iridocyclitis may clot, whereas hyphema attributable to immune-mediated thrombocytopenia or warfarin toxicity generally will not clot.<sup>3</sup> Hyphema attributable to rubeosis iridis (new vascular proliferation of the iris), intraocular neoplasia, or congenital ocular anomalies may occasionally clot.<sup>3</sup>

### EXPANDED DATABASE

Laboratory tests should be performed based on findings from the history and physical examination. A direct blood smear permits rapid estimation of platelet and megathrombocyte numbers and the detection of erythrocyte and leukocyte involvement (e.g., presence of schistocytosis or *Haemobartonella*). Platelets, leukocytes, and erythrocytes should be evaluated by a complete blood count (CBC); the three cell lines may be affected individually (e.g., thrombocytopenia) or con-



**Figure 3**—Hyphema with gravity line. Erythrocytes settle due to gravity in a homogeneous layer in the ventral anterior chamber.



**Figure 4**—Dark red or bluish-black appearance of eight-ball hyphema.

currently (e.g., bone-marrow disease). If bone-marrow disease is suspected based on CBC results, aspiration cytology with or without core biopsy is indicated.<sup>4</sup> Serum biochemical profile and urinalysis may help identify such underlying abnormalities as liver disease, renal insufficiency, or hyperadrenocorticism.

Indications for selecting more specific diagnostic tests are determined by history, physical examination findings, and initial diagnostic test results. Evaluation for infectious diseases should be performed if suggested by geographic location, travel history, or exposure to other risk factors. *Toxoplasma gondii*, feline leukemia virus (FeLV), feline immunodeficiency virus (FIV), and FIP infection and possibly systemic fungal diseases should be considered when hyphema is evident in a cat.<sup>5</sup> The seroprevalence of *T. gondii* in cats with iridocyclitis was reported to be as high as 78.5%.<sup>5</sup> However, serologic evidence of infection by *T. gondii*, FeLV, FIV, or FIP does not necessarily correlate with clinical disease induced by these causative agents.<sup>5</sup> When a systemic bleeding disorder is suspected, a coagulation profile should be completed.<sup>4</sup>

Sampling of aqueous humor to determine local intraocular antibody production is not indicated in patients with hyphema because the sample will be contaminated with systemic blood. When hyphema prevents visualization of intraocular structures, transcorneal B-mode ultrasound (7.5- to 12-MHz transducer) is indicated to determine whether retinal detachment or intraocular tumors are present or to identify other ocular lesions (e.g., luxated lens, intraocular foreign body).<sup>6</sup> Skull radiographs, computed tomography, or magnetic resonance imaging may also reveal an intraocular foreign body, depending on the type or composite. When a metallic intraocular foreign body is suspected, magnetic resonance imaging should be avoided and computed tomography performed. Retinal function can be evaluated using electroretinography.<sup>7</sup>

## TREATMENT

Primary management issues in animals with hyphema include preventing secondary hemorrhage (i.e., rebleeding) by (1) treating the underlying disease, (2) treating iridocyclitis, and (3) controlling secondary glaucoma (Table I). There is considerable variation among specific treatment regimens to eliminate blood from the anterior chamber, but the hallmark of hyphema

is management of the iridocyclitis that is frequently present. Erythrocytes exit the anterior chamber primarily through the iridocorneal drainage angle. The iris produces enough fibrinolytic enzymes in most instances to prevent blood from clotting so that it can more easily exit the anterior chamber via the aqueous humor outflow pathways. Uncomplicated hyphema should resolve within 7 to 21 days.<sup>3</sup> Hyphema that

**TABLE I**  
Treatment of Hyphema<sup>a,b</sup>

Disorder	Drug Class	Drug	Frequency/Dose
Iridocyclitis <sup>3,8</sup>	Topical parasympatholytics	Atropine 1% (use ointment in cats)	1–4 times daily
	Topical corticosteroids	Prednisolone acetate suspension 1%, dexamethasone solution 0.1%	4–6 times daily
		Dexamethasone ointment 0.05%	3–4 times daily
	Topical NSAIDs	Flurbiprofen 0.03%, suprofen 1%, indomethacin 1%, diclofenac 0.1%	4 times daily
	Systemic corticosteroids	Prednisone	1–2 mg/kg/day in divided doses
	Systemic NSAIDs	Aspirin	<b>Dogs:</b> 10–15 mg/kg PO 2–3 times daily <b>Cats:</b> 80 mg PO every 48–72 hr
Flunixin meglumine		<b>Dogs:</b> 0.25–0.5 mg/kg IV, single dose	
Carprofen		<b>Dogs:</b> 2 mg/kg PO twice daily	
Blood or fibrin clot <sup>3,9</sup>	Fibrinolytics	Tissue plasminogen activator	25–75 µg intracamerally
Secondary glaucoma <sup>10,11</sup>	Systemic carbonic anhydrase inhibitors	Dichlorphenamide	<b>Dogs:</b> 2–4 mg/kg PO 2–3 times daily <b>Cats:</b> 1 mg/kg PO 2–3 times daily
		Methazolamide	2–4 mg/kg PO 2–3 times daily
	Topical carbonic anhydrase inhibitors	Dorzolamide 3%	3 times daily
	Topical sympathomimetic drugs	Epinephrine 1%, dipivefrin HCl 0.1%	2–3 times daily
	Topical sympatholytic drugs	Timolol maleate 0.5%	2–3 times daily
	Osmotic agents	Mannitol	0.5–1.0 g/kg IV

<sup>a</sup>See text for details.

<sup>b</sup>Underlying diseases should be treated first in cases of hyphema.

IV = intravenously; PO = orally.

continues to bleed may indicate that the underlying disease is still present. Surgical removal of a blood clot with or without iridectomy is discussed in the human medical literature<sup>2,12</sup> and is rarely necessary in human or veterinary patients.

Prevention of a posterior synechiae and iris bombé is achieved with the use of topical parasympatholytics (e.g., atropine) to dilate the pupil and topical corticosteroids to suppress anterior uveitis (Table I). In addition to preventing synechiae, topical atropine (a topical mydriatic and cycloplegic drug) also relieves some pain associated with spasm of the ciliary musculature and helps to stabilize the blood–aqueous barrier.<sup>13–15</sup> If an increase in IOP is noted after the initiation of mydriatic treatment, atropine should be discontinued immediately and glaucoma treatment initiated.<sup>3</sup>

Topical use of parasympathomimetic drugs (e.g., pilocarpine) to treat hyphema has been advocated to contract the ciliary muscle, which hypothetically facilitates drainage of blood from the anterior chamber through the iridocorneal angle.<sup>16</sup> Parasympathomimetic drugs also cause miosis, which increases iris surface area, thereby hypothetically exposing iris surface fibrinolysins to the clot and blood in the anterior chamber.<sup>16</sup> We do not recommend using topical parasympathomimetic drugs to treat hyphema; they dilate iris blood vessels and increase iridal intravascular pressure, which may exacerbate hyphema. Because these drugs induce miosis, the risk of posterior synechiae formation, iris bombé, and peripheral anterior synechiae formation is increased.

Nonspecific reduction of ocular inflammation to preserve the transparency and function of ocular structures and stabilize the blood–aqueous barrier can be achieved with topical corticosteroids and/or NSAIDs (Table I).<sup>13,17</sup> Topical corticosteroids are contraindicated when corneal ulceration is present. Systemic administration of NSAIDs can further decrease inflammation but should also be used very cautiously because of their interference with platelet function. Systemic corticosteroids (e.g., prednisone, prednisolone) should be used cautiously and only when systemic infectious disease has been ruled out or is being treated concurrently. Systemic immunosuppressive doses of corticosteroids and systemic carbonic anhydrase inhibitors may help to reattach retinas in patients with exudative detachments.<sup>18,19</sup>

Although the use of antifibrinolytic agents in the management of hyphema is controversial, intracameral injection of tissue plasminogen activator (tPA) to induce fibrinolysis can be performed to reverse a pupillary block when the iris is adhered to the lens by a blood or fibrin clot (Table I).<sup>3,9,12</sup> tPA is most effective

when injected within 48 hours of clot formation, but it can also be effective in dissolving clots of longer duration.<sup>3</sup> However, tPA injections may also induce hyphema or result in more severe hyphema from dissolution of a blood clot when given within 24 hours of the initial hemorrhage or when recurrent bleeding is likely.<sup>3,9</sup>

Surgical intervention and concurrent systemic and topical treatment with antibiotics should be considered when hyphema results from penetrating ocular injury or blunt trauma with eyeball rupture. Restricted exercise or even cage rest is recommended to prevent rebleeding. Animals with hyphema may need to be hospitalized for close monitoring of possible secondary hemorrhages and elevation of IOP. IOP should be measured at least daily during the hospital stay and frequently after discharge.<sup>12,16</sup> We do not recommend Schiotz tonometry in animals with weakened corneas caused by penetrating trauma.

If secondary glaucoma develops due to anterior or posterior synechiae of the iris, treatment can be attempted (e.g., intracameral tPA and antiglaucoma drugs) but the prognosis to save vision is poor. When the eyeball is irreversibly blind or painful from secondary glaucoma, enucleation should be performed. Medical treatment of secondary glaucoma consists of a combination of systemic or topical carbonic anhydrase inhibitors, topical sympathomimetic drugs, and sympatholytic drugs (Table I). Osmotic agents are less effective with a leaky blood–ocular barrier. Because of the risk of posterior synechiae, parasympathomimetic drugs (e.g., pilocarpine) are contraindicated.

## COMPLICATIONS

Mild hyphema may resolve without significant sequelae. The main complications of persistent hyphema are increased IOP, peripheral anterior and posterior synechiae, development of cataracts, and an increased risk of corneal blood staining attributable to endothelial damage and breaks in Descemet's membrane.<sup>12</sup> If an underlying disease persists and hemorrhage is recurrent, atrophy of the eyeball (phthisis bulbi) and blindness are usually the long-term results.

## PROGNOSIS

Prognosis for vision in geriatric dogs with hyphema secondary to retinal disease is grave.<sup>20</sup> In cases of unexplained, unresponsive, or recurring hyphema, the diagnosis must be reassessed. Prognosis is grave for any hyphema in which an unknown underlying systemic disease persists. In such cases, enucleation is recommended if the IOP rises to levels that cause pain. When intraocular neoplasia is known or strongly suspected as the cause for hyphema, the affected eye should be enu-

cleated and submitted for histopathologic evaluation.<sup>3</sup> If the underlying cause is nonrecurring or treated and IOP does not increase, an accurate prognosis for return of the eye to cosmetic and visual normalcy can be made once resorption of the hemorrhage allows a complete intraocular examination.<sup>3</sup> It is difficult to predict whether hyphema will resorb.

## REFERENCES

- Henik RA: Systemic hypertension and its management. *Vet Clin North Am Small Anim Pract* 27(6):1355-1372, 1997.
- Folberg R, Parrish RK: Glaucoma following trauma, in Tasman W, Jaeger EA (eds): *Duane's Ophthalmology, Clinical Volume 3, CD-ROM Edition*. Hagerstown, MD, Lippincott-Raven, 1998.
- Collins BK, Moore CP: Diseases and surgery of the canine anterior uvea, in Gelatt KN (ed): *Veterinary Ophthalmology*, ed 3. Baltimore, Lippincott Williams & Wilkins, 1999, pp 755-795.
- Hackner SG: Approach to the diagnosis of bleeding disorders. *Compend Contin Educ Pract Vet* 17(3):331-349, 1995.
- Chavkin MJ, Lappin MR, Powell CC, et al: Seroepidemiologic and clinical observations of 93 cases of uveitis in cats. *Prog Vet Comp Ophthalmol* 2(1):29-36, 1992.
- Williams J, Wilkie DA: Ultrasonography of the eye. *Compend Contin Educ Pract Vet* 18(6):667-676, 1996.
- Komaromy AM, Smith PJ, Brooks DE: Electroretinography in dogs and cats. Part II. Technique, interpretation, and indications. *Compend Contin Educ Pract Vet* 20(3):355-366, 1998.
- Wilkie DA: Uvea, in Birchard SJ, Sherding RG (eds): *Saunders Manual of Small Animal Practice*. Philadelphia, WB Saunders Co, 1994, pp 1213-1216.
- Martin C, Kaswan R, Gratzek A, et al: Ocular use of tissue plasminogen activator in companion animals. *Prog Vet Comp Ophthalmol* 3(1):29-36, 1993.
- Wilkie DA: Glaucoma, in Birchard SJ, Sherding RG (eds): *Saunders Manual of Small Animal Practice*. Philadelphia, WB Saunders Co, 1994, pp 1217-1222.
- Gelatt KN, Brooks DE: The canine glaucomas, in Gelatt KN (ed): *Veterinary Ophthalmology*, ed 3. Baltimore, Lippincott Williams & Wilkins, 1999, pp 701-754.
- Gottsch JD: Hyphema: Diagnosis and management. *Retina* 10(Suppl 1):S65-S71, 1990.
- Bistner S: Allergic- and immunologic-mediated diseases of the eye and adnexae. *Vet Clin North Am Small Anim Pract* 24(4):711-734, 1994.
- Swan KC, Hart WM: A comparative study of the effects of mecholyl, doryl, eserine, pilocarpine, atropine, and epinephrine on the blood-aqueous barrier. *Am J Ophthalmol* 23(12):1311-1319, 1940.
- Van Alphen GWHM, Macri FJ: Entrance of fluorescein into aqueous humor of cat eye. *Arch Ophthalmol* 75(2):247-253, 1966.
- Winston SM: Ocular emergencies. *Vet Clin North Am Small Anim Pract* 11(1):59-76, 1981.
- Ward DA, Ferguson DC, Ward SL, et al: Comparison of the blood-aqueous barrier stabilizing effects of steroidal and non-steroidal anti-inflammatory agents in the dog. *Prog Vet Comp Ophthalmol* 2(3):117-124, 1992.
- Kita M, Marmor MF: Retinal adhesive force in living rabbit, cat, and monkey eyes. Normative data and enhancement by mannitol and acetazolamide. *Invest Ophthalmol Vis Sci* 33(6):1879-1882, 1992.
- Andrew SE, Abrams KL, Brooks DE, Kubilis PS: Clinical features of steroid responsive retinal detachments in twenty-two dogs. *Prog Vet Comp Ophthalmol* 7(2):82-87, 1997.
- Nelms SR, Nasisse MP, Davidson MG, Kirschner SE: Hyphema associated with retinal disease in dogs: 17 cases (1986-1991). *JAVMA* 202(8):1289-1292, 1993.

## About the Authors

Drs. Komaromy, Brooks, Kallberg, and Andrew are affiliated with the Department of Small Animal Clinical Sciences, College of Veterinary Medicine, University of Florida, Gainesville, Florida. Drs. David and Cynthia Ramsey are affiliated with the Department of Small Animal Clinical Sciences, College of Veterinary Medicine, Michigan State University, East Lansing, Michigan. Drs. David Ramsey, Brooks, and Andrew are Diplomates of the American College of Veterinary Ophthalmologists. Dr. Cynthia Ramsey is a Diplomate of the American College of Veterinary Internal Medicine and the American College of Veterinary Emergency Medicine and Critical Care.

## ARTICLE #4 CE TEST

The article you have read qualifies for 1.5 contact hours of Continuing Education Credit from the Auburn University College of Veterinary Medicine. Choose only the one best answer to each of the following questions; then mark your answers on the test form inserted in *Compendium*.

- The dark red or bluish-black color of eight-ball hyphema indicates decreased
  - oxygenation of the animal.
  - ocular blood flow.
  - oxygenation of erythrocytes in the anterior chamber.
  - none of the above
- Which of the following must be considered in cats with intraocular hemorrhage?
  - FIP
  - systemic hypertension
  - T. gondii*
  - all of the above
- Sampling of aqueous humor from an eye with hyphema to determine intraocular antibody production is not indicated because
  - there is no intraocular antibody production.
  - the aqueous humor is contaminated with antibodies from systemic circulation.
  - possible complications (e.g., a dramatic drop in IOP).
  - Sampling of aqueous humor is indicated in eyes with hyphema.

(continues on page 96)



**Hyphema** (continued from page 79)

4. When hyphema is present, a complete history should include questions regarding
  - a. geographic location of residence/travel history.
  - b. recent administration of medication.
  - c. past illnesses/recent visual impairment.
  - d. all of the above
5. In an eye with hyphema, the condition of the retina can be assessed with
  - a. indirect pupillary light response (if the contralateral pupil is visible).
  - b. transcorneal B-mode ultrasound.
  - c. electroretinography.
  - d. all of the above
6. \_\_\_\_\_ is not caused by topical atropine.
  - a. Mydriasis
  - b. Cycloplegia
  - c. Miosis
  - d. Stabilization of the blood-aqueous barrier
7. Use of topical corticosteroids is contraindicated in patients with
  - a. anterior uveitis.
  - b. cataract.
  - c. corneal ulcer.
  - d. conjunctivitis.
8. How fast does uncomplicated hyphema generally resolve?
  - a. 1 day
  - b. 7 to 21 days
  - c. 3 months
  - d. 6 months
9. \_\_\_\_\_ is not a complication of hyphema.
  - a. Optic neuritis
  - b. Glaucoma
  - c. Anterior and posterior synechiae of the iris
  - d. Corneal blood staining
10. \_\_\_\_\_ should not be used to treat iridocyclitis.
  - a. Topical pilocarpine
  - b. Topical atropine
  - c. Topical prednisolone acetate
  - d. Systemic prednisolone

**Index to Advertisers****Small Animal**

Bayer Agriculture Division Animal Health	
Advantage .....	39, 41, 43
Drontal Plus .....	14, 15
Classic Medical Supply	
Ultrasound Equipment .....	59
Fort Dodge Animal Health	
Duramune Vaccines .....	Cover 4
Pain Management Fact Sheet .....	Insert
Innovative Veterinary Diets	
Limited Ingredient Diets .....	4-5
Western Veterinary Conference Symposium .....	60
Mark Morris Institute	
<i>Small Animal Clinical Nutrition</i> .....	34
Merck Publishing Group	
<i>Merck Veterinary Manual CD-ROM</i> .....	53
Nature's Formula Health Products	
Liquid Herbal Remedies .....	16
Novartis	
Clomicalm .....	Cover 2-1
Program .....	26-27
Nutramax Laboratories	
Cosequin .....	6
Pfizer Animal Health	
CoughGuard B, Vanguard 5/B, NasaGuard-B .....	8
Revolution .....	46-47, 48
Zeniquin .....	22-23, 28
Schering-Plough Animal Health	
Galaxy Parvo .....	67
Orbax .....	31, 32-33
Synbionics	
Witness HW .....	11
Veterinary Learning Systems	
VetShow.com .....	Cover 3
Veterinary Products Laboratories	
Flexus Plus .....	71

**Equine**

Fort Dodge Animal Health	
Pinnacle I.N. ....	80
Vetstream	
CD-Equis .....	85

**Food Animal**

Veterinary Learning Systems	
<i>Compendium Reprints</i> .....	S24
<i>Emergency Medicine in Small Animal Practice</i> .....	S2

**OCTOBER 1999  
QUIZ ANSWERS****ARTICLE #1**

Renal Effects of Nonsteroidal Antiinflammatory Drugs—S. D. Forrester,

G. C. Troy

- |      |      |      |      |       |
|------|------|------|------|-------|
| 1. e | 2. d | 3. b | 4. e | 5. a  |
| 6. e | 7. a | 8. b | 9. c | 10. d |

**ARTICLE #2**

Acute Thoracolumbar Disk Extrusion in Dogs. Part I—R. M. Jerram,

C. W. Dewey

- |      |      |      |      |       |
|------|------|------|------|-------|
| 1. b | 2. a | 3. d | 4. a | 5. c  |
| 6. b | 7. c | 8. d | 9. c | 10. a |

**ARTICLE #3**

The Avian Respiratory System—S. E. Orosz

- |      |      |      |      |       |
|------|------|------|------|-------|
| 1. a | 2. c | 3. b | 4. d | 5. b  |
| 6. c | 7. d | 8. a | 9. b | 10. a |

**ARTICLE #4**

Basic Blepharoplasty Techniques—H. L. Hamilton, R. D. Whitley,

S. A. McLaughlin, S. F. Swaim

- |      |      |      |      |       |
|------|------|------|------|-------|
| 1. b | 2. d | 3. d | 4. c | 5. a  |
| 6. d | 7. b | 8. e | 9. a | 10. c |

**ARTICLE #5**

A Practitioner's Guide to Necropsy—E. A. Sartin, J. S. Spano, T. L. Hathcock

- |      |      |      |      |       |
|------|------|------|------|-------|
| 1. b | 2. a | 3. c | 4. d | 5. d  |
| 6. d | 7. d | 8. a | 9. c | 10. d |

**ARTICLE #6**

Diagnosing Equine Protozoal Myeloencephalitis: Complicating Factors—

B. G. Benz, W. G. Carter, T. Tobin

- |      |      |      |      |       |
|------|------|------|------|-------|
| 1. d | 2. a | 3. b | 4. c | 5. a  |
| 6. c | 7. d | 8. b | 9. c | 10. c |

**ARTICLE #7**

Agricultural Economics for Veterinarians: Marketing Beef Cow Herds—

R. L. Larson, V. L. Pierce

- |      |      |      |      |       |
|------|------|------|------|-------|
| 1. d | 2. c | 3. c | 4. a | 5. c  |
| 6. a | 7. b | 8. d | 9. a | 10. c |

**ARTICLE #8**

Cryptosporidiosis—G. L. Stokka, J. D. VanBoening, R. Ridley, D. Van Metre,

R. Falkner

- |      |      |      |      |       |
|------|------|------|------|-------|
| 1. d | 2. a | 3. d | 4. d | 5. c  |
| 6. d | 7. b | 8. d | 9. a | 10. d |