

THE EFFECTS OF REPEATED INJECTIONS OF CHORIONIC GONADOTROPIN ON THE TESTES OF THE LEOPARD FROG (*RANA PIPIENS* SCHREBER)

ROBERT P. McCOURT

Department of Zoology and Entomology, The Ohio State University, Columbus 10

Although certain aspects of the effects of chorionic gonadotropin of human pregnancy urine on male salientia have been described, there is no information concerning the effects of repeated injections of the hormone on the testes and in particular on the process of spermatogenesis. It is commonly known that injections of chorionic gonadotropin of pregnancy urine cause release of sperm from the testes of male frogs and toads. This is the basis of the well known male amphibian pregnancy test.

Studies of the seasonal cycle of spermatogenesis in *Rana pipiens* have been undertaken by several writers. Rugh (1939) and Glass and Rugh (1944) described the meiotic stages present (including spermatozoa) at different seasons of the year. They described the effects of injections of macerated frog anterior pituitary on sperm release but mentioned nothing concerning the effects of the hormone on spermatogenesis. Biesinger and Miller (1952) described the same cycle and also described the effects of both injections of frog anterior pituitary and chorionic gonadotropin from human pregnancy urine on sperm release but mentioned nothing concerning the effects of either of these hormones on spermatogenesis. Van Oordt *et al* (1951) found that repeated injections of "gestyl" (a gonadotropic hormone extracted from the serum of pregnant mares) or of frog anterior pituitary stimulated spermatogenesis in hibernating *Rana temporaria*. However, injections of "gestyl" did not cause the release of spermatozoa. This study describes the effects of repeated injections of commercial chorionic gonadotropin on the testes and on spermatogenesis.

MATERIALS AND METHODS

The experimental animal used was the male leopard frog (*Rana pipiens* Schreber). A weight of 30 gms was used as a minimum indication of sexual maturity. The animals were received from Alburg, Vermont, in January and were kept under refrigeration at approximately 7°C and were not fed until the completion of the experiment in February. The chorionic gonadotropin used was purchased under the brand name "A. P. L." and is extracted from human pregnancy urine. The supply used was obtained from the Ohio State University Hospital, Columbus 10, Ohio.

The experimental animals were given two daily injections of 2 cc of chorionic gonadotropin (25 International Units per cc) for a period of 8 days. At the end of this time immature sperm or a considerable decrease in the quantity of sperm released could be detected by microscopic examination of the urine of the frogs. At intervals of three days following the injections, the testes of two of the frogs were removed and prepared for study. The testes of the injected frogs were compared with testes taken from uninjected control animals and with accounts given by Rugh (1939), Glass and Rugh (1944), and Biesinger and Miller (1952). All tissues were fixed with Bouin's solution, dehydrated and cleared in dioxan, sectioned at ten microns, and stained with Delafield's haematoxylin.

RESULTS

The testis of the frog is surrounded by an extremely thin peritoneum consisting of elongate epithelial cells. Beneath this is a connective tissue capsule (tunica albuginea) which extends into the interior of the testis between the seminiferous tubules. Between the seminiferous tubules is the interstitial tissue consisting of ovoid, granular cells. Within the testis are the radially arranged seminiferous tubules. Most of them converge at the center of the testis where there are longitudinal collecting tubules leading to the vasa efferentia. The tubules terminate blindly beneath the tunica albuginea and in many cases branch before reaching the periphery. These relationships are shown in figure 1. The seminiferous tubules are composed of large spindle-shaped epithelial cells which form a complete membrane around each tubule. Within the tubules of the hibernating frog the most conspicuous cells are the mature spermatozoa. They appear as darkly staining rod-shaped bodies and are clustered around the larger sertoli cells which are frequently binucleated. The tails of the spermatozoa lie free within the lumen of the tubule but in most cases they are not visible as they do not stain with haematoxylin. In some cases spermatogonia can be seen just beneath the epithelial layer. They are small rounded cells in contrast to the larger ovoid sertoli cells and the smaller spindle-shaped epithelial cells. In most cases no more than a single layer was present although in a few cases there were two layers of these cells. In no case was there any evidence of primary or secondary spermatocytes although in a few cases late spermatid stages were present. These relationships are shown in figures 1 and 2.

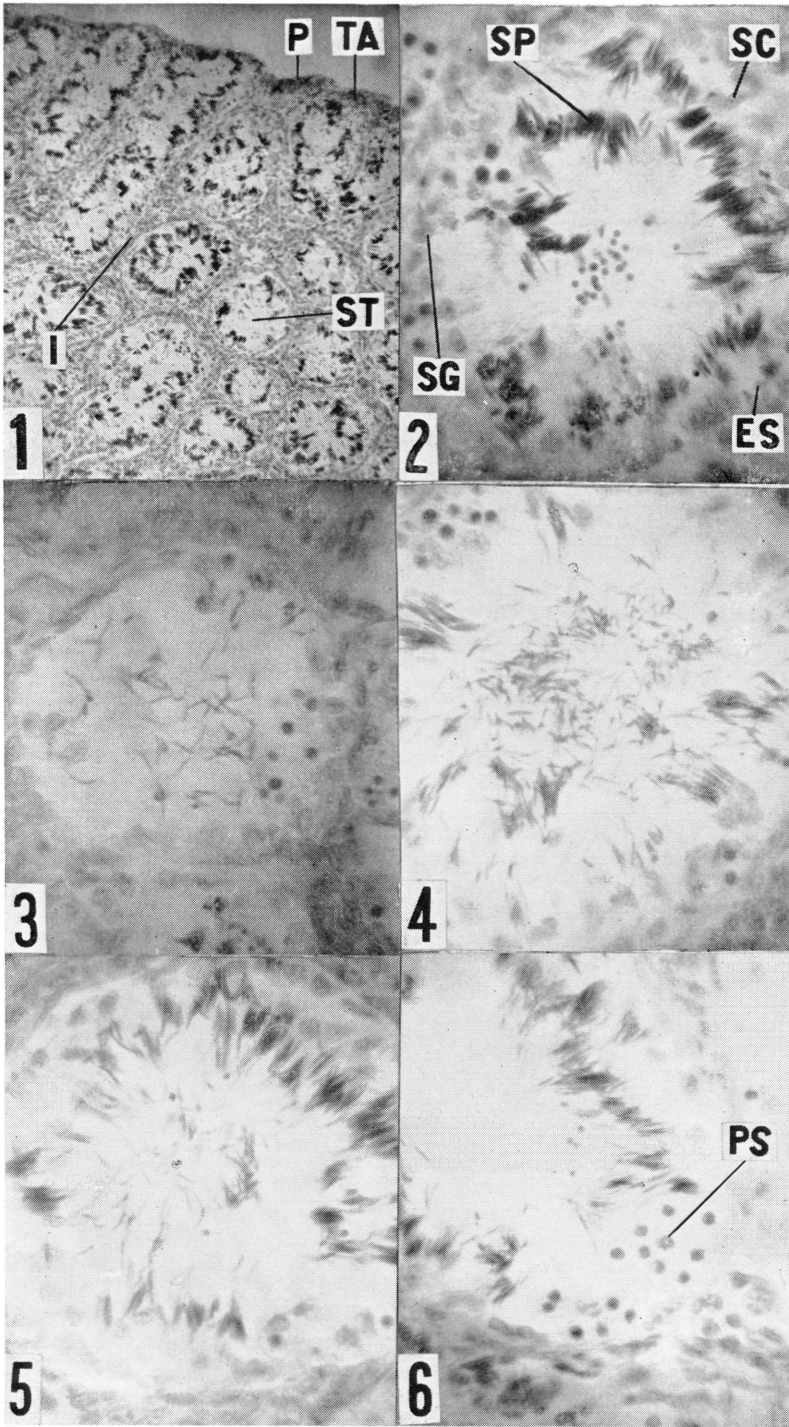
Upon examination of the sectioned testes of the injected animals the most striking difference was the release of the mature spermatozoa. However, it must be pointed out that great differences existed in the amount of sperm released from different seminiferous tubules. In some cases the tubules were empty except for a few sperm in the lumen (fig. 3). In other cases large numbers of sperm still remained in the lumen (fig. 4). In others, large numbers of sperm were still attached to the sertoli cells while many were free in the lumen (fig. 5). These three types of tubules may exist in the same section indicating that sperm release is not uniform throughout any individual testis. In many cases a striking relationship was obvious. The anterior portion of the testis was virtually devoid

EXPLANATION OF FIGURES IN PLATE

1. Section through the testis of an uninjected hibernating frog. 88 X.
2. Section through the testis of an uninjected hibernating frog showing one seminiferous tubule. 366 X.
3. Section through the testis of an injected frog showing almost complete release of spermatozoa from one seminiferous tubule. 366 X.
4. Section through the testis of an injected frog showing moderate release of spermatozoa from one seminiferous tubule. 366 X.
5. Section through the testis of an injected frog showing almost no release of spermatozoa from one seminiferous tubule. 366 X.
6. Section through the testis of an injected frog showing prophase stages of primary spermatocytes. 366 X.

ABBREVIATIONS USED IN FIGURES

- ES. Epithelium of seminiferous tubule.
 I. Interstitial tissue.
 P. Peritoneum.
 PS. Prophase stages of primary spermatocytes.
 SC. Sertoli cell.
 SG. Spermatogonium.
 SP. Mature spermatozoa.
 ST. Seminiferous tubule.
 TA. Tunica albuginea.



of sperm. Progressing towards the posterior end the quantity of sperm in the tubules increased and the posterior portion of the testis was virtually unaffected. Although Biesinger (1951) reported an increase in the size of the seminiferous tubules, it was not apparent in the sections studied. The variation in tubule size in the testis of the control animals made it impossible to determine whether changes had occurred.

Other changes were not apparent in the sections made soon after the completion of the injections but became obvious in sections made more than ten days after the injections had been stopped. The first of these was a decrease in the extent of the interstitial tissue. Although this difference was apparent only in areas where sperm release was extensive it was striking in these cases. This agrees with the changes occurring in the normal seasonal cycle following the breeding season as reported by Glass and Rugh (1944). Although Rugh (1939) and Glass and Rugh (1944) reported that there was no change in the interstitial tissue following injections of frog anterior pituitary, they did not give repeated injections nor did they examine the testes after more than forty-eight hours following the injections. It is apparent, then, that this change is due either to repeated injections or that it does not become visible until sometime after the injections.

The other change was the appearance of prophase stages of primary spermatocytes. They were interpreted as leptotene, zygotene and pachytene stages of the first meiotic division. Examples of these cells are shown in figure 6. The occurrence of these stages was in no way related to the amount of sperm released in that particular area of the testis or to the amount of sperm released in that particular testis. These stages may be found in tubules which are almost devoid of sperm or in tubules which are affected only to a limited extent. This agrees with the work of Van Oordt *et al* (1951) who found that injections of "gestyl" stimulated spermatogenesis although no spermatozoa were released.

DISCUSSION

Little information is available concerning the mechanism of sperm release in amphibians, either after injections of chorionic gonadotropin of human pregnancy urine or in the normal sexual cycle. It has been suggested by Rugh (1939) that smooth muscle is involved. In this study no positive evidence of the presence of smooth muscle in the testis could be found. Further studies and the use of special staining techniques are now being undertaken in an attempt to answer this question. Another possible cause of sperm release is pressure produced by the diffusion of fluid into the testicular cells. Giltz and Miller (1950) found that injections of large quantities (10 to 12 cc) of distilled water caused the release of spermatozoa. Undoubtedly there are many factors involved. This investigation is a preliminary attempt to determine some of the effects of chorionic gonadotropin other than the release of spermatozoa.

SUMMARY AND CONCLUSIONS

1. The testis of the hibernating frog (*Rana pipiens* Schreber) is characterized by the presence of mature spermatozoa attached to sertoli cells at the periphery of the seminiferous tubules and the absence of maturation stages (primary and secondary spermatocytes).

2. Injections of chorionic gonadotropin of human pregnancy urine cause the release of spermatozoa from the testes of the frog into the urine where they can be examined microscopically.

3. The testis shows several changes following repeated injections of the hormone. They are a decrease in the extent of the interstitial tissue and the appearance of prophase stages of primary spermatocytes. Sperm release is not uniform throughout any individual testis.

4. The beginning of maturation is a result of an increase in gonadotropin rather than the release of spermatozoa while the decrease in the extent of the interstitial tissue is apparently related to the release of spermatozoa.

ACKNOWLEDGMENTS

The writer wishes to express his thanks to Dr. David F. Miller and Dr. John W. Price for their assistance during the course of this investigation.

LITERATURE CITED

- Biesinger, D. I.** 1951. A study of seasonal variation and hormone induced changes in the gonads of the male frog, *Rana pipiens*. Ph.D. diss., The Ohio State University, Columbus.
- Biesinger, D. I., and D. F. Miller.** 1952. Seasonal and hormone induced changes in the testes of *Rana pipiens*. Ohio Jour. Sci., 52: 169-175.
- Giltz, M. L., and D. F. Miller.** 1950. Ways of improving the male frog test for pregnancy. Ohio Jour. Sci., 50: 205-209.
- Glass, F. M., and R. Rugh.** 1944. Seasonal study of normal and pituitary stimulated frog *Rana pipiens*. Jour. Morph., 74: 409-428.
- Rugh, R.** 1939. Reproductive processes of the male *Rana pipiens*. Jour. Exp. Zool., 80: 81-105.
- Van Oordt, G. J., J. W. Sluiter, and P. G. W. J. Van Oordt.** 1951. Spermatogenesis in normal and hypophysectomized frogs (*Rana temporaria*) following gonadotrophin administration. Acta. Endocrin., 7: 257-269.
-