

# BRIEF REPORT

Pediatric Dermatology 1–2, 2016

## Congenital Milium of the Nipple

**Abstract:** A 12-month-old girl presented with an asymptomatic, pearly nodule on the left nipple that had been present from birth and was currently 3 mm in diameter and growing. Assuming the diagnosis of congenital primary milium of the nipple, we took a “wait and see” approach. After 3 months, the pearl disappeared without any scarring.

A 12-month-old girl presented with a solitary, pearly nodule on her left nipple that had been present since birth and was currently 3 mm in diameter and growing. There were no associated signs or symptoms. The lesion was firm and hard on palpation. There was no underlying mass in the breast tissue and the contour of the areola was not changed (Fig. 1). Her right breast was normal and no other lesions were found. Her growth and psychomotor development were normal. With the diagnosis of congenital primary milium of the nipple, an autolimited course was expected and no diagnostic tests were performed.

Three months later, the pearl spontaneously disappeared without scarring. One year later, her nipples and areola were normal and symmetric.

### DISCUSSION

The differential diagnosis of a solitary pearl in the nipple included milia, syringoma with milia-like structures, trichoepithelioma, fibroma, milia-like idiopathic calcinosis cutis, and neonatal fibroadnexal polyp (1,2). Only milia and fibroadnexal polyp could be congenital, both are common and autolimited (1,2). The absence of a pedicle, typical of fibroadnexal polyp, justified our “wait and see” approach, as we chose not to perform a biopsy and histologic study of the girl’s nipple.

Milia (singular: milium) appear as papules ranging from white to yellow, similar to a pearl on the skin, and are typically less than 3 mm in diameter (3). They are tiny inclusion cysts within the epidermis that

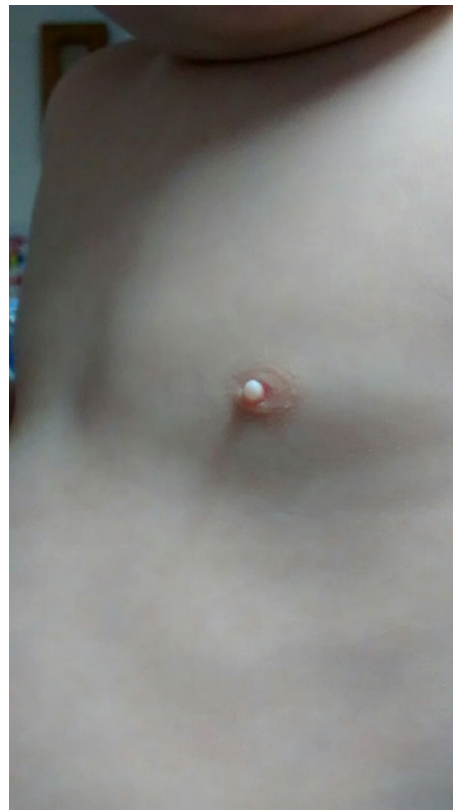
contain concentric layers of trapped keratinized stratum corneum (1,3).

The lesion may be primary or secondary (1,3). Primary milia may be congenital or have onset later in life and arise spontaneously. Secondary milia arise after prolonged trauma or other injuries to the skin at places with a predisposing condition or some chronic medications (1,3).

Congenital primary milia are seen in up to 40% to 50% of full-term newborns, without significant racial or sex differences (1). They may be less common and of delayed onset in premature newborns (1). They most commonly occur as lesions in the area of the vellus hair follicles, cheeks, nose, and eyelids, but can be found anywhere (1,3). They are usually discrete, but the number of lesions may vary from a few to a few hundred, as multiple eruptive milia (3). Larger, solitary lesions can be seen on the foreskin, scrotum, areola, and vulva (1,3).

Pearls in the areola are frequent, but involvement of the nipple seems to be rare. We found three published cases of milia in the nipple and only one was congenital (Table 1) (1,4,5).

The diagnosis of milia is clinical. Acquired milia tend to be long-standing. Congenital milia generally



**Figure 1.** Pearly white lesion on the left nipple.

DOI: 10.1111/pde.13010

**TABLE 1.** *Cases of Milia of the Nipple*

Reference	Age, months	Sex	Ethnicity	Past medical history	Duration before presentation	Primary complaint or incidental finding	Size, mm	Symptoms	Diagnostic test	Follow-up
Jain et al (5)	15	Female	Not described	Not described	2 months (mechanical trauma—squeezing)	Primary complaint	8	Pain	Excisional biopsy	Not known
Park et al (1)	16	Male	Not described	None	Probably congenital	Primary complaint	5	Asymptomatic	Ultrasonography, excisional biopsy	Not known
Spyropoulou et al (4)	6	Female	Not described	Not described	1 month	Primary complaint	5	Asymptomatic	Excisional biopsy	Not known

disappear spontaneously, mostly during the third or fourth week of life, although a few may persist until the third month or after (1,3). Pearls in areas of great friction or subject to trauma and recurrent bleeding may need excision.

Because milia resolve spontaneously, excision on the nipple or areola in a female child may result in unnecessary aesthetic and functional sequelae.

#### REFERENCES

1. Park J, Kim JI, Kim DW et al. Congenital primary milium of the nipple. *Dermatolog Sinica* 2014;32:129–130.
2. Costa AL, Betloch I, Perez-Crespo M et al. Mammary skin tag in a 2-year-old girl: a long-lasting adnexal polyp of neonatal skin? *Pediatr Dermatol* 2009;26:618–620.
3. Berk DR, Bayliss SJ. Milia: a review and classification. *J Am Acad Dermatol* 2008;59:1050–1063.
4. Spyropoulou GA, Pavlidis L, Trakatelli M et al. Rare benign tumours of the nipple. *J Eur Acad Dermatol Venereol* 2015;29:7–13.
5. Jain S, Sarkar R, Garg VK et al. Epidermal inclusion cyst or giant milium of the nipple. *Indian J Dermatol Venereol Leprol* 2012;78:103–105.

Muriel Guarda Ferreira, M.D.  
 Manuel Baptista Salgado, M.D.  
 Ambulatory Pediatric Service, Children's Hospital, Centro Hospitalar e Universitário de Coimbra, Coimbra, Portugal

Address correspondence to Muriel Guarda Ferreira, M.D., Ambulatory Pediatric Service, Children's Hospital, Centro Hospitalar e Universitário de Coimbra, Coimbra, Portugal, Rua Dr. Afonso Romão, 3030 Coimbra, Portugal, or e-mail: [murielguardaferreira@gmail.com](mailto:murielguardaferreira@gmail.com).