

Case 1590

Prolapsed submucosal uterine leiomyoma

C. Oliveira, S. Vinhais, T. M. Cunha

INSTITUTO PORTUGUÊS DE ONCOLOGIA de Francisco Gentil de LISBOA

Section: Genital (Female) Imaging

Published: 2002, Nov. 24

Patient: 30 year(s), female

Clinical Summary

A patient with menorrhagia and dysmenorrhoea underwent an MRI study which revealed an uncommon presentation of a very common uterine pathology.

Clinical History and Imaging Procedures

The patient was admitted after several episodes of menorrhagia (anaemia of 5-8g/dl), and pelvic pain. Two days prior to admission, a pelvic and transvaginal ultrasound was performed, which revealed a submucosal uterine leiomyoma. Afterwards, during admission, an MRI study was made, leading to the diagnosis of prolapsed submucosal uterine leiomyoma. A hysterectomy was performed.

Discussion

Uterine leiomyoma, the most frequent solid uterine neoplasm (accounting for approximately 30% of all hysterectomies performed in the US), is a benign lesion composed mainly of smooth muscle with varying amounts of fibrous connective tissue elements. As leiomyomas enlarge, they may outgrow their blood supply, resulting in various types of degeneration such as hyaline, myxoid, cystic and red degeneration.

Uterine leiomyomas develop during the reproductive years in 20-30% of women, may grow rapidly during pregnancy or contraceptive use and usually regress after the menopause, which suggests an important role of oestrogen and progesterone in their growth.

These lesions, which may be single or multiple, are classified according to their position in the uterus as submucosal, intramural or subserous. Submucosal leiomyomas constitute only 5% of uterine

leiomyomas, may be pedunculated and may prolapse from the uterine cavity. The prevalence of prolapsing submucosal leiomyomas was 2.5% in a population of 1785 women undergoing abdominal surgery for uterine leiomyomas.[1] Submucosal leiomyomas can be asymptomatic or may present with menorrhagia, dysmenorrhoea, infertility, pelvic pressure or as a palpable mass lesion.

Although ultrasound (specially transvaginal ultrasound) can often diagnose and characterise leiomyomas, MRI is the most accurate imaging technique for detection, localisation and characterisation of leiomyomas. In respect of submucosal leiomyomas, MRI is also better than ultrasonography in determining the presence of prolapse, its caudal extent and location of the stalk.

Most commonly, non-degenerated uterine leiomyomas are well-circumscribed masses of homogeneously decreased signal intensity compared with that of the adjacent myometrium on T1- and especially on T2-weighted images. On the other hand, cellular leiomyomas, which are composed mainly of compact smooth muscle cells, can show relatively higher signal on T2-weighted images and show enhancement on contrast-enhanced images. Leiomyomas appear to be delineated by a discrete low signal intensity margin. Sometimes a high intensity rim may be seen surrounding these lesions on T2-weighted images, which corresponds to dilated lymphatics, dilated veins or oedema. Central or diffuse areas of increased signal intensity may be evident in certain types of degeneration such as in the cystic or myxoid types.

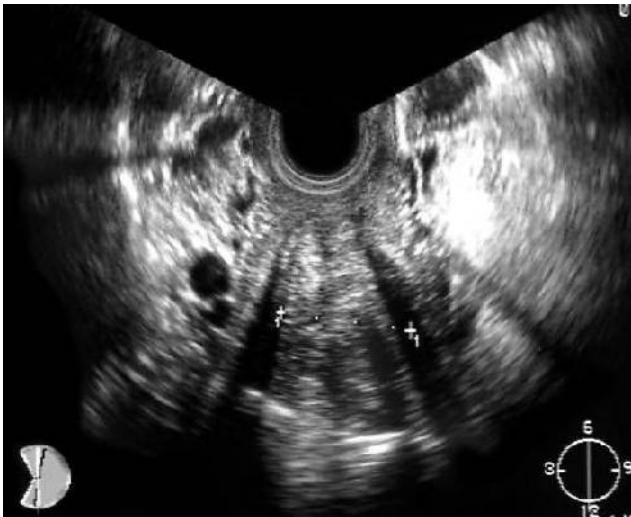In addition to making an accurate diagnosis and characterisation of these lesions, MRI can assist in pre-treatment planning by selecting the lesions which are more suitable for the different treatment modalities such as hysteroscopic resection (for submucosal-intramural leiomyomas) or transabdominal or laparoscopic myomectomy (for intramural and subserosal leiomyomas). Further, MRI can demonstrate post-surgical complications such as haematoma, abscess, fistula, uterine rupture and peritoneal inclusion cyst. MRI can also monitor for changes in size of individual lesions as well as of the uterus during GnRH analogue therapy. Three-dimensional contrast-enhanced MRI arteriography can show the uterine arteries thus providing important data when planning for leiomyoma embolisation; MRI can also be used after embolisation in order to demonstrate the degree of shrinkage and loss of enhancement of the leiomyomas.

Final Diagnosis

Prolapsed submucosal uterine leiomyoma

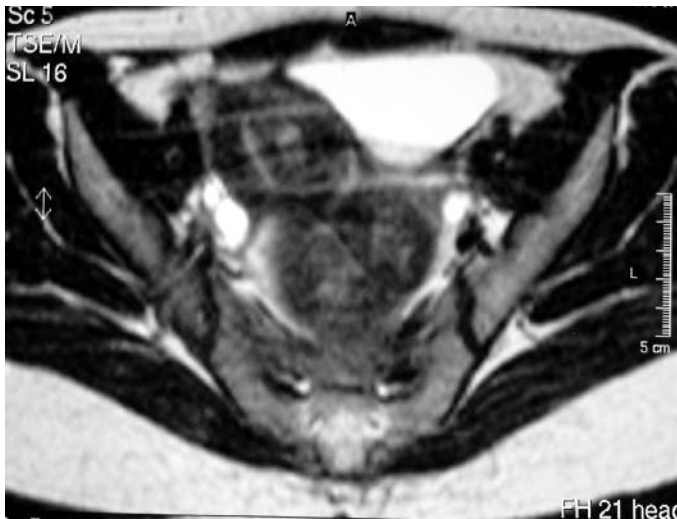
Figures

Figure 1

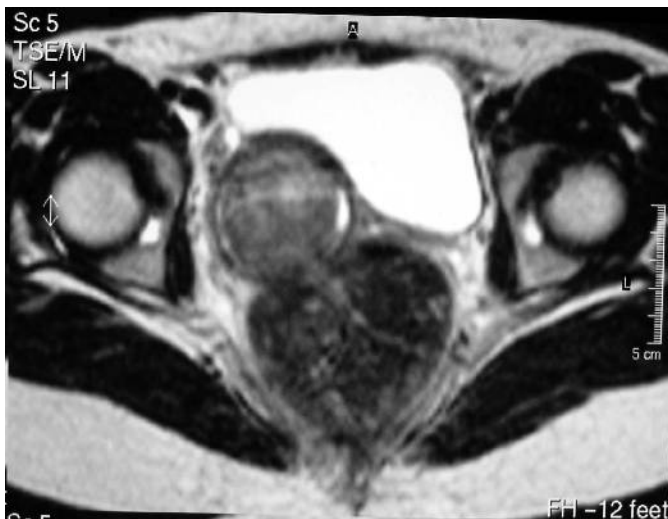

A uterine leiomyoma is evident. It seems to display intramural/submucous growth.

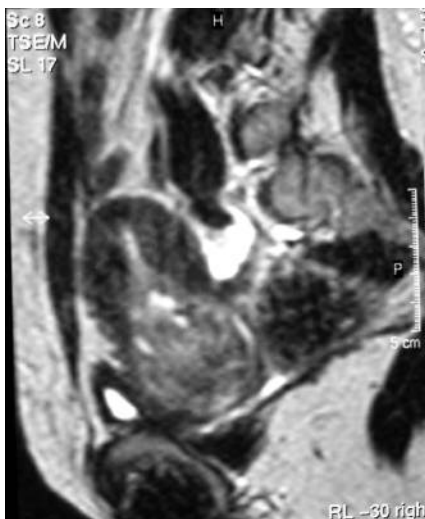Figure 2



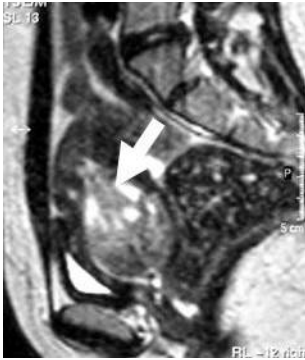This axial T2-weighted image is at the level of the body of the uterus. The leiomyoma is partially identified as a heterogeneous, lesion of intermediate signal intensity inside the uterine cavity.



This axial T2-weighted image is at the level of the uterine cervix. The leiomyoma is already protruding through the cervical canal.

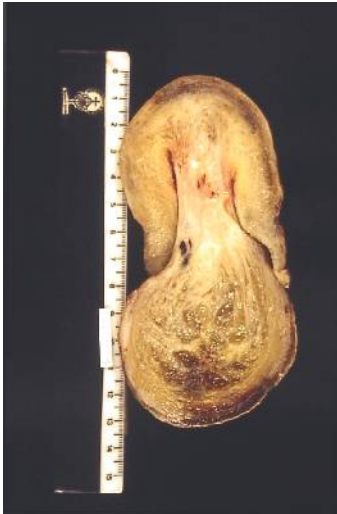

This sagittal T2-weighted uterine scan shows the leiomyoma (intermediate signal intensity, heterogeneous) protruding through the cervical canal. Cystic/myxoid degeneration is present as areas of high signal intensity.



This parasagittal T2-weighted uterine scan was performed to the left of the previous one and clearly depicts the leiomyoma's stalk (white arrow).

Figure 3



Hysterectomy specimen shows a prolapsing leiomyoma. The stalk implantation point is clearly evident. Degeneration of the cystic/myxoid type is also seen.

MeSH

Uterine Neoplasms [C04.588.945.418.948]

Tumors or cancer of the UTERUS.

Cervix Neoplasms [C13.371.270.875.170]

Tumors or cancer of the uterine cervix.

References

- [1] Panageas E, Kier R, McCauley TR, McCarthy S. Submucosal uterine leiomyomas: diagnosis of prolapse into the cervix and vagina based on MR imaging. *AJR Am J Roentgenol.* 1992 Sep;159(3):555-8.
- [2] Sherer DM, Schwartz BM, Otero FJ, Eisenberg C, Abulafia O. Transvaginal sonographic depiction of aborting pedunculated intracavitary uterine leiomyoma. *J Clin Ultrasound.* 1999 Sep;27(7):405-8.
- [3] Murase E, Siegelman ES, Outwater EK, Perez-Jaffe LA, Tureck RW. Uterine leiomyomas: histopathologic features, MR imaging findings, differential diagnosis, and treatment. *Radiographics.* 1999

Sep-Oct;19(5):1179-97.

[4] Park KH, Chung JE, Kim JY, Kim YT Endoscopic management of uterine myoma Yonsei Med J 1999 Dec;40(6):583-8

[5] Spies JB, Roth AR, Jha RC, Gomez-Jorge J, Levy EB, Chang TC, Ascher SA Leiomyomata treated with uterine artery embolization: factors associated with successful symptom and imaging outcome. Radiology. 2002 Jan;222(1):45-52

Citation

C. Oliveira, S. Vinhais, T. M. Cunha (2002, Nov. 24)

Prolapsed submucosal uterine leiomyoma {Online}

URL: <http://www.eurorad.org/case.php?id=1590>